

Coprolalia in aphasic patients with stroke: a longitudinal observation from the BLAS₂T database

Fazlallah Afshangian, Mohammad Nami, Amin Abolhasani Foroughi, Amir Rahimi, Ryan Husak, Franco Fabbro, Barbara Tomasino, Christine Kremer & for the BLAS₂T (Bilingual Aphasia in Stroke-Study Team)

To cite this article: Fazlallah Afshangian, Mohammad Nami, Amin Abolhasani Foroughi, Amir Rahimi, Ryan Husak, Franco Fabbro, Barbara Tomasino, Christine Kremer & for the BLAS₂T (Bilingual Aphasia in Stroke-Study Team) (2017): Coprolalia in aphasic patients with stroke: a longitudinal observation from the BLAS₂T database, Neurocase, DOI: [10.1080/13554794.2017.1387274](https://doi.org/10.1080/13554794.2017.1387274)

To link to this article: <http://dx.doi.org/10.1080/13554794.2017.1387274>



Published online: 13 Oct 2017.



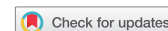Submit your article to this journal [↗](#)



View related articles [↗](#)



View Crossmark data [↗](#)



Coprolalia in aphasic patients with stroke: a longitudinal observation from the BLAS₂T database

Fazlallah Afshangian^a, Mohammad Nami^{b,c,d}, Amin Abolhasani Foroughi^{e,f}, Amir Rahimi^{g,h}, Ryan Husakⁱ, Franco Fabbro^j, Barbara Tomasino^j, Christine Kremer^k and for the BLAS₂T (Bilingual Aphasia in Stroke-Study Team)*

^aDepartment of English Language, Faculty of Foreign Languages, Rodaki Institute of Higher Education, Tonekabon, Iran; ^bDepartment of Neuroscience, School of Advanced Medical Sciences and Technologies, Shiraz University of Medical Sciences, Shiraz, Iran; ^cNeuroscience Laboratory (Brain, Cognition and Behavior), Department of Neuroscience, School of Advanced Medical Sciences and Technologies, Shiraz University of Medical Sciences, Shiraz, Iran; ^dClinical Neurology Research Center, Shiraz University of Medical Sciences, Shiraz, Iran; ^eDepartment of Radiology, School of Medicine, Shiraz University of Medical Sciences, Shiraz, Iran; ^fMedical Imaging Research Center, Shiraz University of Medical Sciences, Shiraz, Iran; ^gDepartment of Molecular Medicine, School of Advanced Medical Sciences and Technologies, Shiraz University of Medical Sciences, Shiraz, Iran; ^hBioinformatics and Computational Biology Research Center, Shiraz University of Medical Sciences, Shiraz, Iran; ⁱSLP at Baptist Health Lexington, University of Kentucky, Lexington, KY, USA; ^jNeurolinguistic Unit, Scientific Institute "E.Medea", Udine, Italy; ^kNeurology Department, Skåne University Hospital, Department of Clinical Sciences, Lund University, Lund, Sweden

ABSTRACT

The BLAS₂T (bilingual aphasia in stroke-study team) initiative has been a multi-center attempt to investigate longitudinal changes in language function in a cohort of stroke subjects. This report discusses linguistic performance in four cases from the BLAS₂T database who demonstrated coprolalia as an irresistible urge to say obscene words. Coprolalia was found to partly resolve in a 30-day follow-up in three cases. Recognition of coprolalia and language recovery patterns in bilingual aphasic patients with stroke would potentially lead to their even better individualized care and neurolinguistic/cognitive rehabilitation.

ARTICLE HISTORY

Received 23 December 2016
Accepted 23 September 2017

KEYWORDS

Coprolalia; bilingual aphasia; stroke; linguistic performance; BLAS₂T

Introduction

Aphasia refers to the loss or impairment of verbal communication due to brain dysfunction leading to diminished language production, problem in perceiving spoken or written messages as well as impairment in repetition, naming, reading, or writing (Wright, Downey, Gravier, Love, & Shapiro, 2007). The condition typically results from lesions in cerebral areas of the dominant-hemisphere involved in the motor or sensory features of speech. Several types of lesions ranging from vascular to degenerative, traumatic, or neoplastic origin may lead to disordered language function (El Hachoui et al., 2016; Gialanella, Prometti, Vanoglio, Comini, & Santoro, 2016; Purdy, Wanigasekara, Canete, Moore, & McCann, 2016; Sekhon, Douglas, & Rose, 2015; Thiel & Zumbansen, 2016). A widely accepted classification categorizes aphasias into non-fluent (Broca's, transcortical motor, global and mixed transcortical) and fluent (anomic, conduction, Wernicke's, transcortical sensory and subcortical) types (Sinanovic, Mrkonjic, Zukic, Vidovic, & Imamovic, 2011).

Although there are growing number of individuals who speak other languages than mother tongue, the existing literature on aphasia in bilingual or polyglot subjects is scant (Khachatryan et al., 2016).

In the case of stroke, there exist a wide range of language deficits including aphasia, agraphia, acalculia, and alexia. Aphasia is the most prevalent neurocognitive consequence

of stroke found in nearly 30% of acute-phase stroke patients (Sinanovic et al., 2011).

Practically, language impairments due to stroke tend to recover spontaneously after 2 weeks (ischemic stroke) or within 4–8 weeks (hemorrhagic stroke) from the disease onset. In fact, it is the type and intensity of aphasia which greatly determines the recovery course and outcome of aphasia. The type and severity of the initial aphasia substantially defines the recovery course and outcome. Language impairments in individuals who experience an ischemic stroke often improve earlier (within a few weeks) than individuals who experience a hemorrhagic stroke. These individuals may not show considerable improvement in their language functioning until 4–8 weeks after stroke onset. While language impairments tend to improve naturally during the early phase of recovery, timely treatment is necessary to facilitate an optimal language recovery (Khachatryan et al., 2016; Sinanovic et al., 2011; Thiel & Zumbansen, 2016).

While both languages tend to be affected in bilingual aphasia after stroke, depending on factors such as the age of second-language (L2) acquisition, first language (L1) is more intensely disrupted in grammatical or syntactical processes. In some patients with bilingual aphasia following stroke, both languages are similarly affected while in others, L2 seems to marginally outperform. Whatever the case, in many instances spontaneous recovery may occur (Tscherren et al., 2011).

A rare language presentation in aphasic patients is coprolalia. The condition is characterized by uncontrolled use of curse words and obscene language. An important qualifier of this condition is that the utterance of obscene words or socially inappropriate and/or derogatory remarks is not merely uncontrolled but frankly involuntary and occurs out of social or emotional context. Moreover, coprolalia occurs in the absence of agitation and is not a form of verbal aggression or a verbal manifestation of a more generalized aggressive syndrome. This condition is shown to be linked to the disinhibition of limbic cortex–basal ganglia loops associated with activity in pre- and post-rolandic language regions, insula, thalamus, and cerebellum (Maia & Cardoso, 2001; Nuwer, 1982; Stern et al., 2000).

While coprolalia is often seen in Tourette's disorder (Daniel & Perry, 2016; Eddy & Cavanna, 2013; Ganos, Edwards, & Muller-Vahl, 2016; Kobierska, Sitek, Gocyla, & Janik, 2014; Massot-Tarrus et al., 2016; Muller-Vahl, 2012) and some patients with schizophrenia (Bowers & Pleydell-Pearce, 2011; Isaacs, 2014; Sinanovic et al., 2011), it is not considered as a common presentation in stroke patients (Sinanovic et al., 2011). In other words, coprolalia is a rare neurolinguistic presentation in subacute stroke mainly affecting the areas perfused by the posterior cerebral artery. Dysfunction in the limbic structures or serotonergic system following stroke is considered as the main underpinning cause for coprolalia (Sinanovic et al., 2011; Toscano et al., 2014). While aggressive behaviors in stroke are largely linked to hemispheric lesions in the territory of anterior, middle, and mainly posterior cerebral arteries, there is a lack of description in stroke patients with coprolalia (Chan, Campayo et al., 2006; Botez, Carrera, Maeder, & Bogousslavsky, 2007; Toscano et al., 2014). Meanwhile, the pathology may root in the dysfunction of limbic system, namely amygdala as well as the temporal and orbitofrontal cortices (Toscano et al., 2014).

From the BLAS₂T (bilingual aphasia in stroke-study team) database, in which we prospectively assessed stroke patients' language function, we have identified four cases of coprolalia following stroke. What attention-grabbing was the concurrence of coprolalia in few of our cases from the BLAS₂T database, not the potential effect that coprolalia might have on the recovery course of this cases from aphasia, and vice versa. As such, the present study is an association report without commenting on the causal-correlation links between coprolalia and bilingual aphasia. In other words, this observational study has meant to highlight the possibility of coprolalia presentation as an incidental finding in bilingual aphasic cases and not the mutual effects of the two conditions.

Below we portray and discuss the clinical vignettes and neurolinguistic course of these cases with coprolalia, within a 30-day follow-up window after the onset of stroke.

Setting and patients

In line with operationalizing Cognitive Science and Technologies' Research and Development in our academic setting (Ashjzadeh et al., 2014), our multicentric attempt to register and prospectively follow patients with bilingual aphasia after stroke (BLAS₂T database) enabled us to study the

course of language function in such patients since 2014. Of patients enrolled from January 2014 to January 2015 ($n = 148$), four patients with stroke were found to have coprolalia (2.7%). The database excludes patients with prior history of stroke or significant neuropsychiatric illnesses. All enrolled patients underwent baseline evaluations as per related hospital protocols including brain computed tomography.

Four bilingual cases (speaking Farsi as L2 and either Azeri or Lurish as L1) with coprolalia were isolated to be discussed in the present report. The validated Bilingual Aphasia Test (BAT; Paradis, 2011) versions for L1 and L2 of our patients were used to assess the language function of these cases at day-1, -3, -7, -14, and -30 follow-up time-points. Meanwhile, given the repetition of the test, the potential learning effect was potentially considered as a threat to the result interpretation. However, while the repetition of the naming test in relatively close intervals could have, in principle, created learning effects, this effect has subjected to both L1 and L2.

Paradis not only developed the test but provided the theoretical foundations, description of the stimuli selection, cross-language equivalence, the overall assessment as well as implementation and scoring procedures and interpretation of results (Paradis, 2011). In our case, the BAT's manual was carefully consulted before the test was administered. This widely used and validated tool is available in nearly 60 language versions including Farsi, Azari, and Lurish, online at www.mcgill.ca/linguistics/research/bat/.

The BAT profile we assessed in our cases constituted 14 subscales including (1) pointing, (2) simple command, (3) verbal auditory discrimination, (4) naming, (5) series, (6) syntactic comprehension, (7) perception word, (8) lexical decision, (9) perception sentence, (10) antonym, (11) morphology, (12) semantic opposite, (13) synonym, and (14) listening comprehension, each scored from the scale of 0 to 10 (Nilipour, 2002; Paradis, 2011). Linguistic assessments were done for patients' L1 and L2 by a trained examiner (who spoke Lurish as L1, so could communicate the BAT's Farsi version in Lurish when assessing Lurish-speaking patients). The subscale performance results were used to evaluate the overall aphasia score.

All sessions' audios were recorded, carefully reviewed, and double-checked by a cognitive neuroscientist. Baseline axial routine protocols (with and without contrast) for brain computed tomography (Siemens, Germany; kV, effective mA s, rotation time (s) of 130 kV, 260 mA s, 2 s, respectively) were obtained from the patients and studied by a certified radiologist. The patient's performance in the related tasks upon BAT as well as their longitudinal trends in language function throughout the examination time-points, brain computed tomography finding, and behavioral features were evaluated.

Results

From the selected aphasic patients with coprolalia in subacute phase of stroke, three had ischemic (left occipital, right frontotemporal/left temporoparietal, and left temporal) and one had hemorrhagic (right thalamic) lesions. All patients exhibited coprolalia in the subacute phase which resolved in 30-day follow-up in three out of four cases. The overall aphasia scores were found to be roughly in favor of L2 in all coprolalia cases.

The temporal area was a more common site affected in our small series of stroke cases with coprolalia. Except for one case who displayed poorer function at day-30 follow-up compared to earlier time-points (perhaps due to boredom or depressed mood leading to lack of cooperation), all cases showed relative improvement of language tasks by time in our 30-day follow-up in both languages. This is in line with some earlier reports on linguistic performance in bilingual aphasics following stroke (Tschirren et al., 2011).

Case 1

M.P.N, an 85-year-old male, bilingual (L1: Lurish, L2: Farsi), right-handed, illiterate, case of hypertension, asthma, and mild cognitive impairments who developed expressive aphasia following left occipital ischemic stroke (no hemorrhage) on day-1, -3 and -7, and -14 poststroke follow-up. On/around day-20 follow-up, he started to use curse words mainly with strangers. He demonstrated marked memory impairment of anterograde amnesia type (as per the Mini-Mental State Examination). Meanwhile, he showed coprolalia. He was uncooperative and declined to receive speech therapy. Since admission, he received Acetylsalicylic acid (ASA) 80 mg po qd and atorvastatin 40 mg po qd, as well as risperidone, olanzapine, quetiapine, donepezil, and memantine for his neurocognitive and behavioral symptoms. In our longitudinal follow-up for L1 and L2 language function, this case showed a relatively favorable performance with an improving trend in most tasks, while the function showed an unexplained decline at day-30 follow-up. This has presumably been due to lack of cooperation secondary to boredom or mood change. The patient continued to use vulgar language at this point. His linguistic performance, longitudinal trend in language function, and baseline imaging are demonstrated in Figure 1.

Case 2

S.N., a 28-year-old female, bilingual (L1: Azari, L2: Farsi), right-handed, unemployed with 11 years' education, case of rheumatoid arthritis who developed global aphasia following right frontotemporal and left temporoparietal ischemic stroke, (no hemorrhage) on day-1, -3, and -7 poststroke follow-up. Having received speech therapy five times a week for minimum 30-min sessions and following hospital discharge, she started to improve with her motor aphasia while neurobehavioral symptoms including coprolalia and apraxia started to emerge. The condition continued to progress till day-30 follow-up. Despite swearing with the examiner, she often showed calm and coherent verbal communication with her family. Upon further follow-ups (day-60), she turned to use a more comprehensible language with almost fully resolved coprolalia. Since admission, she received ASA 80 mg po qd and atorvastatin 40 mg po qd. In our longitudinal follow-up for L1 and L2 language function, this case showed an overall poor performance in most and many tasks in L1 and L2, respectively. L2 was found to marginally outperform L1 on day-30 follow-up. Some tasks (e.g., repetition) which were unfavorable in L1 showed a better trend in L2 (Figure 2).

Case 3

M.P., a 37-year-old male, bilingual (L1: Azari, L2: Farsi), left-handed butcher, with 12 years education, and remote history of opium addiction who presented with global aphasia following right thalamic hemorrhagic stroke, on day-1 and -3 poststroke follow-up. On day-7 follow-up, he could mention family member names, while his non-fluent aphasia started to partially recover with repeated use of obscene language. He was communicating calmly with his siblings while using curse words with the medical personnel. Besides scheduled physical therapy for hemiparesis, the patient received speech therapy five times a week for minimum 30-min sessions, though continued to suffer Wernicke's aphasia and coprolalia up to day-30 follow-up. He was also transferred to psychiatry ward due to repeated cursing on week-2 follow-up. Since admission, he received ASA 80 mg po qd and atorvastatin 40 mg po qd. Moreover, atypical antipsychotics including risperidone, olanzapine, and quetiapine were administered upon his hospital course. In our longitudinal follow-up for L1 and L2 language function, the patient showed a notably better linguistic performance in L2 tasks by day-7 follow-up after which L2 started to regain. While both languages were found to remarkably improve by day-30 follow-up, L2 marginally outperformed at this point. Some tasks (e.g., syntactic comprehension, word repetition, and lexical decision) which poorly performed in L1, showed a better score in L2 throughout the follow-up (Figure 3).

Case 4

M.G., a 45-year-old male, bilingual (L1: Azari, L2: Farsi), right-handed tailor, with 12 years education, cigarette smoker, case of hyperlipidemia and hypertension, who presented with global aphasia following left temporal ischemic stroke (no hemorrhage), on day-1 and -3 poststroke follow-up. On day-7 follow-up, the patient started to excessively use repeated curse words exclusively with the medical staff and the examiner. He also showed visual agnosia upon cognitive examination on day-7 time-point. He received scheduled physical therapy for hemiparesis. Despite receiving speech therapy five times a week for minimum 30-min sessions, the patient continued to progress with aphasia (mainly of Wernicke's type) up to day-30 follow-up. At this point, he was found to remain coprolaliac (though to lesser extent) with medical staff but not family members. His other cognitive symptoms were pathologic fear and anterograde amnesia (as per the Mini-Mental State Examination). Despite being conscious and orient on day-30 follow-up, he was found to have lost L1 completely and could barely communicate in Farsi. He used L2 to curse. Since admission, he received ASA 80 mg po qd and atorvastatin 40 mg po qd. The longitudinal follow-up for L1 and L2 language functions revealed profoundly impaired linguistic function up to day-14 follow-up when he showed trivial improvement in word repetition and lexical decision tasks. He showed some improved function in L1 naming task by day-30. Besides a poor overall BAT score, he continued to use curse words and behave aggressively till day-30 follow-up after which he gradually used a less obscene language. The patient's linguistic

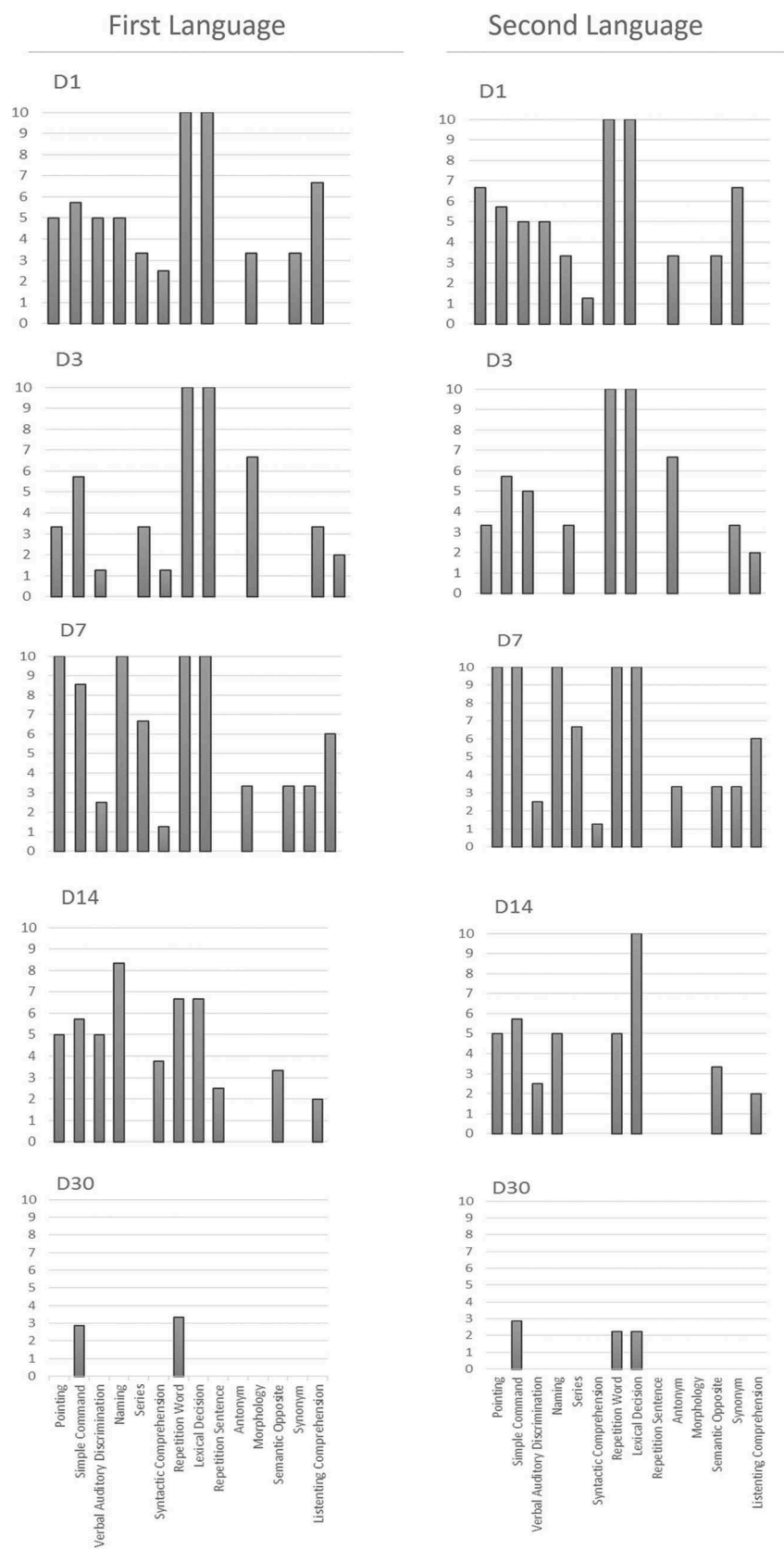
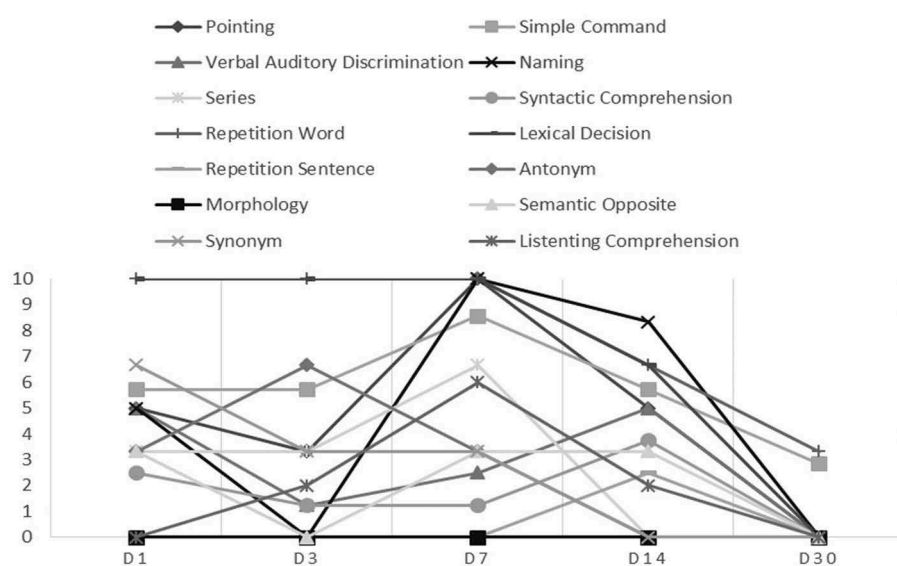


Figure 1. (a) MPN's Lurish (L1) and Farsi (L2) profiles on the BAT. (A) Language tasks including (from left to right) pointing, simple command, verbal auditory discrimination, naming, series, syntactic comprehension, perception word, lexical decision, perception sentence, antonym, morphology, semantic opposite, synonym, and listening comprehension were administered and scored according to the BAT manual for L1 (Lurish) and L2 (Farsi) from the scale of 0 to 10. Since there is no Lurish version of BAT available, the examiner's L1 (Lurish) was taken as the benchmark in communicating the equivalent Farsi version of BAT for the patient's L1. (b) The longitudinal trend for language function in L1 and L2 based on each task. (B) The abrupt decline on day-30 follow-up was perhaps due to his lack of cooperation, profound agitation while using obscene language (coprolalia). (C) MPN's baseline brain CT scan indicating left occipital ischemic stroke (no hemorrhage). BAT: Bilingual Aphasia Test; L1: first language; L2: second language.

First Language



Second Language

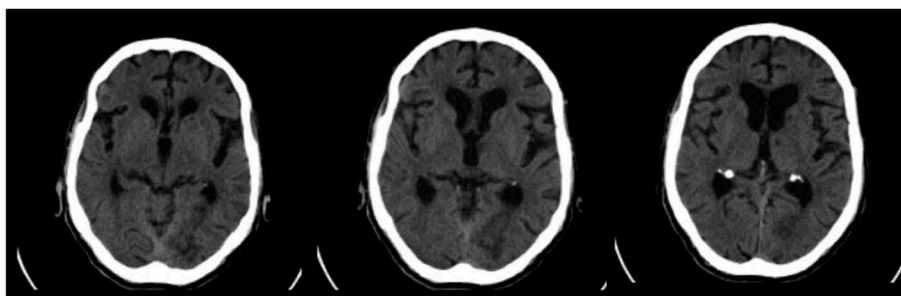
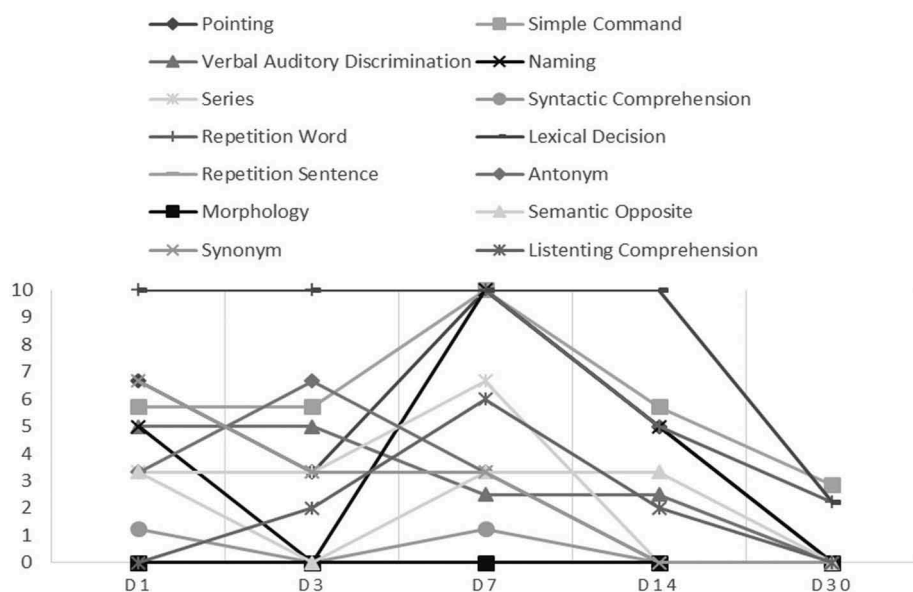


Figure 1. (Continued).

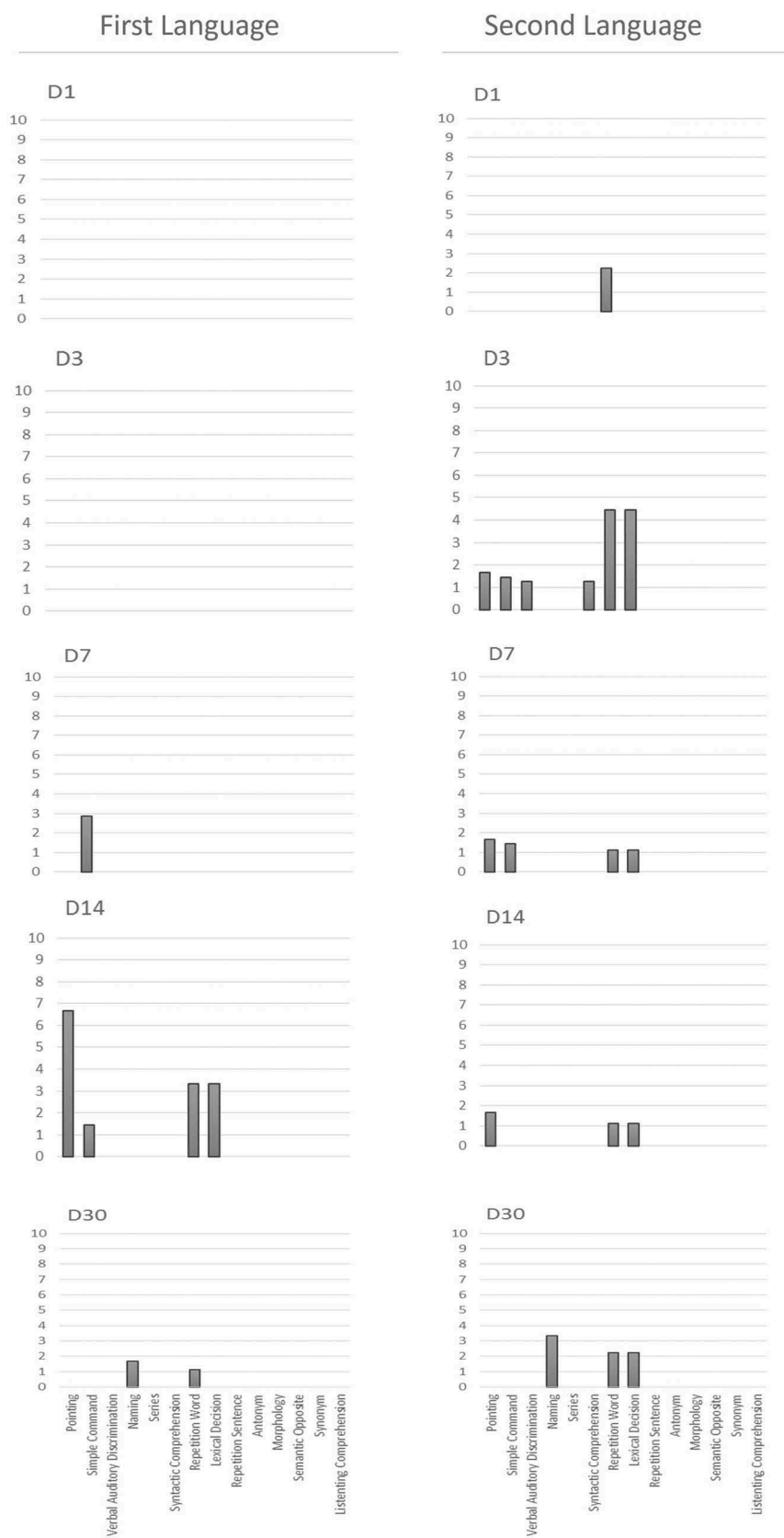
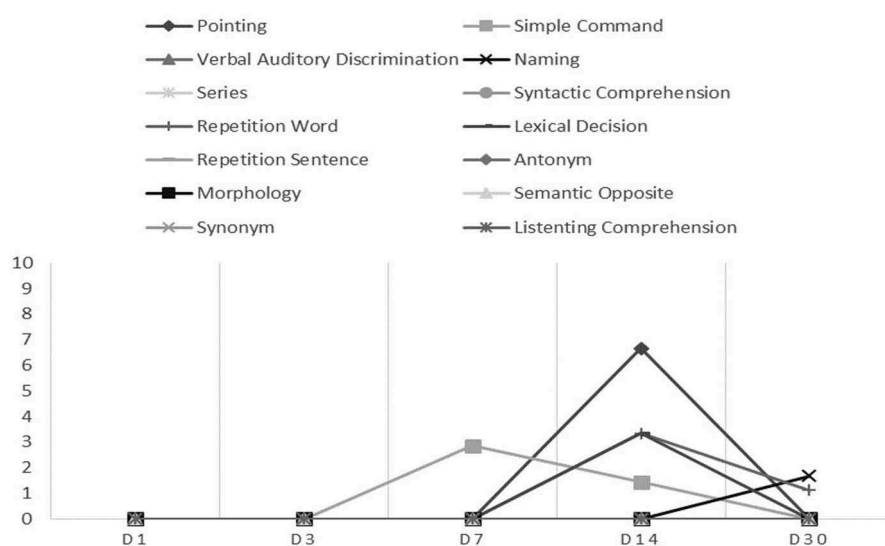


Figure 2. (a) SN's Azari (L1) and Farsi (L2) profiles on the BAT. (A) Language tasks including (from left to right) pointing, simple command, verbal auditory discrimination, naming, series, syntactic comprehension, perception word, lexical decision, perception sentence, antonym, morphology, semantic opposite, synonym, and listening comprehension were administered and scored according to the BAT manual for L1 (Azari) and L2 (Farsi) from the scale of 0–10. (b) The longitudinal trend for linguistic performance in L1 and L2 based on each task. (B) The patient showed an overall steadier trend for L2 tasks and demonstrated a more favorable L2 functions for naming, word repetition, and lexical decision tasks on day-30 follow-up. The patient's copropregia resolved at this point. (C) SN's baseline brain CT scan indicating right frontotemporal and left temporoparietal ischemic stroke with no hemorrhage. BAT: Bilingual Aphasia Test; L1: first language; L2: second language.

First Language



Second Language

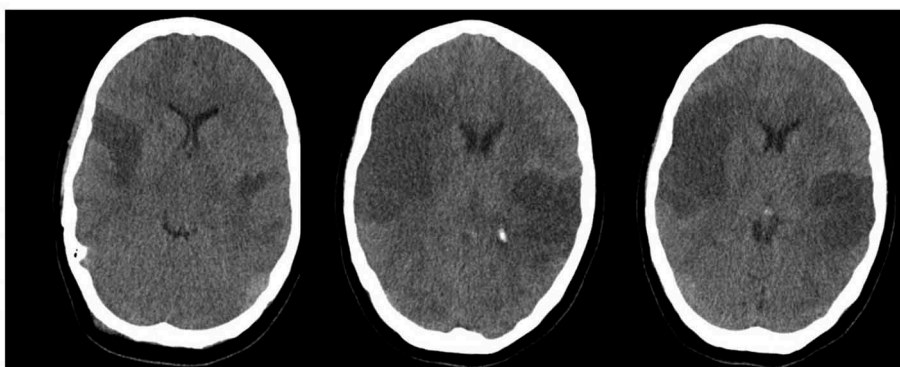
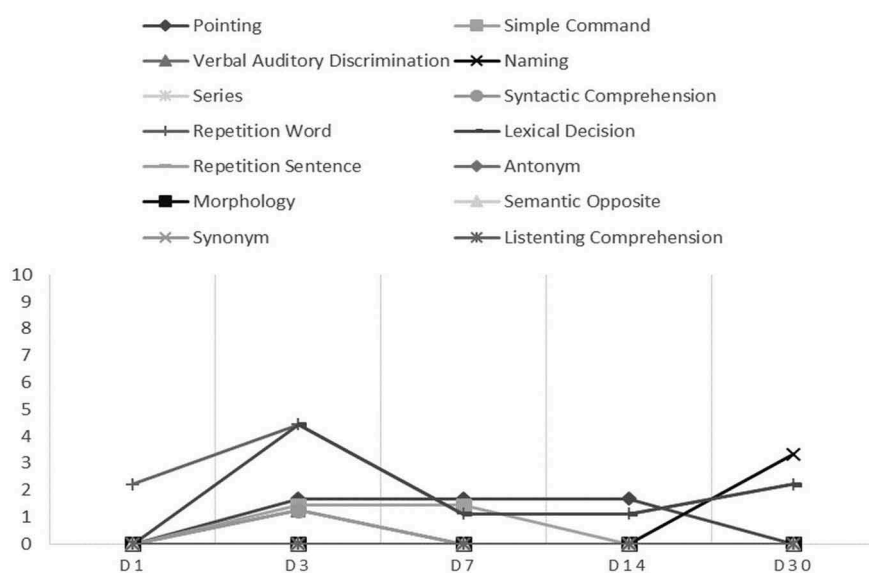


Figure 2. (Continued).

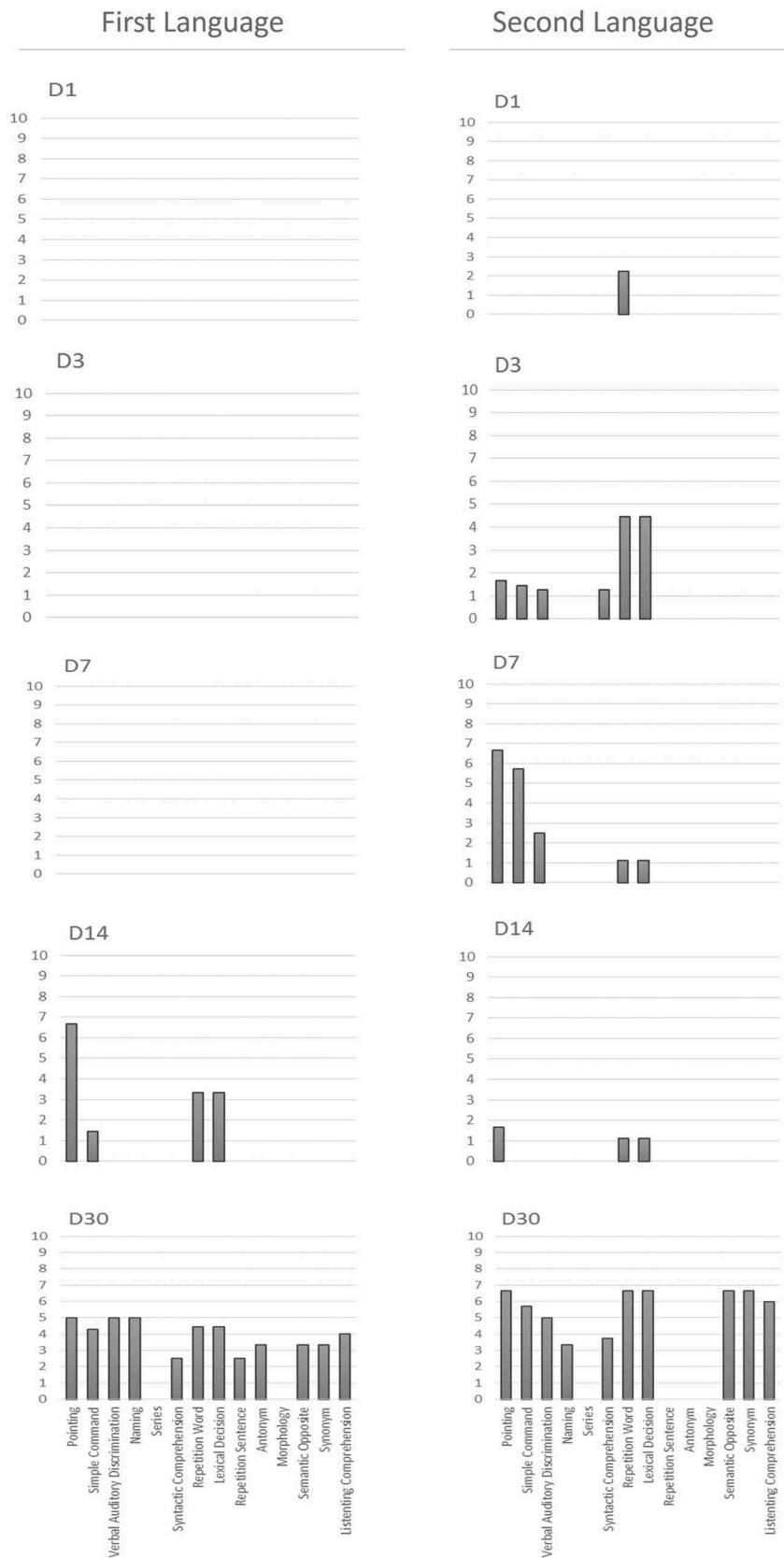
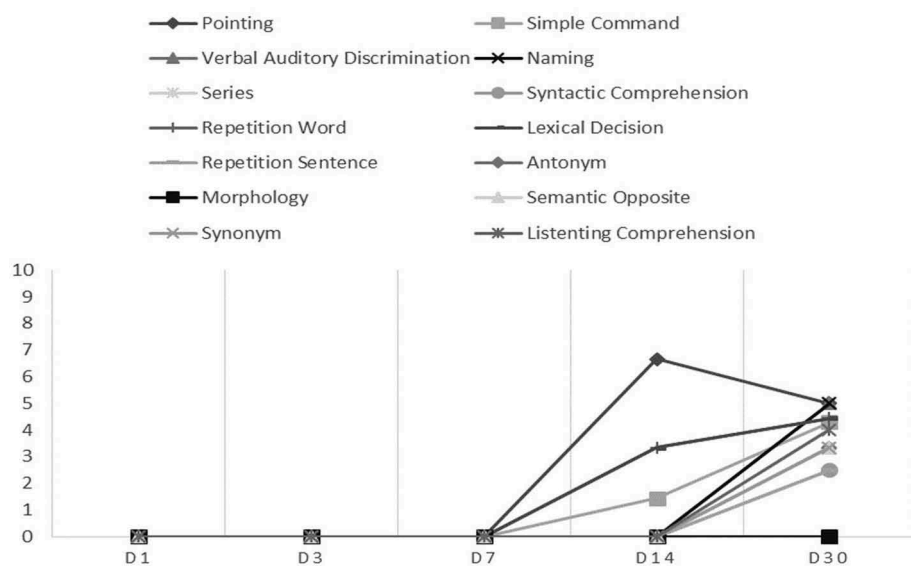


Figure 3. (a) MP's Azari (L1) and Farsi (L2) profiles on the BAT. (A) Language tasks including (from left to right) pointing, simple command, verbal auditory discrimination, naming, series, syntactic comprehension, perception word, lexical decision, perception sentence, antonym, morphology, semantic opposite, synonym, and listening comprehension were administered and scored according to the BAT manual for L1 (Azari) and L2 (Farsi) from the scale of 0–10. (b) The longitudinal trend for linguistic performance in L1 and L2 based on each task. (B) The patient's overall BAT score was lower in L1. While both L1 and L2 showed recovery by day-30 follow-up, L2 showed a marginally more favorable trend. The patient's coprolalia was markedly resolved by day 30. (C) MP's baseline brain CT scan indicating right thalamic hemorrhagic stroke. BAT: Bilingual Aphasia Test; L1: first language; L2: second language.

First Language



Second Language

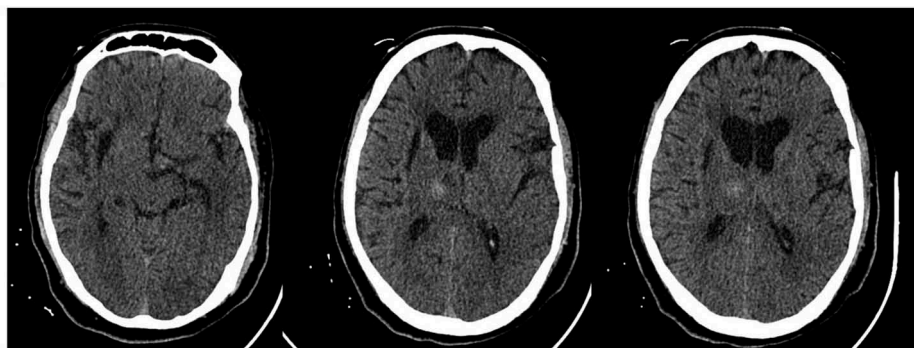
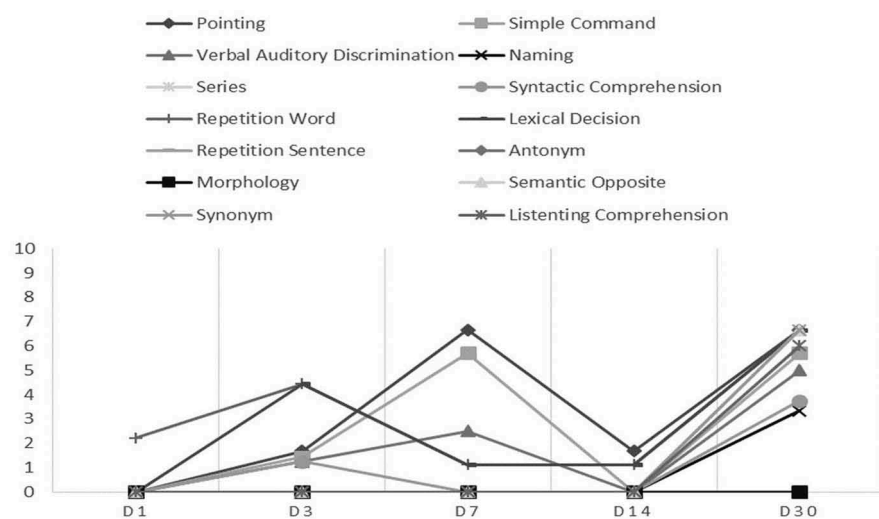


Figure 3. (Continued).

performance, longitudinal trend in language function, and baseline imaging are demonstrated in Figure 4.

Discussion

Based on our preliminary findings, some aspects of language function in bilingual aphasic patients appear to be associated with the presentation of coprolalia. Meanwhile, whether coprolalia spontaneously ameliorates through the course of recovery from bilingual aphasia needs to be further investigated. The clinical appraisal of linguistic performance in aphasic patients using the Persian version of BAT has been pursued since the 1980s (Nilipour, Rezai, Meysami, & Abasiyan Bidgoli, 2012). The newer versions of the assessment tool in Azari and Kurdish became recently available and research in this field has gained more attention. Although many sample populations of Iranian patients have been examined for aphasia, with the related reports published since then, the current literature on bilingual aphasia in stroke appears to be relatively scarce (Nilipour et al., 2012). As such, a multicenter effort under the "BLAS₂T" project-identity has been developed to register, organize, analyze, and materialize clinical data on bilingual aphasia in stroke as the joint-initiative of 14 national and international centers since 2014.

The issue of coprolalia in stroke patients has received a relatively less attention in the research literature. Within our 2014–2015 dataset, we encountered four cases with such a clinical presentation who had occipital, frontotemporal/temporoparietal, temporal, and thalamic stroke demonstrating coprolalia. They were reacting to medical staff's (and to lesser extent relatives') solicitation by using curse words. However, such behavior was only evident when subjects were stimulated by the external stimuli. While in some instances brief restraint and use of major tranquilizers was mandated, in three out of four cases, coprolalia resolved by day-14 or -30 post-stroke follow-up. Given their selective behavior toward some medical staff and relatives, such presentation may be well differentiated from agitated delirium which is the case in extensive lesions in different posterior cerebral artery territories (Page, 2009; Vatsavayi, Malhotra, & Franco, 2003).

The relatively low frequency of aggressive behavior with coprolalia in our report may partly be due to inclusion of patients with involuntary swearing and exclusion of patients who demonstrated confusion or agitated delirium. However, given our small series of bilingual stroke victims with coprolalia, no particular region of interest could be pinpointed to predict patients' language obscenity. Nevertheless, temporal and occipital areas were affected in three of our cases. The involvement of temporal, occipital, and thalamic region in our small series with coprolalia following stroke may possibly suggest the posterior cerebral artery territory lesions as a common culprit (Chan, Campayo et al. 2006). The existing evidence also suggest the central role of the limbic system (namely amygdala) in cognitively regulating emotions to prevent violent outbursts (Isenberg et al., 1999; Oftadehal, Mahmoodi Kahriz, & Torabinami, 2012). Neuroimaging studies (using positron emission tomography scans) on how swearing reverberates within the complex cognitive processing systems in our brain corroborated the activation of amygdala when

exposed to curse words (Isenberg et al., 1999). The involvement of amygdala both in swearing and expression of the emotional valence such as happiness, sadness, stress, fear, disgust, and surprise may partly explain why curse words are used in emotional and not necessarily negative outbursts (Isenberg et al., 1999). At least in three of our cases, the amygdala as well as occipito-limbic connections were potentially involved. Moreover, the involvement of more extensive areas including the serotonergic system may further explain how different anatomical lesions generate comparable behavioral symptoms (Olivier & Van Oorschot, 2005). As demonstrated in Figures 1–4, L1 and L2 in such cases may disproportionately recover. Different patterns of recovery in bilingual aphasia (Paradis, 2000) are summarized in Table 1.

In our patients, the pattern of recovery in L1 and L2 was more compatible with parallel (Case 1), differential (Cases 2 and 3), and mixed (Case 4). The issue whether age of L2 acquisition influences the cortical areas once the language is being recovered is open to debate (Mehrpour, Motamed, Aghaei, Jalali, & Ghoreishi, 2014).

According to Pearce et al., the syntactic and grammatical features of L2 may vary from those of L1, especially if L2 is acquired after the age of 7 (Pearce, 2005). Based on the Krapf's hypothesis, last-learned languages in aphasia tend to recover even earlier than the mother tongue. This however does not seem to hold necessarily true in many instances (Mehrpour et al., 2014). The above was debated by Pearce et al. substantiating that the language most used just before the onset of aphasia is the one to recover earlier (Pearce, 2005). More recent justifications by Paradis suggest that recovery of either of languages in aphasic patient may at least partly depend on: (1) relevance of the language to the situation, (2) extent of the lesion, and (3) different reading knowledge for L1 and L2 (Paradis, 2011). Moreover, L1 or L2 recovery is shown to be facilitated in the absence of procedural memory impairments (Fabbro, 2001; Zanini et al., 2004).

Recent studies suggest that the control mechanisms are greatly affected in selective rather than parallel recovery pattern in bilingual aphasia. The functional connectivity in language and cognitive control areas in the brain tends to

Table 1. Recovery patterns of aphasia in polyglot patients.

Type of recovery in bilingual aphasia	Characteristics
Parallel	L1 and L2 are impaired and reinstated at an identical rate
Differential	L1 and L2 tend to differentially recuperate based on their premorbid functions
Selective	A common presentation in which one language fails to recover. In practice, almost one-third of bilingual aphasia cases with stroke demonstrate a selective recovery pattern and fail to regain one or more of their languages
Blended	During the course of recovery, patients often mix L1 and L2 inappropriately
Antagonistic	In this uncommon pattern, initially, one language starts to regain to some levels first and then regresses while the other one begins to recover
Successive	One language starts to recover only after the other one is regained. While the rate of recovery varies, both languages may eventually recover
Mixed patterns	A less common pattern involving mutual interference between the languages upon recovery


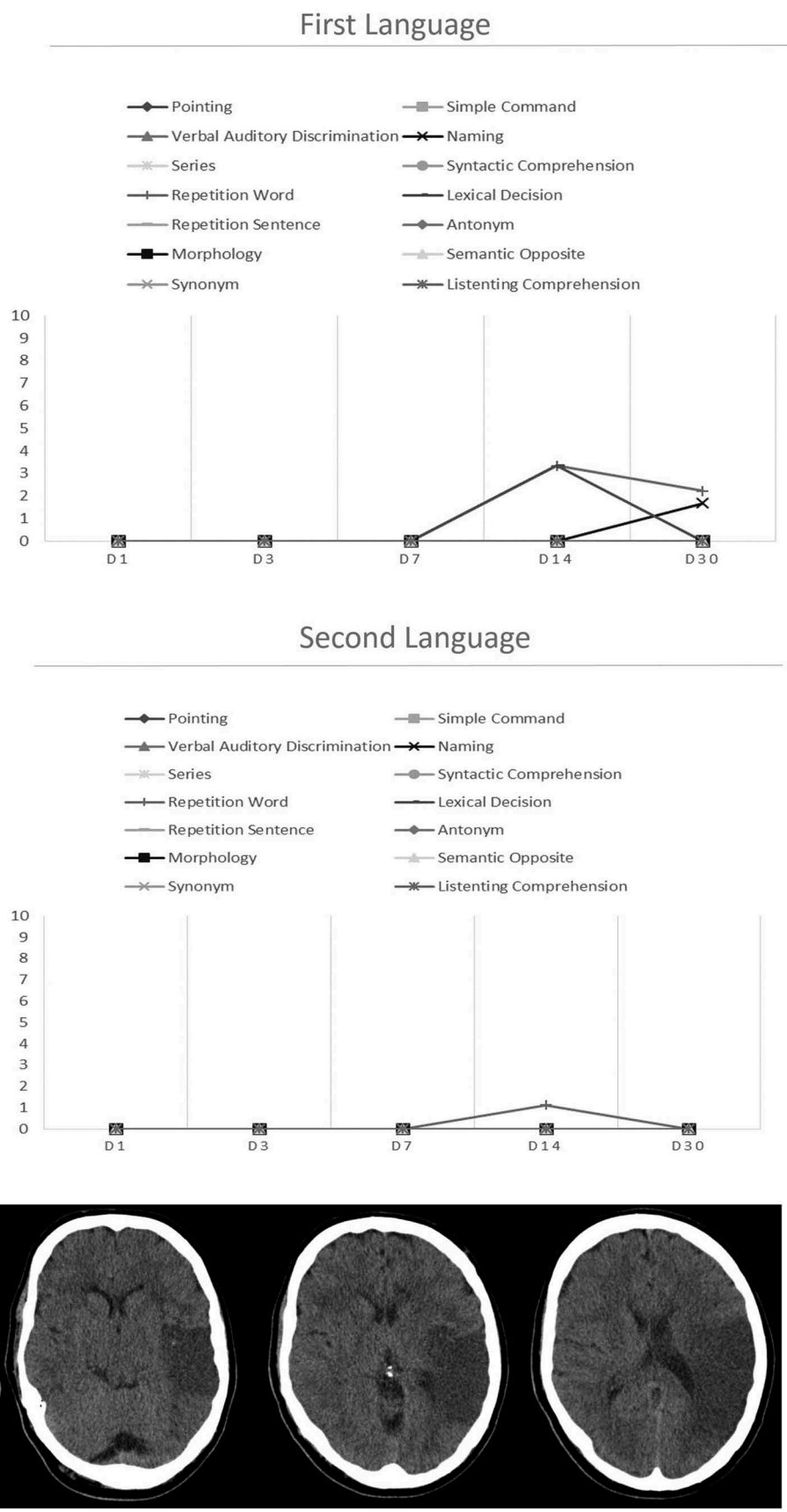


Figure 4. (a) MG's Azari (L1) and Farsi (L2) profiles on the BAT. (A) Language tasks including (from left to right) pointing, simple command, verbal auditory discrimination, naming, series, syntactic comprehension, perception word, lexical decision, perception sentence, antonym, morphology, semantic opposite, synonym, and listening comprehension were administered and scored according to the BAT manual for L1 (Azari) and L2 (Farsi) from the scale of 0 to 10. (b) The longitudinal trend for linguistic performance in L1 and L2 based on each task. (B) The patient's overall BAT score remained profoundly poor up to day-14 follow-up after which he showed minimal improvement in L1. The patient's coprolalia continued up to around day 30 and started to resolve thereafter. (C) MG's baseline brain CT scan indicating left temporal ischemic stroke (no hemorrhage). BAT: Bilingual Aphasia Test; L1: first language; L2: second language.



reestablish when language recovery is in process following stroke (Nair et al., 2015). This may partly explain why stroke patients with differential or selective language recovery pattern often lose behavioral control mechanism.

Our four reported cases were bilingual aphasic subjects who were incidentally found to present with coprolalia. The focus of the present report was the simultaneous presentation of coprolalia and bilingual aphasia. While L1 and L2 were similarly affected, coprolalia could resolve in three of the reported cases, suggesting that the condition may spontaneously ameliorate once language function starts to regain.

The intersubject variations have been regarded as a limitation to the present report. Prospective studies which stratify a relatively larger number of cases based of their radiological and BAT findings would be required to enhance our current state of knowledge on the correlations between coprolalia and bilingual aphasia.

Conclusion

Insights into the recognition of coprolalia and language recovery patterns in stroke-induced bilingual aphasia may possibly lead to more efficient approaches toward individualized care and neurolinguistic or cognitive rehabilitation programs.

Disclosure statement

No potential conflict of interest was reported by the authors.

References

- Ashjazadeh, N., Boostani, R., Ekhtiari, H., Emamghoreishi, M., Farrokhi, M., Ghanizadeh, A., ... Vesal, A. (2014). Operationalizing cognitive science and technologies' research and development; the "Brain and Cognition Study Group (BCSG)" initiative from Shiraz, Iran. *Basic Clinical Neuroscience*, 5, 104–116.
- Botez, S. A., Carrera, E., Maeder, P., & Bogousslavsky, J. (2007). Aggressive behavior and posterior cerebral artery stroke. *Archives of Neurology*, 64, 1029–1033. doi:10.1001/archneur.64.7.1029
- Bowers, J. S., & Pleydell-Pearce, C. W. (2011). Swearing, euphemisms, and linguistic relativity. *PLoS One*, 6, e22341. doi:10.1371/journal.pone.0022341
- Chan, K. L., Campayo, A., Moser, D. J., Arndt, S., & Robinson, R. G. (2006). Aggressive behavior in patients with stroke: Association with psychopathology and results of antidepressant treatment on aggression. *Archives of Physical Medicine and Rehabilitation*, 87, 793–798. doi:10.1016/j.apmr.2006.02.016
- Daniel, C., & Perry, M. S. (2016). Ictal coprolalia: A case report and review of ictal speech as a localizing feature in epilepsy. *Pediatric Neurology*, 57, 88–90. doi:10.1016/j.pediatrneurol.2015.11.013
- Eddy, C. M., & Cavanna, A. E. (2013). 'It's a curse!': Coprolalia in Tourette syndrome. *European Journal of Neurology: The Official Journal of the European Federation of Neurological Societies*, 20, 1467–1470.
- El Hachoui, H., Visch-Brink, E. G., De Lau, L. M., Van De Sandt-Koenderman, M. W., Nouwens, F., Koudstaal, P. J., & Dippel, D. W. (2016). Screening tests for aphasia in patients with stroke: A systematic review. *Journal of Neurology*.
- Fabbro, F. (2001). The bilingual brain: Cerebral representation of languages. *Brain and Language*, 79, 211–222. doi:10.1006/brln.2001.2481
- Ganos, C., Edwards, M. J., & Muller-Vahl, K. (2016). "I swear it is Tourette's!": On functional coprolalia and other tic-like vocalizations. *Psychiatry Research*, 246, 821–826. doi:10.1016/j.psychres.2016.10.021
- Gialanella, B., Prometti, P., Vanoglio, F., Comini, L., & Santoro, R. (2016). Aphasia and activities of daily living in stroke patients. *European Journal of Physical and Rehabilitation Medicine*.
- Isaacs, D. (2014). Swearing. *Journal of Paediatrics and Child Health*, 50, 1–2. doi:10.1111/jpc.12478
- Isenberg, N., Silbersweig, D., Engelen, A., Emmerich, S., Malavade, K., Beattie, B., ... Stern, E. (1999). Linguistic threat activates the human amygdala. *Proceedings of the National Academy of Sciences of the United States of America*, 96, 10456–10459. doi:10.1073/pnas.96.18.10456
- Khachatryan, E., Vanhoof, G., Beyens, H., Goeleven, A., Thijs, V., & Van Hulle, M. M. (2016). Language processing in bilingual aphasia: A new insight into the problem. *Wiley Interdisciplinary Reviews. Cognitive Science*, 7, 180–196. doi:10.1002/wcs.1384
- Kobierska, M., Sitek, M., Gocyla, K., & Janik, P. (2014). Coprolalia and copropraxia in patients with Gilles de la Tourette syndrome. *Neurologia i Neurochirurgia Polska*, 48, 1–7.
- Maia, D. P., & Cardoso, F. (2001). Complex phonic tic and disinhibition in Tourette syndrome: Case report. *Arquivos De Neuro-Psiquiatria*, 59, 587–589. doi:10.1590/S0004-282X2001000400019
- Massot-Tarrus, A., Mousavi, S. R., Dove, C., Hayman-Abello, S. S., Hayman-Abello, B., Derry, P. A., ... Mirsattari, S. M. (2016). Coprolalia as a manifestation of epileptic seizures. *Epilepsy & Behavior: E&B*, 60, 99–106. doi:10.1016/j.yebeh.2016.04.040
- Mehrpour, M., Motamed, M. R., Aghaei, M., Jalali, N., & Ghoreishi, Z. (2014). Unusual recovery of aphasia in a polyglot Iranian patient after ischemic stroke. *Basic Clinical Neuroscience*, 5, 173–175.
- Muller-Vahl, K. R. (2012). Monolingual coprolalia in bilingual patients with Tourette syndrome. *Movement Disorders: Official Journal of the Movement Disorder Society*, 27, 1468. doi:10.1002/mds.25166
- Nair, V. A., Young, B. M., La, C., Reiter, P., Nadkarni, T. N., Song, J., ... Prabhakaran, V. (2015). Functional connectivity changes in the language network during stroke recovery. *Annals of Clinical and Translational Neurology*, 2, 185–195. doi:10.1002/acn3.165
- Nilipour, R. (2002). Emerging issues in speech therapy in Iran. *Folia Phoniatrica Et Logopaedica: Official Organ of the International Association of Logopedics and Phoniatrics (IALP)*, 54, 65–68. doi:10.1159/000057916
- Nilipour, R., Rezai, H., Meysami, N., & Abasiyan Bidgoli, S. (2012). Neuropsychological double dissociation between linguistic levels: Clinical linguistic evidence from Iranian aphasic patients. *Basic and Clinical Neuroscience*, 3, 5–15.
- Nuwer, M. R. (1982). Coprolalia as an organic symptom. *Advances in Neurology*, 35, 363–368.
- Oftadehal, M., Mahmoodi Kahriz, B., & Torrabani, M. (2012). Cognitive emotion regulation, depression and stress in Iranian students. *Neuroscience Research Letters*, 3, 39–42.
- Olivier, B., & Van Oorschot, R. (2005). 5-HT1B receptors and aggression: A review. *European Journal of Pharmacology*, 526, 207–217. doi:10.1016/j.ejphar.2005.09.066
- Page, V. J. (2009). Tackling agitated delirium—the tip of the iceberg. *Critical Care (London, England)*, 13, 158. doi:10.1186/cc7912
- Paradis, M. (2000). Generalizable outcomes of bilingual aphasia research. *Folia Phoniatrica Et Logopaedica: Official Organ of the International Association of Logopedics and Phoniatrics (IALP)*, 52, 54–64. doi:10.1159/000021513
- Paradis, M. (2011). Principles underlying the Bilingual Aphasia Test (BAT) and its uses. *Clinical Linguistics & Phonetics*, 25, 427–443. doi:10.3109/02699206.2011.560326
- Pearce, J. M. (2005). A note on aphasia in bilingual patients: Pitres' and Ribot's laws. *European Neurology*, 54, 127–131. doi:10.1159/000089083
- Purdy, S. C., Wanigasekara, I., Canete, O. M., Moore, C., & McCann, C. M. (2016). Aphasia and auditory processing after stroke through an international classification of functioning, disability and health lens. *Seminars in Hearing*, 37, 233–246. doi:10.1055/s-0036-1584408
- Sekhon, J. K., Douglas, J., & Rose, M. L. (2015). Current Australian speech-language pathology practice in addressing psychological well-being in people with aphasia after stroke. *International Journal of Speech-Language Pathology*, 17, 252–262. doi:10.3109/17549507.2015.1024170
- Sinanovic, O., Mrkonjic, Z., Zukic, S., Vidovic, M., & Imamovic, K. (2011). Post-stroke language disorders. *Acta Clinica Croatica*, 50, 79–94.
- Stern, E., Silbersweig, D. A., Chee, K. Y., Holmes, A., Robertson, M. M., Trimble, M., ... Dolan, R. J. (2000). A functional neuroanatomy of tics

- in Tourette syndrome. *Archives of General Psychiatry*, 57, 741–748. doi:10.1001/archpsyc.57.8.741
- Thiel, A., & Zumbansen, A. (2016). The pathophysiology of post-stroke aphasia: A network approach. *Restorative Neurology and Neuroscience*, 34, 507–518.
- Toscano, M., Vigano, A., Puledra, F., Verzina, A., Rocco, A., Lenzi, G. L., & Di Piero, V. (2014). Serotonergic correlation with anger and aggressive behavior in acute stroke patients: An intensity dependence of auditory evoked potentials (IDAP) study. *European Neurology*, 72, 186–192. doi:10.1159/000362268
- Tschirren, M., Laganaro, M., Michel, P., Martory, M. D., Di Pietro, M., Abutalebi, J., & Annoni, J. M. (2011). Language and syntactic impairment following stroke in late bilingual aphasics. *Brain and Language*, 119, 238–242. doi:10.1016/j.bandl.2011.05.008
- Vatsavayi, V., Malhotra, S., & Franco, K. (2003). Agitated delirium with posterior cerebral artery infarction. *The Journal of Emergency Medicine*, 24, 263–266. doi:10.1016/S0736-4679(02)00750-3
- Wright, H. H., Downey, R. A., Gravier, M., Love, T., & Shapiro, L. P. (2007). Processing distinct linguistic information types in working memory in aphasia. *Aphasiology*, 21, 802–813. doi:10.1080/02687030701192414
- Zanini, S., Tavano, A., Vorano, L., Schiavo, F., Gigli, G. L., Aglioti, S. M., & Fabbro, F. (2004). Greater syntactic impairments in native language in bilingual Parkinsonian patients. *Journal of Neurology, Neurosurgery, and Psychiatry*, 75, 1678–1681. doi:10.1136/jnnp.2003.018507

APPENDIX

Collaborators and consultants at the BLAS₂T multi center initiative (alphabetically):

- Abotalebi, Jubin (Faculty of Psychology, University Vita-Salute San Raffaele, Milano, Italy)
- Daneshi, Sayyed Abdolhadi (Department of Neurosurgery, Iran University of Medical Sciences, Tehran, Iran)
- Farhoudi, Mehdi (Neuroscience Research Center, Tabriz University of Medical Sciences, Tabriz, Iran)
- Fridriksson, Julius (C-STAR program, University of Southern Carolina, Colombia, SC, USA)
- Habibi, Amir Hasan (Department of Neurology, Iran University of Medical Sciences, Tehran, Iran)
- Kiran, Swathi (Department of Speech, Language and Hearing Sciences, Boston University, TX, USA)
- Majerus, Steve (Department of Psychology, University of Leige, Belgium)
- Mirzaaskari, Zahra (Department of Neurology, Iran University of Medical Sciences, Tehran, Iran)
- Sefidkar, Arash (Department of Neurology, Guilan University of Medical Sciences, Guilan, Iran)