

# Successful retinal blood flow augmentation after extracranial-intracranial bypass

Tackeun Kim<sup>1</sup> · Min Jai Cho<sup>1</sup> · Sang Jun Park<sup>2</sup> · Moon-Ku Han<sup>3</sup> ·  
Davendra Hari Ojar<sup>4</sup> · Chang Wan Oh<sup>1</sup> · Jae Seung Bang<sup>1</sup>

Received: 2 September 2017 / Accepted: 9 October 2017  
© Springer-Verlag GmbH Austria 2017

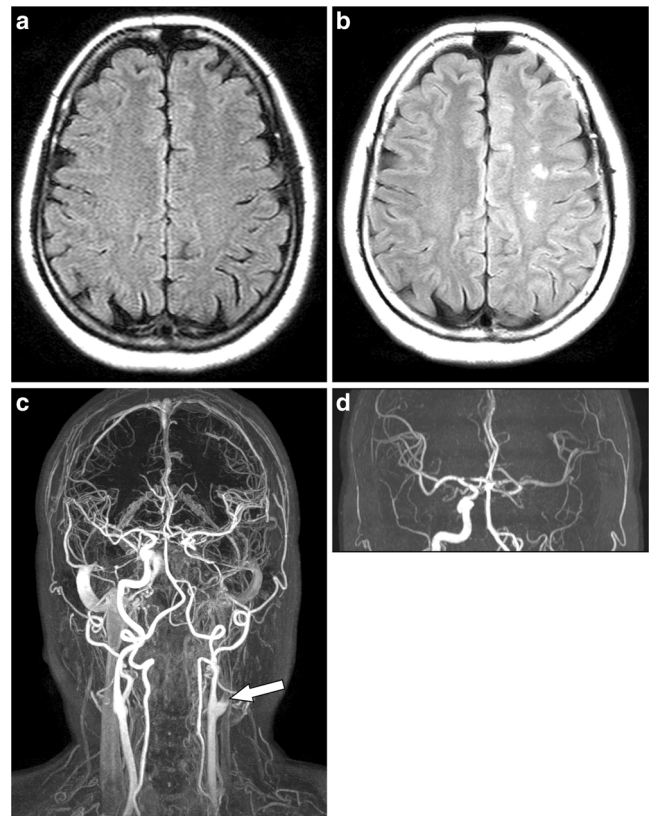
**Abstract** A 61-year-old woman visited us with recent onset right-side weakness. Magnetic resonance imaging showed ischemic changes at the left internal border zone due to occlusive disease affecting the left proximal internal carotid artery. Prompt oral dual antiplatelet therapy and intravenous fluid were administered with subsequent induced hypertension and without reperfusion therapy. Although the hemiparesis was improved, she complained of a new-onset transient left-side monocular visual loss. Fluorescein angiography confirmed delayed perfusion in the left eye. We performed extracranial-intracranial bypass for flow augmentation. After bypass, the amaurosis fugax resolved. Follow-up retinal fluorescein angiography also showed improved retinal perfusion.

**Keywords** Cerebral revascularization · Fluorescence angiography · Transient monocular blindness · Ischemia

## Introduction

The extracranial-intracranial (EC-IC) bypass surgery was introduced by Yasargil in 1967 [10]. Since then, it was widely

applied to treat steno-occlusive lesions involving intracranial or extracranial internal carotid arteries (ICA). However, several randomized controlled studies demonstrated that cerebral revascularization provided no benefits over medical treatment



**Fig. 1** **a** Premorbid MR T2 FLAIR image shows no ischemic changes. **b** Left-sided internal border-zone infarction is seen in the T2 FLAIR image of current hospital admission. **c** The white arrow indicates the proximal occlusion of left internal carotid artery. MR angiography shows cross-filling of the left hemisphere via the anterior and posterior communicating arteries

✉ Jae Seung Bang  
bang78425@hanmail.net

<sup>1</sup> Department of Neurosurgery, Seoul National University Bundang Hospital, 82, Gumi-ro 173 Beon-gil, Bundang-gu, Seongnam-si, Gyeonggi-do 13620, Republic of Korea

<sup>2</sup> Department of Ophthalmology, Seoul National University Bundang Hospital, Seongnam-si, Republic of Korea

<sup>3</sup> Department of Neurology, Seoul National University Bundang Hospital, Seongnam-si, Republic of Korea

<sup>4</sup> Department of Radiology, Eric Williams Medical Science Complex, Uriah Butler Highway, Champ Fleurs, Trinidad and Tobago

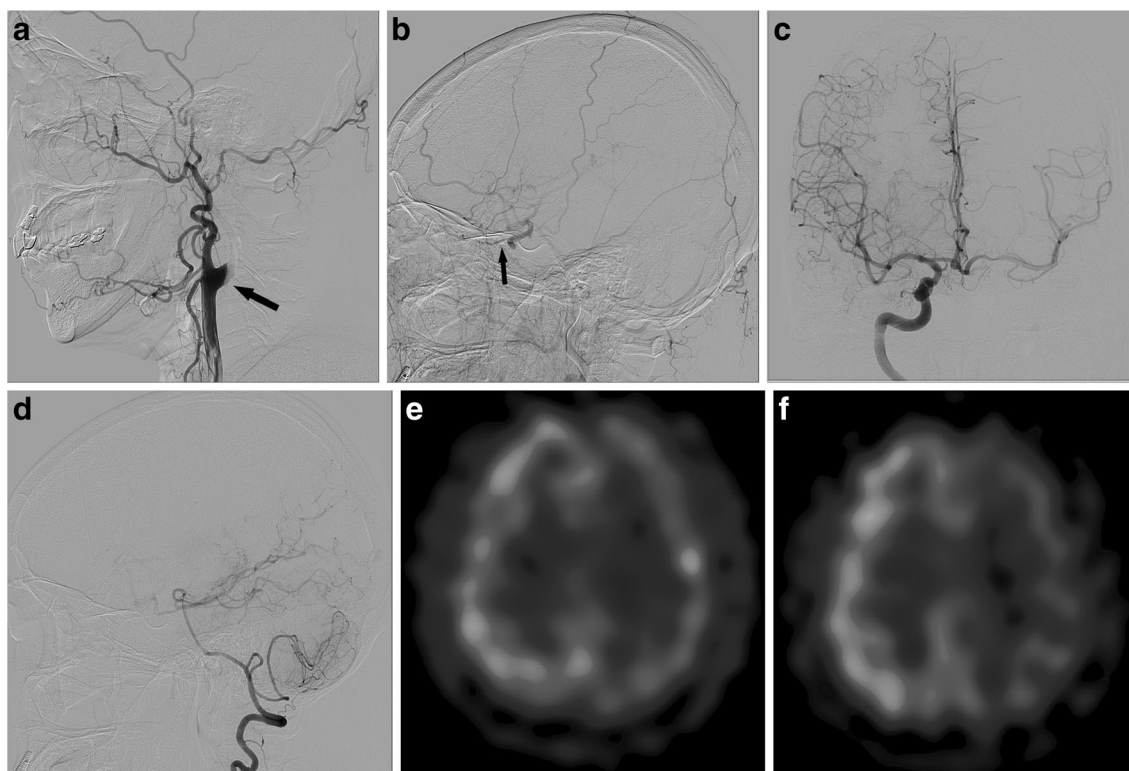
in terms of reducing the subsequent risk of stroke [3, 9]. As per results, EC-IC bypass for intracranial or extracranial stenocclusive disease is currently restricted to specific conditions, such as moyamoya disease [5]. Nevertheless, EC-IC bypass is still an effective option for ICA stenosis or occlusion causing repetitive ischemic symptoms in spite of best medical treatment. In this case report, we demonstrate the effectiveness of EC-IC bypass for treating amaurosis fugax caused by retinal hypoperfusion due to ICA occlusion, which could be confirmed by fluorescein angiography (FAG).

## Case report

A 61-year-old woman visited the emergency department with a new-onset right-side hemiparesis from 7 h earlier. In the significant medical history, the patient had previous video-assisted thoracoscopic tumorectomy for adenocarcinoma at the right lower lung (T1aN0M0) 5 years ago. The preoperative magnetic resonance image (MRI) of brain showed no abnormal findings (Fig. 1a); no magnetic resonance (MR) angiography was performed at that time. During this hospital admission, follow-up **d**MRI showed subacute ischemic infarction at the left internal border zone (Fig. 1b) and complete loss of

signal within the left ICA, just above the common carotid artery bifurcation (Fig. 1c). The left anterior and middle cerebral arteries were supplied from right ICA via the anterior communicating artery (Fig. 1d).

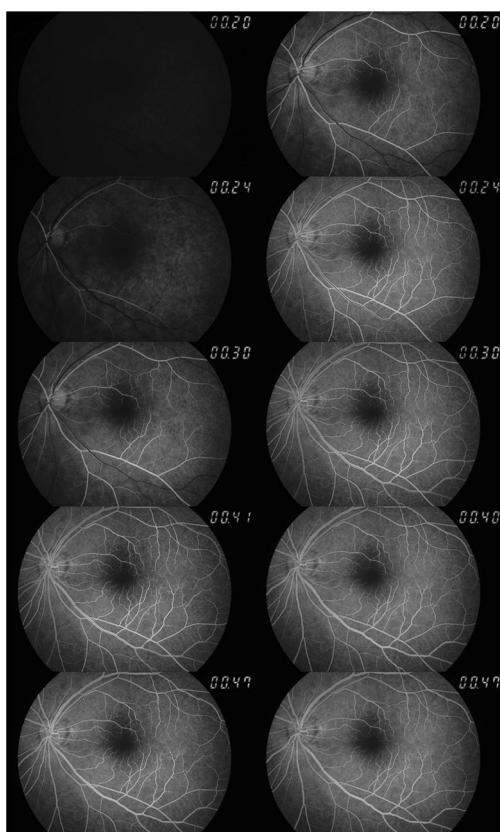
Due to the delayed patient arrival, intravenous thrombolysis could not be performed. Instead, dual antiplatelet therapy (oral aspirin and clopidogrel) and adequate intravenous fluid replacement were given with a concomitant induced elevated blood pressure using phenylephrine. Following admission to the stroke unit, the right-side weakness gradually improved to nearly normal power over the next 24 h. However, the patient then complained of a new-onset and intermittent left-side monocular visual loss (amaurosis fugax). Cerebral digital subtraction angiography (DSA) further confirmed complete occlusion of the left proximal ICA (Fig. 2a). Left external carotid artery selective angiography demonstrated reconstitution of the cavernous ICA via trans-ophthalmic collaterals (Fig. 2b). Cross-filling of contrast media from the right ICA and posterior circulation were also noted (Fig. 2c and d). Single-photon emission computed tomography with acetazolamide showed left-side basal hypoperfusion with decreased vascular reserve (Fig. 2e and f). FAG evaluation of the retinal perfusion performed by an ophthalmologist showed delayed perfusion in the left eye (Fig. 3).



**Fig. 2** **a** Digital subtraction angiography shows abrupt complete occlusion of the left proximal internal carotid artery (*black arrow*). **b** Angiographic reconstitution of the ophthalmic artery via the posterior ethmoidal arteries from the external carotid artery system (*black arrow*). **c, d** The left hemisphere is supplied from the anterior and posterior

communicating arteries. **e**. Single photon emission computed tomography (SPECT) shows left-side basal hypoperfusion. **f** SPECT with acetazolamide challenge shows decreased vascular reserve in the left hemisphere

A review of the border-zone infarction of the left corona radiata and clinical amaurosis fugax due to simultaneous retinal hypoperfusion led us to perform extracranial-intracranial bypass surgery and to thus relieve the cerebral and retinal hypoperfusion. Because there was major collateral support from both the anterior and posterior communicating arteries, single superficial temporal artery (STA) to cortical middle cerebral artery bypass (MCA) was planned. A question-mark incision was made from the anterior tragus to frontal side. From the scalp flap, the parietal branch of the STA was harvested with 8 cm length from STA bifurcation. It was anastomosed with the angular branch of the left MCA (Fig. 4a) via rectangular craniotomy (Fig. 4b) around Chater's point [2]. Intraoperative flow measurement using ultrasonic flow meter (HT310; Transonic Systems, Ithaca, NY, USA) showed intact bypass flow with a rate of 70 ml/min. After brief recovery in the intensive care unit, the patient was transferred to the general ward without any neurologic change nor any postsurgical amaurosis fugax recurrence. Postoperative quantitative MR angiography (NOVA; VasSol, River Forest, IL, USA) showed increased bypass flow (85 ml/min, Fig. 4c) through the STA (Fig. 4d). Follow-up retinal FAG also showed improved



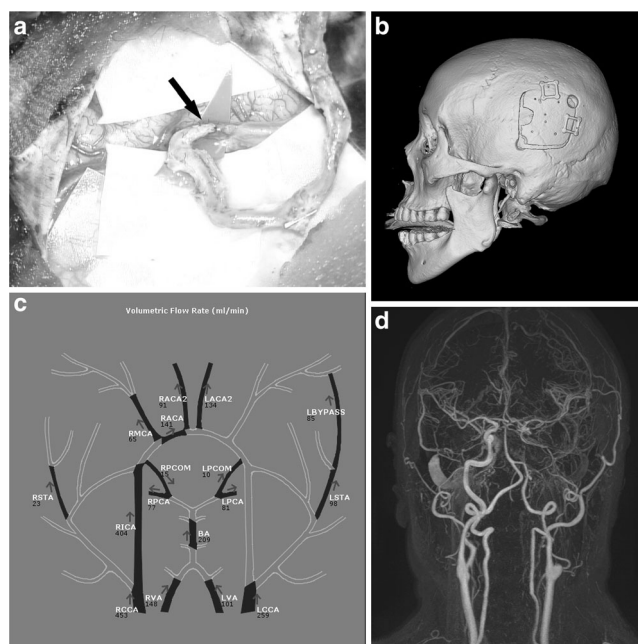
**Fig. 3** Serial fluorescein angiography showing preoperative perfusion status of the left retina (*left-side column series*) and correlative postoperative evaluation (*right-side column series*). Comparison of the two columns confirmed significant improvement of overall retinal perfusion

retinal perfusion compared with preoperative examination (Fig. 3). The patient was discharged with fine motor dysfunction on the left hand (modified Rankin Scale 1).

## Discussion

Randomized-controlled trials have claimed that cerebral revascularization using STA-MCA anastomosis provided no benefits over medical treatment in terms of reducing the subsequent risk of stroke [8, 9]. A critical observation made of these studies, however, was the enrollment of their patients based solely on clinical symptoms and angiographic findings [9] and without hemodynamic status data. Nevertheless, other trials based on hemodynamic impairment also failed to prove the superiority of bypass surgery over medical treatment [3]. Following these results, the indication of EC-IC bypass was narrowed to specific conditions, such as refractory or crescendo transient ischemic attack (TIA) in spite of best medical care.

In this report, the patient suffered from newly developed amaurosis fugax in spite of current best medical practice. When EC-IC collaterals around orbit are not well-developed, the resultant hypoperfusion and decreased reservoir capacity can cause retinal ischemia as well as cerebral ischemia. Unlike cerebral vasculature, the retinal vessels can uniquely be observed via a lens. Retinal perfusion can be measured by



**Fig. 4** **a** The superficial temporal artery is anastomosed with the cortical branch of the middle cerebral artery. **b** Three-dimensional reconstruction image shows the craniotomy site. **c** Quantitative MR angiography shows abundant volume flow of bypass pedicle. **d** Anastomotic point is clearly visualized by MR angiography

calculating both the filling and washout delay using retinal FAG [1, 7]. Some literatures reported about improvement of retinal perfusion after EC-IC bypass [4, 6]. In comparison with prior literature studies, the current report has now demonstrated the usefulness of fluorescein angiography as a feasible evaluating tool for retinal hypoperfusion. This simple diagnostic test can also provide crucial information about retinal perfusion restoration after revascularization surgery as well as perfusion status of retina in setting of ICA occlusive disease.

**Compliance with ethical standards** This study was approved by institutional review board (B-1708/412–701). The consent from the patient was waived because postoperative follow-up had already finished.

**Conflict of interest** None.

## References

1. Arnold AC, Hepler RS (1994) Fluorescein angiography in acute nonarteritic anterior ischemic optic neuropathy. *Am J Ophthalmol* 117:222–230
2. Chater N, Spetzler R, Tonnemacher K, Wilson CB (1976) Microvascular bypass surgery. Part 1: anatomical studies. *J Neurosurg* 44:712–714
3. Grubb RL Jr, Powers WJ, Derdeyn CP, Adams HP Jr, Clarke WR (2003) The carotid occlusion surgery study. *Neurosurg Focus* 14:e9
4. Kawaguchi S, Sakaki T, Morimoto T, Okuno S, Nishikawa N (1999) Effects of bypass on ocular ischaemic syndrome caused by reversed flow in the ophthalmic artery. *Lancet* 354:2052–2053
5. Kim T, CW O, Kwon OK, Hwang G, Kim JE, Kang HS, Cho WS, Bang JS (2016) Stroke prevention by direct revascularization for patients with adult-onset moyamoya disease presenting with ischemia. *J Neurosurg* 124:1788–1793
6. Omodaka S, Endo H, Doi H, Shimizu H, Fujimura M, Aizawa N, Nakazawa T, Tominaga T (2014) Usefulness of laser speckle flowgraphy for the assessment of ocular blood flow in extracranial-intracranial bypass. *J Stroke Cerebrovasc Dis* 23:e445–e448
7. Terelak-Borys B, Skonieczna K, Grabska-Liberek I (2012) Ocular ischemic syndrome—a systematic review. *Med Sci Monit* 18:RA138–RA144
8. The EC/IC Bypass Study Group (1985) Failure of extracranial-intracranial arterial bypass to reduce the risk of ischemic stroke. Results of an international randomized trial. *N Engl J Med* 313:1191–1200
9. The EC/IC Bypass Study Group (1985) The international cooperative study of extracranial/intracranial arterial anastomosis (EC/IC bypass study): methodology and entry characteristics. *The EC/IC bypass study group. Stroke* 16:397–406
10. Yasargil MG (1969) *Microsurgery applied to neurosurgery*. George Thieme, Stuttgart