

Takayasu Arteritis: A Treatable Cause of Stroke in Infancy

Michael H. Kohrman, MD and Peter R. Huttenlocher, MD

Takayasu disease is an arteritis of unknown etiology involving the aorta and its major branches. Untreated, 75% of patients die within two years. A 6-month-old black female presented with a right focal seizure, a flaccid right hemiparesis, decreased pulses in the right arm, a large left frontoparietal hypodense area on computed tomography, and an elevated erythrocyte sedimentation rate. Cerebral angiography demonstrated irregular dilatation of both carotid arteries and narrowing of the left middle cerebral artery. Aneurysm of the right sinus of Valsalva, dilatation of the aortic root, narrowing of the origins of both carotid arteries, and beading of the descending aorta were demonstrated by cardiac angiography. The patient was treated with prednisone (2 mg/kg/day) and azathioprine (1 mg/kg/day). There was gradual return of the erythrocyte sedimentation rate to normal over the ensuing 3-10 months, resolution of the hemiparesis, and acquisition of normal developmental milestones. Digital subtraction angiography revealed improvement in the appearance of the descending aorta and of the common carotid arteries with the disappearance of the arterial wall irregularities. Early diagnosis and vigorous immunosuppression may improve outcome in this rare and often fatal vascular disease in childhood.

Kohrman MH, Huttenlocher PR. Takayasu arteritis: A treatable cause of stroke in infancy. *Pediatr Neurol* 1986;2:154-8.

Introduction

Takayasu or nonspecific aortitis, first described by Savory in 1856 [1], and Kussmaul in 1872 [2], affects the aorta and its larger branches. Cerebrovascular involvement is uncommon with stroke, reported only in 5-10% of patients [3-5]. The pulmonary arteries also may be involved [6]. The disease has been known by many terms including pulseless disease, young female arteritis, idiopathic aortitis, reverse coarctation syndrome, and Martorell syndrome. Takayasu in 1908 described the ocular manifestations as consisting of wreath-like anastomosis surrounding the optic disk [7]. The most common signs are hypertension, absent pulses, and vascular bruits [3]. Although it occurs world-wide, the disease is most commonly found in

India, Japan, China, and Southeast Asia [8]. The age of onset in most patients is between 15-20 years [4]. There is a female to male predominance of 9 to 1 [4]. Rarely have patients under 2 years of age been reported [9-11]. Two of these patients had rapidly fatal courses. Immunosuppression with steroids has greatly improved patient outcome in adults. Prior to the use of steroids, 75% of adult patients died in the first 2 years after diagnosis [12]. We present a 14-month-old black female infant who had a stroke at age 5 months and who improved after immunosuppressive therapy.

Case Report

This black female child was well until the age of 5 months when she experienced 3 days of fever, diarrhea, vomiting, and irritability. Her appetite decreased, and she was reported to have had neck stiffness and inability to support her head. On the day of admission she had a focal motor seizure with transient apnea, followed by paresis of the right arm and leg. During the next 24 hours she had several further brief convulsions and worsening of the hemiparesis. She remained alert interictally. She was born at term, by normal spontaneous vaginal delivery, of an 18-year-old primiparous mother. Birth weight was 2,900 grams. There had been no difficulty with the pregnancy or neonatal period. The family history was unremarkable.

Her head circumference was 40.2 cm (2nd percentile), weight 6.1 kg (10th percentile), length 63 cm (50th percentile), temperature 37.9°C, pulse 118, respirations 18, and blood pressure 119/89 mm Hg. Her pupils were 3 mm and reactive; the optic fundi were unremarkable. Extraocular movements were intact. Facial movements were symmetric. Gag reflex was present and the tongue was in the midline. She had a flaccid right hemiparesis. Her deep tendon reflexes were hyperactive accompanied by a few beats of right ankle clonus. Her plantar response was flexor bilaterally. The left axillary pulse was diminished.

The hemoglobin was 8.8 gm/dl, hematocrit 26.8%, white cell count 5,700/mm³ (5% bands, 50% neutrophils, 36% lymphocytes, 19% monocytes). Platelet count was 668,000/mm³. Hemoglobin electrophoretic pattern was normal. Erythrocyte sedimentation rate (ESR) was 75 mm/hr. Serum electrolytes were normal. Glucose was 88 mg/dl. Cerebrospinal fluid (CSF) contained 1 RBC/mm³ and 3 WBC/mm³. The CSF protein was 34 mg/dl and the glucose was 31 mg/dl. Urine amino acids were normal. Rheumatoid factor was 1:40 (normal <80), C-reactive protein was 12.2 mg/dl (normal <0.6 mg/dl) and anti-nuclear antibody was 50. Her total hemolytic complement was 175 U (normal: 182-320 U), C₄ immuno-adherence was 2,000 U (normal: 3,000-5,000 U). Catecholamines and VMA were normal. Plasma renin activity was 10.17 ng/ml/hr (normal: 4.6-13 ng/ml/hr). Her PPD test was negative.

A large left frontoparietal unenhanced hypodense area was demonstrated by computed tomography (CT) (Fig 1). Cerebral angiography revealed marked vascular changes, including ectasia of the left carotid body, peculiar segmental constrictions in the proximal

From the Departments of Pediatrics and Neurology; University of Chicago, Pritzker School of Medicine; Chicago, Illinois. Presented in part at the Fourteenth Annual Child Neurology Society Meeting; Memphis, TN; October, 1985.

Communications should be addressed to:

Dr. Huttenlocher; Department of Pediatrics, Section of Pediatric Neurology; The University of Chicago; Box 228, 5841 South Maryland Avenue; Chicago, IL 60637.

Received February 24, 1986; accepted March 25, 1986.

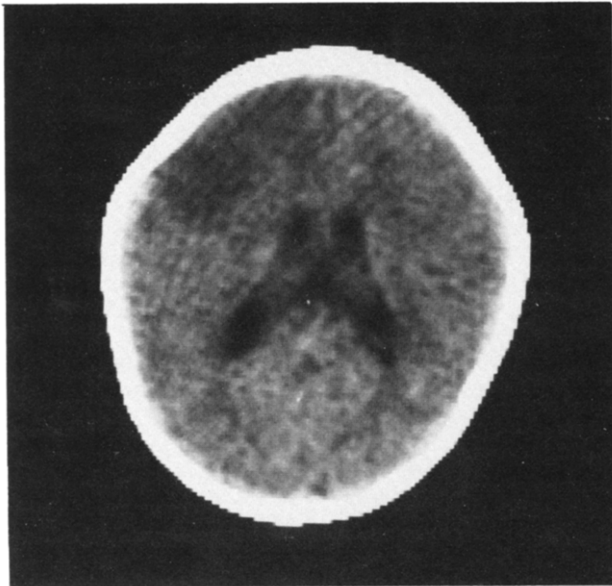


Figure 1. CT scan demonstrates a left frontoparietal hypodensity.

intracranial branches of the left middle cerebral artery, and sudden termination of the proximal anterior cerebral artery and several of its smaller branches (Fig 2). Cardiac ultrasound studies and cardiac catheterization documented an aneurysm of the sinus of Valsalva, dilatation of the aortic root, narrowing of the origins of both carotid arteries, and a beaded appearance of the descending aorta (Fig 3,4). Ultrasound study of the kidneys was noncontributory. Ultrasound study of the aorta revealed a dilated thoraco-abdominal aorta and a questionable narrowing of the celiac axis. Electroencephalogram (EEG) was unremarkable.

She was treated initially with dexamethasone (1 mg/kg/day) (Fig 5) which was replaced by prednisone (2 mg/kg/day). Her ESR fell to 38 mm/hr but then rose gradually to 73 mm/hr. Azathioprine (1 mg/kg/day) was added concurrently with a fall in the ESR to 5 mm/hr over the next 2 months. Digital subtraction venous angiogram performed after 3 months of immunosuppression (Fig 6) demonstrated continued dilatation of the aortic arch, a normal descending aorta, slight dilatation of the common carotid arteries with no abnormality of the arterial walls, and occlusion of the right vertebral artery (not visualized on previous studies). EEG revealed a mild asymmetry of sleep spindles that indicated left hemisphere dysfunction. Ultrasound of the aorta demonstrated a normal aorta and celiac axis. In general, the follow-up angiographic study demonstrated striking improvement compared to the initial findings.

At 14 months of age her head circumference was 43 cm (2nd percentile), weight 7.9 kg (3rd percentile) and height 72 cm (7th percentile). She used several words meaningfully and responded to her name. She cruised around furniture. Her right hand was kept fistled, but she used it to grasp objects and transferred objects from her left to her right hand. She had full extension at the elbow and wrist but slight limitation of supination on the right. She tended to keep the left leg externally rotated when cruising and took steps with minimal assistance. Her reflexes were normal and symmetric but her right Babinski response was extensor. After gradually discontinuing azathioprine, the ESR rose to 37 mm/hr. Currently she is being treated with prednisone (2 mg/kg/day) and azathioprine (1 mg/kg/day).

Discussion

Takayasu arteritis rarely is recognized in infancy [9-11]. Considering the widespread arterial changes of this disease, stroke is remarkably uncommon in all age

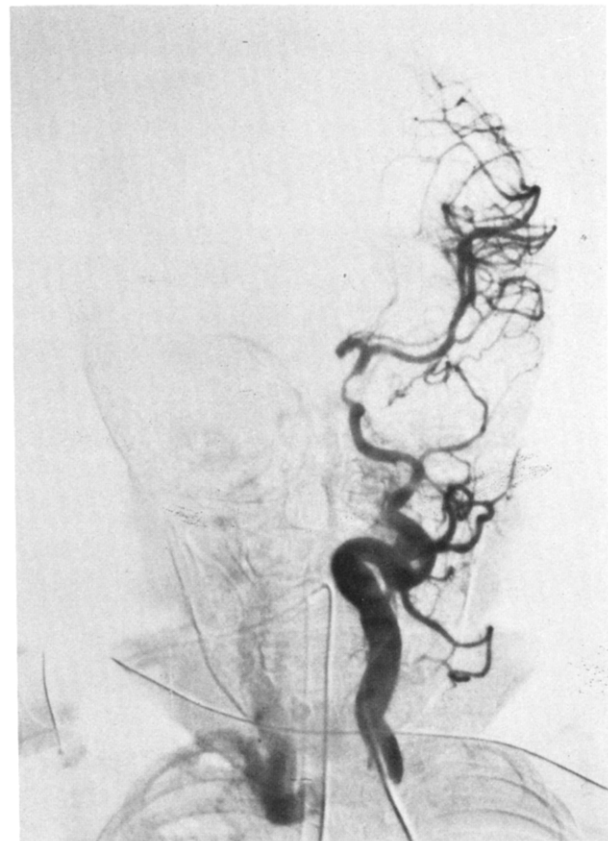


Figure 2. Cerebral angiogram (left carotid injection) demonstrates ectasia at the level of the carotid body, narrowing of the distal internal carotid artery, and lack of filling of the anterior cerebral artery.

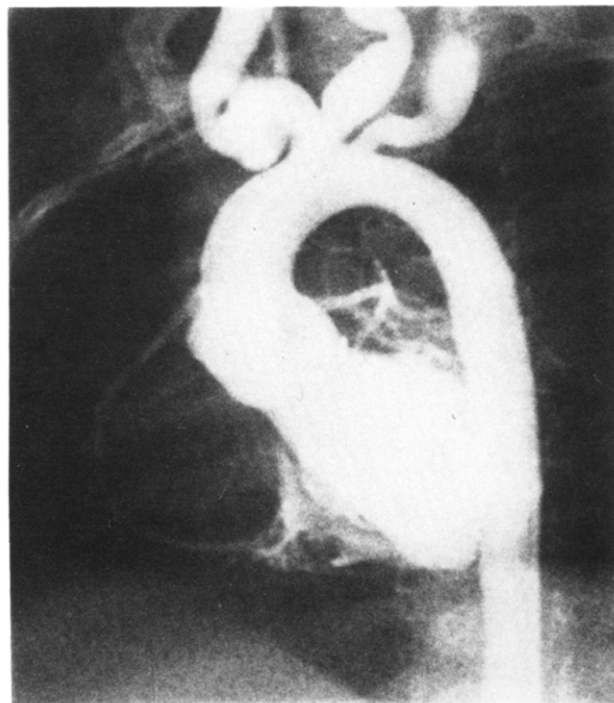


Figure 3. Cardiac catheterization with a left ventricular injection reveals dilatation of the aortic root, aneurysm of the sinus of Valsalva, and dilatation at the origins of the left carotid and right subclavian arteries.

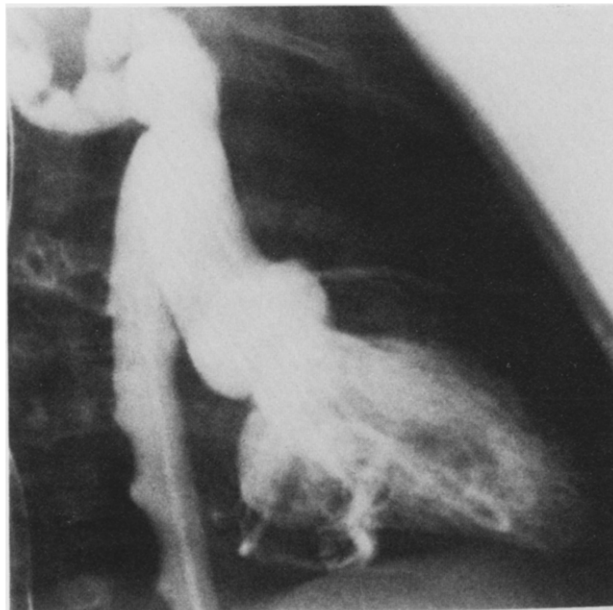


Figure 4. Cardiac catheterization with a left ventricular injection demonstrates the beaded appearance of the descending aorta and multiple ectasias of the right subclavian artery.

groups. Lupi-Herrera et al. [3], reported in a study of 107 patients, that 7% had hemiplegia, 1% had paraplegia, 57% had headache, and 15% had syncope. Cupps and Fauci [4] reported stroke in 7% and syncope in 51%. Tech et al. [5], in a study of 48 patients, described hemiplegia in 10%, headache in 19%, blurred vision in 4%, optic atrophy in 1%, and ptosis in 1%. In a recent study of 32 North American patients, 1 patient had hemiparesis as the result of stroke, 2 patients had seizures, 3 patients had diplopia secondary to cerebrovascular insufficiency, and 2 patients had episodes of amaurosis [8]. The etiology of stroke appears to be thrombus formation or embolus from distal large vessels. No neurologic signs were reported in 7 patients with cardiac valvular involvement [13].

Constitutional symptoms in older patients include weight loss (22%), fever (18%), and asthenia (56%) [3]. Cardiovascular signs and symptoms include hypertension (78%), intermittent claudication (29%), pulse deficit (46%), and vascular bruits (94%) [3]. Elevation of ESR occurs in 83% of patients and C-reactive protein in 23%. The blood urea nitrogen is elevated in 16%, while the creatinine is elevated in 4% [3]. Rheumatoid factor is positive in 4%. Serum γ -globulin is increased in 34% and proteinuria occurs in 28% [3]. In this series from Mexico, 48% of patients had a history of active tuberculosis [3].

Features of Takayasu arteritis overlap those features of granulomatous arteritis and sclerosing arteritis [8]. The granulomatous features correspond to the active phase of the disease, with inflammation confined to the media and adventitia [8]. The cellular infiltrate consists predominantly of lymphocytes, plasma cells, and histiocytes [8]. The sclerosing arteritis signifies the

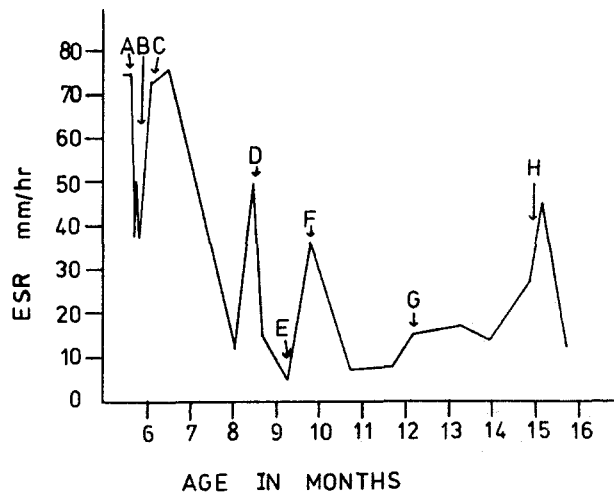


Figure 5. ESR is documented throughout the course of therapy. (A) Dexamethasone 0.5 mg/kg/day; (B) Prednisone 2 mg/kg/day begun; (C) Azathioprine 1 mg/kg/day added; (D) Otitis media; (E) Digital subtraction angiogram and prednisone taper begun; (F) Otitis media; (G) Azathioprine 0.8 mg/kg/day and prednisone 1.25 mg/kg/day; (H) Herpangina, prednisone 2 mg/kg/day, and azathioprine 1.0 mg/kg/day.

chronic phase of the disease [8] which is characterized by bland fibrous intimal hyperplasia, medial degeneration, and adventitial fibrosis [8]. Disruption of the elastic lamina, thrombus formation, and aneurysm formation occur in the chronic phase of the disease. The arterial involvement is divided into four types [3]: type 1 (Shimizu-Sano) involves the ascending aorta and its major branches; type 2 (Kimoto) involves the abdominal aorta and renal arteries; type 3 (Inada)

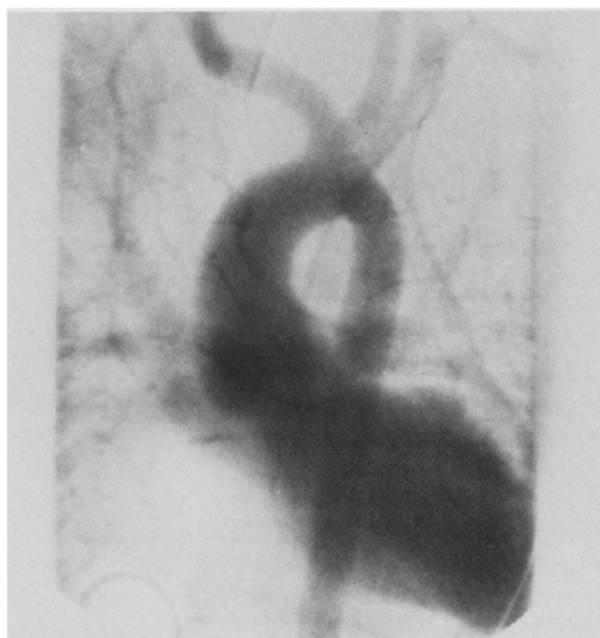

Figure 6. Digital subtraction angiogram with an inferior vena cava injection demonstrates the normal appearance of the origins of the left carotid and right subclavian arteries and lumen of the descending aorta.

combines the features of types 1 and 2, and; type 4 (Lupi-Herrera) involves the pulmonary arteries. Our patient appears to have type 1.

The etiology of Takayasu arteritis is unknown. There is a strong association with previous exposure to tuberculosis. Tuberculin sensitivity has been demonstrated in 81-100% of patients studied [14]. Between 21-70% of patients have had active tuberculosis [14]. The general incidence of active tuberculosis in these populations ranges from 0.028-0.309% and the prevalence from 1.5-4.2%. Rabbits inoculated with *M. tuberculosis* in the subadventitia of the aorta showed changes similar to those of Takayasu arteritis [3]. One pair of twins, born to parents who were first cousins, was reported to be concordant for Takayasu arteritis [15]. HLA and blood types of the twins were identical to the father's. A number of families were reported with involvement in two generations and also families with two affected siblings [15]. However, no consistent HLA association was reported in Japan, Mexico, or the United States [8].

Therapy of stroke in infancy is available for only a few causes, including Takayasu arteritis. It should be distinguished from other forms of focal vasculitis [4], traumatic injury to the carotid artery [16], moyamoya disease [17], sickle cell cerebrovascular disease [18], and embolic occlusion from cardiac thrombi [19]. ESR measurement and ultrasound examination of the heart and great vessels are simple screening tests which help to differentiate Takayasu arteritis from these other conditions, as does the finding of arterial hypertension. Characteristic changes in the large vessels are readily demonstrable by digital subtraction angiography.

Four cases of stroke in Takayasu arteritis have been described in the pediatric population. A 9-month-old female presented with seizures, fever, nystagmus, bulbar signs, and a right hemiparesis. Her ESR was 90 mm/hr, and CSF was normal initially but the protein content rose to 100 mg/dl. Angiography revealed lesions in both common carotid, the left subclavian, and the superior mesenteric arteries, as well as in the descending aorta. The patient died 7 weeks after onset of symptoms despite steroid therapy [10]. Three older children, ages 6-10 years, were reported [20-22], two with fatal outcomes. Takayasu arteritis without cerebrovascular involvement was described in two infants [9,11]. One child presented with an abdominal mass and vomiting at 7 months, and had rapidly progressive heart failure. Autopsy demonstrated an aneurysm of the right common iliac artery and an ilio caval fistula [9]. The other child presented at 6 months of age with failure-to-thrive and excessive sweating. At 8 months of age the child had fever, hypertension, renal failure, and elevated ESR (94 mm/hr). Angiography indicated severe aortic, mesenteric, and renal artery involvement. Both kidneys were reimplanted and the child is doing well 4½ years later, without use of immunosuppressive drugs [11].

This case appears to be an example of restricted involvement (type 2 disease) which may have a better prognosis.

Prior to steroid therapy, 75% of patients died within 2 years of diagnosis [12]. Steroid therapy clearly decreases the signs of systemic inflammation in adult patients with Takayasu arteritis [4,8,12,23]. Adult 5-year survival rate with steroid therapy is 94% [8]. Although it has been suggested that steroid therapy alone is sufficient for most patients with Takayasu arteritis, there has been no controlled trial of the effects of steroids or cytotoxic drugs [4,8]. Steroid therapy alone did not reduce the ESR to normal levels in our patient. Among 29 patients treated with corticosteroids alone, 16 had an ESR initially greater than 40 mm/hr; in only 5 of the 16 did the ESR fall to the normal range after treatment [23]. Of the 29 patients, 18 had positive clinical responses to therapy. The addition of azathioprine resulted in the ESR returning to normal in our patient, accompanied by improvement of the vascular lesions as demonstrated by angiography. Although the disease now may have a low mortality in adults because of corticosteroid therapy, incomplete response to steroids appears to be a reasonable criterion for the use of more vigorous immunosuppression, especially in infants with a rapidly progressive form of the disease.

References

- [1] Savoy WS. Case of a young woman in whom the main arteries of both upper extremities and the left side of the neck were throughout completely obliterated. *Med Chir Trans London* 1856;39:205.
- [2] Kusmaul A. Zwei fälle von spontaner allmählicher verschliessung grosser halsarterien-stämme. *Deutsche Klinik* 1872;24:461.
- [3] Lupi-Herrera E, Sanchez-Torres G, Marcusamer J, et al. Takayasu's arteritis: Clinical study of 107 cases. *Am Heart J* 1977;93:94-103.
- [4] Cupps TR, Fauci A. The vasculitides. Philadelphia: WB Saunders, 1981:107-15.
- [5] Tech PC, Tan LK, Chia BL, et al. Nonspecific aorto-arteritis in Singapore with special reference to hypertension. *Am Heart J* 1978;95:683-95.
- [6] Ishikawa K. Natural history and classification of occlusive thromboaropathy (Takayasu's disease). *Circulation* 1978;57:27-35.
- [7] Takayasu M. Case with unusual changes of the central vessels in the retina. *Acta Soc Ophthalmol Japan* 1908;12:554 translated in Judge RD, Currier RD, Grace WA, et al. Takayasu's arteritis and aortic arch syndrome. *Am J Med* 1962;32:379-92.
- [8] Hall S, Barr W, Lie JT, et al. Takayasu arteritis: A study of 32 North American patients. *Medicine* 1985;64:89-99.
- [9] Gronemeyer PS, Demellow DE. Takayasu's disease, with aneurysm of right common iliac artery and ilio caval fistula in a young infant: Case report and review of the literature. *Pediatrics* 1982;69:626-31.
- [10] Westphal J, Lobbecke F, Mietens C. Arteritis von der abgehenden grossen gefäße (Takayasu-Arteritis) in sauglingsalter. *Klin Paediatr* 1976;188:570-7.
- [11] Eke F, Balfe JW, Hardy BE. Three patients with arteritis. *Arch Dis Child* 1984;59:877-83.
- [12] Fraga A, Mintz G, Valle L, et al. Takayasu's arteritis: Frequency of systemic manifestations (study of 22 patients) and favorable response to maintenance steroid therapy with adrenocorticosteroids (12 patients). *Arthritis Rheum* 1972;15:617-24.

- [13] Gupta SK, Khanna MN, Lahiri TK, et al. Involvement of cardiac valves in Takayasu's arteritis. Report of 7 cases. *Indian Heart J* 1980;32:148-55.
- [14] Pantell JH, Goodman BW. Takayasu arteritis: The relationship with tuberculosis. *Pediatrics* 1981;67:84-8.
- [15] Numano F, Isohisa I, Kishi U, et al. Takayasu's disease in twin sisters. Possible genetic factors. *Circulation* 1978;58:173-7.
- [16] Pitner SE. Carotid thrombosis due to intraoral trauma. *N Engl J Med* 1965;274:764-7.
- [17] Suzuki J, Kodama N. Moyamoya disease: A review. *Stroke* 1984;14:104-9.
- [18] Stockman J, Nigro M, Mishkin M, et al. Occlusion of large cerebral vessels in sickle cell anemia. *N Engl J Med* 1972;287:846-9.
- [19] Carter S, Gold AP. Acute hemiplegia of infancy and childhood. *Pediatr Clin North Am* 1976;23:413-33.
- [20] Wiggelinkhuizen J, Cremin BJ. Takayasu arteritis and renovascular hypertension in childhood. *Pediatrics* 1978;62:209-17.
- [21] Lomas RW, Bolande RP, Gibson WM. Primary arteritis of the aorta in a child. *Am J Dis Child* 1959;97:87-91.
- [22] Vinijchaikul K. Primary arteritis of the aorta and its main branches (Takayasu's arteriopathy). A clinicopathologic autopsy study of eight cases. *Am J Med* 1967;43:15-26.
- [23] Nakao K, Iheda M, Kimata S, et al. Takayasu's arteritis: Clinical report of eighty-four cases and immunological studies of seven cases. *Circulation* 1967;35:1141-54.