

## CASE REPORT

# Cortical blindness as a rare presentation of hemorrhagic cerebral hyperperfusion syndrome following vertebral angioplasty

Chao Fu,<sup>1</sup> Zhongxin Xu,<sup>2</sup> Zhenzhen Hu,<sup>3</sup> Shuai Yao,<sup>2</sup> Fengmin Liu,<sup>1</sup> Baiqi Feng,<sup>4</sup> Conghai Zhao,<sup>1</sup> Weidong Yu<sup>1</sup>

► Additional material is published online only. To view please visit the journal online (<http://dx.doi.org/10.1136/bcr-2017-013412>).

<sup>1</sup>Department of Neurosurgery, China-Japan Union Hospital of Jilin University, Changchun, China

<sup>2</sup>Department of Neurology, China-Japan Union Hospital of Jilin University, Changchun, China

<sup>3</sup>Department of Radiology, China-Japan Union Hospital of Jilin University, Changchun, China

<sup>4</sup>Department of Neurosurgery, Qianguo County Hospital, Songyuan, China

## Correspondence to

Dr Weidong Yu, [fc616@126.com](mailto:fc616@126.com)

CF and ZX contributed equally.

Accepted 26 September 2017

## SUMMARY

Cerebral hyperperfusion syndrome (CHS) is a well-documented complication after carotid endarterectomy or stenting. In contrast, CHS following vertebral revascularization is extremely rare. Here we present a case of a 77-year-old man with high-grade vertebral stenosis who subsequently underwent balloon angioplasty, complicated by hemorrhagic CHS manifesting as cortical blindness, although strict postoperative blood pressure control was administered. To our knowledge, cortical blindness as a presentation of hemorrhagic CHS has not previously been reported. This study highlights the fact that identifying high-risk patients, as well as making an individual therapeutic plan, is important prior to revascularization. Further studies are needed to elucidate the exact mechanism of this condition and thereby prevent it.

## BACKGROUND

Cerebral hyperperfusion syndrome (CHS), defined as >100% increase in cerebral blood flow compared with baseline, is well-described following carotid endarterectomy (CEA) or carotid artery stenting (CAS).<sup>1–3</sup> It usually presents with secondary headache, seizures, focal neurological deficits, cerebral edema, or intracerebral hemorrhage (ICH). The incidence of CHS after CEA is variably reported from 0.5% to 2.2% with an ICH incidence of 0.6%, whereas after CAS the incidence of CHS is 1.1% with an ICH incidence of 0.7%.<sup>4</sup>

However, CHS following vertebral angioplasty is extremely rare, with only five cases having been reported in the literature.<sup>5–8</sup> We present a case of cortical blindness as a rare presentation of hemorrhagic CHS after vertebral angioplasty. Although the clinical manifestations of CHS vary, to the best of our knowledge cortical blindness associated with hemorrhagic CHS has not previously been reported.

## Case presentation

A 77-year-old man presented with dizziness, nausea and vomiting of 12 days duration. He had no history of hypertension. Neurological examination was unremarkable. Admission non-contrast head CT and fluid-attenuated inversion recovery imaging showed no anomaly (figure 1A,B). A diffusion-weighted imaging scan showed a right occipital

lobe infarct (figure 1C). Subsequent catheter-based cerebral angiography revealed an approximately 90% stenosis in the V4 segment of the left vertebral artery (VA), as well as occlusion of the right VA (figure 1D,E).

## TREATMENT

Percutaneous transluminal angioplasty (PTA) without stent placement was scheduled. Antiplatelet therapy with clopidogrel (75 mg/day) and aspirin (100 mg/day) was administered for 3 days. The procedure was performed uneventfully under general anesthesia using a 3 mm × 20 mm catheter balloon (Apollo, MicroPort Medical, Shanghai, China), and the residual stenosis was about 30% (figure 1F). Intravenous heparin was given at a dose of 3000 IU once the operation began, but it was not given continuously because the procedure was finished within an hour. Immediate postoperative CT scans demonstrated no hemorrhage or edema (figure 2A). Anticoagulation therapy was not used after the operation. A systolic blood pressure (BP) target of <120 mm Hg was strictly instituted during the initial 24 hours postoperatively. In recovery the patient was initially asymptomatic; however, 6 hours later he complained of severe headache followed by blindness in both eyes. Examination showed the pupils were equal in size and responsive to light, with no light perception in both eyes (cortical blindness). Emergency head CT scan demonstrated bilateral occipital hemorrhages (figure 2B). The diagnosis of CHS was based on the following: (1) occurrence within 6 hours post-PTA; (2) new onset headache and cortical blindness; (3) bilateral occipital hemorrhages related to the symptoms and signs; (4) absence of other pathologies such as metabolic or coagulation disorders. It was decided to introduce antiedema treatment and his visual acuity gradually improved on postoperative day 5.

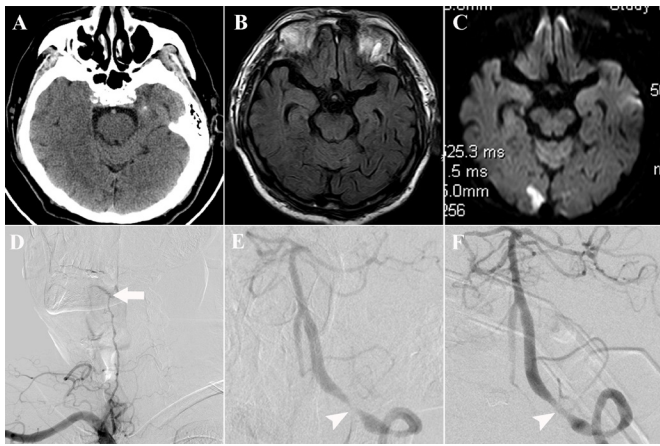
## OUTCOME AND FOLLOW-UP

At 6-month follow-up he still manifested a right homonymous hemianopia. Magnetic resonance angiography showed satisfactory morphology of the left VA and diffusion tensor imaging tractography of the optic radiation showed a remarkable interruption of the left optic radiations (figure 3).



CrossMark

**To cite:** Fu C, Xu Z, Hu Z, et al. *BMJ Case Rep* Published Online First: [please include Day Month Year]. doi:10.1136/bcr-2017-013412

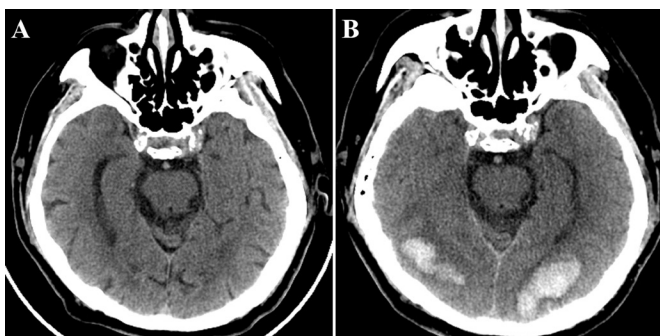


**Figure 1** (A, B) Non-contrast head CT and fluid-attenuated inversion recovery images on admission showing no anomaly. (C) Diffusion-weighted image revealing a right occipital infarct. (D, E) Catheter-based angiograms showing complete occlusion of the right vertebral artery (VA) at the C2–C3 level (arrow) and a high-grade stenosis (arrowhead) of the V4 segment of the left VA, with flow limitation in the vertebrobasilar artery. (F) Angiogram after balloon angioplasty demonstrating satisfactory vertebral recanalization (arrowhead), with a significant increase of blood flow in the vertebrobasilar artery.

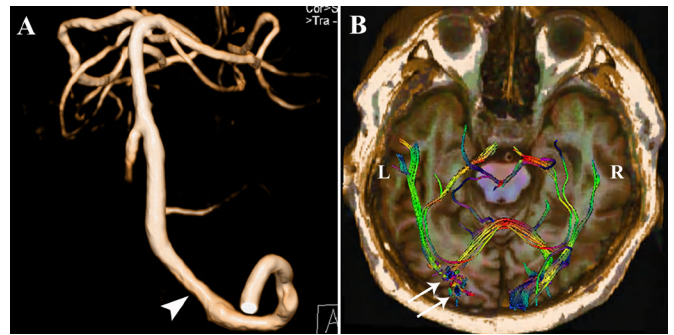
**DISCUSSION**

CHS is a well-documented complication following carotid revascularization procedures; in contrast, this entity following vertebral reconstruction is extremely rare. As far as we know, including our case, only six cases of CHS associated with vertebral revascularization have been reported in the English literature (see online Supplementary table 1).<sup>5–8</sup> Of these, there were five men and only one woman, indicating that male gender is associated with a higher risk of CHS. PTA and stenting was performed in four patients and PTA in two patients. It is of note that all patients had severe stenosis (90–98%). CHS with ICH occurred in four patients while CHS manifested as increased perfusion on single-photon emission CT or xenon-enhanced CT in two patients. Patients with ICH had a worse outcome than those without, which is consistent with a large study by Ogasawara *et al.*<sup>4</sup> To the best of our knowledge, cortical blindness as a presentation of hemorrhagic CHS has not previously been reported.

Although the exact mechanism contributing to this phenomenon has yet to be elucidated, it is likely that the capillary bed beyond the stenosis is prone to perfusion breakthrough bleeding



**Figure 2** (A) Immediate postoperative CT scan showing no hemorrhage or edema. (B) Head CT scan at 6 hours postoperatively showing bilateral occipital hemorrhages.



**Figure 3** (A) Follow-up magnetic resonance angiogram showing satisfactory morphology of the left vertebral artery (arrowhead). (B) Follow-up diffusion tensor image showing a remarkable disruption of the left optic radiation (arrows).

after the increase in blood flow due to the presence of impaired autoregulation.<sup>5</sup> Potential risk factors include older age, hypertension, profound cerebral ischemia, high-grade stenosis, poor collateral blood flow, and contralateral artery occlusion.<sup>1,2</sup> Our patient was aged 77 years and occipital ischemia, high-grade VA stenosis, and contralateral VA occlusion indicated a high risk of CHS; in view of this, we chose balloon angioplasty rather than stent placement. If a stent is deployed during the operation and anticoagulation is continuously used after the procedure, the occurrence of hemorrhagic CHS can lead to a devastating outcome. Therefore, identification of the high-risk patient as well as selection of an individual treatment plan is important prior to revascularization.

It is recommended that BP is rigorously managed in order to prevent CHS; however, no definitive guidelines exist regarding the target BP. Moreover, BP control may be challenging, and even when there is normal BP, CHS can occur.<sup>9</sup> Abou-Chebl *et al.*<sup>10</sup> strictly maintained BP at <120/80 mm Hg in patients at high risk of CHS and found a significant decrease in the incidence of CHS and ICH. In the current study, although postoperative BP was rigorously controlled, it did not seem to help prevent hemorrhagic CHS, which is accordance with a previous study.<sup>4</sup>

Generally, most cases have mild symptoms and signs; progression to severe and life-threatening symptoms, however, can occur if CHS is not recognized and treated adequately.<sup>1</sup> Imaging modalities, including but not limited to transcranial Doppler ultrasound, CT, MRI, single photon emission CT, xenon-enhanced CT, and positron emission CT can be useful in the early diagnosis of CHS.

**CONCLUSION**

CHS is an extremely rare complication of vertebral revascularization. As far as we know, this is the first report of hemorrhagic CHS manifesting as cortical blindness. Identifying high-risk patients and then making an individual therapeutic plan is important prior to revascularization. Further studies are warranted to reveal the underlying mechanisms of this condition and thereby prevent it.

**Contributors** CF, ZX, CZ, and WY diagnosed and treated the patient. CF, ZH, SY, BF, and WY designed the study, interpreted the data, and wrote the manuscript. CF, ZX, FL, CZ, and WY revised the manuscript.

**Competing interests** None declared.

**Patient consent** Obtained.

**Ethics approval** Ethics Committee of the China-Japan Union Hospital of Jilin University.

## Learning points

- ▶ CHS following vertebral revascularization is extremely rare.
- ▶ Cortical blindness is a rare clinical manifestation of hemorrhagic CHS.
- ▶ Preoperative identification of the high-risk patients, as well as selection of an individual treatment plan, is important.

**Provenance and peer review** Not commissioned; externally peer reviewed.

© BMJ Publishing Group Ltd (unless otherwise stated in the text of the article) 2017. All rights reserved. No commercial use is permitted unless otherwise expressly granted.

## REFERENCES

- 1 van Mook WN, Rennenberg RJ, Schurink GW, *et al*. Cerebral hyperperfusion syndrome. *Lancet Neurol* 2005;4:877–88.
- 2 Yoshie T, Ueda T, Takada T, *et al*. Prediction of cerebral hyperperfusion syndrome after carotid artery stenting by CT perfusion imaging with acetazolamide challenge. *Neuroradiology* 2016;58:253–9.
- 3 Pucillo AL, Choragudi NL, Mateo RB, *et al*. Cerebral hyperperfusion after angioplasty and stenting of a totally occluded left subclavian artery: a case report. *Heart Dis* 2003;5:15–17.
- 4 Ogasawara K, Sakai N, Kuroiwa T, *et al*. Intracranial hemorrhage associated with cerebral hyperperfusion syndrome following carotid endarterectomy and carotid artery stenting: retrospective review of 4494 patients. *J Neurosurg* 2007;107:1130–6.
- 5 Rezende MT, Spelle L, Mounayer C, *et al*. Hyperperfusion syndrome after stenting for intracranial vertebral stenosis. *Stroke* 2006;37:e12–e14.
- 6 Meyers PM, Higashida RT, Phatouros CC, *et al*. Cerebral hyperperfusion syndrome after percutaneous transluminal stenting of the craniocervical arteries. *Neurosurgery* 2000;47:335–45.
- 7 Bando K, Satoh K, Matsubara S, *et al*. Hyperperfusion phenomenon after percutaneous transluminal angioplasty for atherosclerotic stenosis of the intracranial vertebral artery. Case report. *J Neurosurg* 2001;94:826–30.
- 8 Zhang R, Zhou G, Xu G, *et al*. Posterior circulation hyperperfusion syndrome after bilateral vertebral artery intracranial stenting. *Ann Vasc Surg* 2009;23:686.e1–686.e5.
- 9 Farooq MU, Goshgarian C, Min J, *et al*. Pathophysiology and management of reperfusion injury and hyperperfusion syndrome after carotid endarterectomy and carotid artery stenting. *Exp Transl Stroke Med* 2016;8:7.
- 10 Abou-Chebl A, Reginelli J, Bajzer CT, *et al*. Intensive treatment of hypertension decreases the risk of hyperperfusion and intracerebral hemorrhage following carotid artery stenting. *Catheter Cardiovasc Interv* 2007;69:690–6.

Copyright 2017 BMJ Publishing Group. All rights reserved. For permission to reuse any of this content visit <http://group.bmj.com/group/rights-licensing/permissions>.  
BMJ Case Report Fellows may re-use this article for personal use and teaching without any further permission.

Become a Fellow of BMJ Case Reports today and you can:

- ▶ Submit as many cases as you like
- ▶ Enjoy fast sympathetic peer review and rapid publication of accepted articles
- ▶ Access all the published articles
- ▶ Re-use any of the published material for personal use and teaching without further permission

For information on Institutional Fellowships contact [consortiasales@bmjgroup.com](mailto:consortiasales@bmjgroup.com)

Visit [casereports.bmj.com](http://casereports.bmj.com) for more articles like this and to become a Fellow