

# Accepted Manuscript

A Case of Subarachnoid Hemorrhage Caused by Tuberculous Aneurysm

Wei Liu, Chuanfeng Li, Xianming Liu, Zhiming Xu, Lu Kong

PII: S1878-8750(17)31856-9

DOI: [10.1016/j.wneu.2017.10.128](https://doi.org/10.1016/j.wneu.2017.10.128)

Reference: WNEU 6781

To appear in: *World Neurosurgery*

Received Date: 28 June 2017

Revised Date: 21 October 2017

Accepted Date: 23 October 2017

Please cite this article as: Liu W, Li C, Liu X, Xu Z, Kong L, A Case of Subarachnoid Hemorrhage Caused by Tuberculous Aneurysm, *World Neurosurgery* (2017), doi: 10.1016/j.wneu.2017.10.128.

This is a PDF file of an unedited manuscript that has been accepted for publication. As a service to our customers we are providing this early version of the manuscript. The manuscript will undergo copyediting, typesetting, and review of the resulting proof before it is published in its final form. Please note that during the production process errors may be discovered which could affect the content, and all legal disclaimers that apply to the journal pertain.



# A Case of Subarachnoid Hemorrhage Caused by Tuberculous Aneurysm

Wei LIU<sup>1</sup>, Chuanfeng LI<sup>2</sup>, Xianming LIU<sup>2</sup>, Zhiming XU<sup>2</sup>, Lu KONG<sup>2</sup>

<sup>1</sup>Department of Neurosurgery, Affiliated hospital of Qingdao University, <sup>2</sup>Qingdao Municipal hospital, Qingdao, China

Corresponding Author: Lu KONG / E-mail: lukongqmh@yahoo.com

## Abstract

In this paper, we report a case of intracranial tuberculoma with adjacent intracerebral inflammatory aneurysm, and include a brief discussion of the developmental mechanism of these pathologies. A 28-year-old man presented with sudden onset of severe headache. He was diagnosed with pulmonary tuberculosis 8 years ago, and had been treated with anti-tuberculosis medications for 6 months. Head computed tomography (CT) showed a small hematoma in the left Sylvian fissure with subarachnoid hemorrhage. Cerebral digital subtraction angiography (DSA) was performed and no aneurysm was found. He was discharged after non-surgical treatment. Three weeks later, he came back to our department with complaint of aphasia. Magnetic resonance (MR) images showed a cystic lesion with mass effect. During operation, we encountered the brain abscess and were surprised to find a middle cerebral artery aneurysm while dissecting. The abscess was totally removed, and the

aneurysm was secured by clipping. The aneurysm was suspected of being inflammatory in nature and associated with the patient's tuberculosis.

A 28-year-old male presented with sudden onset of severe headache, associated with nausea and vomiting. His head computed tomography (CT) examination showed a small hematoma in the left Sylvian fissure with subarachnoid hemorrhage (Fig. 1). He was diagnosed with pulmonary tuberculosis 8 years ago and had been treated with anti-tuberculosis medications for 6 months with good compliance. He later discontinued the medicine by himself as the tuberculosis seemed to be cured. After admission, his chest CT revealed multiple patchy shadows (Fig. 2). Cerebral angiography was performed, and no intracranial aneurysm was found (Fig. 3). After 2 weeks of non-surgical treatment, the patient recovered and was discharged. Three weeks later, the patient came back and presented with headache and aphasia. Brain magnetic resonance (MR) images showed a round subcortical mass which was 5 cm in diameter on the left temporal lobe. The lesion was hypointensive on both T1-weighted imaging and T2-weighted imaging and a ring enhancement was found after contrast (Fig. 4). The patient underwent surgical treatment. The operation was performed through pterional approach, and high intracranial pressure was noted after dural opening. In the process of dissection, we encountered a brain abscess which consisted of a thick fibrous wall and dark brown purulent liquid. After the exudate

was evacuated and the wall of abscess was completely removed, we were surprised to find a saccular aneurysm which was 6 mm in diameter arising from M2 bifurcation of the left middle cerebral artery (Fig.5). The aneurysm was judiciously examined. As the neck was not wide and the shape was regular, the clipping procedure seemed to be quite straight-forward. The aneurysm was occluded by a single clip, then the aneurysm wall was resected. The cyst fluid, abscess wall and the aneurysm tissue were sent to lab for pathological examination. CT examination was performed on the third day postoperatively which confirmed the abscess was totally removed (Fig. 6). Pathological results showed the wall of abscess consisted of fibrous connective tissue with severe chronic inflammation. Microscopically, the cystic wall was composed of many plasma cells, lymphocytes with neutrophils infiltration. The typical multi-nuclear giant cell response was also identified. The aneurysm tissue had similar characteristics that were mentioned above. In addition, eosinophils, foam cell infiltration, necrosis in some areas, and phagocytosis of hemoglobin-containing macrophages were observed. (Fig. 7a, 7b). Furthermore, a polymerase chain reaction test for tuberculosis was positive. Accordingly, the mass was confirmed to be a tuberculous brain abscess and tuberculous infectious aneurysm. He was subsequently treated by anti-tuberculous medication for 12 months. Then he was reexamined by CT and MR, which showed no

recurrence of brain abscess and aneurysm (Fig. 8a, b). The patient recovered gradually and completely.

### **Discussion:**

Although intracranial tuberculomas develops in 1% of all patients with active tuberculosis, few reports are available on aortic aneurysms that are associated with pulmonary tuberculosis, or on intracranial inflammatory aneurysms associated with tuberculous meningitis (TBM) [1–3].

Subarachnoid hemorrhage caused by rupture of tuberculosis associated aneurysm is a rare complication and only a few case reports has been published so far. However, most of the reports focus on the mechanism of infectious aneurysm formation secondary to intracranial tuberculosis. Our case is specially about the tuberculous cerebral abscess caused by rupture of the infectious aneurysm. To our knowledge, no one has reported such case before. The small aneurysm was almost full of thrombus and located at the M2 bifurcation. After the aneurysm was clipped, a portion of the aneurysm wall was removed for histopathological examination, and results showed that the aneurysm was caused by a tuberculous vascular inflammation. These observations suggested that the aneurysms were infectious and related to tuberculosis. At surgery, the abscess wall was also removed and sent for histopathological examination, which confirmed the diagnosis of tuberculous brain abscess. The bacteria within

the aneurysm and its parent artery were released to subarachnoid space after aneurysm rupture, thus led to the rapid formation of brain abscess. Although DSA was performed and no vascular lesion was found after the patient's first subarachnoid hemorrhage, we were surprised to find such an aneurysm after careful checkup during the operation. The aneurysm was solid and filled with thrombus, suggesting that it was an inflammatory aneurysm and there was no blood flow within it. Thus, the aneurysm was not detected on both DSA and MR images, and could be readily misdiagnosed primarily.

Tuberculosis in the central nervous system may present as tuberculoma, cerebral abscess, or TBM. Vasculitis secondary to TBM can cause infarcts, and, rarely, aneurysm formation. Inflammatory changes occur in the vessel wall of the arteries bathed in the exudate leading to narrowing of the lumen or occlusion by thrombus formation [4,5]. Intracranial tuberculous aneurysm may develop by two mechanisms: arteritis caused by the bacteria and weakening of the vessel wall due to inflammatory exudate [6,7]. This case report illustrated a rare case of intracranial infectious aneurysm related to tuberculosis and complicated by hemorrhage and brain abscess.

## Reference

1. Griffiths SJ, Sgouros S, James G, et al. Intraventricular hemorrhage due to ruptured posterior inferior cerebellar artery aneurysm in tuberculous meningitis. *Childs Nerv Syst* 2000; 16:872-4
2. Gupta PK, Gupta S, Singh D, et al. MR imaging and angiography in tuberculous meningitis. *Neuroradiology* 1994; 36:87-92.
3. Whelan MA, Stern J. Intracranial tuberculoma. *Radiology* 1981; 138:75-81.
4. Artal C. Infections of the spinal cord. In: Garcia MJC, editor *CNS infections: a clinical approach*. London: Springer-Verlag; 2014. p. 181–210.
5. Misra UK, Kalita J, Maurya PK. Stroke in tuberculous meningitis. *J Neurol Sci*. 2011; 303:22–30.
6. Saraf R, Limaye U. Ruptured intracranial tubercular infectious aneurysm secondary to a tuberculoma and its endovascular management. *Br J Neurosurg* 2013; 27:243-5.
7. Leiguarda R, Berthier M, Starkstein S, Nogués M, Lylyk P. Ischemic infarction in 25 children with tuberculous meningitis. *Stroke* 1988; 19:200-4.

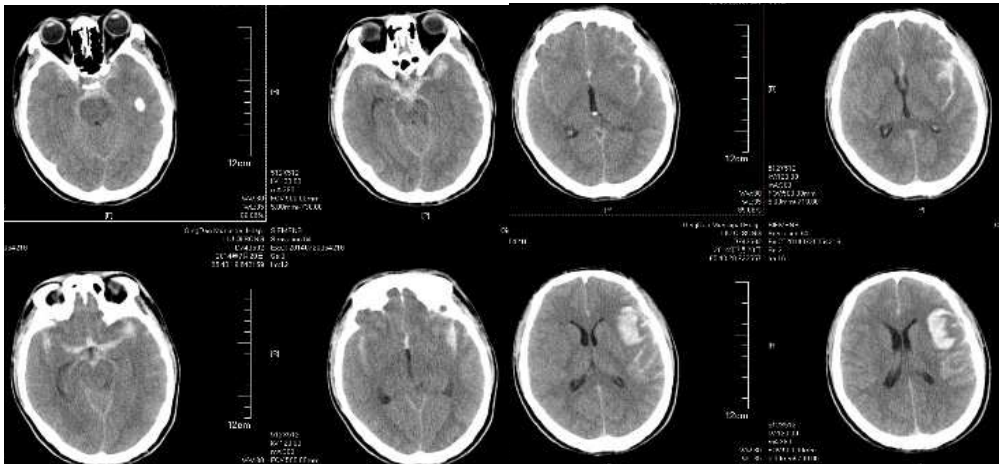


Fig. 1 Subarachnoid hemorrhage and hematoma. CT scan showing subarachnoid hemorrhage and hematoma. A hematoma is noted in the region of the left sylvian fissure.

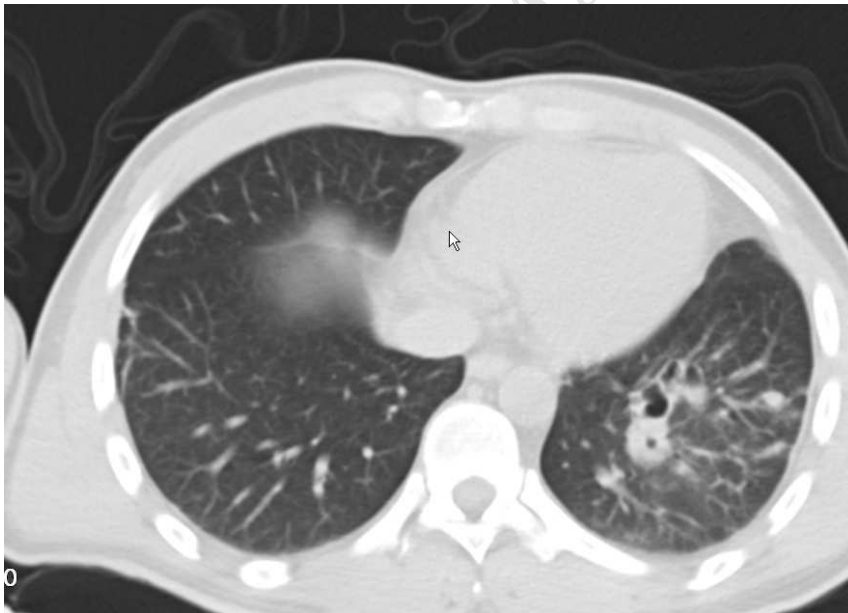

Fig. 2 Pulmonary CT scan. Patchy shadow can be found in the left lower lung, suspected tuberculosis.



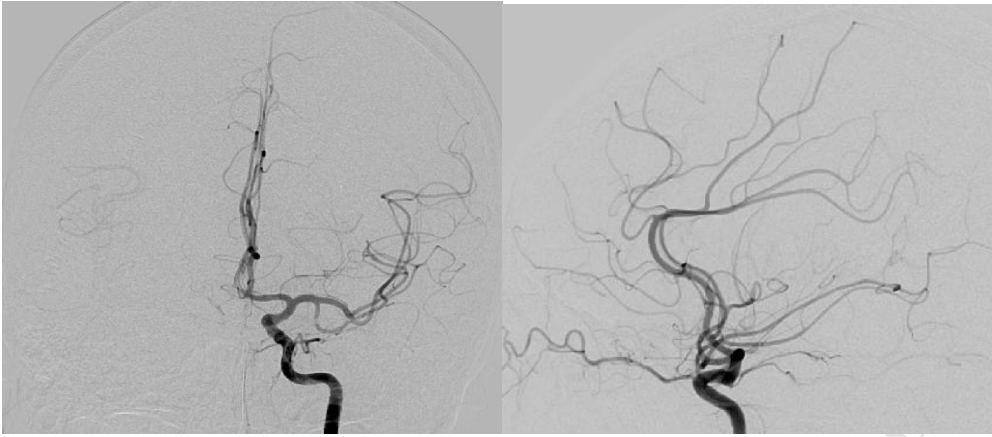


Fig. 3 Cerebral aneurysms and other vascular malformations were not found after DSA

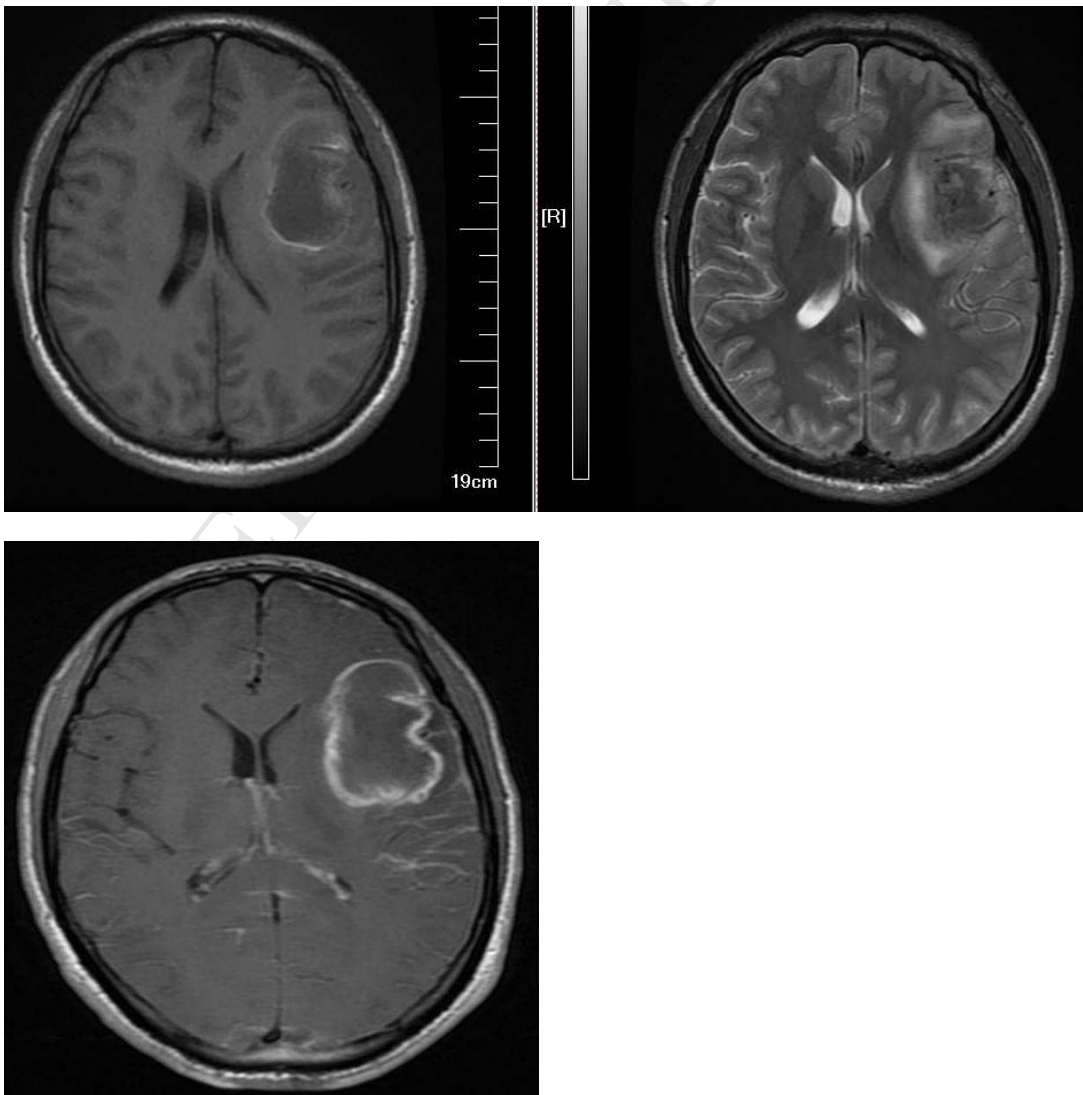


Fig. 4 MRI showing ring enhancing lesions in the posterior frontal lobe with perilesional edema suggestive of cerebral abscess.

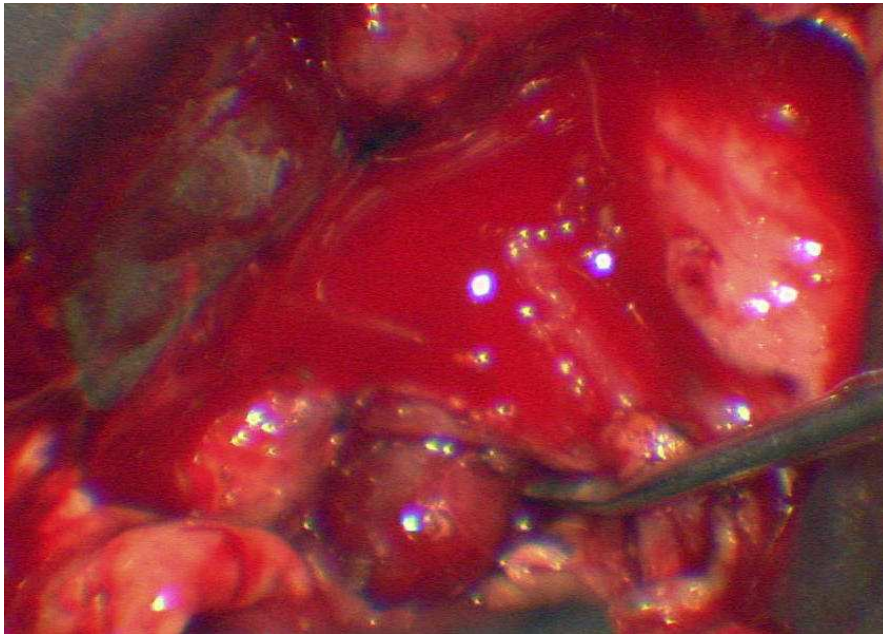


Fig.6 a saccular aneurysm was found during the surgery.

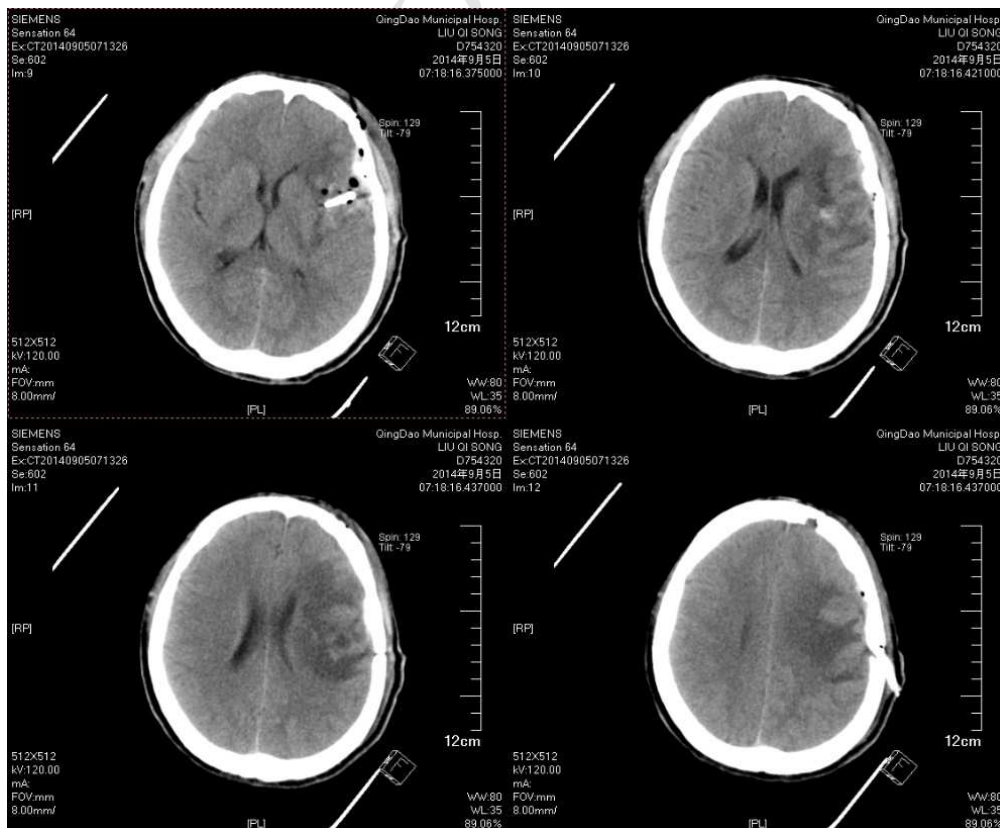


Fig. 6 CT examination after cerebral abscess was resected and aneurysm was clipped.

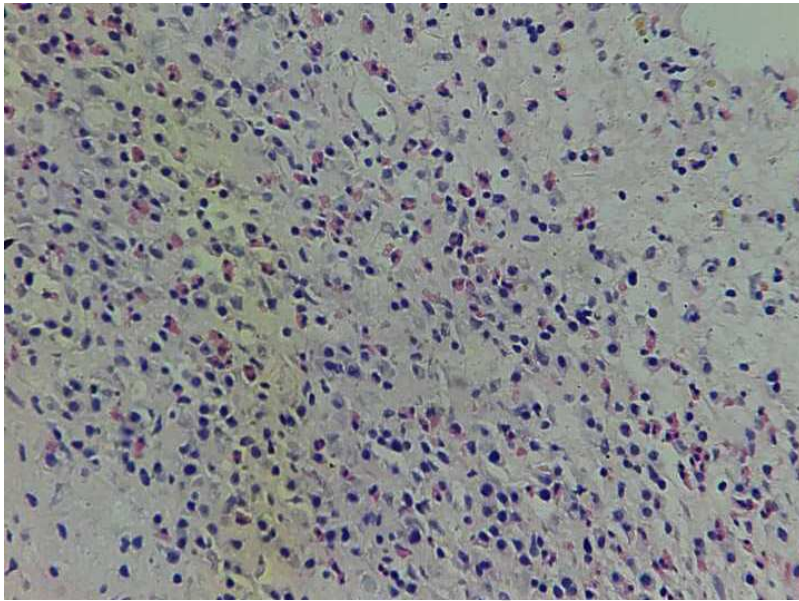


Fig. 7a The pathological examination of the aneurysm wall showed a lot of plasma cells, lymphocytes, eosinophils, foam cell infiltration, necrosis in some areas, and phagocytosis of hemoglobin-containing macrophages were observed.





treatment, no recurrence of tuberculosis abscessFi.

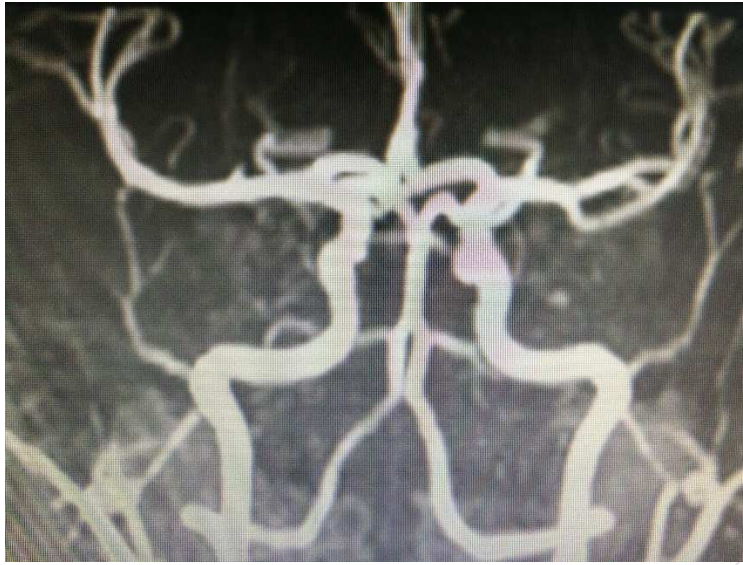


Fig 8b, the MR angiography showed no recurrence of aneurysm.

## Highlights

- Reporting a rare case of tuberculous related abscess and intracranial aneurysm concurrently.
- Tuberculous may cause infectious aneurysms and brain abscess even after long-time remission.
- mechanism of tuberculosis related vasculitis and formation of aneurysm.

## Abbreviation

CT	computed tomography
DSA	digital subtraction angiography
MR	magnetic resonance
MCA	middle cerebral artery
TBM	tuberculous meningitis

ACCEPTED MANUSCRIPT