

# Brachiocephalic Arterial Occlusive Disease Presenting as Limb-Shaking Transient Ischemic Attacks

Eric D. Goldstein, MD,\* Rocco Cannistraro, MD,\* Stephen English, MD,†  
Rocio Vazquez Do Campo, MD,\* and Benjamin Eidelman, MD, PhD\*

Limb-shaking transient ischemic attacks (LSTIAs) are a phenomenon that occurs due to transient hypoperfusion to a cerebral motor territory with a chronically outstripped autoregulatory vascular reserve. First described in 1962 by Miller Fisher, the pathogenesis and the global understanding of this presentation have undergone a significant advancement throughout the years. Typically, patients will present with this syndrome of transient hypoperfusion in the context of extracranial carotid intrinsic vessel stenosis or by intracranial vascular stenosis to select motor pathways. We present within this case report a novel mechanism by which LSTIAs may emerge. Through this knowledge, clinicians may need to consider expansion of their diagnostic breadth to include proximal vasculature luminal integrity.

**Key Words:** Stroke—limb-shaking TIA—TIA—myoclonus.

© 2017 National Stroke Association. Published by Elsevier Inc. All rights reserved.

## Case Report

A 76-year-old right-handed Caucasian man presented with a 3-month duration of “seizure-like episodes” consisting of irregular jerking movements of the left hemibody extremities occurring with positional changes. Based on clinical history, the subject’s symptoms were consistent with limb-shaking transient ischemic attacks (LSTIA). Computed tomography with angiography of the head and neck revealed 41% stenosis of the right internal carotid artery at the level of the carotid bulb as well as nonspecific subcortical microvascular ischemic findings. Neurosurgery was consulted for further characterization of the cervical vasculature by conventional arteriography, revealing

a significant calcific stenosis of the brachiocephalic artery (Fig 1). Dynamic duplex carotid ultrasonography was performed, demonstrating a supine peak systolic velocity of 45 cm/s and a reduction to 21 cm/s with erect posture. Subsequently, a left subclavian to carotid bypass along with a left common-to-right common carotid bypass was performed by vascular surgery. The postoperative interview revealed a resolution of the LSTIA events.

## Discussion

LSTIAs were first described by Miller Fisher in 1962.<sup>1</sup> Although not personally witnessed, Fisher illustrates movements with a description of “shaking, twisting, drawing up or moving irregularly.” Initially, LSTIAs were thought to be embolic in nature; however, over time, an association with contralateral carotid occlusive disease was noted.<sup>2,3</sup> Furthermore, chronically reduced cerebral blood flow with a maximally dilated cerebral vasculature serves as the backdrop for symptom onset.<sup>4</sup> Since its description, several other causes have been recognized, including the moyamoya phenomenon and focal stenosis of the anterior cerebral artery.<sup>5,6</sup> However, carotid occlusive disease is the most well-described etiology, with 1 study revealing

From the \*Department of Neurology, Mayo Clinic, Jacksonville, Florida; and †Department of Neurology, Mayo Clinic, Rochester, Minnesota.

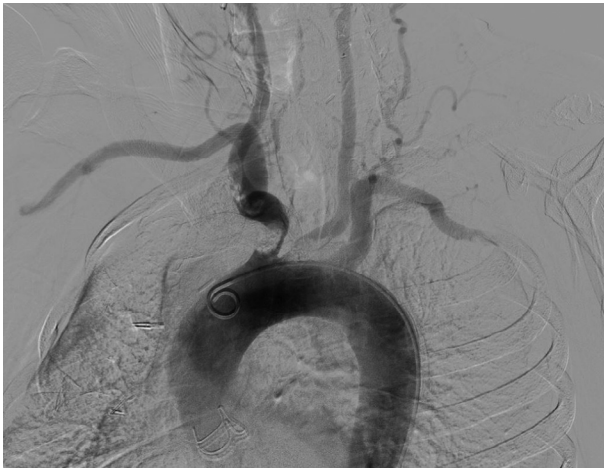
Received July 23, 2017; accepted September 24, 2017.

Address correspondence to Eric D. Goldstein, MD, Department of Neurology, Mayo Clinic, 4500 San Pablo Rd Cannaday 2E, Jacksonville, FL 32224. E-mail: [Goldstein.eric@mayo.edu](mailto:Goldstein.eric@mayo.edu).

1052-3057/\$ - see front matter

© 2017 National Stroke Association. Published by Elsevier Inc. All rights reserved.

<https://doi.org/10.1016/j.jstrokecerebrovasdis.2017.09.052>



**Figure 1.** Conventional arteriogram revealing a significant intraluminal brachiocephalic arterial occlusive disease without a significant proximal carotid disease. One can also note vertebral artery vasculopathy.

of 147 patients with symptomatic internal carotid artery disease, 28.6% experienced LSTIA symptoms and served as a poor predictor for long-term functional outcomes.<sup>7</sup>

To our current knowledge, there does not appear to be documented reports of brachiocephalic vasculopathy presenting as LSTIA. The patient described has significant vasculopathy both intra- and extracranially, which may account for a chronically vasodilated state outstripping an inherent cerebral autoregulatory reserve. This

report, together with other documented vascular etiologies, contributes to a growing body of evidence that hypoperfusion-related cerebral ischemia is not solely confined to carotid disease, but may be anywhere along the proximal cerebral vascular tree. When faced with a patient presenting similarly, providers may need to extend their diagnostic inquiry from a focal carotid investigation to a comprehensive vascular study.

## References

1. Fisher CM. Concerning recurrent transient cerebral ischemic attacks. *Can Med Assoc J* 1962;86(June):1091-1099.
2. Yanagihara T, Piepgras DG, Klass DW. Repetitive involuntary movement associated with episodic cerebral ischemia. *Ann Neurol* 1985;18:244-250.
3. Tatemichi TK, Young WL, Prohovnik I, et al. Perfusion insufficiency in limb-shaking transient ischemic attacks. *Stroke* 1990;21:341-347.
4. Baumgartner RW, Baumgartner I. Vasomotor reactivity is exhausted in transient ischaemic attacks with limb shaking. *J Neurol Neurosurg Psychiatry* 1998;65:561-564.
5. Kim HY, Chung CS, Lee J, et al. Hyperventilation-induced limb shaking TIA in moyamoya disease. *Neurology* 2003;60:137-139.
6. Han SW, Kim SH, Kim JK, et al. Hemodynamic changes in limb shaking TIA associated with anterior cerebral artery stenosis. *Neurology* 2004;63:1519-1521.
7. Knoflach M, Matosevic B, Meinhart M, et al. Prognostic relevance of limb shaking in symptomatic carotid artery occlusion. *Cerebrovasc Dis* 2011;32:35-40.