

CASE REPORT

Anabolic steroid abuse: what shall it profit a man to gain muscle and suffer the loss of his brain?

M. Omar, R. Abdul, A. Panday and S. Teelucksingh

From the Department of Internal Medicine, Medical Associates Hospital, Corner Albert and Abercromby Streets, St. Joseph, Trinidad and Tobago.

Address correspondence to M. Omar, Department of Internal Medicine, Medical Associates Hospital, Corner Albert and Abercromby Streets, St. Joseph, Trinidad and Tobago. email: mike.b.omar@gmail.com

Learning Point for Clinicians

The use of anabolic androgenic steroids may be an underestimated cause of cerebral venous thrombosis. The pervasive yet clandestine use of these and other endocrine modulating drugs amongst athletes challenges the epidemiological study of their pro-thrombotic consequences and by extension the astuteness of the clinician in such a circumstance as depicted in this case.

Case presentation

A 30-year-old previously well bodybuilder presented with a 3-day history of increasingly frequent focal motor seizures of his left upper limb and subtle dyscognitive changes ranging from 10 to 30 s duration. Soon after admission, he developed dysarthria and a left sided hemiparesis with greater weakness in the upper limb.

There was no history of headaches or visual changes and his medical, surgical and family history were unremarkable. There was no history of smoking but drug history revealed the consistent use of cycles of anabolic androgenic steroids (AAS) for the preceding 2 years.

The cycles involved parenteral testosterone enanthate 500 mg combined with nandrolone decanoate 400 mg weekly for 3 months. This was alternated with a post-cycle regimen of daily clomiphene citrate 100 mg and tamoxifen citrate 40 mg as well as weekly tapering doses of beta-human chorionic gonadotropin (hCG) 5000 IU for almost 2 months before resuming androgens.

Physical examination exhibited a 90 kg man of athletic build with mild dysarthria and a dense, flaccid left sided hemiparesis including the face. Otherwise, there were no abnormalities.

Laboratory investigations showed a haemoglobin of 18.0 g/dl and a haematocrit of 52.9% with no morphological abnormalities on the blood film. Screening tests for connective tissue and hypercoagulable disorders (including erythrocyte sedimentation rate, anti-neutrophilic antibodies, factor V Leiden, protein C, protein S and lupus anticoagulant) were negative. Renal and liver function tests were also within normal limits but JAK2 mutation testing was not obtained due to financial constraints.

Magnetic resonance imaging with venography of the brain revealed acute superior sagittal sinus thrombosis (Figure 1) with an associated cortical based acute infarct in the right parietal lobe. No haemorrhagic conversion was noted at that time.

The patient was treated with sodium valproate to control seizures and low molecular weight heparin was used as a prelude to initiating anticoagulation with warfarin. The pivotal factor in further management was counselling against future use of performance enhancement drugs.

Over the ensuing 6 months of follow-up, with strict compliance to management, there was marked improvement in power and the haematocrit decreased to 45%. Additionally, he has remained seizure free allowing the discontinuation of the anticoagulation and anti-epileptic drugs. Fortunately, there appears to be no residual adverse effects.

Discussion

The use of AAS and other endocrine modulating drugs is not uncommon amongst young athletes and gym enthusiasts¹ with under-reporting of their potential side effects.

Testosterone and other synthetic analogues such as nandrolone are abused for their myotrophic potential to enhance appearance and performance. Ostensibly, AAS are cycled with the use of oestrogen modulators such as tamoxifen to prevent

Submitted: 24 June 2017; Revised (in revised form): 26 June 2017

© The Author 2017. Published by Oxford University Press on behalf of the Association of Physicians. All rights reserved.

For Permissions, please email: journals.permissions@oup.com

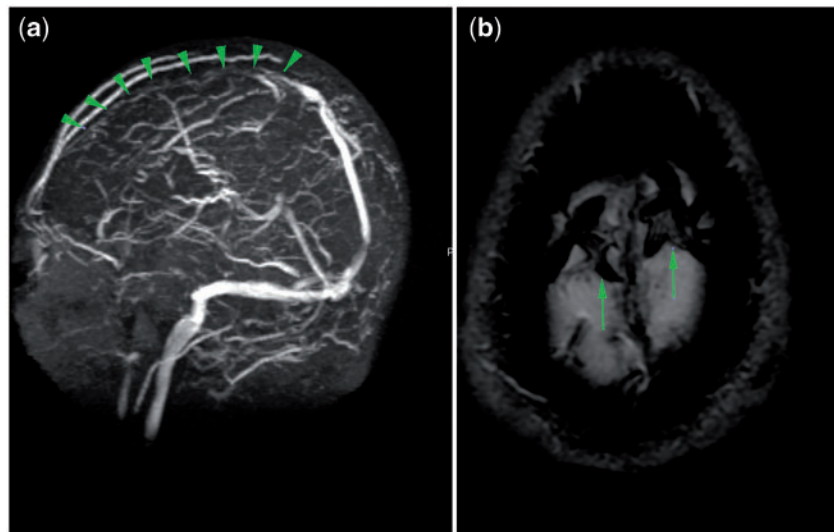


Figure 1. Left (a)—Coronal magnetic resonance venography reveals loss of vascular flow signal in the superior sagittal sinus and the bilateral superficial cortical veins in the frontal and anterior parietal lobes (arrowheads). Right (b)—Axial gradient-echo magnetic resonance image of the superior aspect of the brain demonstrates 'blooming' of the clot in the thrombosed superficial cerebral cortical veins (arrows).

gynaecomastia and clomiphene citrate and hCG to re-stimulate endogenous luteinizing hormone preventing testicular atrophy.

On review of the existing literature, there are few case reports suggesting an association between tamoxifen and cerebral thrombosis.² However, these cases were in the setting of adjuvant therapy for breast cancer which in itself may predispose to a pro-thrombotic state. Additionally, there is sparse compelling data to demonstrate the thrombogenicity of either clomiphene or hCG.

On the other hand, there is existing and emerging literature associating exogenous androgen therapy with an increased risk of both arterial³ and venous thrombosis.^{4,5} In particular, a few case reports have purported the use of AAS as a sole risk factor for cerebral venous thrombosis⁴⁻⁶ and especially in previously healthy, young bodybuilders. The suggested mechanism entails androgenic stimulation of platelet aggregation through either increased production of thromboxane A₂ or decreased prostacyclin and cyclooxygenase activity. Another possible pathogenic mechanism may reside in the stimulatory effect of androgens on erythropoietin synthesis, polycythaemia and increased blood viscosity³ as was evident in the current case.

Conflict of interest: None declared.

References

1. Maharaj VR, Dookie T, Mohammed S, Ince S, Marsang BL, Teelucksingh S. *et al.* Knowledge, attitudes and practices of anabolic steroid usage among gym users in Trinidad. *West Indian Med J* 2000; **49**:55–8.
2. Kim Y, Kim OJ, Kim J. Cerebral venous thrombosis in a breast cancer patient taking tamoxifen: report of a case. *Int J Surg Case Rep* 2015; **6**:77–80.
3. Stergiopoulos K, Brennan JJ, Mathews R, Setaro JF, Kort S. Anabolic steroids, acute myocardial infarction and polycythemia: a case report and review of the literature. *Vasc Health Risk Manag* 2008; **4**:1475–80.
4. Jaillard AS, Hommel M, Mallaret M. Venous sinus thrombosis associated with androgens in a healthy young man. *Stroke* 1994; **25**:212–3.
5. Sahraian MA, Mottamedi M, Azimi AR, Moghimi B. Androgen-induced cerebral venous sinus thrombosis in a young body builder: case report. *BMC Neurol* 2004; **4**:22.
6. Sveinsson O, Herrman L. Cortical venous thrombosis following exogenous androgen use for bodybuilding. *BMJ Case Rep* 2013; **2013**:bcr2012008638.