



Advantages of Staged Angioplasty in a Patient with Internal Carotid Artery Pseudo-Occlusion Besides Prevention of Cerebral Hyperperfusion Syndrome

Satoshi Takahashi¹, Takenori Akiyama¹, Jin Nakahara², Takahito Yoshizaki², Norihiro Suzuki², Kazunari Yoshida¹

Key words

- Carotid artery stenting
- Cerebral hyperperfusion syndrome
- Pseudo-occlusion
- Staged angioplasty

Abbreviations and Acronyms

CAS: Carotid artery stenting
CBF: Cerebral blood flow
CHS: Cerebral hyperperfusion syndrome
CT: Computed tomography
CVR: Cerebrovascular reserve
ICA: Internal carotid artery
MCA: Middle cerebral artery
PTA: Percutaneous transluminal angioplasty

From the Departments of ¹Neurosurgery and ²Neurology, Keio University, School of Medicine, Tokyo, Japan

To whom correspondence should be addressed:
 Satoshi Takahashi, M.D., Ph.D.
 [E-mail: satoshi710@mac.com]

Citation: *World Neurosurg.* (2018) 109:409-412.
<https://doi.org/10.1016/j.wneu.2017.10.096>

Journal homepage: www.WORLDNEUROSURGERY.org

Available online: www.sciencedirect.com

1878-8750/\$ - see front matter © 2017 Elsevier Inc. All rights reserved.

INTRODUCTION

Staged angioplasty has been reported to be effective in preventing postoperative cerebral hyperperfusion syndrome (CHS) in patients with severe carotid artery stenosis^{1,2}; thus, it is also recommended in patients with internal carotid artery (ICA) pseudo-occlusion.

Here, we report on a patient with left ICA pseudo-occlusion that was successfully treated by staged angioplasty. Some previously unreported advantages of staged angioplasty in patients with acute ICA pseudo-occlusion are discussed.

CASE DESCRIPTION

Onset and Course

An Asian man in his 50s presented at the emergency room with the chief complaint of motor aphasia and severe motor weakness (manual muscle test score of 2/5) mainly in his right upper extremity.

■ **BACKGROUND:** Staged angioplasty for carotid artery stenosis has been reported to be effective in preventing postoperative cerebral hyperperfusion syndrome (CHS) in patients with severe carotid stenosis; thus, it is also recommended for patients with internal carotid artery (ICA) pseudo-occlusion, the treatment strategy for which is controversial.

■ **CASE DESCRIPTION:** This study reports the case of an Asian man in his 50s who had motor aphasia and right-side weakness caused by pseudo-occlusion of the left ICA. After medical treatment, he underwent a staged angioplasty. After the first stage of percutaneous transluminal angioplasty, anterograde blood flow to the left ICA increased but the distal ICA remained partially collapsed. Initially, the second stage of carotid artery stenting (CAS) was planned for 2 weeks after the first stage; however, hemorrhagic infarction was observed the day before the CAS, and it was postponed by 2 weeks, after adjustment of antiplatelet therapy. At the time of the CAS, the diameter of the initially collapsed left distal ICA was remodeled and it was fully dilated; thus, we used a balloon-type embolic protection device and conducted CAS successfully without apparent embolic complications. The postoperative course was uneventful. The patient did not develop CHS.

■ **CONCLUSIONS:** Besides preventing CHS, staged angioplasty has advantages when used for treating patients with ICA pseudo-occlusions in that the extent of dilation of the distal ICA after percutaneous transluminal angioplasty can be confirmed and the development of a possible hemorrhagic infarction can be assessed before stent placement.

Magnetic resonance imaging showed a high-intensity area in his left frontal lobe on diffusion-weighted imaging—fluid-attenuated inversion recovery, suggesting acute cerebral infarction (Figure 1C and D). The time of symptom onset was unknown, and the patient could not be treated by intravenous injection of alteplase. The C4 and C5 regions of the left ICA were not depicted well, and signals from the left middle cerebral artery (MCA) were weaker than those from the contralateral side (Figure 1A). The patient was admitted and initially treated with argatroban, aspirin, statin, and clopidogrel (Figure 2). Because carotid artery ultrasonography suggested severe stenosis or occlusion of the left ICA, cerebral angiography was performed on the ninth day of admission, showing severe stenosis of the left ICA just after carotid bifurcation along with delayed

blood flow to the distal ICA (Figure 3A and B). A diagnosis of pseudo-occlusion of the left ICA was made. Cerebral blood flow (CBF) to the left MCA region was maintained through collaterals from the left posterior communicating artery and recurrent meningeal artery from the external carotid artery (Figure 3B and C). Single-photon emission computed tomography (CT) showed a substantial decrease in blood flow to the left MCA region (Figure 1G and H), and surgical intervention aiming at increasing blood flow to the region was proposed to the patient and his family, who were completely informed of the risks associated with the procedure.

Surgical Intervention

Because the extent of the decrease in CBF was considerably high, we chose staged angioplasty as the surgical strategy. On the twelfth

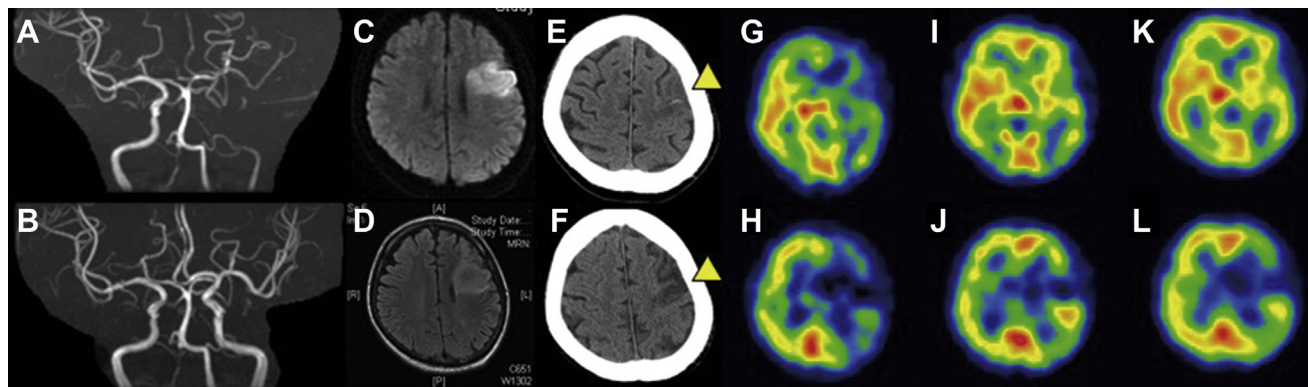


Figure 1. Magnetic resonance imaging (MRI), computed tomography, and single-photon emission computed tomography images. (A) MRI angiography on admission showed that the C4 and C5 portions of the left internal carotid artery were not depicted well and that signals of the left middle cerebral artery were weaker than those from contralateral side. (B) The left internal carotid artery and middle cerebral artery were depicted well after carotid artery stenting. (C) Diffusion-weighted imaging and (D)

fluid-attenuated inversion recovery MRI showed an acute infarction in the left frontal lobe. (E) The hemorrhagic infarction (arrowhead) was observed on a computed tomography image obtained 13 days after percutaneous transluminal angioplasty (PTA), (F) but it had not enlarged 2 weeks later (arrowhead). Cerebral blood flow of the left hemisphere was significantly decreased before PTA (G, H), recovered on PTA (I, J), and remained unchanged after carotid artery stenting (K, L).

day of admission, percutaneous transluminal angioplasty (PTA) was performed. Under local anesthesia, an 8-F guiding catheter was introduced into the left common carotid artery after systemic heparinization. A filter-type embolic protection device was navigated into the distal ICA through the stenotic lesion, and the lesion was dilated with a 3-mm semicompliant balloon. After the procedure, anterograde blood flow to the left ICA increased (Figures 3D and 4B), but the distal ICA remained partially collapsed. Carotid artery stenting (CAS) was initially planned for 2 weeks after the PTA; however, a CT scan performed the day before the CAS showed a hemorrhagic infarction (Figure 1E). Antiplatelet therapy was adjusted to prevent worsening of the

hemorrhagic infarction (Figure 2), and CAS was performed 2 weeks later, after another confirmatory CT scan (Figure 1F). During CAS, the diameter of the initially collapsed left distal ICA was remodeled and dilated (Figure 3E); thus, we could use a balloon-type embolic protection device. Under local anesthesia, an 8-F guiding catheter was introduced into the left common carotid artery after systemic heparinization. The balloon-type embolic protection device was navigated into the distal ICA through the stenotic lesion. After predilatation with a 3-mm semicompliant balloon, a self-expanding closed-cell nitinol stent was placed (Figure 3F), and postdilatation with a 4-mm semicompliant balloon was further performed.

Postoperative Course

The postoperative course was uneventful (Figures 1B and 3F). The patient did not develop CHS (Figure 1I–L) and his motor aphasia in conjunction with motor weakness improved (to a manual muscle test score of 3/5). He was transferred to a nearby rehabilitation hospital 2 months after admission. Further carotid artery ultrasonography was performed just before the transfer; carotid artery stenosis was still improved, and there was no sign of restenosis.

DISCUSSION

Pseudo-occlusion of the ICA is characterized by an extremely narrow residual

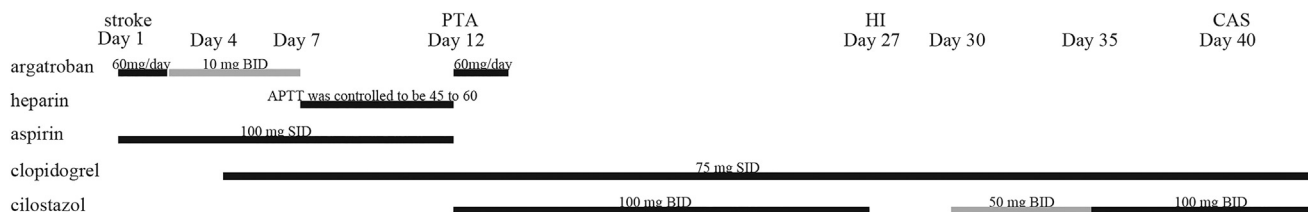
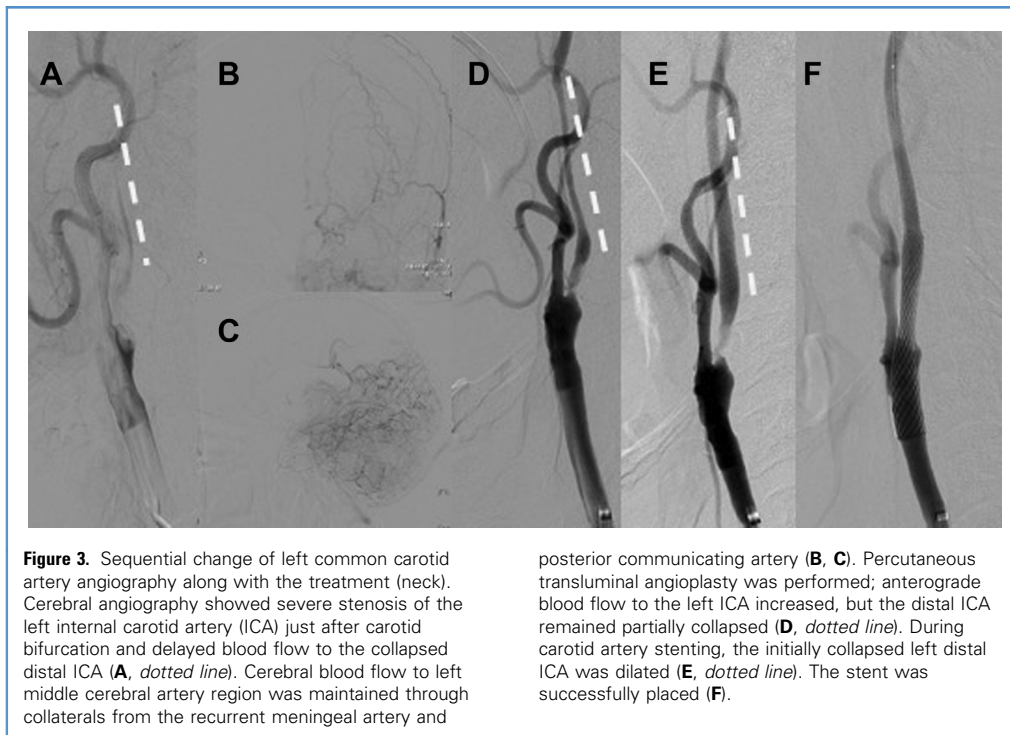


Figure 2. Summary of antithrombotic therapy. After admission, the patient was initially treated with argatroban and aspirin. Clopidogrel was added on day 4. Heparin was started on day 7 instead of argatroban, and argatroban was restarted after percutaneous transluminal angioplasty for 2 days (for reasons of health care insurance). The day before percutaneous transluminal angioplasty, VerifyNow assay (Accriva Diagnostics, San Diego, California, USA) showed that the patient’s aspirin reaction unit level was 582, which was higher than the cutoff of aspirin resistance (aspirin

reaction unit level ≥ 550). Aspirin was changed to cilostazol (P2Y12 reaction unit level 110 at the same time). On day 27, after confirming hemorrhagic infarction, cilostazol was stopped for 2 days until further computed tomography showed no progression of hemorrhagic infarction. On day 30, cilostazol was restarted at a lower dose and was increased to a full dose 5 days before carotid artery stenting (CAS). APTT, activated partial thromboplastin time; BID, twice a day; HI, hemorrhagic infarction; SID, once a day.

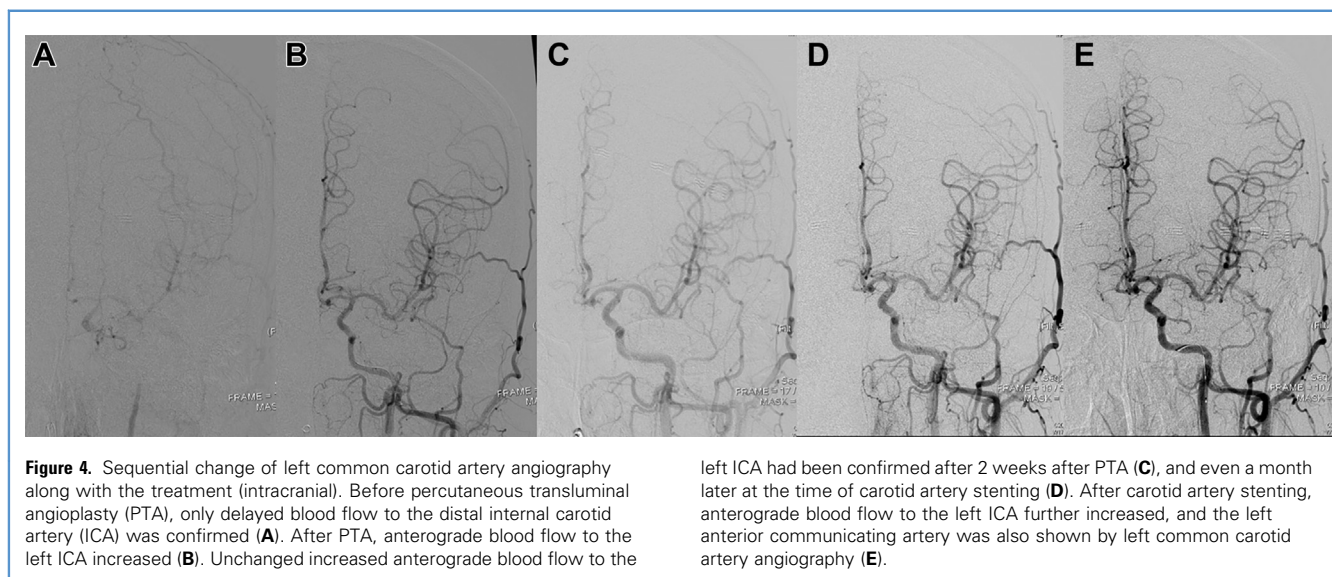


lumen and a collapsed distal portion induced by hypoperfusion.³ The treatment strategy for ICA pseudo-occlusion is controversial, and data from 2 major clinical trials (i.e., ECST [European Carotid Surgery Trial] and NASCET [North American Symptomatic Carotid Endarterectomy Trial]⁴) have shown that the rate of stroke among patients with pseudo-occlusion is not higher than that among

patients with high-grade ICA stenosis without narrowing of the distal ICA counterpart.⁵ The efficacy of surgical intervention for the clinical entity has also been reported.^{6,7} In the present case, we recommended that the patient undergo surgical intervention because cerebral angiography showed poor collateral circulation and it was considered that the hypoperfusion could

potentially worsen the cerebral ischemia of the patient in the future.

Staged angioplasty has been reported to be effective in preventing postoperative CHS in patients with severe carotid stenosis with impaired CBF.² A preoperative asymmetry index of CBF less than 80% and a cerebrovascular reserve (CVR) less than 20% on split-dose single-photon emission CT were reported to be risk



factors for CHS after CAS.¹ An adequate (not too much) increase of CBF by PTA increases not only CBF but also CVR. So CVR can be normalized at the time of CAS, and thus, a staged procedure may be beneficial for avoiding CHS. In the present case, we chose staged CAS as the strategy because the extent of ICA narrowing and decrease in CBF was high and there was a chance of the patient's developing CHS. Consequently, this patient did not develop CHS during his clinical course. During CAS, we found that the narrowing of the distal ICA had improved. This finding was unexpected and proved to be an advantage of staged angioplasty in patients with ICA pseudo-occlusion, because restricted dilatation of the distal ICA after CAS is reported to result in a higher risk of in-stent occlusion.³ As a consequence of staged angioplasty, we confirmed full dilatation of the distal ICA before stent placement and thus placed the stent more confidently without being concerned about in-stent occlusion.

According to the original report of staged angioplasty, the interval between the first and second stages of staged angioplasty is usually 2 weeks.² In the present case, a CT scan performed 13 days after PTA showed a relatively fresh hemorrhagic infarction, and we postponed the stent placement scheduled for the next day and also stopped cilostazol immediately and started lower-dose cilostazol instead 2

days later. With this adjustment, the hemorrhagic lesion did not worsen. However, it remains unknown whether this adjustment was truly effective in preventing the enlargement of the hemorrhagic infarction. Alternatively, if we had placed the stent before the development of the hemorrhagic infarction, such an adjustment might have been difficult because of the risk of in-stent stenosis or occlusion.

CONCLUSIONS

We treated a patient with progressing ICA pseudo-occlusion by means of a staged angioplasty. In the present case, besides preventing CHS, staged angioplasty allowed us to ensure full dilatation of the distal ICA before stent placement. Thus, we emphasize that staged angioplasty is advantageous in treating patients with ICA pseudo-occlusion because the extent of dilation of the distal ICA after PTA can be assessed before stent placement.

REFERENCES

1. Yoshimura S, Kitajima H, Enomoto Y, Yamada K, Iwama T. Staged angioplasty for carotid artery stenosis to prevent postoperative hyperperfusion. *Neurosurgery*. 2009;64:ONS122-ONS128 [discussion: ONS128-ONS129].
2. Uchida K, Yoshimura S, Shirakawa M, Shindo S, Egashira Y, Iwama T, et al. Experience of staged angioplasty to avoid hyperperfusion syndrome for carotid artery stenosis. *Neurol Med Chir (Tokyo)*. 2015;55:824-829.
3. Matsuda Y, Terada T, Okada H, Masuo O, Ohshima K, Tsuura M, et al. Angiographic characteristics of pseudo-occlusion of the internal carotid artery before and after stenting. *Neurosurgery*. 2016;79:832-838.
4. Barnett HJM, Taylor DW, Haynes RB, Sackett DL, Peerless SJ, Ferguson GG, et al. Beneficial effect of carotid endarterectomy in symptomatic patients with high-grade carotid stenosis. *New Engl J Med*. 1991;325:445-453.
5. Rothwell PM, Gutnikov SA, Warlow CP. Reanalysis of the final results of the European Carotid Surgery Trial. *Stroke*. 2003;34:514-523.
6. Terada T, Tsuura M, Matsumoto H, Masuo O, Tsumoto T, Yamaga H, et al. Endovascular treatment for pseudo-occlusion of the internal carotid artery. *Neurosurgery*. 2006;59:301-309 [discussion: 301-309].
7. Akkan K, Ilgit E, Onal B, Cindil E, Solak EP, Oncu F, et al. Endovascular treatment for near occlusion of the internal carotid artery: 30-day outcome and long-term follow-up [e-pub ahead of print]. *Clin Neuroradiol*. <https://doi.org/10.1007/s00062-016-0546-8>, accessed August 10, 2017.

Conflict of interest statement: The authors declare that the article content was composed in the absence of any commercial or financial relationships that could be construed as a potential conflict of interest.

Received 18 August 2017; accepted 17 October 2017

Citation: *World Neurosurg*. (2018) 109:409-412.

<https://doi.org/10.1016/j.wneu.2017.10.096>

Journal homepage: www.WORLDNEUROSURGERY.org

Available online: www.sciencedirect.com

1878-8750/\$ - see front matter © 2017 Elsevier Inc. All rights reserved.