


Accepted Manuscript

ZIKA vasculitis: A new cause of stroke in children?

Anne Landais, Audrey Césaire, Manuel Fernandez, Sébastien Breurec, Cécile Herrmann, Frédérique Delion, Philippe Desprez



PII: S0022-510X(17)34427-1
DOI: doi:[10.1016/j.jns.2017.10.045](https://doi.org/10.1016/j.jns.2017.10.045)
Reference: JNS 15640

To appear in: *Journal of the Neurological Sciences*

Received date: 12 June 2017
Revised date: 26 July 2017
Accepted date: 26 October 2017

Please cite this article as: Anne Landais, Audrey Césaire, Manuel Fernandez, Sébastien Breurec, Cécile Herrmann, Frédérique Delion, Philippe Desprez , ZIKA vasculitis: A new cause of stroke in children?. The address for the corresponding author was captured as affiliation for all authors. Please check if appropriate. *Jns*(2017), doi:[10.1016/j.jns.2017.10.045](https://doi.org/10.1016/j.jns.2017.10.045)

This is a PDF file of an unedited manuscript that has been accepted for publication. As a service to our customers we are providing this early version of the manuscript. The manuscript will undergo copyediting, typesetting, and review of the resulting proof before it is published in its final form. Please note that during the production process errors may be discovered which could affect the content, and all legal disclaimers that apply to the journal pertain.

ZIKA vasculitis: a new cause of stroke in children?

Anne Landais^a MD, Audrey Césaire^b MD, Manuel Fernandez^c MD, Sébastien Breurec^{def} MD, PhD, Cécile Herrmann^d MD, Frédérique Delion^b MD, Philippe Desprez^b MD.

Authors' institutional affiliations

- a. Neurology Department ,University Hospital of Pointe-à-Pitre, Guadeloupe, France ;
- b. Paediatrics Department , University Hospital of Pointe-à-Pitre, Guadeloupe, France;
- c. Radiology Department University Hospital of Pointe-à-Pitre, Guadeloupe, France;
- d. Laboratory of Microbiology, University Hospital of Pointe-à-Pitre, Guadeloupe, France ;
- e. Institut Pasteur de Guadeloupe, Pointe-à-Pitre, France ;
- f. Université des Antilles, Pointe-à-Pitre France

Correspondence to Dr Landais Anne Neurology Department University Hospital of Pointe-à-Pitre Route de Chauvel 97139 [landais.anne12@gmail.com]

Tel number : 0590891437 Fax number 0590891431

Funding Source : None

Abstract

Viral infectious vasculitis is a cause of stroke in children. Zika virus infection is often asymptomatic. Neurological complications have however been reported: Guillain-Barré, ADEM, meningoencephalitis, myelitis, microcephaly in the fetus of infected mothers. We discuss the case of a child presenting acute infection with ZIKV that was associated with a stroke. A 10-months-old boy without medical history presented after 2 days of fever and cutaneous rash, conjunctivitis on day 5, a right hemiparesis on day 6. Brain MRI found an ischemic stroke in the left superficial MCA territory with distal occlusion of left M1 portion of the MCA. Specific real-time reverse PCR detected Zika virus in serum. There are no known cases of cerebral infarction associated with Zika infection. However, cases of cerebral infarcts associated with dengue vasculitis have rarely been described. It has been recently showed that there is a tropism of the Zika virus for endothelial cells. This could be responsible for stroke, possibly particularly in young children.

Keywords

Zika virus infection, vasculitis, ischemic stroke, child

TEXT

To the Editor

Infectious vasculitis is a cause of stroke in children. Zika virus (ZIKV), transmitted to humans by the bite of Aedes mosquito, is asymptomatic in most infected individuals. Neurological complications have however been reported: Guillain-Barré, ADEM, meningoencephalitis, myelitis, microcephaly in the fetus of infected mothers.¹⁻³ We discuss the case of a child presenting acute infection with ZIKV that was associated with a stroke.

A 10-months-old boy without a notable medical history, specifically no history of congenital heart disease, metabolic or blood disease, sickle cell disease or recent trauma, first presented 2 days of fever and cutaneous rash.

On day 5, he presented a conjunctivitis.

On day 6 his family observed motor deficit of the right upper and lower limbs with impossibility to sit or to stand.

He was admitted to the pediatric emergency room on day 7. The examination showed right hemiparesis. The right plantar reflex could not be elicited.

Brain MRI (Magnetic resonance imaging) showed an acute cortical infarct in the left middle cerebral artery territory on diffusion- and T2 -weighted sequences with distal occlusion of left M1 portion of the MCA on TOF sequences.

The echo-Doppler of the supra-aortic trunks was normal. The transcranial Doppler noted a damped flow on the left MCA on the M1portion. Transthoracic echocardiography was normal. No arrhythmia was identified during heart monitoring for 3 days.

A lumbar puncture was performed. The leukocyte count was 8, the red cell count was 11 per cubic millimeter. Gram examination and cultures were negative. The protein level was 0.18g per liter, and glucose level was 3.40mmol/l.

PCR for varicella zoster, herpes simplex viruses, enterovirus, cytomegalovirus and Zika in his cerebrospinal fluid were negative.

Specific real-time reverse PCR((Eurobio, Les Ulis, France) detected Zika virus in serum but not in urine. ZIKV serologies performed, on serum a few months later showed positive IgG results (3, threshold of 1.1), negative IgM results, in favor an old infection.

The thrombophilia screening was negative, except for anti Beta 2 GP1 IgG antibodies weakly positive (30.9 USG).

Treatment with aspirin was started and physiotherapy was instituted.

A partial motor recovery was noted at 3 months follow-up consult, with a residual weakness of the right arm. Walking was acquired at 13 months.

1. Discussion

Viral (post) Infectious vasculitis represents a cause of child ischemic stroke. It is characterized by the presence of inflammatory lesions in the vascular wall caused either by a

direct invasion of endothelium by the virus or by an immune phenomenon. Cases of stroke secondary to infection with varicella, HIV, parvovirus B9 or CMV have been reported ...

Zika virus is an arthropod-borne arbovirus of the genus Flaviviridae that also includes dengue virus, yellow fever virus, West Nile virus.. It was first identified in Uganda in 1947. The current epidemic began in May 2015 in Brazil to largely spread throughout the South American continent and the Caribbean islands including the French West Indies island of Guadeloupe.

There are no known cases of cerebral infarction associated with Zika infection. However, cases of cerebral infarcts associated with dengue vasculitis have rarely been described.⁴⁻⁶ Zika is a blood-borne pathogen. There is a tropism of the Zika virus (ZIKV) for endothelial cells (EC): Liu et al have conducted immunostaining, plaque assay, and quantitative reverse transcription polymerase chain reaction of ZIKV RNA to evaluate the possible infection of endothelial cells by ZIKV; they showed in September 2016 that the ZIKV strains readily infect human umbilical vein endothelial cells and human endothelial cells derived from the aortic and coronary artery, as well as the saphenous vein. Infected endothelial cells release infectious progeny virus.⁷ Their data identified EC as a key cell type for ZIKV infection and support the view of hematogenous dissemination of ZIKV.

This case report of a child with a left-MCA territory infarct following ZIKV infection has not, to our knowledge been published before, so we believe it is worth reporting so that others can be aware and better data collected on whether this is common or unusual - as part of our expanding spectrum of understanding of neurological complications of ZIKV in different populations.

The combination of the clinical syndrome and the positive serum RT-PCR establish the diagnosis of ZIKAV infection. The clinical course and the MRI (including the DWI images)

establish the associated L-MCA territory acute infarct. No other obvious causes of stroke were found. The whole picture is suggestive maybe not of a causal relationship but at least of an association between ZIKV and the stroke.

While ZIKA virus continues to spread rapidly, its' clinical spectrum is still a matter of investigation. Its neurotropism has already been mentioned. A vascular tropism of the virus also exists, that could be responsible for stroke, possibly particularly in young children. Clinicians should be aware of the risks for patients returning from endemic areas. Zika virus infection should be considered in children patients with stroke living in or travelling from endemic areas. Further studies should clarify the spectrum and incidence of neurological associations.

Conflicts of interest :

None

References

1. Oehler E, Watrin L, Larre P, et al. Zika virus infection complicated by Guillain-Barre syndrome - case report, French Polynesia, December 2013. *Euro Surveill* 2014; 19.
2. Mécharles S, Herrmann C, Poullain P, Tran TH, Deschamps N, Mathon G, Landais A, Breurec S, Lannuzel A. *Lancet*. Acute myelitis due to Zika virus infection. *Lancet*. 2016 Apr 2;387(10026):1481.
3. Niemeyer B, Niemeyer R, Borges R, Marchiori E. Acute Disseminated Encephalomyelitis Following Zika Virus Infection. *Eur Neurol*. 2016 Nov 29;77(1-2):45-46.
4. Mathew S, Pandian JD. Stroke in patients with dengue. *Journal of Stroke and Cerebrovascular Diseases*, 2010; 19(3): 253-6
5. Nanda SK, Jayalakshmi S, Mohandas S. Pediatric ischemic stroke due to dengue vasculitis. *Pediatr Neurol*. 2014 Oct;51(4):570-2.
6. Chen WH. An unusual transitory increase of lupus anticoagulant in dengue virus infection complicated with cerebral ischaemia. *J Infect*. 2006 Mar;52(3):e87-91. Epub 2005 Jul 19.
7. Liu S, DeLalio LJ, Isakson BE, Wang TT. AXL-Mediated Productive Infection of Human Endothelial Cells by Zika Virus. *Circ Res*. 2016 Sep 20. pii: CIRCRESAHA.116.309866. [Epub ahead of print]

Legends for figures

Imaging of the brain

MRI with the use of Diffusion-weighted sequences (figure 1) and T2 weighed-sequences revealed hyperintensity in the superficial territory of the left middle cerebral artery. TOF sequences (figure 2) showed occlusion of the distal portion of the M1 branch of the left middle cerebral artery. The MRI was performed with the use of a 1.5T MRI unit.

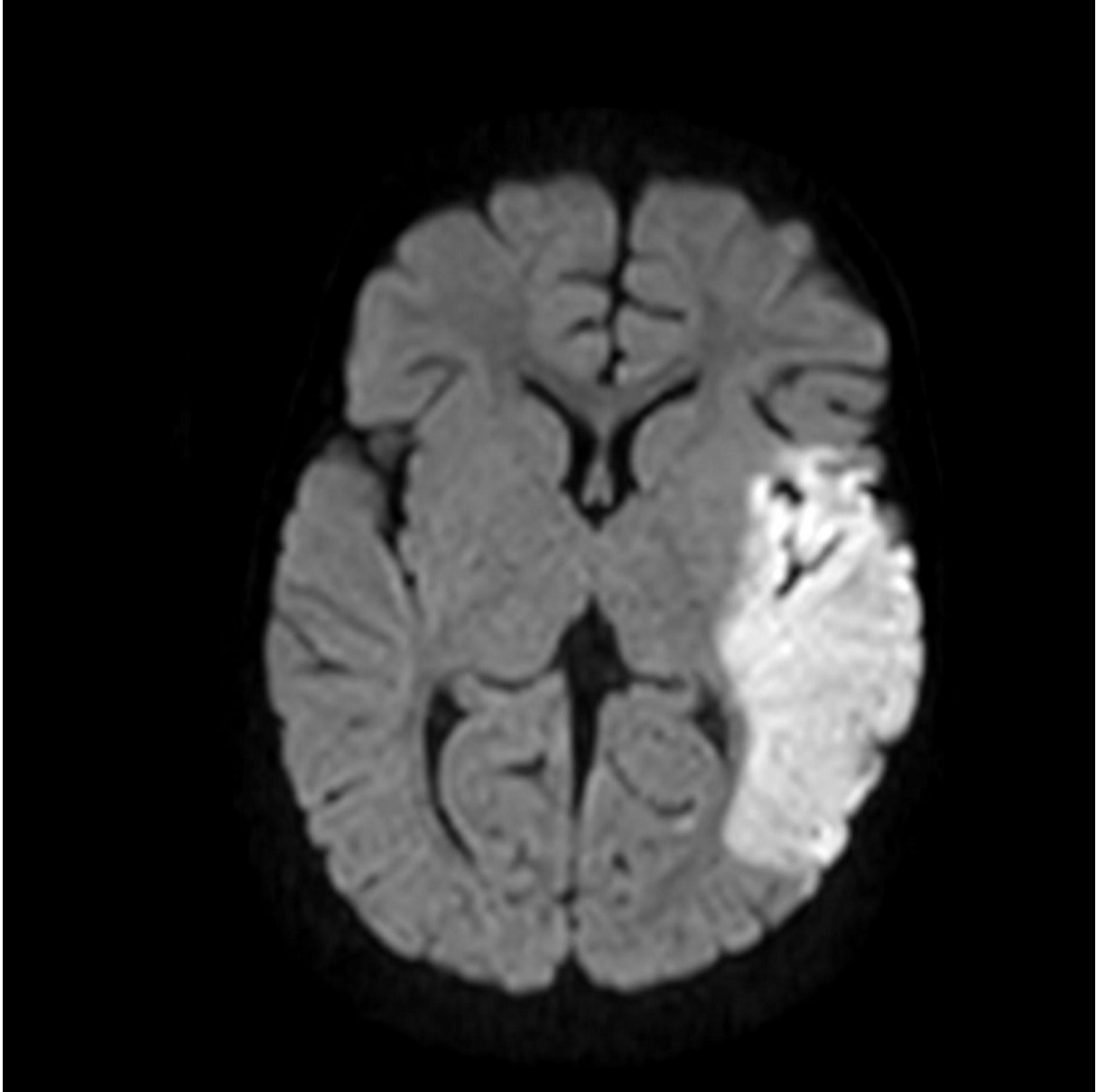


Figure 1

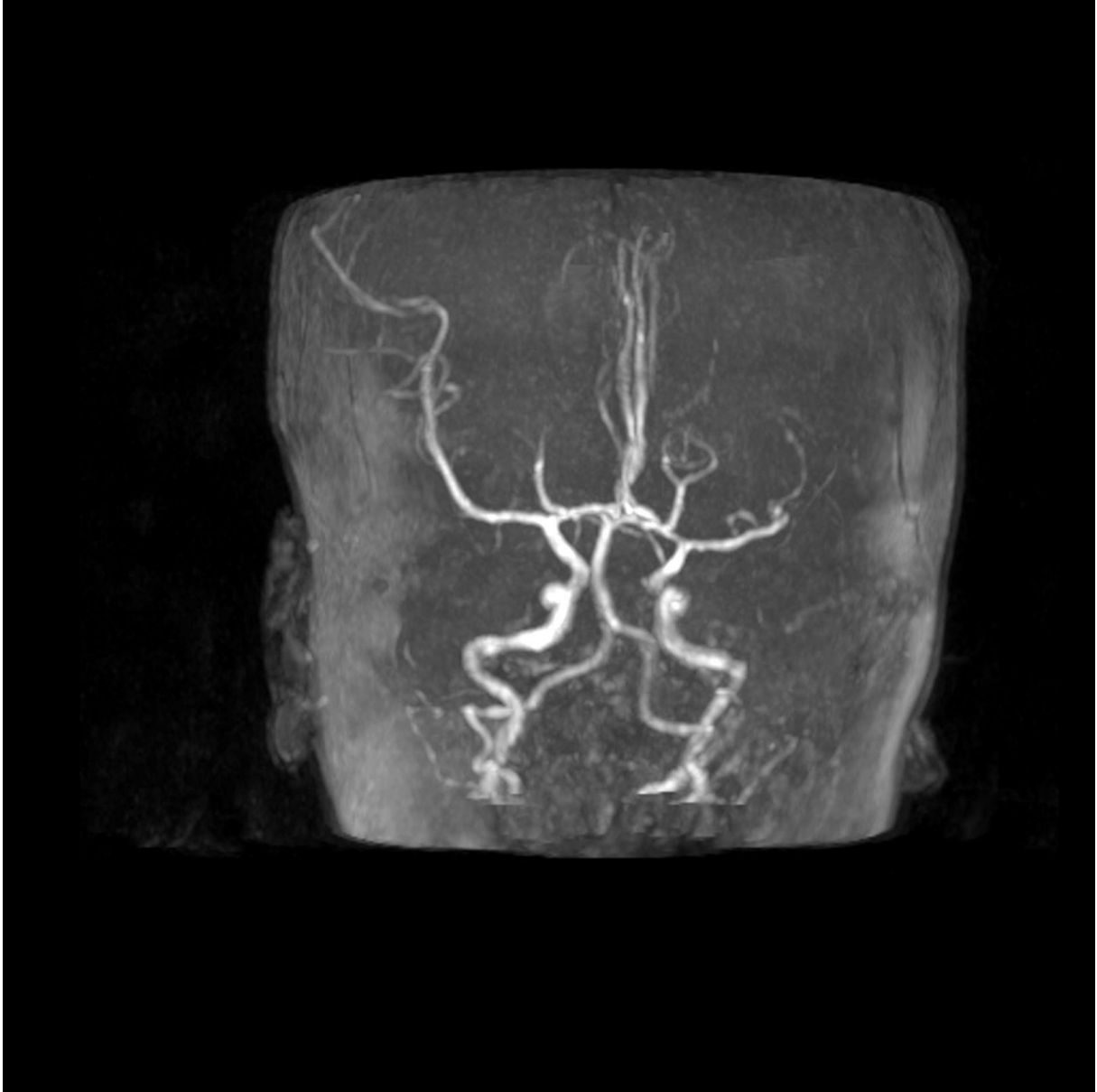


Figure 2