

**The Pediatric Infectious Disease Journal Publish Ahead of Print**

**DOI: 10.1097/INF.0000000000001832**

**Cerebral Infarction and Refractory Seizures in a Neonate with Suspected Zika Virus Infection**

Adam Raymond, BS, and Jonathan Jakus, MD, FACOG

Touro College of Medicine - New York, NY; and Montefiore-Nyack Hospital - Nyack, NY

**Address correspondence to:** Adam Raymond (attn.: Jonathan Jakus, MD), Department of Obstetrics and Gynecology, Montefiore-Nyack Hospital, 160 N. Midland Ave, Nyack, NY 10960, [adam.raymond3@student.touro.edu], 845-353-1441.

**Abbreviated Title:** Stroke and Seizures with Suspected Zika Virus Infection

**Running Head:** Stroke and Seizure with Zika Virus Infection

**Funding Source:** No external funding for this manuscript.

**Financial Disclosure:** All authors indicate they have no financial relationships relevant to this article to disclose.

**Conflict of Interest:** All authors indicate they have no potential conflicts of interest to disclose.

**Acknowledgments**

Thank you to Montefiore-Nyack Hospital, Clarkstown Pediatrics, and the following contributors for their contributions.

- Thomas McNamee, MD FACOG - Patient's obstetrician, case consultant
- Sharon Jakus, MD FACOG - Manuscript revision, case consultant
- Douglas Puder, MD FAAP - Pediatric case consultant
- Jeffrey Karasik, MD FAAP - Patient's PCP, case consultant
- Maja Djordjevic, MD FAAP - Pediatric case consultant

- Jen Lucia, PA-C - Patient's mother's post-partum care provider, case consultant
- Michael Petrella, MD - Pediatric case consultant
- Mahmoud Ibrahim, MD - Neonatal intensive care consultant
- Douglas Charney, MD - Placental pathology consultant

ACCEPTED

**Abstract**

Congenital Zika syndrome is a set of congenital anomalies associated with Zika virus infection during pregnancy. We present the unique case of a neonate born to a suspected Zika virus positive mother that developed an embolic stroke and medication resistant seizures. This report may impact the evolving definition of congenital Zika syndrome.

**Key words:** Zika, Virus, Stroke, Seizures, Congenital Zika Syndrome

ACCEPTED

## Introduction

There is a developing pattern of congenital manifestations of neonatal Zika virus infection collectively referred to as congenital Zika syndrome. The Zika flavivirus is highly neurotropic and has been implicated in a number of disease states in the neonatal central nervous system. These diseases include cerebral calcifications, ventriculomegaly, seizures, and microcephaly [1]. The full range of effects that Zika virus has on the developing fetus is unknown and this report may contribute to the growing list of outcomes associated with fetal Zika virus infection. This report aims to describe a novel case of middle cerebral artery occlusion with refractory seizures in a suspected Zika virus positive neonate and discuss possible mechanisms of embolus formation leading to stroke in this patient.

## Case

In September, 2016 a 22 year old primiparous woman at 39 weeks gestation presented to our hospital's emergency department 3 days before her estimated date of confinement complaining of diffuse abdominal pain. She was afebrile with stable vital signs, was having uterine contractions every two minutes, and was admitted to the Labor and Delivery service for spontaneous rupture of membranes.

Upon admission to the Labor and Delivery service the fetal heart rate was 145 bpm with the fetus in vertex position. Further history revealed travel to the Dominican Republic at 16 weeks gestation and Florida at 31 weeks gestation. At this point, she was presumed to be Zika virus positive. Serum analysis was negative for HIV, GBS, rubella, hepatitis B, *Chlamydia*, and gonorrhea, and RPR was nonreactive. Zika virus IgM antibody ELISA study was reactive and confirmed by RT-PCR. West Nile Equivalent Microspheres Immunofluorescent assay was also

reactive. Due to failure to progress, delivery via caesarean section was indicated and yielded one live male neonate.

At delivery, the newborn had one and five minute APGAR scores of 9 and 9. The patient's head circumference was 36.5 centimeters (88<sup>th</sup> percentile) and his weight was 3,392 grams. Cardiac auscultation revealed a grade 2 systolic ejection murmur at the left sternal border suggestive of an atrial septal defect.

On day one of life the patient developed focal tonic-clonic rhythmic movements of the right upper and lower extremities prompting admission to the neonatal intensive care unit with diagnoses of seizures and presumed sepsis. The patient experienced four more self-limiting episodes of tonic-clonic seizures of the right upper extremity and right lower extremity. Despite phenobarbital administration the patient continued to have right foot jerking movements. Adjustment of phenobarbital dosage and maintenance on 10.8 mg of phenobarbital by mouth every twelve hours was therapeutic. On the patient's eighth day of life, a repeat MRI was performed which showed an embolic stroke of the left operculum with hemorrhagic transformation in the area of the left precentral gyrus (Figure 2).

Cranial ultrasound, CBC, comprehensive metabolic panel, and ammonia value were within normal limits. Non-contrast CT scan demonstrated a hypodense wedge-shaped area with cortical and subcortical involvement of white matter (Figure 1). The scan was negative for hemorrhages and hydrocephalus. Magnetic resonance imaging confirmed the diagnosis of acute left posterior frontal lobe infarction secondary to occlusion of branches of the left middle cerebral artery (Figure 2). An abnormally developed corpus callosum was noted (Figure 2). Coagulation studies performed on the mother were all within normal limits with the exception of Protein S which was 59 U/dL [N: 60-145 U/dL]. A direct Coombs Test was negative.

Real-time RT-PCR analysis performed on tissue from the placenta, umbilical cord, and amniotic membrane detected Zika virus RNA in tissue from the maternal side of the placenta. Zika IgM ELISA testing of the patient's serum found no serologic evidence of recent Zika virus infection, however confirmatory testing by Zika virus real-time RT-PCR was indeterminate because test sensitivity was compromised. A microsphere immunofluorescence assay suggested the presence of flavivirus (e.g. Zika, Dengue, and West Nile virus) antibodies and a West Nile E polyvalent microsphere immunofluorescence assay was reactive. Although the patient was tested for dengue and Chikungunya virus antibodies, the patient's mother was not tested and her yellow fever vaccine status is unknown.

At the patient's two month follow up visit he was developing normally. Pediatric milestones were met appropriately, head circumference was within normal limits, and seizures were well-controlled.

## **Discussion**

CZS has several well-documented manifestations but the full spectrum of outcomes associated with prenatal Zika virus infection has not been established. The patient in this case report was exposed to risk factors associated with Zika virus infection and demonstrated several known manifestations of antenatal Zika infection. In utero, the patient traveled to two areas associated with a heightened risk of infection with Zika virus: Florida and the Dominican Republic. At birth the patient presented with dysgenesis of his corpus callosum and seizures, which have both previously been observed in patients with perinatal Zika virus infection. Embolic cerebral infarction, however, has not been reported as a potential outcome of perinatal Zika virus infection.

Studies suggest that viral infections in a mother or fetus elevate the risk of thrombus formation and cerebral infarction in newborns. Vertically transmitted viruses like VZV have been associated with stroke in newborns more so than other viruses. Fetal thrombotic vasculopathy (FTV) is implicated in the development of thromboemboli in various organs as well as embolic stroke in the newborn [2]. The mother's placenta showed subchorionic infarction and calcifications but there was no evidence of placental thrombosis, making vasculitis a more likely cause of embolus formation. If this patient's cerebral infarction was caused by a venous embolus, his atrial septal defect provides a potential route for the embolus to travel to the middle cerebral artery.

While Zika virus is implicated in the development of vasculitis in this patient there are other causes of perinatal vasculitis and ischemia such as maternal cocaine use that need to be ruled out. The patient's mother denied drug use during the course of the pregnancy. A drug toxicology screen was not performed. Coagulation studies were within normal limits in the mother with the exception of protein S which was slightly deficient (a common finding in pregnancy).

The patient's suboptimal response to phenobarbital administration provides evidence that the seizures were secondary to frontal lobe infarction [3]. During physical examination in the NICU the patient showed diminished deep tendon reflexes in all extremities, however this can likely be attributed to the effects of phenobarbital.

Despite an insufficient sample for Zika virus IgM ELISA testing of the patient's serum and a positive West Nile virus result, it is still likely that Zika virus is present and playing a central role in this patient's condition. The Center for Disease Control (CDC) currently states that in the event of a negative Zika IgM ELISA result the possibility of a false negative result

should be considered, especially if the patient was recently exposed to the virus, the patient's clinical presentation is consistent with Zika infection, and other causes of illness are ruled out [4]. All three of these criteria are met in this case. A false positive West Nile virus ELISA IgM result should also be considered because Zika and West Nile viruses are closely related flaviviruses, which elevates the chance of cross-reactivity and false positive results [4]. It is uncommon for West Nile virus to be vertically transmitted [5], however, placental cells have been shown to be specifically susceptible to Zika virus [6]. Even if the patient or his mother was infected with West Nile virus, pregnant mothers and neonates infected with West Nile virus show minimal differences in pregnancy and delivery related negative outcomes as compared to uninfected mothers [7].

Neonatal seizures, vasculitides and stroke [8] are characteristic of vertically transmitted infections (e.g. VZV) [8, 9] and dysgenesis of the corpus callosum is a specific finding in neonates who were infected with Zika virus in utero. Microcephaly is absent in this patient but Zika virus positivity does not necessarily manifest as a head circumference abnormality. ELISA testing is not specific enough to rely on as the sole factor for diagnosis of Zika virus and clinical factors must be relied upon for diagnosis.

Zika virus is known to be highly neurotropic and have an affinity for placental tissue [6] leading to vertical transmission from mother to fetus and neurologic sequelae. Based on clinical and laboratory findings it is likely that this patient was infected with Zika virus in utero and at the time of birth. Zika virus appears to have infiltrated the central nervous system and caused cerebral infarction in this newborn. Refractory seizures developed in the patient as either a direct neurotropic effect of Zika virus infection or as a secondary effect of cerebral infarction. More information is needed to assess the relative risk of embolus formation and cerebral infarction in



neonates that were infected with Zika virus in utero and determine the association of these outcomes with refractory seizures in these patients. Other potential mechanisms for the development of cerebral infarction in these patients should be investigated as well.

ACCEPTED

## References

1. de Fatima Vasco Aragao Maria, van der Linden Vanessa, Brainer-Lima Alessandra Mertens, et al. Clinical features and neuroimaging (CT and MRI) findings in presumed Zika virus related congenital infection and microcephaly: retrospective case series study BMJ 2016.
2. Elbers J, Viero S, MacGregor D, et al. Placental Pathology in Neonatal Stroke. PEDIATRICS. 127(3):e722-e729. 2011.
3. Kang SK, Markowitz GJ, Kim ST, et al. Age- and sex-dependent susceptibility to phenobarbital-resistant neonatal seizures: role of chloride co-transporters. Front. Cell. Neurosci.. 9. 2015.
4. Fact Sheet for Health Care Providers: Interpreting Zika MAC-ELISA Results. <http://cdc.gov/zika/pdfs/zika-mac-elisa-fact-sheet-for-hcp.pdf>. Published June 29, 2016.
5. Pregnancy & Breastfeeding. Centers for Disease Control and Prevention. <http://www.cdc.gov/westnile/faq/pregnancy.html>. Published March 31, 2015.
6. Jurado KA, Simoni MK, Tang Z, et al. Zika virus productively infects primary human placenta-specific macrophages. 1(13). 2016.
7. Pridjian G, Sirois PA, McRae S, et al. Prospective study of pregnancy and newborn outcomes in mothers with West Nile illness during pregnancy. Birth Defects Research Part A: Clinical and Molecular Teratology. 106(8):716-723. 2016.
8. Baskin HJ, Hedlund G. Neuroimaging of herpesvirus infections in children. Pediatr Radiol. 37(10):949-963. 2007.
9. Westerman MP, Green D, Gilman-Sachs A. Coagulation changes in individuals with sickle cell trait. American journal of hematology. 69(2):89-94. 2002.

**Figure Legends:**

Figure 1. CT scan without contrast of the patient's brain from base to vertex showing a wedge-shaped hypodense abnormality in the left frontal lobe.

Figure 2. MRI without contrast of the patient's brain showing acute left posterior frontal lobe infarct and dysgenesis of the corpus callosum.

ACCEPTED

Figure 1

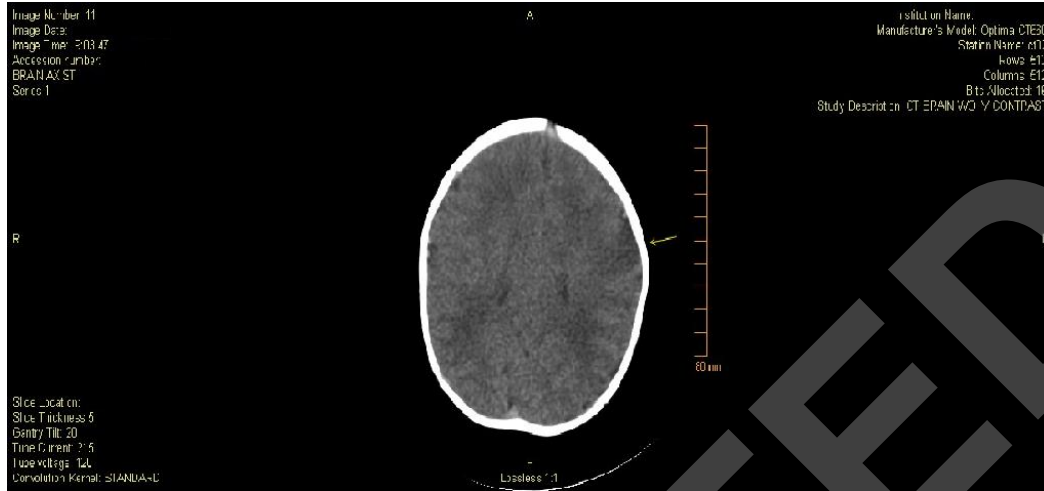


Figure 2

