



## King's Research Portal

DOI:

[10.1016/j.cortex.2017.10.006](https://doi.org/10.1016/j.cortex.2017.10.006)

*Document Version*

Peer reviewed version

[Link to publication record in King's Research Portal](#)

*Citation for published version (APA):*

Maffei, C., Capasso, R., Cazzoli, G., Colosimo, C., Dell'Acqua, F., Piludu, F., Catani, M., & Miceli, G. (2017). Pure word deafness following left temporal damage: Behavioral and neuroanatomical evidence from a new case. *Cortex*, 97, 240-254. <https://doi.org/10.1016/j.cortex.2017.10.006>

### **Citing this paper**

Please note that where the full-text provided on King's Research Portal is the Author Accepted Manuscript or Post-Print version this may differ from the final Published version. If citing, it is advised that you check and use the publisher's definitive version for pagination, volume/issue, and date of publication details. And where the final published version is provided on the Research Portal, if citing you are again advised to check the publisher's website for any subsequent corrections.

### **General rights**

Copyright and moral rights for the publications made accessible in the Research Portal are retained by the authors and/or other copyright owners and it is a condition of accessing publications that users recognize and abide by the legal requirements associated with these rights.

- Users may download and print one copy of any publication from the Research Portal for the purpose of private study or research.
- You may not further distribute the material or use it for any profit-making activity or commercial gain
- You may freely distribute the URL identifying the publication in the Research Portal

### **Take down policy**

If you believe that this document breaches copyright please contact [librarypure@kcl.ac.uk](mailto:librarypure@kcl.ac.uk) providing details, and we will remove access to the work immediately and investigate your claim.

# Accepted Manuscript

Pure word deafness following left temporal damage: behavioral and neuroanatomical evidence from a new case

Chiara Maffei, Rita Capasso, Giulia Cazzolli, Cesare Colosimo, Flavio Dell'Acqua, Francesca Piludu, Marco Catani, Gabriele Miceli



PII: S0010-9452(17)30340-4

DOI: [10.1016/j.cortex.2017.10.006](https://doi.org/10.1016/j.cortex.2017.10.006)

Reference: CORTEX 2155

To appear in: *Cortex*

Received Date: 5 September 2016

Revised Date: 4 August 2017

Accepted Date: 6 October 2017

Please cite this article as: Maffei C, Capasso R, Cazzolli G, Colosimo C, Dell'Acqua F, Piludu F, Catani M, Miceli G, Pure word deafness following left temporal damage: behavioral and neuroanatomical evidence from a new case, *CORTEX* (2017), doi: 10.1016/j.cortex.2017.10.006.

This is a PDF file of an unedited manuscript that has been accepted for publication. As a service to our customers we are providing this early version of the manuscript. The manuscript will undergo copyediting, typesetting, and review of the resulting proof before it is published in its final form. Please note that during the production process errors may be discovered which could affect the content, and all legal disclaimers that apply to the journal pertain.

**Pure word deafness following left temporal damage: behavioral and neuroanatomical evidence from a new case.**

Chiara Maffei<sup>1</sup>, Rita Capasso<sup>2</sup>, Giulia Cazzolli<sup>1</sup>, Cesare Colosimo<sup>3</sup>, Flavio Dell'Acqua<sup>4</sup>, Francesca Piludu<sup>3</sup>, Marco Catani<sup>5</sup>, and Gabriele Miceli<sup>1</sup>

<sup>1</sup>Center for Mind/Brain Sciences, University of Trento, Italy

<sup>2</sup>Brain Associates, Rome, Italy

<sup>3</sup>Dept. of Radiology, Catholic University, Largo A. Gemelli 8, 00168 Rome, Italy

<sup>3</sup>Natbrainlab, Department of Neuroimaging, Institute of Psychiatry, King's College London, De Crespigny Park, 8AF London, United Kingdom

<sup>4</sup>Natbrainlab, Department of Forensic and Neurodevelopmental Sciences, Institute of Psychiatry, King's College London, De Crespigny Park, 8AF London, United Kingdom

Please address correspondence to:

Gabriele Miceli, MD

Center for Mind/Brain Sciences, University of Trento

Corso Bettini 31

38068 Rovereto (TN) – Italy

[gabriele.miceli@unitn.it](mailto:gabriele.miceli@unitn.it)

## 1. Introduction

The term *word deafness* (Kusmaul, 1877) denotes the inability to process auditory speech input. The disorder is frequently observed in clinical aphasic syndromes, in which it is part of complex impairments that also affect reading comprehension, speech, and writing (e.g., Wernicke's aphasia). Much more rarely, selective difficulties processing auditory verbal stimuli are observed in the absence of significant damage to the processing of visual verbal stimuli. In these cases, the scope of the auditory input disorder varies. In few patients, it is restricted to speech input processing (Albert & Bear, 1974; Coslett, Brashear, & Heilman, 1984). The term *pure word deafness* (PWD) applies to these cases. More frequently, it extends to environmental noises, voices and music (e.g., Praamstra, Hagoort, Maassen, & Crul, 1991a; Semenza et al. 2012b; Slevc and Shell 2015). In these latter cases, the term *auditory agnosia* (or *generalized auditory agnosia*) is preferred (Engelien et al., 1995; Fujii et al., 1990; Godefroy et al., 1995; Motomura, Yamadori, Mori & Tamaru, 1986; Pan, Luo & Tsieh, 2004; Suh et al., 2012). (The same term, however, has been used to denote also selective damage to non-verbal auditory processing, as in Taniwaki, Tagawa, Sato & Iino, 2000).

In its literal meaning, the term *pure word deafness* denotes individuals with selective damage to speech input processing and intact reading comprehension, speech and writing. Such cases are very rare (e.g., Takahashi et al. 1992; Yaqub, Gascon, Al-Nosha, & Whitaker, 1988), and in most cases the label has been applied to subjects who, in addition to disproportionate damage to auditory (as opposed to visual) verbal input processing, and regardless of the scope of the auditory disorder, also suffer from

a variety of associated output deficits. In some patients, the impairment is very mild (e.g., LeGros Clark & Russell, 1938; Spreen, Benton & Fincham, 1965; Barraquer-Bordas, Peña-Casanova & Pons-Irazazabal, 1980; Miceli, 1982). More frequently, obvious but not severe damage to writing and speech is described (e.g., Mott, 1907; Marshall, Rappaport & Garcia-Buñuel, 1985; Praamstra, Hagoort, Massen & Crul, 1991; Miceli et al., 2008).<sup>1</sup>

Selective disorders of auditory processing have been reported mostly in adults following a stroke (for a review, see Simons & Lambon-Ralph, 1999) and occasionally in other neurological conditions, such as encephalitis (Arias et al., 1995; Goldstein, 1974), primary progressive aphasia (Otsuki, Soma, Sato, Homma, & Tsuji, 1998), multiple sclerosis (Tabira, Tsuji, Nagashima, Nakajima, & Kuroiwa, 1981), head trauma (Franklin, 1989), mitochondrial encephalomyopathy (Miceli et al., 2008), central pontine myelinolysis (Garde & Cowey, 2000) and Creutzfeldt-Jakob disease (Tobias, Mann, Bone, de Silva, & Ironside, 1994). It has also been documented in children with Landau-Kleffner disease (Baynes, Kegl, Brentari, Kussmaul, & Poizner, 1998) and brain tumor (Pan, Kuo, & Hsieh, 2004).

We report a case of pure word deafness (PWD) that followed a left temporal stroke. Our subject suffers from a selective impairment of auditory speech processing. Her recognition of environmental noises, voices and music is spared, and reading comprehension, speech and writing are preserved. We discuss our case in the context of previous reports of subjects with selective impairments of central auditory input processing, and discuss the neural and functional basis of her disorder.

---

<sup>1</sup> The terminology used to refer to selective disorders of auditory processing is inconsistent and controversial. Since a discussion of this issue is beyond the scope of this manuscript, the interested reader is referred to the reviews by Buchman, Garron, Trost-Cardamone, Wichter, & Schwartz (1986) and Simons & Lambon-Ralph (1999).

### 1.1. Selective disorders of auditory processing due to bilateral lesions

The most frequent cause of selective auditory processing disorders is bilateral damage to the temporal lobe (Geschwind, 1965; Poeppel, 2001; Simons & Ralph, 1999). In most patients, cortical damage is reported (Ishii, Ueda, Ohkoshi, Mizusawa, & Shoji, 1995; Kazui, Naritomi, Sawada, Inoue, & Okuda, 1990; Marshall, Rappaport, & Garcia-Bunuel, 1985; Praamstra, Hagoort, Maassen, & Crul, 1991a; Tanaka, Yamadori, & Mori, 1987). Lesion size in these cases ranges from extensive disruption of temporal, parietal and/or frontal regions (Dalla Pria, Spinnler, & Vallar, 1979; Ernest, Monroe, & Yarnell, 1977; Semenza et al., 2012), to circumscribed damage to primary auditory cortices (Déjérine & Sérioux, 1897; Miceli et al., 2008). In fewer instances, lesions are entirely subcortical and affect the medial geniculate nucleus (case 2 in Hayashi & Hayashi, 2007b; Motomura et al., 1986), the putamen (Taniwaki, Tagawa, Sato, & Iino, 2000), or midbrain structures (Hoistad & Hain; Jani, Lauren, Mark, & Brewer, 1991; Johkura, Matsumoto, Komiyama, Hasegawa, & Kuroiwa, 1998; Meyer, Kral, & Zentner, 1996; Musiek, Charette, Morse, & Baran, 2004; Pan et al., 2004; Vitte et al., 2002).

In bilateral cases, selective auditory processing disorders vary in severity, duration and scope, depending on lesion size and site. The most severely impaired patients present with so-called *cortical deafness*. In the face of normal or very mildly impaired peripheral hearing, these subjects do not react to auditory stimuli and behave as if they were deaf, even though they may erratically acknowledge sounds (e.g. Garde & Cowey, 2000; for a similar case and a review, see Semenza et al., 2012). Cortical deafness frequently constitutes the presenting symptom in cases with acute onset

(e.g., stroke), but is rarely permanent (Barraquer-Bordas, Peña-Casanova, & Pons-Irazazabal, 1980). More often it evolves, over a variable period of time, towards a less severe auditory processing impairment (e.g. Adams, Rosenberger, Winter, & Zollner, 1977; Michel, Peronnet, & Schott, 1980). In less severe forms, patients react to auditory stimuli but cannot process them accurately. In most cases verbal and non-verbal sounds are affected (e.g., Auerbach, Allard, Naeser, Alexander, & Albert, 1982; Ishii et al., 1995; Kazui et al., 1990; Marshall et al., 1985), but occasional reports of selective loss of speech input processing are on record (Albert & Bear, 1974; Dalla Pria et al., 1979; Jones & Dinolt, 1952; Kanshepolksy, Kelley, & Waggener, 1973; Miceli et al., 2008; Shivashankar, Shashikala, Nagaraja, Jayakumar, & Ratnavalli, 2001).

Since they typically suffer from extensive bilateral lesions, subjects with persistent selective auditory processing disorders usually also suffer from mild, associated language deficits (Ernest et al., 1977; Mott, 1907), even though language skills are reported as being essentially spared in occasional cases (Chocholle, Chedru, Botte, Chain, & Lhermitte, 1975; Le Gros Clark & Russell, 1938).

In bilateral cases, selective disorders of auditory input processing are ascribed to direct damage to both auditory cortices (Auerbach et al., 1982; Déjérine & Sérieux, 1897; Miceli et al., 2008). In the case of subcortical lesions, they are attributed to white matter damage preventing auditory input from reaching primary and/or associative auditory cortices and from there, language areas in the left hemisphere (Patient 2 in Hayashi & Hayashi, 2007a; Motomura et al., 1986; Taniwaki et al., 2000). The mechanisms underlying poor auditory input processing in the event of bilateral damage are schematically represented in Figure 1, left panel.

The observation that most cases occur following cortical damage to both hemispheres, and the bilateral organization of the ascending auditory projections (i.e. acoustic information from one ear is projected to both left- and right primary auditory cortices) have been considered as sufficiently significant for models of bilateral, domain-general organization of the primary auditory cortex.

These hypotheses assume that early acoustic input is processed by both auditory cortices, but that an early, domain-general computational asymmetry exists between the two hemispheres, either because the left hemisphere is better equipped for the processing of fast temporal changes and the right for spectral processing (Zatorre, Belin, & Penhune, 2002), or because it is better endowed for acoustic sampling over very short intervals, and the right for sampling over longer intervals (Hickok & Poeppel, 2007). On both accounts, the left hemisphere is better suited for verbal input processing because, as compared to non-verbal sounds, speech is characterized by faster spectral changes and requires sampling over shorter intervals. In support of the proposed asymmetrical processing, hemispheric differences were observed at the macroanatomical level (Penhune, Zatorre, MacDonald, & Evans, 1996; v. Economo & Horn, 1930); at the microanatomical level (Hutsler, 2003; Morosan et al., 2001; Seldon, 1981); and in neuroimaging studies (Warrier et al., 2009; Zatorre et al., 2002) – but, see Binder et al. (2000); Hickok & Poeppel (2007) for contrasting evidence.

Both the spectro-temporal and the differential sampling hypothesis assume that the levels of acoustic processing that feed into language-specific (phonological) representations are represented bilaterally. Therefore, they easily account for the behavioral features of bilateral PWD. They accommodate cases showing generalized disruption of auditory processing – when damage is severe, all sources of auditory input are affected (Adams et al., 1977; Earnest, Monroe, & Yarnell, 1977; Gazzaniga



et al., 1973; Lambert, Eustache, Lechevalier, Rossa, & Viader, 1989; Marshall et al., 1985; Miceli, 1982; Michel et al., 1980; Oppenheimer & Newcombe, 1978; Rosati et al., 1982), as well as the disproportionate impairment of speech processing observed in some instances – recognition of incoming speech requires flawless processing of fast temporal transitions, much more than needed for non-verbal sounds (Albert & Bear, 1974; Auerbach et al., 1982; Miceli et al., 2008; Tallal & Newcombe, 1978). They also accommodate the greater impairment of consonant vs vowel processing frequently observed in PWD, as vowels are longer and mostly differ spectrally (formant frequency), whereas consonants mostly differ temporally (formant transitions) (Young, 2008). However, because they assume a quantitative rather than a qualitative asymmetry, they also predict that PWD should occur following bilateral damage – unilateral PWD should be exceptional and not seriously compromise speech perception (Hickok & Poeppel, 2007; Poeppel, 2001).

### 1.2. Selective disorders of auditory processing that follow unilateral lesions: a disconnection syndrome?

Even though bilateral temporal damage is by far their most frequent cause, cortical acoustic disorders have also been described following a single, left temporal lesion (usually a stroke). Speech was selectively affected in some cases (Coslett, Brashear, & Heilman, 1984; Hayashi & Hayashi, 2007b; Hemphill & Stengel, 1940; Nagafuchi & Suzuki, 1993; Wang, Peach, Xu, Schneck, & Manry, 2000), whereas both speech and non-speech sounds were disrupted in others (e.g. Gazzaniga et al., 1973; Pasquier et al., 1991; Suh et al., 2012).

In accounting for unilateral cases, a disconnection mechanism has been proposed.

Lichtheim (1885) was first to attribute word deafness (Case IV) to the disconnection of Wernicke's area from both primary acoustic cortices, which would prevent acoustic input from reaching intact left-hemisphere regions critical for speech comprehension. A few years later, Liepmann published the first autopsy report of a patient in whom a left temporal hemorrhage interrupted both the left acoustic radiation and transcallosal connections from the right hemisphere (Liepman, 1898; Liepmann & Storch, 1902). In support of the disconnection mechanism, Goldstein (1974) reviewed seven cases with unilateral lesions at autopsy, originally described by van Gehuchten & Goris (1901); Liepmann (1912) – a subject initially seen by Wernicke; Pötzl (1919); Henschen (1920); Schuster & Taterka (1926); Henneberg (1926); Kleist (1934). The disconnection hypothesis was maintained also by Geschwind (1965) who, like Lichtheim and Liepmann, attributed PWD to strategically located temporal lesions that interrupt ipsilesional fibers connecting Heschl's gyrus to Wernicke's area in the posterior superior temporal gyrus, as well as transcallosal fibers connecting these areas to their right-hemisphere homologues. The behavioral effect of such unilateral lesions would be indistinguishable from that of bilateral temporal damage: in either case, acoustic input from both hemispheres would not reach language-specific areas in the left hemisphere. These mechanisms are schematized in Figure 1, right panel.

This account has been implicitly accepted in most unilateral cases. Since the early autopsy reports, however, evidence of anatomical disconnection has been scarce. In several patients, unilateral damage was assumed solely on the basis of clinical history (Albert & Bear, 1974; Gazzaniga et al., 1973; Saffran, Marin, & Yeni-Komshian, 1976a). These reports have no localizing value, as some cases whose clinical history was consistent with a single stroke turned out to have bilateral neuroradiological

damage (e.g., Hayashi & Hayashi, 2007b).

In the absence of clear anatomical data, in several unilateral cases the main argument for disconnection relies on behavioral evidence from dichotic listening tasks. In healthy volunteers, simultaneous presentation of competing verbal stimuli to both ears (syllables, short words/non-words or digits) typically results in more accurate reports of items delivered to the right, than to the left ear (Hugdahl et al., 2003; Kimura, 1961) – the so-called Right-Ear Advantage (REA). The effect has been attributed to the facts that: a. each temporal lobe receives acoustic input from both ears, but crossed acoustic pathways prevail over uncrossed pathways, and b. language-dominant structures prevail functionally over homologous right-hemisphere structures when speech stimuli must be processed. As a consequence, in a dichotic listening condition right-ear stimuli gain privileged access to left-hemisphere areas critical for speech processing (Kimura, 2011).

Consistent with the disconnection hypothesis, some unilateral cases showed a reversal of the REA (also called “left ear advantage” or “right ear suppression”) due to extinction of stimuli presented to the right ear (e.g., Albert & Bear, 1974; Saffran, Marin, & Yeni-Komshian, 1976; Stefanatos et al., 2005; Wolmetz, Poeppel & Rapp, 2010, personal communication). This performance profile was taken as behavioral evidence of damaged right ear-left hemisphere pathways and intact processing along pathways connecting the left ear to the right acoustic cortex. In other words, an index of functional disconnection was considered as evidence for anatomical disconnection, in the absence of conclusive anatomical evidence.

There is a problem with this view. On a strong version of disconnection, two regions A and B are “disconnected” when they are intact and damage is restricted to the fiber

pathways that link them. Under these circumstances, A and B maintain their functional specialization, except for the aspects that depend on their interconnections (Catani & Mesulam, 2008). In most unilateral PWD cases, however, damage involves cortical and subcortical left temporal regions (e.g., Wolmetz, Poeppel, & Rapp, 2010; Slevc, Martin, Hamilton, & Joanisse, 2011; Stefanatos, Gershkoff, & Madigan, 2005). In the presence of damage to grey and white matter, it is not clear if cortical damage, disconnection, or both cause PWD. In a subject with massive, left-lateralized damage to primary and associative acoustic cortices and Wernicke's area but spared transcallosal fibers, cortical damage was considered as the more likely cause of PWD (Slevc et al., 2011). Cases whose lesions are consistent with disconnection as defined earlier do exist, but are extremely rare (Liepmann & Storch, 1902; Schuster & Taterka, 1926; Takahashi et al., 1992). Furthermore, these latter reports do not provide data showing functional disconnection. Hence, speech processing in the left hemisphere via residual intra- and inter-hemispheric connections cannot be ruled out.

The present report focuses on a case of PWD caused by left temporal ischemia. Structural neuroimaging techniques were used to reconstruct brain damage, and to correlate the patient's behavior to the neural substrate. Damage to primary and associative acoustic cortices in the left temporal lobe was analyzed by an automatic parcellation technique (Destrieux et al., 2010) that yields measures of cortical thickness and gyral volume. Damage to intrahemispheric and transcallosal connections was studied by means of virtual dissection techniques based on diffusion tractography and spherical deconvolution models (Dell'Acqua et al., 2007). Detailed lesion reconstruction in unilateral PWD cases with evidence of functional disconnection can help establish if complete anatomical disconnection is needed to

cause the disorder, and evaluate the relative role of cortical damage and of damage to subcortical pathways in its pathogenesis. It can also contribute to the current debate on the role of the left and right hemisphere in auditory input processing.

## **2. Neuropsychological Case Report**

FO is a right-handed, native Italian, who suffered an ischemic stroke at age 38. She owns a degree in accounting (13 years of education), and holds a secretarial job in a public company. She never complained of acoustic disorders prior to her stroke. At onset, FO felt as if she “had gone deaf”, and only perceived “garbled speech”.

Relatives reported fluent but “paragrammatic” speech with neologisms and paraphasic (mostly phonemic) errors. In the following weeks, subjective hearing loss subsided, and FO complained only of mild right hypoacusis. Speech difficulties also cleared progressively. When she was assessed at 5 months post-onset, articulation was intact during spontaneous narrative but speech rate was reduced by long pauses. Errors consisted of infrequent, self-corrected phonemic paraphasias and paragrammatisms (Supplementary material).

At the time of this study (3 years post-onset), subjective hearing loss had receded, but FO still complained of problems with acoustic comprehension. She reported that after the stroke, she had started answering phone calls by putting the phone to her left ear (instead of the right ear), due to poor right-ear acoustic comprehension. She found telephone conversations difficult, and had severe problems understanding surnames and numbers. Speech comprehension benefited from lip reading.

Normal acoustic brainstem response (ABR), pure tone audiometry and structural MRI ruled out brainstem damage and peripheral hearing loss. On speech audiometry tests,

FO reported a lower percentage of correct words (40-60%), especially in the right ear, compared to healthy subjects (95-100%) (see also Supplementary materials).

### 2.1 Neuropsychological profile: Pure Word Deafness

Three years post-onset, FO completed a computerized battery for aphasia (Miceli, Laudanna, & Capasso, 2004). Tasks explored sub-lexical, lexical, semantic and grammatical skills. During acoustic tasks, FO was not allowed to see the examiner's mouth (for details on neuropsychological testing, see Supplementary material).

FO flawlessly and without hesitation discriminated (in a same-different task) and identified vowels (by matching a spoken CV syllable to one of five written alternatives, consisting of the same stop consonant + /a/, /e/, /i/, /o/, /u/). Further testing of vowel processing was therefore deemed superfluous. In a same-different task using minimal pairs of auditorily-presented natural CV syllables (stop + /a/), she fared very poorly (error rate: 26/60, or 41.7%; chance: 50%). Her performance was less impaired when one syllable of the pair was presented in writing (error rate: 11/60, or 18%; chance: 50%). In both tasks, 100 cognitively unimpaired participants never made more than 1/60 errors (1.7%). Less impaired performance in acoustic/visual syllable matching than in acoustic syllable discrimination is likely to result from the fact that in the former task the visually-presented syllable is shown 1 s before the acoustic syllable is pronounced, and remains in view until the participant responds, whereas in the latter the two syllables are presented consecutively, at a 1- sec interval.

All tasks that required acoustic word processing were impaired, while tasks of comparable difficulty and structure, but using written words or pictures, were spared.

FO flawlessly discriminated auditorily-presented action words from semantic,

phonologically unrelated foils (0/10 errors), but produced 3/10 errors when asked to distinguish the target from a phonemic foil (100 normal controls made no phonemic errors on this task).<sup>2</sup> No errors on semantic or orthographic foils occurred in the corresponding written task. Performance on sentence-picture matching was markedly poor for acoustic stimuli but normal for visual stimuli. Repetition and writing-to-dictation were severely impaired, both for words (error rate: 31.1% and 19.6%, respectively) and for nonwords (error rate: 69.4% and 60%, respectively). Regardless of task and stimulus type, errors were segmentally related to the target. By contrast, reading aloud and delayed copy were normal (no errors on word reading and on delayed copy of words and nonwords; 1/46 errors in nonword reading, or 2.2%).

Speech prosody and articulation were normal. Output was fluent and phonemic approximations were no longer present in spontaneous speech and picture description tasks. Connected narratives (daily life activities) were grammatically correct.

Compared to a sample of 20 cognitively unimpaired subjects (Miceli, Silveri, Romani & Caramazza, 1989), speech rate (86 words per minute) was mildly reduced, due to pauses, false starts and repairs, but Mean Length of Utterance (7.64 words) was in the low normal range. Correct subordinate sentences were produced in all narratives.

In spoken naming, FO made phonemic errors to 2/52 stimuli (3.8%), and produced 1/52 (1.9%) visual/semantic error. In written naming, she produced 2/44 (4.5%) spelling errors and 3/44 (6.8%) visual/semantic errors.

The ability to process environmental sounds, music and voices was tested in several tasks (Supplementary Material). FO, who reported no interest in music, was asked to

---

<sup>2</sup> FO did not make errors in a similar task using nouns. Since differences between nouns and verbs were not present in picture naming, narratives, and transcoding tasks, and since the two word/picture matching tasks were administered on separate days, the discrepancy is likely to reflect fluctuations in performance accuracy.

verify environmental sound/picture pairs, to name the musical instrument producing a note, to name famous melodies, to establish if two melodies were the same or different, and to name celebrities and singers from their voices. Each task was completed also by 20 healthy, age- and education-matched controls. Statistical comparisons were carried out according to Crawford & Howell (1998). In all tasks, FO's performance was indistinguishable from that of healthy volunteers (t values ranging between 1.694 and 0.436; p values ranging between .107 and .668).<sup>3</sup>

## 2.2 Dichotic Listening Test

Three CV syllables (/ba/, /da/, /ga/) recorded by a female speaker were used. Each stimulus consisted of two different syllables, presented simultaneously via headphones, one to each ear. Nine syllable pairs were prepared, each corresponding to a combination of different target syllables; each stimulus was presented 10 times, for a total of 90 randomized trials. FO was instructed to report the syllables she had just heard. Twenty cognitively unimpaired subjects (15 female; mean age: 25.6; SD=3.5; mean years of education: 16.9; SD=1.6) completed the same task. Healthy subjects showed a clear REA, as in previous studies (for review, see Hugdahl et al., 2003). By contrast, FO presented an almost complete right-ear suppression (Figure 2).

---

<sup>3</sup> We tried to carry out an in-depth analysis of auditory processing in our subject, but failed. FO refused to complete tasks using semisynthetic syllables, as they "did not sound human" (the same comment was offered by a few healthy volunteers). We administered a duality threshold task, in order to establish the minimum interval at which FO perceived two clicks (square waves) as separate. Intervals ranged from 2 to 6ms. FO almost always reported hearing one click. Results from 10 matched volunteers were heterogeneous – 6/10 showed the expected threshold (between 3-4ms), 2/10 always perceived two clicks, and 2/10 always perceived one click. Based on these results, it is not possible to exclude that FO would have perceived only one click even before her stroke (hence, to establish whether her post-stroke performance was normal or impaired relative to her premorbid skills).



Responses to right-ear and left-ear syllables were also considered separately. FO reported correctly fewer syllables presented to the right ear than controls ( $t=-7.567$   $p<0.001$ ), but a comparable number of left-ear syllables ( $t=0.773$   $p=0.449$ ). Excellent performance on stimuli presented to the left ear may have been facilitated by the fact that in this task FO was asked to choose within a small set of alternatives ( $n=3$ ).

### 3. Summary of Behavioral Tasks

FO presented with a very pure form of word deafness. Speech input processing was damaged, whereas reading, writing and speech were spared. Processing of environmental sounds, voices and music was within normal limits. As in previous unilateral PWD cases (Albert & Bear, 1974; Saffran et al., 1976a; Stefanatos et al., 2005; Wolmetz et al., personal communication), a marked REA reversal was observed in dichotic listening.

Even though REA reversal has been considered as its functional hallmark, anatomical disconnection has not been clearly demonstrated *in vivo* in subjects showing this behavioral profile. In some reports, no details on lesion site and extension are provided (Albert & Bear, 1974; Saffran et al., 1976). In others, cortical damage is documented, but information on white matter damage is not available (Stefanatos et al., 2005; Wolmetz et al., 2010).

In the present study, careful anatomical investigation of the lesion was carried out to clarify the potential role of cortical and subcortical damage in FO's PWD.

### 4. Neuroimaging Investigation

#### 4.1. MRI Data acquisition

Data were acquired on a 4T Bruker MedSpec scanner, using an eight channel receive head coil. For the structural analysis, T1-weighted data at a resolution of 1x1x1 mm were acquired. For tractography analyses, 30 diffusion-weighted volumes and 5 volumes with no diffusion gradient applied were acquired at a resolution of 2x2x2 mm using a twice-refocused 2D SE-EPI sequence. The diffusion weighting was equal to a b-value of 1000 s/mm<sup>2</sup>.

#### 4.2. T1-weighted images

T1-weighted images of the patient are shown in Figure 3. We expected left hemisphere regions involved in acoustic input processing to be damaged (as very schematically represented in Figure 1, right panel, Cortical damage). In agreement with this prediction, atrophy and abnormal cortical and subcortical intensity were evident in the left superior temporal gyrus, the superior temporal sulcus, the posterior insula and lower part of the posterior supramarginal gyrus and angular gyrus. The damage affected only limited parts of the regions listed above. For example, abnormalities of Heschl's gyrus were evident for the lateral portion whereas the medial one was relatively intact. The polar temporal cortex, most of the middle temporal gyrus and medial geniculate nuclei were intact. No lesions were found in the right hemisphere.

To obtain a quantitative estimate of cortical damage, T1 data were processed in Freesurfer (<http://surfer.nmr.mgh.harvard.edu/>) version 6.0.0. The brain was registered to Talaraich space (Lancaster et al., 2000), skull-stripped, and an estimate of the gray/white boundary was constructed. Statistical maps were generated using

FreeSurfer Group Descriptor (FSGD) File Format (Version 1). Results were obtained with an FWHM (full-width/half max) of 10 mm. The cortical surfaces of the left and right hemisphere were analyzed separately. The maps generated by this analysis show the distribution of  $p$  values for pairwise comparisons between patient and healthy controls. The cerebral cortex was then parcellated into 33 cortical regions per hemisphere (Desikan-Killiany atlas), labels for gyral regions of interest were created, and mean cortical thickness calculated for each. Data obtained for FO were compared to those of 35 healthy age- and gender-matched controls.

The results of the quantitative cortical morphometry analysis in FO are shown in Figure 4. Gyri on the left show diffuse cortical thinning when compared to the corresponding structures on the right (Figure 4a). The automatic segmentation of the cortical thickness was particularly difficult for those left-hemisphere regions where a clear boundary between cortical and white matter was not distinguishable due to the lesion. Since this limitation may lead to inaccurately estimate left cortical thickness, absolute values of gyral volume in our subject are also reported, as the two measures together reflect more precisely the extent of damage. Results confirmed the reduction of cortical thickness and gyral volume in FO's left hemisphere, due to post-stroke atrophy (Table 1). Reduced thickness and volume were observed in the lateral and superior aspects of the left superior temporal gyrus, including the planum polare and planum temporale, the transverse temporal (Heschl's) gyrus, and the posterior insula. A statistical map of the comparison of cortical thickness in FO and controls (Figure 4b) shows that the cortical thinning in the left hemisphere was unevenly distributed along the superior temporal gyrus (mostly in the lateral portion anterior to the Heschl's gyrus and planum polare) and in the posterior insula, extending to portions of the angular and supramarginal gyri. In a context of diffuse thinning, a

circumscribed area of increased cortical thickness was visible in the posterior portion of the middle temporal gyrus.<sup>4</sup> Patches of cortical thinning were present on the longitudinal frontal gyri and inferior temporal gyrus.

### 4.3 Diffusion Tractography

Data were corrected for eddy current distortion and subject motion using ExploreDTI (<http://www.exploredti.com>) (Leemans & Jones, 2009). Diffusion-weighted data were then processed using spherical deconvolution (SD) (Dell'Acqua et al., 2007; Dell'Acqua et al., 2010), a multi-fiber based model, whose multi-peak shaped function provides information on the number of distinct fiber directions, their orientation, and their weight in each voxel. This permits the reconstruction of multiple fiber components within a single voxel, allowing to partially resolve fiber crossing, which has been previously demonstrated to represent a problem for the reconstruction of the acoustic radiation (Behrens, Berg, Jbabdi, Rushworth, & Woolrich, 2007). Whole brain SD tractography was performed in StarTrack (Dell'Acqua et al., 2010), selecting every brain voxel with at least one fiber orientation as a seed voxel. A modified version of the FACT (Fiber Assignment by Continuous Tracking) algorithm was used (Dell'Acqua, Simmons, Williams, & Catani, 2012). Streamlines were halted when a voxel without fiber orientation was reached or when the curvature between two steps exceeded a threshold of 60°.

Virtual dissections of the white matter tracts were performed in TrackVis (<http://trackvis.org>) using a multiple-ROI approach (Catani & Thiebaut de Schotten, 2008).

---

<sup>4</sup> The meaning of this observation is uncertain. It could correspond to an absolute increase of cortical thickness in this area, or to a less marked thinning in comparison to neighboring areas.

Figure 5 shows the tractography reconstruction performed in FO. Dissection of the *thalamic-temporal radiations* was performed using a large sphere placed around the medial geniculate nucleus (MGN) and a second ROI drawn by hand on a coronal slice in the posterior temporal lobe. The *acoustic radiations* were separated from the other thalamic-temporal radiations using a third ROI located in the Heschl's gyrus. In the right hemisphere an additional sphere placed along the course of the acoustic radiations was necessary to visualize the entire course of its streamlines. *Inter-temporal transcallosal tracts* were dissected using coronal ROIs placed in the posterior temporal lobe of each hemisphere. The streamlines of the *temporal longitudinal fasciculus*, a tract connecting different regions of the superior and middle temporal gyri were reconstructed using one ROI placed in the white matter of each temporal lobe (Forkel and Catani, in press). The *thalamic-occipital radiations*, which include the optic radiations and the splenium, were also reconstructed for comparison with the temporal tracts (Catani, Jones, Donato, & Ffytche, 2003; Catani & Thiebaut de Schotten, 2008; Menjot De Champfleury et al., 2013; Wang et al., 2012). Fibers passing through these ROIs were reconstructed in three dimensions and visualized using stream-tubes. Volume and hindrance modulated orientational anisotropy (HMOA) (Dell'Acqua et al., 2013) were extracted for each tract to compare hemispheric asymmetry as an indication of the extent of white matter damage in the left hemisphere.

As in the case of the cortical involvement, we expected to find damage to the white matter pathways that connect cortical areas involved in speech input processing (very schematically represented in Figure 1, right panel, under Subcortical damage). Intrahemispheric connections should be affected (the acoustic radiation joining Heschl's gyrus to the posterior Superior Temporal Gyrus, and the longitudinal

temporal fasciculus that connects the portions of superior temporal gyrus), as well as the left-hemisphere terminations of transcallosal pathways (the fiber tracts reaching the primary and associative acoustic cortices in the left superior temporal gyrus from the corresponding right-hemisphere cortices – note that in our case subcortical damage would not be as deeply located as in Figure 1, but would correspond to the subcortical extension of cortical damage). Figure 5 shows the results for each individual tract in both hemispheres. The left thalamic-temporal radiations showed reduced volume (2.777ml) and HMOA (0.0874) compared to the right hemisphere (volume 6.544ml; HMOA 0.0934). Within the thalamo-temporal connections, projections from the medial geniculate to the Heschl's gyrus (acoustic radiations) were dissected as a single bundle in the left hemisphere and as a two-segment bundle in the right hemisphere. This difference may be related to degeneration of callosal fibres in the left hemisphere and to the consequently facilitated tracking of the acoustic pathways through regions of crossing. Despite this difference, which may lead to an underestimation of the volume and HMOA in the right hemisphere, clear asymmetry in favour of the right hemisphere was evident (Figure 5, upper row). In comparison, tract specific measurements of the thalamic-occipital radiations were symmetrical for both volume (left 13.4ml; right 13.1ml) and HMOA (left 0.1328; right 0.1325).

Asymmetry was also noticed for the *temporal longitudinal fasciculus*, especially for the segment running along the superior temporal gyrus which showed reduced volume (1.384ml) and HMOA (0.0694) compared to its right homologue (3.016ml; HMOA 0.0764). Smaller differences were noticed for the streamlines of the temporal longitudinal fasciculus running through the middle temporal gyrus (volume left 7.088 vs volume right 8.064; HMOA left 0.0865 vs HMOA right 0.08796). Temporal

connections of the corpus callosum were also asymmetrically distributed with significantly fewer streamlines reaching the left temporal lobe.

## 5. Discussion

In this case report we present detailed MRI analyses of a unilateral stroke lesion associated with PWD. Damage was documented for both cortical (mainly to Heschl's and superior temporal gyrus) and white matter (thalamic-temporal projections including acoustic radiations, callosal connections and intralobar temporal tracts) temporal regions of a network dedicated to speech sound processing. White matter damage was only partial and therefore incompatible with the pure disconnection mechanism historically proposed to explain PWD in unilateral lesion. Similarly, cortical damage spared significant portions of Heschl's and superior temporal gyrus.

The fact that in most cases Pure Word Deafness (PWD) is caused by bilateral temporal lesions has been considered as crucial evidence in favor of the hypothesis that speech sounds are bilaterally processed in the human brain. However, there is also accumulating evidence of permanent PWD in patients with unilateral, left temporal damage. In these latter cases, PWD is often considered as a disconnection syndrome (Geschwind, 1965). On this view, a strategically located cortico-subcortical (or, entirely subcortical) damage would sever intrahemispheric connections between primary and associative acoustic areas, as well as transcallosal connections between primary acoustic areas, and between so-called Wernicke's area and its right-hemisphere homologue (Figure 1). Speech processing would be disrupted by the disconnection of Wernicke's area from regions involved in earlier, lower-level language processes in both hemispheres.

We reported on cortical damage and impaired white matter connectivity in a subject who developed PWD following a left temporal lesion. In FO, reading, writing and speech were normal, and acoustic processing of non-verbal input was spared.

#### 6.1. Is disconnection the cause of FO's pure word deafness?

From the behavioral standpoint, the marked REA reversal in dichotic listening is consistent with functional disconnection. From the anatomical perspective, however, an account based entirely on disconnection is not tenable (at least, not in the strong version advocated by Mesulam & Catani, 2008), as damage to both cortical and subcortical structures was incomplete. Damage to the left superior temporal gyrus affected large portions of Heschl's gyrus and extended to the superior portions of the supramarginal and angular gyrus, and to the posterior portions of the insula. However, it was incomplete. Part of Heschl's gyrus was spared and damage to the posterior portion of the superior temporal gyrus was obvious but uneven. As for white matter structures, the vascular lesion partially disrupted intrahemispheric white matter pathways connecting primary and associative auditory areas in the superior temporal gyrus, and transcallosal fibers connecting lesioned left-hemisphere regions with intact, homologous right-hemisphere regions.

In FO, then, functional disconnection may be due to combined cortical and subcortical damage, in the absence of a complete anatomical disconnection. Damage to the left primary auditory cortex and partial disconnection of the latter from the left posterior superior temporal gyrus would disrupt processing of verbal stimuli in the left hemisphere (hence, the REA reversal). Partial sparing of the left posterior superior temporal gyrus and of its transcallosal connections with homologous right-



hemisphere regions could still allow speech sounds analyzed in the right hemisphere to reach residual functional areas in left auditory associative cortices. Consistent with this possibility, in the dichotic listening task FO identified the same number of syllables presented to the left ear as controls. In everyday conversation, auditory processing in this patient could be affected by tissue damage in the posterior superior temporal gyrus per se, or by the fact that this gyrus receives input from the right hemisphere in an abnormal time frame. The same or a similar mechanism may be at work in most unilateral PWD cases with unilateral left temporal lesion.

This does not mean that a *bona fide* anatomical disconnection cannot cause unilateral PWD. To yield PWD, a disconnection as defined by Catani & Mesulam (2008) should result from strictly subcortical damage to the left hemisphere<sup>5</sup>. The lesion should spare cortical structures, while at the same time disrupting on one hand the left acoustic radiation or the connections between the primary auditory cortex and the posterior superior temporal gyrus, and on the other the transcallosal fibers that connect those cortices with their right hemisphere homologues. Unfortunately, reports potentially consistent with this account are exceedingly rare (Liepmann & Storch, 1902; Schuster & Taterka, 1926; Takahashi et al., 1992), and do not provide sufficient information on anatomical and functional disconnection.

## 6.2. Unilateral PWD and asymmetric processing of auditory input

Current theories assume that acoustic stimuli are relayed symmetrically to auditory cortices (for review, Brugge et al., 2103) where, at an early stage already, they are

---

<sup>5</sup> Different considerations may apply to lesions affecting neural structures further downstream in the auditory pathways, such as the midbrain or the medial geniculate nucleus. In this study, only damage at the hemispheric level is considered.

computed in parallel but asymmetrically. On the “spectro-temporal model of lateralization” (Zatorre et al., 2002) and the “asymmetrical sampling in time” hypothesis (Hickok & Poeppel, 2007a; Poeppel, Emmorey, Hickok, & Pytkänen, 2012; Poeppel, 2001, 2003) the processing abilities of the left hemisphere (analysis of fast temporal changes over very short time windows) are better suited for speech analysis than those of the right hemisphere (spectral analysis over long time windows). These hypotheses successfully predict generalized auditory processing deficits (Godefroy et al., 1995; Ishii et al., 1995; Kazui et al., 1990; Lambert et al., 1989; Marshall et al., 1985; Miceli, 1982; Motomura et al., 1986; Oppenheimer & Newcombe, 1978; Praamstra et al., 1991; Tanaka et al., 1987) and selective speech input disorders (Auerbach et al., 1982; Miceli et al., 2008; Yaqub, Gascon, Al-Nosha, & Whitaker, 1988) following bitemporal lesions. They also accommodate greater difficulties with stop consonants than with vowels and other consonants, reported in PWD (Miceli, 1982; Miceli et al., 2008; Saffran et al., 1976b; Wang et al., 2000).

On both views, though, left/right asymmetries are domain-general and quantitative, rather than language-specific and qualitative. Therefore, bilateral damage is deemed necessary to yield PWD. Unilateral cases are thought of as exceptions (Poeppel, 2001; Hickok & Poeppel, 2007), as in unilateral lesions the right hemisphere should still guarantee accurate processing of speech sounds. Many reports of unilateral PWD (see Introduction) militate against this view. Our patient is a case in point. On both the Hickok & Poeppel (2007) and the Zatorre et al. (2002) account, the lesion profile documented in FO (Heschl’s gyrus was partially spared in the left hemisphere and intact in the right) predicts essentially normal speech input processing. That even partial damage to the left Heschl’s gyrus yielded a permanent PWD argues for a

specific role of the left temporal lobe in speech processing.<sup>6</sup>

The fact that PWD can result from unilateral lesions could be reconciled with the hypothesis of quantitative and domain-independent hemispheric differences by assuming that speech processing is disrupted at a time-dependent prephonemic, language non-specific stage in some cases, and at a time-independent phonemic, language-specific stage in others (Auerbach et al., 1982). The former deficit would yield generalized input processing deficits; the latter, a selective disruption of speech input. Another way to reconcile the same contrast is by assuming that the degree of right-left asymmetry varies across subjects. Unilateral damage would yield PWD only when the asymmetry is extreme (i.e., in subjects in whom the analysis of spectral change and/or the rapid sampling in time are fully left-lateralized). This possibility receives some support from rare cases where auditory processing disorders followed right temporal lesions, affecting only environmental sounds (Fujii et al., 1990; Spreen, Benton, & Fincham, 1965) or music (in a crossed-aphasic subject - Roberts, Sandercock, & Ghadiali, 1987).

FO does not allow strong arguments on these issues. At the behavioral level, she shows a stark dissociation between performance on speech tasks (always impaired) and on non-speech tasks (always indistinguishable from that of healthy volunteers). Even though fine-grained tests tapping the ability to process subtle auditory cues in the context of synthetic speech and non-speech sounds, as in Stefanatos et al. (2005)

---

<sup>6</sup> Note that in unilateral PWD, a complete anatomical disconnection mechanism would be compatible with model that assume a bilateral organization of speech sound processing. A left temporal damage completely interrupting intrahemispheric and transcallosal connections to Wernicke's area would prevent low-level auditory input from both the right and the left hemisphere from reaching the left hemisphere regions specialized for word comprehension. However, such a mechanism has never been demonstrated, and was clearly ruled out in our subject.

or Slevc et al. (2011), could not be administered, evidence from FO adds to that of other published cases showing that PWD can result from left temporal lobe lesions. Even though its underlying cause(s) remains elusive, these reports are too numerous to be considered merely as exceptions to a 'bilateral damage' rule. Together with studies showing the effect of left (but not right) hemisphere damage on phoneme discrimination/identification tasks (Blumstein, Cooper, Zurif, & Caramazza, 1977; Caplan, Gow, & Makris, 1995; Miceli, Caltagirone, Gainotti, & Payer-Rigo, 1978) they suggest that, whatever the elementary basis of computational asymmetries, speech is processed asymmetrically in the temporal lobes, and left hemisphere damage is key in the disorders of speech input processing.

### 6.3. The recovery of speech output deficits in FO

Improvement from severe, widespread language deficits to milder, selective disorders of auditory processing is not uncommon in PWD (e.g., Motomura et al., 1986; Slevc et al., 2011). Recovery was obvious also in FO. At 3 years post-onset, language disorders had evolved from severe speech production and comprehension deficits into a very pure form of PWD. In this context, the absence of phonemic errors in narrative speech is particularly interesting. FO produced such errors in spontaneous speech and repetition, in the acute/subacute stage. At 3 years post-onset, though, phonemic errors occurred in repetition, but not in connected speech. A similar profile was reported in Hemphill & Stengel's controversial case (1940), and in the subjects described by Yaqub et al., (1988) and Szirmai, Falsang and Csüri (2003). In all these cases, phonologically related errors persisted in a task that requires auditory processing (repetition), but were missing in a purely output task (spontaneous speech). This

observation favors the hypothesis that input and output phonological processes are at least partly distinct.

In FO, behavioral changes co-occurred with extensive modifications of cortical thickness and connectivity in the left hemisphere. In the face of a very circumscribed ischemia, neuroimaging showed cortical and subcortical damage affecting large-scale neural networks, and extending well beyond the borders of direct ischemic damage. From the behavioral standpoint, she showed a REA reversal in dichotic listening and reported the same number of left-ear syllables as controls and, anecdotally, after her stroke she started using the left ear as the preferred source of acoustic input. These observations are compatible with the possibility that in our subject the right hemisphere plays a crucial role in post-stroke speech processing.

An involvement of right-hemisphere mechanisms in recovery is consistent with data from two additional cases. In a PET study (Engelien et al., 1995) a patient with PWD showed bilateral activation in sound categorization tasks that activated only left hemisphere regions in healthy controls. In case NL (Slevc et al., 2011), acute Wernicke's aphasia had evolved into PWD with normal written comprehension and essentially normal speech, reading and writing at 3 years post-onset. In this subject, processing of non-speech stimuli improved following a remediation program, and fMRI showed atypical right supramarginal gyrus activation in auditory language tasks (Martin, Hamilton, & Slevc, 2010). Evidence from aphasia also suggests a role for the right hemisphere. In a recent study, better recovery was observed in subjects with strongly represented right AF (Forkel et al., 2014).

Even though her condition improved, however, FO still suffers from auditory processing disorders. In everyday life, she reports continuing difficulty with unfamiliar words and surnames, and exploits compensatory strategies (e.g. lip

reading) to facilitate speech comprehension. In formal testing, she is not able to discriminate words differing for subtle phonological contrasts, and fares significantly more poorly when repeating non-words (25/36 incorrect, 69.4%) than words (14/45 incorrect, 31.1%). Overall, results demonstrate that the right hemisphere, even though it may contribute to recovery from language disorders, cannot guarantee proficient speech input processing when critical left hemisphere regions are damaged.

## 7. Conclusions

FO developed PWD following a circumscribed left temporal lesion. Right-ear suppression in a dichotic listening task is consistent with functional disconnection, but only incomplete anatomical disconnection was documented. Neuroimaging data showed partial damage to left temporal cortex and to transcallosal inter-temporal connections. Functional disconnection in this patient could therefore result from a combination of cortical and white matter damage. FO's data confirm that PWD can result from left unilateral temporal damage, and point to an asymmetric functional role of the primary auditory cortex. At 3 years post-onset, language difficulties had essentially recovered, except for speech input processing. This suggests that the left posterior superior temporal gyrus is necessary for adequate processing of speech sounds, even though the right hemisphere may support auditory input processing and compensate for other language impairments. In the chronic stage, a very circumscribed left hemisphere lesion resulted in reduced cortical thickness in large-scale neural networks in the damaged left hemisphere.

**ACKNOWLEDGMENTS**

Funding was provided by PAT (Provincia Autonoma di Trento) and Fondazione CaRiTRO (Cassa di Risparmio di Trento e Rovereto) (grant number 000040101985 to GM). The authors wish to thank Emanuela Rota for referring FO, and prof. Silvano Prosser for performing the ERP study.

## References

- Adams, A. E., Rosenberger, K., Winter, H., & Zollner, C. H. (1977). A case of cortical deafness. *Arch Psychiatr Nervenkr*, 224, 213–220.
- Albert, M. L., & Bear, D. (1974). Time to understand. A case study of word deafness with reference to the role of time in auditory comprehension. *Brain : A Journal of Neurology*, 97(2), 373–84.
- Arias, M., Requena, I., Ventura, M., Pereiro, I., Castro, A., & Alvarez, A. (1995). A case of deaf-mutism as an expression of pure word deafness: neuroimaging and electrophysiological data. *European Journal of Neurology*, 2, 583–5.
- Auerbach, S. H., Allard, T., Naeser, M., Alexander, M. P., & Albert, M. L. (1982). Pure word deafness. Analysis of a case with bilateral lesions and a defect at the prephonemic level. *Brain : A Journal of Neurology*, 105(Pt 2), 271–300.
- Auriat, A.M., Borich, M.R., Snow, N.J., Wadden, K.P., Boyd, L.A. (2015). Comparing a diffusion tensor and non-tensor approach to white matter fiber tractography in chronic stroke. *NeuroImage. Clinical*, 7, 771–81.
- Barraquer-Bordas, L., Pena-Casanova, J., & Pons-Irazazabal, L. (1980). Central deafness without aphasic disorders in a patient with bilateral temporal lesions. *Revue Neurologique*, 136(5), 377–80.
- Baynes, K., Kegl, J. A., Brentari, D., Kussmaul, C., & Poizner, H. (1998). Chronic auditory agnosia following Landau-Kleffner syndrome: a 23 year outcome study. *Brain and Language*, 63(3), 381–425.
- Behrens, T. E. J., Berg, H. J., Jbabdi, S., Rushworth, M. F. S., & Woolrich, M. W. (2007). Probabilistic diffusion tractography with multiple fiber orientations: What can we



- gain? *NeuroImage*, 34(1), 144–155.
- Binder, J. R., Frost, J. a, Hammeke, T. a, Bellgowan, P. S., Springer, J. a, Kaufman, J. N., & Possing, E. T. (2000). Human temporal lobe activation by speech and nonspeech sounds. *Cerebral Cortex*, 10(5), 512–528.
- Blumstein, S. E., Cooper, W. E., Zurif, E. B., & Caramazza, A. (1977). The perception and production of Voice-Onset Time in aphasia. *Neuropsychologia*, 15(3), 371–383.
- Boatman, D., Gordon, B., Hart, J., Selnes, O., Miglioretti, D., & Lenz, F. (2000). Transcortical sensory aphasia: revisited and revised. *Brain : A Journal of Neurology*, 123 ( 8), 1634–42.
- Borich, M.R., Wadden, K.P., Boyd, L.A. (2012). Establishing the reproducibility of two approaches to quantify white matter tract integrity in stroke. *Neuroimage* 59, 2393–2400.
- Brugge, J. F., Volkov, I. O., Garell, P. C., Reale, R. a, & Howard, M. a. (2003). Functional connections between auditory cortex on Heschl's gyrus and on the lateral superior temporal gyrus in humans. *Journal of Neurophysiology*, 90(6), 3750–3763.
- Buchman, A.S., Garron, D.C., Trost-Cardamone, J.E., Wichter, M.D., & Schwartz, M. (1986). Word deafness: One hundred years later. *Journal of Neurology, Neurosurgery and Psychiatry*, 49, 489–499.
- Bürgel, U., Amunts, K., Hoemke, L., Mohlberg, H., Gilsbach, J. M., & Zilles, K. (2006). White matter fiber tracts of the human brain: Three-dimensional mapping at microscopic resolution, topography and intersubject variability. *NeuroImage*, 29(4), 1092–1105.
- Caplan, D., Gow, D., & Makris, N. (1995). Analysis of lesions by MRI in stroke patients

- with acoustic-phonetic processing deficits. *Neurology*, 45(2), 293–8.
- Catani, M., Allin, M. P. G., Husain, M., Pugliese, L., Mesulam, M. M., Murray, R. M., & Jones, D. K. (2007). Symmetries in human brain language pathways correlate with verbal recall. *Proceedings of the National Academy of Sciences of the United States of America*, 104(43), 17163–17168.
- Catani, M., & Ffytche, D. H. (2005). The rises and falls of disconnection syndromes. *Brain*, 128(10), 2224–2239.
- Catani, M., Howard, R. J., Pajevic, S., & Jones, D. K. (2002). Virtual in vivo interactive dissection of white matter fasciculi in the human brain. *NeuroImage*, 17(1), 77–94.
- Catani, M., Jones, D. K., Donato, R., & Ffytche, D. H. (2003). Occipito-temporal connections in the human brain. *Brain: A Journal of Neurology*, 126(Pt 9), 2093–107.
- Catani, M., Jones, D. K., & Ffytche, D. H. (2005). Perisylvian language networks of the human brain. *Annals of Neurology*, 57(1), 8–16.
- Catani, M., & Mesulam, M. (2008). What is a disconnection syndrome? *Cortex*, 44(8), 911–913.
- Catani, M., & Thiebaut de Schotten, M. (2008). A diffusion tensor imaging tractography atlas for virtual in vivo dissections. *Cortex*, 44(8), 1105–1132.
- Chocholle, R., Chedru, F., Botte, M. C., Chain, F., & Lhermitte, F. (1975). Psychoacoustic study of a case of “cortical deafness”. *Neuropsychologia*, 13(2), 163–72.
- Coslett, H. B., Brashear, H. R., & Heilman, K. M. (1984). Pure word deafness after bilateral primary auditory cortex infarcts. *Neurology*, 34(3), 347–52.
- Crawford, J. R., & Howell, D. C. (1998). Comparing an Individual’s Test Score Against

- Norms Derived from Small Samples. *The Clinical Neuropsychologist*, 12(4), 482–486.
- Dalla Pria, M., Spinnler, H., & Vallar, G. (1979). Pure word deafness and bilateral posterior perisylvian softenings: report of a case with neuropsychological-C.A.T. correlation. *Schweizer Archiv Für Neurologie, Neurochirurgie Und Psychiatrie Archives Suisses de Neurologie, Neurochirurgie et de Psychiatrie*, 125(1), 47–58.
- Damasio, H., & Damasio, A. (1979). “Paradoxical” ear extinction in dichotic listening: possible anatomic significance. *Neurology*, 29(5), 644–53.
- Dejerine, J., & Serieux, P. (1897). Un cas de surdité verbale pure terminée par sensorielle suivie d’autopsie. *Compte-Rendus Des Seances de La Societe de Biologie*, 10, 1074–1077.
- Dell’Acqua, F., Rizzo, G., Scifo, P., ... Fazio, F. (2007). A Model-Based Deconvolution Approach to Solve Fiber Crossing in Diffusion-Weighted MR Imaging. *Biomedical Engineering, {IEEE} Transactions on*, 54(3), 462–472.
- Dell’Acqua, F., Scifo, P., Rizzo, G., Catani, M., Simmons, A., Scotti, G., & Fazio, F. (2010). A modified damped Richardson-Lucy algorithm to reduce isotropic background effects in spherical deconvolution. *NeuroImage*, 49(2), 1446–1458.
- Earnest, M. P., Monroe, P. A., & Yarnell, P. R. (1977). Cortical deafness: demonstration of the pathologic anatomy by CT scan. *Neurology*, 27(12), 1172–5.
- Engelen, A., Silbersweig, D., Stern, E., Huber, W., Döring, W., Frith, C., & Frackowiak, R. S. (1995). The functional anatomy of recovery from auditory  
 . A PET study of sound categorization in a neurological patient and normal controls. *Brain : A Journal of Neurology*, 118(6), 1395–409.

- Ernest, M. P., Monroe, P. A., & Yarnell, P. R. (1977). Cortical deafness: demonstration of the patologic anatomy by CT scan. *Neurology*, 27(1172-1175).
- Forkel, S. J., Thiebaut de Schotten, M., Dell'Acqua, F., Kalra, L., Murphy, D. G. M., Williams, S. C. R., & Catani, M. (2014). Anatomical predictors of aphasia recovery: a tractography study of bilateral perisylvian language networks. *Brain : A Journal of Neurology*, 137(Pt 7), 2027–39.
- Franklin, S. (1989). Dissociations in auditory word comprehension; evidence from nine fluent aphasic patients. *Aphasiology*, 3(3), 189–207.
- Fujii, T., Fukatsu, R., Watabe, S., Ohnuma, A., Teramura, K., Kimura, I., Kogure, K. (1990). Auditory sound agnosia without aphasia following a right temporal lobe lesion. *Cortex; a Journal Devoted to the Study of the Nervous System and Behavior*, 26(2), 263–8.
- Galuske, R., Schumann, A., Schlote, W., Bratzke, H., & Singer, W. (1999). Intereal connections in the human auditory cortex. *Neuroimage*, 9 (6 Pt 2).
- Garde, M. M., & Cowey, A. (2000). “Deaf hearing”: unacknowledged detection of auditory stimuli in a patient with cerebral deafness. *Cortex; a Journal Devoted to the Study of the Nervous System and Behavior*, 36(1), 71–80. Retrieved from
- Gazzaniga, M. S., Velletri Glass, A., Sarno, M. T., & Posner, J. B. (1973). Pure Word Deafness and Hemispheric Dynamics a Case History. *Cortex*, 9(1), 136–143.
- Geschwind, N., & Geschwind, N. (1965). Disconnection syndromes in animals and man. *Brain*, 88, 237–644.
- Glasser, M. F., Sotiropoulos, S. N., Wilson, J. A., Coalson, T. S., Fischl, B., Andersson, J. L., ... Jenkinson, M. (2013). The minimal preprocessing pipelines for the Human

- Connectome Project. *NeuroImage*, 80, 105–124.
- Godefroy, O., Leys, D., Furby, A., De Reuck, J., Daems, C., Rondepierre, P., ... Desauty, A. (1995). Psychoacoustical deficits related to bilateral subcortical hemorrhages. A case with apperceptive auditory agnosia. *Cortex; a Journal Devoted to the Study of the Nervous System and Behavior*, 31(1), 149–59.
- Goldstein, N. (1974). Auditory agnosia for speech (Pure Word Deafness). *Brain and Language*, 1, 195–204.
- Hackett, T. A., Stepniewska, I., & Kaas, J. H. (1998). Subdivisions of auditory cortex and ipsilateral cortical connections of the parabelt auditory cortex in macaque monkeys. *The Journal of Comparative Neurology*, 394(4), 475–95.
- Hayashi, K., & Hayashi, R. (2007a). Pure word deafness due to left subcortical lesion: Neurophysiological studies of two patients. *Clinical Neurophysiology*, 118(4), 863–868.
- Hayashi, K., & Hayashi, R. (2007b). Pure word deafness due to left subcortical lesion: neurophysiological studies of two patients. *Clinical Neurophysiology : Official Journal of the International Federation of Clinical Neurophysiology*, 118(4), 863–8.
- Hemphill, R. E., & Stengel, E. (1940). a Study on Pure Word-Deafness. *Journal of Neurology and Psychiatry*, 3(3), 251–262.
- Henneberg, R. (1926). Hirnbefund bei reiner Worttaubheit. *Zentralblatt Für Nervenheilkunde Und Psychatrie*, 43, 251–2.
- Henschen, S. E. (1920). *Klinische und Patologische Beiträge zur Pathologie des Gehirns*. Stockholm: Nordiska Bokhandeln.
- Hickok, G. (2014). The architecture of speech production and the role of the phoneme in

- speech processing, *Language, Cognition and Neuroscience*, 29, 2-20.
- Hickok, G., & Poeppel, D. (2007). The cortical organization of speech processing. *Nature Reviews Neuroscience*, 8(5), 393–402.
- Hoistad, D. L., & Hain, T. C. Central hearing loss with a bilateral inferior colliculus lesion. *Audiology & Neuro-Otology*, 8(2), 111–3.
- Hugdahl, K., Heiervang, E., Ersland, L., Lundervold, A., Steinmetz, H., & Smievoll, A. I. (2003). Significant relation between MR measures of planum temporale area and dichotic processing of syllables in dyslexic children. *Neuropsychologia*, 41(6), 666–675.
- Hutsler, J. J. (2003). The specialized structure of human language cortex: Pyramidal cell size asymmetries within auditory and language-associated regions of the temporal lobes. *Brain and Language*, 86(2), 226–242.
- Ishii, K., Ueda, Y., Ohkoshi, N., Mizusawa, H., & Shoji, S. (1995). Cortical auditory disorder caused by bilateral temporal infarctions. *Internal Medicine (Tokyo, Japan)*, 34(8), 801–5.
- Jäncke, L. (2009). The plastic human brain. *Restorative Neurology and Neuroscience*, 27(5), 521–38.
- Jani, N. N., Laureno, R., Mark, A. S., & Brewer, C. C. (1991). Deafness after bilateral midbrain contusion: a correlation of magnetic resonance imaging with auditory brain stem evoked responses. *Neurosurgery*, 29(1), 106–8; discussion 108–9.
- Johkura, K., Matsumoto, S., Komiyama, A., Hasegawa, O., & Kuroiwa, Y. (1998). Unilateral saccadic pursuit in patients with sensory stroke: sign of a pontine tegmentum lesion. *Stroke; a Journal of Cerebral Circulation*, 29(11), 2377–80.

- Jones, D. K. (2003). Determining and visualizing uncertainty in estimates of fiber orientation from diffusion tensor MRI. *Magnetic Resonance in Medicine*, 49(1), 7–12.
- Jones, D.K., Cercignani, M. (2010). Twenty-five pitfalls in the analysis of diffusion MRI data. *NMR Biomed.* 23, 803–820.
- Jones, J., & Dinolt, R. (1952). Pure word deafness. *The Laryngoscope*, 62(2), 194–203.
- Kanshepolksy, J., Kelley, J. J., & Waggener, J. D. (1973). A cortical auditory disorder. Clinical, audiologic and pathologic aspects. *Neurology*, 23(7), 699–705.
- Kazui, S., Naritomi, H., Sawada, T., Inoue, N., & Okuda, J. (1990). Subcortical auditory agnosia. *Brain and Language*, 38(4), 476–87.
- Kim, S.H., Lee, D.G., You, H., Son, S.M., Cho, Y.W., Chang, M.C., Lee, J., Jang, S.H., 2011. The clinical application of the arcuate fasciculus for stroke patients with aphasia: a diffusion tensor tractography study. *NeuroRehabilitation* 29, 305–10.
- Kimura, D. (1961). Some effects of temporal-lobe damage on auditory perception. *Canadian Journal of Psychology*, 15, 156–65.
- Kleist, K. (1934). *Gehirnpathologie*. Leipzig: Barth.
- Kluender, K. R., Coady, J. A., & Kieft, M. (2003). Sensitivity to change in perception of speech. *Speech Communication*, 41(1), 59–69.
- Kohn, S. E., & Friedman, R. B. (1986). Word-meaning deafness: A phonological-semantic dissociation. *Cognitive Neuropsychology*, 3(3), 291–308.
- Kussmaul, Adolf.: Die Störungen der Sprache. Versuch einer Pathologie der Sprache. Leipzig: F. C. W. Vogel 1877.
- Lambert, J., Eustache, F., Lechevalier, B., Rossa, Y., & Viader, F. (1989). Auditory

- agnosia with relative sparing of speech perception. *Cortex; a Journal Devoted to the Study of the Nervous System and Behavior*, 25(1), 71–82.
- Le Gros Clark, W. E., & Russell, W. R. (1938). Cortical deafness without aphasia. *Brain*, 61(4), 375–383.
- Leemans, A., & Jones, D. K. (2009). The B-matrix must be rotated when correcting for subject motion in DTI data. *Magnetic Resonance in Medicine*, 61(6), 1336–1349.
- Lichtheim, L. (1885). On aphasia. *Brani*, 7, 433–484.
- Liepman, H. (1898). Ein Fall von reiner Sprachtaubheit. In: *Psychiatrische Abhandlungen* (Wernicke, C., Ed.).
- Liepmann, H. (1912). Anatomische befunde bei Aphasischen und Apraktischen. *Neurologisches Zentralblatt*, 31, 1524–30.
- Liepmann, H., & Storch, E. (1902). Der mikroskopische Gehirnbefund bei dem Fall Gorstelle. *European Neurology*, 11(2), 115–120.
- Makris, N., Preti, M. G., Asami, T., Pelavin, P., Campbell, B., Papadimitriou, G. M., ... Kubicki, M. (2013). Human middle longitudinal fascicle: variations in patterns of anatomical connections. *Brain Structure & Function*, 218(4), 951–68.
- Marshall, R. C., Rappaport, B. Z., & Garcia-Bunuel, L. (1985). Self-monitoring behavior in a case of severe auditory agnosia with aphasia. *Brain and Language*, 24(2), 297–313.
- Martin, R. C., Hamilton, a. C., & Slevc, L. R. (2010). fMRI of speech production in a case of pure word deafness. *Procedia - Social and Behavioral Sciences*, 6, 29–30.
- Menjot De Champfleur, N., Lima Maldonado, I., Moritz-Gasser, S., MacHi, P., Le Bars,



- E., Bonafé, A., & Duffau, H. (2013). Middle longitudinal fasciculus delineation within language pathways: A diffusion tensor imaging study in human. *European Journal of Radiology*, 82(1), 151–157.
- Metz-Lutz, M. N., & Dahl, E. (1984). Analysis of word comprehension in a case of pure word deafness. *Brain and Language*, 23(1), 13–25.
- Meyer, B., Kral, T., & Zentner, J. (1996). Pure word deafness after resection of a tectal plate glioma with preservation of wave V of brain stem auditory evoked potentials. *Journal of Neurology, Neurosurgery, and Psychiatry*, 61(4), 423–4.
- Miceli, G. (1982). The processing of speech sounds in a patient with cortical auditory disorder. *Neuropsychologia*, 20(1), 5–20.
- Miceli, G., Caltagirone, C., Gainotti, G., & Payer-Rigo, P. (1978). Discrimination of voice versus place contrasts in aphasia. *Brain and Language*, 6(1), 47–51.
- Miceli, G., Conti, G., Cianfoni, A., Di Giacomo, R., Zampetti, P., & Servidei, S. (2008). Acute auditory agnosia as the presenting hearing disorder in MELAS. *Neurological Sciences*, 29(6), 459–62.
- Miceli, G., Laudanna, A., Burani, C., & Capasso, R. (2004). Batteria per l'Analisi dei Deficit Afasici BADA. *EMS, Bologna*.
- Miceli, G., Silveri, M.C., Romani, C. & Caramazza, A. (1989). Variation in the pattern of omissions and substitutions of grammatical morphemes in the spontaneous speech of so-called agrammatic patients. *Brain and Language*, 36:447-492.
- Michel, F., Peronnet, F., & Schott, B. (1980). A case of cortical deafness: clinical and electrophysiological data. *Brain and Language*, 10(2), 367–77.
- Moore, B. C. J. (2008). The role of temporal fine structure processing in pitch perception,

masking, and speech perception for normal-hearing and hearing-impaired people.

*Journal of the Association for Research in Otolaryngology : JARO*, 9(4), 399–406.

Morosan, P., Rademacher, J., Schleicher, A., Amunts, K., Schormann, T., & Zilles, K.

(2001). Human primary auditory cortex: cytoarchitectonic subdivisions and mapping into a spatial reference system. *NeuroImage*, 13(4), 684–701.

Motomura, N., Yamadori, A., Mori, E., & Tamaru, F. (1986). Auditory agnosia. Analysis of a case with bilateral subcortical lesions. *Brain : A Journal of Neurology*, 109 ( Pt 3, 379–91.

Mott, F. W. (1907). Bilateral lesion of the auditory cortical centre: Complete deafness and aphasia. *British Medical Journal*, 2(2432), 310–5.

Musiek, F. E., Charette, L., Morse, D., & Baran, J. A. (2004). Central Deafness Associated with a Midbrain Lesion. *Journal of the American Academy of Audiology*, 15(2), 133–151.

Nagafuchi, M., & Suzuki, J. (1993). Auditory agnosia due to incision of splenium corporis callosi. *Acta Oto-Laryngologica*, 76(2), 109–13. Retrieved from

Nakakoshi, S., Kashino, M., Mizobuchi, a, Fukada, Y., & Katori, H. (2001). Disorder in sequential speech perception: a case study on pure word deafness. *Brain and Language*, 76(2), 119–129.

Oldfield, R. C. (1971). The assessment and analysis of handedness: the Edinburgh inventory. *Neuropsychologia*, 9(1), 97–113.

Oppenheimer, D. R., & Newcombe, F. (1978). Clinical and anatomic findings in a case of auditory agnosia. *Archives of Neurology*, 35(11), 712–9.

Otsuki, M., Soma, Y., Sato, M., Homma, A., & Tsuji, S. (1998). Slowly progressive pure

- word deafness. *European Neurology*, 39(3), 135–40.
- Pan, C.-L., Kuo, M.-F., & Hsieh, S.-T. (2004). Auditory agnosia caused by a tectal germinoma. *Neurology*, 63(12), 2387–9.
- Pasquier, F., Leys, D., Steinling, M., Guieu, J. D., Petit, H., & Cambier, J. (1991). Right unilateral auditory agnosia following left lenticular hemorrhage. *Revue Neurologique*, 147(2), 129–37.
- Penhune, V. B., Zatorre, R. J., MacDonald, J. D., & Evans, a C. (1996). Interhemispheric anatomical differences in human primary auditory cortex: probabilistic mapping and volume measurement from magnetic resonance scans, *Cerebral Cortex*, 6(5), 661-72.
- Pinard, M., Chertkow, H., Black, S., & Peretz, I. (2002). A case study of pure word deafness: modularity in auditory processing? *Neurocase : Case Studies in Neuropsychology, Neuropsychiatry, and Behavioural Neurology*, 8(1-2), 40–55.
- Poeppel, D. (2001). Pure word deafness and the bilateral processing of the speech code. *Cognitive Science*, 25(5), 679–693.
- Poeppel, D. (2003). The analysis of speech in different temporal integration windows: Cerebral lateralization as “asymmetric sampling in time.” *Speech Communication*, 41(1), 245–255.
- Poeppel, D., Emmorey, K., Hickok, G., & Pylkkänen, L. (2012). Towards a new neurobiology of language. *The Journal of Neuroscience : The Official Journal of the Society for Neuroscience*, 32(41), 14125–31.
- Potzl, O. (1919). *Zur Klinik und Anatomie der reinen Wrrtaubheit*. Berlin: Karger.
- Praamstra, P., Hagoort, P., Maassen, B., & Crul, T. (1991). Word deafness and auditory cortical function. A case history and hypothesis. *Brain : A Journal of Neurology*, 114

(3), 1197–1225.

- Rademacher, J., Bürgel, U., & Zilles, K. (2002). Stereotaxic localization, intersubject variability, and interhemispheric differences of the human auditory thalamocortical system. *NeuroImage*, 17(1), 142–60.
- Roberts, M., Sandercock, P., & Ghadiali, E. (1987). Pure word deafness and unilateral right temporo-parietal lesion: a case report.
- Rosati, G., De Bastiani, P., Paolino, E., Prosser, S., Arslan, E., & Artioli, M. (1982). Clinical and audiological findings in a case of auditory agnosia. *Journal of Neurology*, 227(1), 21–7.
- Saffran, E. M., Marin, O. S., & Yeni-Komshian, G. H. (1976). An analysis of speech perception in word deafness. *Brain and Language*, 3(2), 209–228.
- Schuster, P., & Taterka, H. (1926). Beitrag zur Anatomie und Klinik der reinen Worttaubheit. *Zeitschrift für Die Gesamte Neurologie Und Psychiatrie*, 105, 494–538.
- Seldon, H. L. (1981). Structure of human auditory cortex. I. Cytoarchitectonics and dendritic distributions. *Brain Research*, 229(2), 277–94.
- Semenza, C., Cavinato, M., Rigon, J., Battel, I., Meneghello, F., & Venneri, A. (2012). Persistent cortical deafness: a voxel-based morphometry and tractography study. *Neuropsychology*, 26(6), 675–83.
- Shivashankar, N., Shashikala, H. R., Nagaraja, D., Jayakumar, P. N., & Ratnavalli, E. (2001). Pure word deafness in two patients with subcortical lesions. *Clinical Neurology and Neurosurgery*, 103(4), 201–205.
- Simons, J. S., & Lambon-Ralph, M. A. (1999). The Auditory Agnosias. *Neurocase*, 5(June 2012), 379–406.

- Slevc, L. R., Martin, R. C., Hamilton, A. C., & Joanisse, M. F. (2011). Speech perception, rapid temporal processing, and the left hemisphere: a case study of unilateral pure word deafness. *Neuropsychologia*, 49(2), 216–30.
- Slevc, L. R., & Shell, A. R. (2015). Auditory agnosia. In Celesia, G. G., & Hickok G., Eds.). *Handbook of Clinical Neurology*, Vol. 129(3<sup>rd</sup> series). Pp. 573-587.
- Spreen, O., Benton, A. L., & Fincham, R. W. (1965). Auditory agnosia without aphasia. *Archives of Neurology*, 13, 84–92.
- Stefanatos, G. A., Gershkoff, A., & Madigan, S. (2005). On pure word deafness, temporal processing, and the left hemisphere. *Journal of the International Neuropsychological Society : JINS*, 11(4), 456–70; discussion 455.
- Studdert-Kennedy, M., & Shankweiler, D. (1970). Hemispheric specialization for speech perception. *The Journal of the Acoustical Society of America*, 48(2), 579–94.
- Suh, H., Shin, Y.-I., Kim, S. Y., Kim, S. H., Chang, J. H., Shin, Y. B., & Ko, H.-Y. (2012). A case of generalized auditory agnosia with unilateral subcortical brain lesion. *Annals of Rehabilitation Medicine*, 36(6), 866–70.
- Szirmai, I., Farsang, M., & Csüri, M. (2003). Cortical auditory disorder caused by bilateral strategic cerebral bleedings. Analysis of two cases. *Brain and Language*, 85, 159–165.
- Tabira, T., Tsuji, S., Nagashima, T., Nakajima, T., & Kuroiwa, Y. (1981). Cortical deafness in multiple sclerosis. *Journal of Neurology, Neurosurgery, and Psychiatry*, 44(5), 433–6.
- Takahashi, N., Kawamura, M., Shinotou, H., Hirayama, K., Kaga, K., & Shindo, M. (1992). Pure word deafness due to left hemisphere damage. *Cortex; a Journal*

- Devoted to the Study of the Nervous System and Behavior*, 28(2), 295–303.
- Tallal, P., & Newcombe, F. (1978). Impairment of auditory perception and language comprehension in dysphasia. *Brain and Language*, 5(1), 13–34.
- Tanaka, Y., Yamadori, a, & Mori, E. (1987). Pure word deafness following bilateral lesions. A psychophysical analysis. *Brain : A Journal of Neurology*, 110 (2), 381–403.
- Taniwaki, T., Tagawa, K., Sato, F., & Iino, K. (2000). Auditory agnosia restricted to environmental sounds following cortical deafness and generalized auditory agnosia. *Clinical Neurology and Neurosurgery*, 102(3), 156–162.
- Thiebaut de Schotten, M., Ffytche, D. H., Bizzi, A., Dell’Acqua, F., Allin, M., Walshe, M., Catani, M. (2011). Atlasing location, asymmetry and inter-subject variability of white matter tracts in the human brain with MR diffusion tractography. *NeuroImage*, 54(1), 49–59.
- Tobias, E., Mann, C., Bone, I., de Silva, R., & Ironside, J. (1994). A case of Creutzfeldt-Jakob disease presenting with cortical deafness. *Journal of Neurology, Neurosurgery, and Psychiatry*, 57(7), 872–3.
- Tyler, L. K., & Moss, H. (1997). imageability and category-specificity. *Cognitive Neuropsychology*, 14, 293–318.
- v. Economo, C., & Horn, L. (1930). Über Windungsrelief, Maße und Rindenarchitektonik der Supratemporalfläche, ihre individuellen und ihre Seitenunterschiede. *Zeitschrift Für Die Gesamte Neurologie Und Psychiatrie*, 130(1), 678–757.
- van Gehuchten, A., & Goris, C. (1901). Un cas de surdit  verbale pure par abc s du lobe temporal gauche: tr panation, gu rison. *Le Nevrxax*, 3, 65–82.

- Vitte, E., Tankéré, F., Bernat, I., Zouaoui, A., Lamas, G., & Soudant, J. (2002). Midbrain deafness with normal brainstem auditory evoked potentials. *Neurology*, 58(6), 970–3.
- Wang, E., Peach, R. K., Xu, Y., Schneck, M., & Manry, C. (2000). Perception of dynamic acoustic patterns by an individual with unilateral verbal auditory agnosia. *Brain and Language*, 73(3), 442–455.
- Wang, Y., Fernandez-Miranda, J. C., Verstynen, T., Pathak, S., Schneider, W., & Yeh, F. C. (2012). Rethinking the role of the middle longitudinal fascicle in language and auditory pathways. *Cerebral Cortex*, 23(10), 2347–2356.
- Warrier, C., Wong, P., Penhune, V., Zatorre, R., Parrish, T., Abrams, D., & Kraus, N. (2009). Relating structure to function: Heschl's gyrus and acoustic processing. *The Journal of Neuroscience : The Official Journal of the Society for Neuroscience*, 29(1), 61–69.
- Wolmetz, M., Poeppel, D., & Rapp, B. (2011). What does the right hemisphere know about phoneme categories? *Journal of Cognitive Neuroscience*, 23(3), 552–569.
- Yamada, K., Kizu, O., 2006. MR tractography for stroke. *Int. Congr. Ser.* 1290, 67–72.
- Yaqub, B. A., Gascon, G. G., Al-Nosha, M., & Whitaker, H. (1988). Pure word deafness (acquired verbal auditory agnosia) in an Arabic speaking patient. *Brain : A Journal of Neurology*, 111, 457–66.
- Young, E. D. (2008). Neural representation of spectral and temporal information in speech. *Philosophical Transactions of the Royal Society of London. Series B, Biological Sciences*, 363(1493), 923–945.
- Zatorre, R. J., Belin, P., & Penhune, V. B. (2002). Structure and function of auditory cortex: music and speech. *Trends in Cognitive Sciences*, 6(1), 37–46.

**Figure Captions:**

**Figure 1.** Schematic representation of lesion profiles underlying pure word deafness (PWD). The thalamus (TH), the superior temporal gyrus (STG), Heschl's transverse temporal gyrus (HG) and the main white matter connections involved in PWD are shown. **Left panel:** Possible cortical and subcortical lesion sites in PWD due to bilateral damage. Cortical lesions (panel A) involve the grey matter of STG and HG. Subcortical lesions (panel B) most often affect the auditory system at the level of the medial geniculate nucleus (less frequently, putaminal damage has been reported). Combined cortical damage to one hemisphere and subcortical damage to the other is also possible. **Right panel:** Possible lesion sites in PWD due to unilateral damage. When the lesion is restricted to the cortex (panel A), damage affects left HG and STG. In subcortical lesions (panel B), damage interrupts intratemporal and transcallosal connections, disconnecting left-hemisphere language areas from auditory inputs. Combined cortical and subcortical damage is the most frequent occurrence, and may be the case in the subject reported here.

**Figure 2. Dichotic Listening results.** Number of syllables presented to the right and/or left ear and reported correctly by FO and the control group. The responses of the control group show the typical Right-Ear Advantage (REA); those of the patient show the reverse pattern, with an almost total extinction of stimuli presented to the right ear.



**Figure 3.** Axial, coronal, and sagittal view of T1-weighted structural scans of FO's brain. Red arrows indicate the lesion in the left hemisphere. Abnormal cortical intensity and gyral atrophy is evident in the portion of the superior temporal gyrus (stg) between the Heschl's gyrus (hg) and the temporal pole, a smaller region in the posterior middle temporal gyrus (mtg) and in the posterior insula (ins).

**Figure 4. A:** Cortical thickness and gyral volume of areas known to be involved in auditory input processing were reconstructed in both temporal lobes in FO. The green lines outline the cortical extent of the intact right Heschl's gyrus; the red lines outline the corresponding regions in the damaged left hemisphere (see also Table 1). **B:** Statistical map of the comparison of cortical thickness in FO and in 35 matched healthy controls. Cluster-wise statistical significance was calculated via 10,000 Monte Carlo simulations implemented in FSDG ( $P < 0.001$ ).

**Figure 5.** SD-based tractography reconstruction of the acoustic radiation (AR), the optic radiation (OR) and the transcallosal fibers in FO's left hemisphere. A 3D reconstruction of the lesion is also shown (in red). Colors are chosen arbitrarily. **A:** From left to right: reconstruction of AR (green), OR (light blue) and lesion volume shown on axial map; reconstructed tracts superimposed on axial density maps of FO's brain as displayed in FSLView (z-coordinates are subject-specific); lateral and frontal views of AR and OR at their stemming point. OR starts from the lateral geniculate body of the thalamus (LGN), more laterally than AR (which originates from the medial geniculate nucleus, MGN). **B:** From left to right: virtual reconstruction of transcallosal fibers shown on coronal map in frontal view; anatomy of the

reconstructed tracts superimposed on axial density maps of FO's brain as displayed in FSLView (z-coordinates are subject-specific); top view of the fibers as they reach auditory and association areas in each hemisphere. Fibers connecting the two auditory cortices are in red; fibers connecting posterior association areas are in yellow.

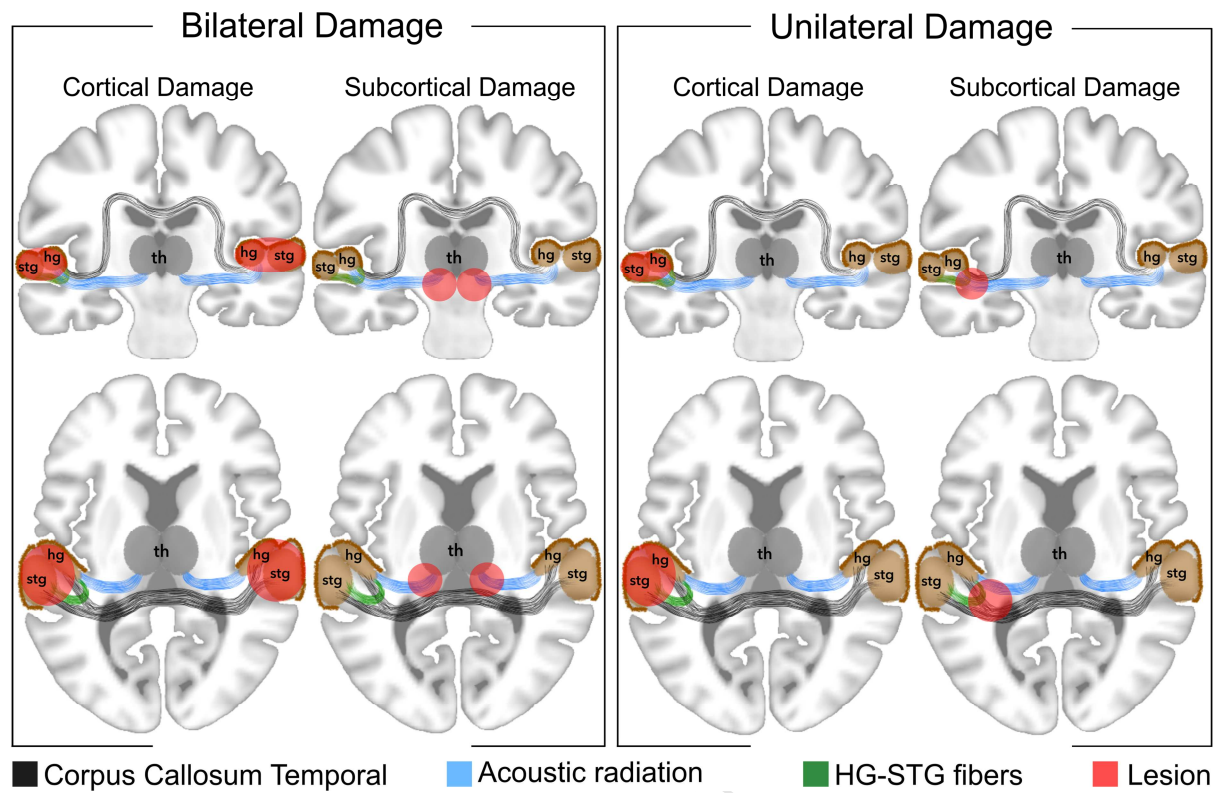
Table 1. Cortical thickness and gyral volume in areas involved in auditory input processing. Numbers report measures of cortical thickness (a) and gyral volume (b) in the left and in the right hemisphere of FO. Cortical and gyral parcellation are based on Destrieux et al., 2010; terminology is based on Duvernoy, 1991.

a)

<b>GYRUS</b>	<i>cortical thickness (mm<sup>2</sup>)</i>	<b>GYRUS</b>	<i>cortical thickness (mm<sup>2</sup>)</i>
lh_G_temp_sup-G_T_transv	2,06	rh_G_temp_sup-G_T_transv	2,477
lh_G_temp_sup-Lateral	2,41	rh_G_temp_sup-Lateral	2,604
lh_G_temp_sup-Plan_polar	2,897	rh_G_temp_sup-Plan_polar	3,091
lh_G_temp_sup-Plan_tempo	1,866	rh_G_temp_sup-Plan_tempo	2,501
lh_S_circular_insula_inf	2,026	rh_S_circular_insula_inf	2,624
lh_S_circular_insula_sup	2,269	rh_S_circular_insula_sup	2,379
lh_S_temporal_sup	1,94	rh_S_temporal_sup	2,265
lh_S_temporal_transverse	2,064	rh_S_temporal_transverse	2,677

b)

<b>GYRUS</b>	<i>volume (mm<sup>3</sup>)</i>	<b>GYRUS</b>	<i>volume (mm<sup>3</sup>)</i>
lh_G_temp_sup-G_T_transv	539	rh_G_temp_sup-G_T_transv	1011
lh_G_temp_sup-Lateral	2276	rh_G_temp_sup-Lateral	4532
lh_G_temp_sup-Plan_polar	1090	rh_G_temp_sup-Plan_polar	1753
lh_G_temp_supPlan_tempo	511	rh_G_temp_supPlan_tempo	1539
lh_S_circular_insula_inf	1273	rh_S_circular_insula_inf	2099
lh_S_circular_insula_sup	1890	rh_S_circular_insula_sup	2080
lh_S_temporal_sup	4568	rh_S_temporal_sup	9851
lh_S_temporal_transverse	184	rh_S_temporal_transverse	394



## Dichotic Listening

