



Magnetic resonance imaging findings of two cases with multinodular and vacuolating neuronal tumor

Erkan Gökçe¹

Received: 3 October 2017 / Accepted: 7 December 2017
© Belgian Neurological Society 2017

Abstract

Multinodular and vacuolating neuronal tumors (MVNT) are low grade neuronal tumors classified in cerebral tumors based on 2016 WHO central nerve system classification. Previously, MVNTs were probably tumors incidentally determined by imaging methods, but they could not be diagnosed or they were misdiagnosed. Two cases are reported in the present study, for which radiological imaging was carried out for epilepsy in one and for headache in the other. The first case was a twenty seven years old female patient with headache complaint. Brain MRI examination revealed a clustering lesion of multinodular character located in an about $4.0 \times 3.5 \times 1.5$ cm area which had a left precuneal subcortical-juxtacortical location. The other case was a male patient with epilepsy. A clustering lesion of multinodular nature was determined in an area of about $2.0 \times 2.0 \times 1.5$ cm in cortical-subcortical area in corona radiata-convexity plane of right middle frontal gyrus. No changes in size or nature were determined in follow-up examinations. MVNTs are recently defined tumors, and the characteristic feature for diagnosis of these rare tumor entities could be a subcortical white matter lesion with satellite nodules that manifest itself as T2/FLAIR hyperintensity. Increasing number of case reports and studies in the literature could make the radiological and pathological signs of the condition clearer.

Introduction

Multinodular and vacuolating neuronal tumors (MVNT) are superficially located cerebral neuronal tumors which were first identified in 2013 [1–3]. World Health Organization Classification of Tumors of the Central Nervous System (2016) includes MVNT as a unique cytoarchitectural pattern of gangliocytoma [4, 5]. The true epidemiology of MVNTs is unknown, some of them either diagnosed incidentally or detected on MR scanning in patients with epilepsy, but they are often misdiagnosed on imaging [2–4, 6]. A small number of case reports and several MVNT series have been reported in the neuropathologic and radiologic literature [1–3, 5–9]. The present study reports two radiologically diagnosed cases with MVNT, who underwent MRI because of epilepsy and the other because of headache.

Case reports

Case 1

Cranial computed tomography (CT) of a 27 years old woman due to headache had been reported to be normal by us (Fig. 1a). However, magnetic resonance imaging (MRI) obtained with 1.5T MR unit showed a multinodular clustering lesion of about $4.0 \times 3.5 \times 1.5$ cm dimensions with juxtacortical location in the precuneus which was hyperintense on T2 weighted (Fig. 1b, c) and FLAIR series (Fig. 1d), slightly hypointense on T1 weighted series (Fig. 1e), non-enhanced after contrast administration (Fig. 1f), without peripheral edema and without mass effect on all the series (Fig. 1b–e). Diffusion restriction was not observed on diffusion MR (Fig. 2a). A significant metabolite change was not observed in lesion area with MR spectroscopy (MRS). Dynamic susceptibility contrast (DSC) perfusion MR without preloading did not indicate perfusion increase in the lesion area (Fig. 2b, c). No change in size or nature of the lesion was observed in about 3 years of follow-up imaging.

✉ Erkan Gökçe
drerkangokce@gmail.com

¹ Gaziosmanpaşa University Medicine School, Merkez, Tokat, Turkey

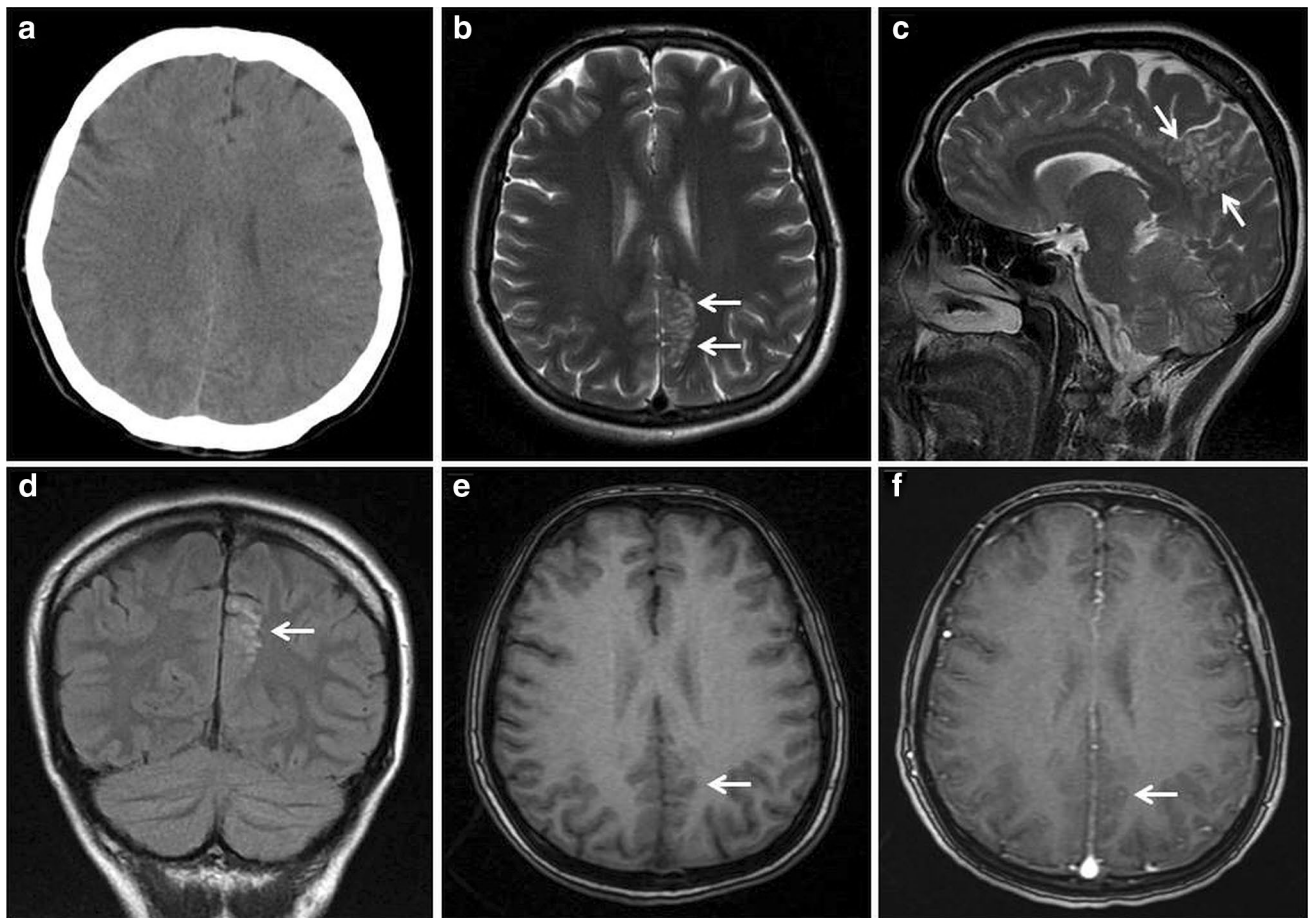


Fig. 1 CT and MR images of a 27-year-old female patient with headache complaints. **a** The mass cannot be clearly distinguished on the CT examination. **b** Axial and **c** clustering multinodular lesion located in subcortical–juxtacortical area of left precuneus is seen on sagittal

T2 weighted MRI (arrow). **d** Coronal FLAIR image shows hyperintense lesion (arrow). **e** Lesion cannot be distinguished on axial gradient T1 weighted image. **f** Non-enhancing is seen on axial contrast-enhanced image

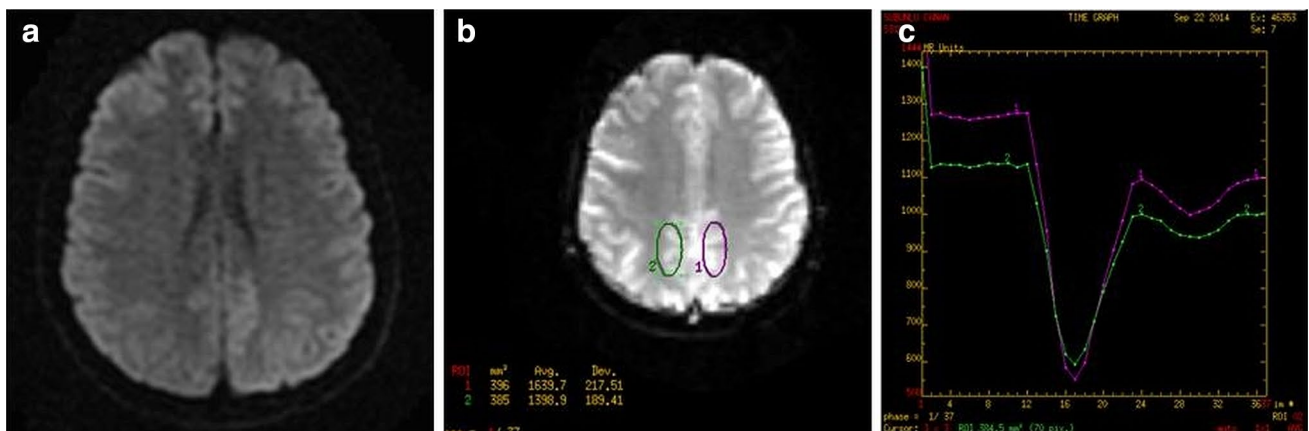


Fig. 2 Diffusion and DSC perfusion MR images of a 27-year-old female patient with headache. **a** No diffusion restriction on diffusion weighted imaging. **b** A minimal rCBC increase was observed

in lesion area with perfusion MR. **c** Perfusion dynamics of the lesion was similar to that of normal parenchyma in perfusion chart

Case 2

A $2.0 \times 2.0 \times 1.5$ cm lesion was detected in the brain MRI (1.5T MR) of a 21 years old male patient who had epilepsy. The lesion was located in the right middle frontal gyrus. The clustering multinodular lesion was hyperintense on T2 weighted (Fig. 3a, b) and FLAIR series (Fig. 3c), slightly hypointense on T1 weighted series (Fig. 3d), non-enhanced after contrast administration (Fig. 1e), without peripheral edema, without mass effect on all the series (Fig. 3a–e). The lesion did not have diffusion restriction on diffusion MR (Fig. 3f). MRS did not indicate significant metabolite change in lesion area. DSC perfusion MR series without preloading did not show perfusion increase in the lesion area (Fig. 4a, b). No change was observed in size or nature of the lesion throughout the 2 years of follow-up imaging of the patient.

Discussion

MVNTs are low-grade tumors which have been placed in the cerebral tumors list in 2016 WHO's classification of central nerve system tumors [4]. Macroscopically, MVNTs are round, nodular-looking, small, well-bordered, clustering tumors located subcortically and in next to deep cortical layers [2–4]. Microscopically, they have mature-looking neurons embedded in a fibrillary background and have large cytoplasmic vacuoles [2–4]. Tumor cells have immunopositivity for human early stage neuronal development associated protein HuC/HuD and Olig2. On the other hand, they exhibit negativity or weak positivity for mature neurons related neuronal lineage markers such as neuronal nuclear antigen, synaptophysin and neurofilament proteins [1–3, 7, 8]. They also have immunopositivity for alpha-internexin [8]. Alpha-internexin positivity of MVNT supports the

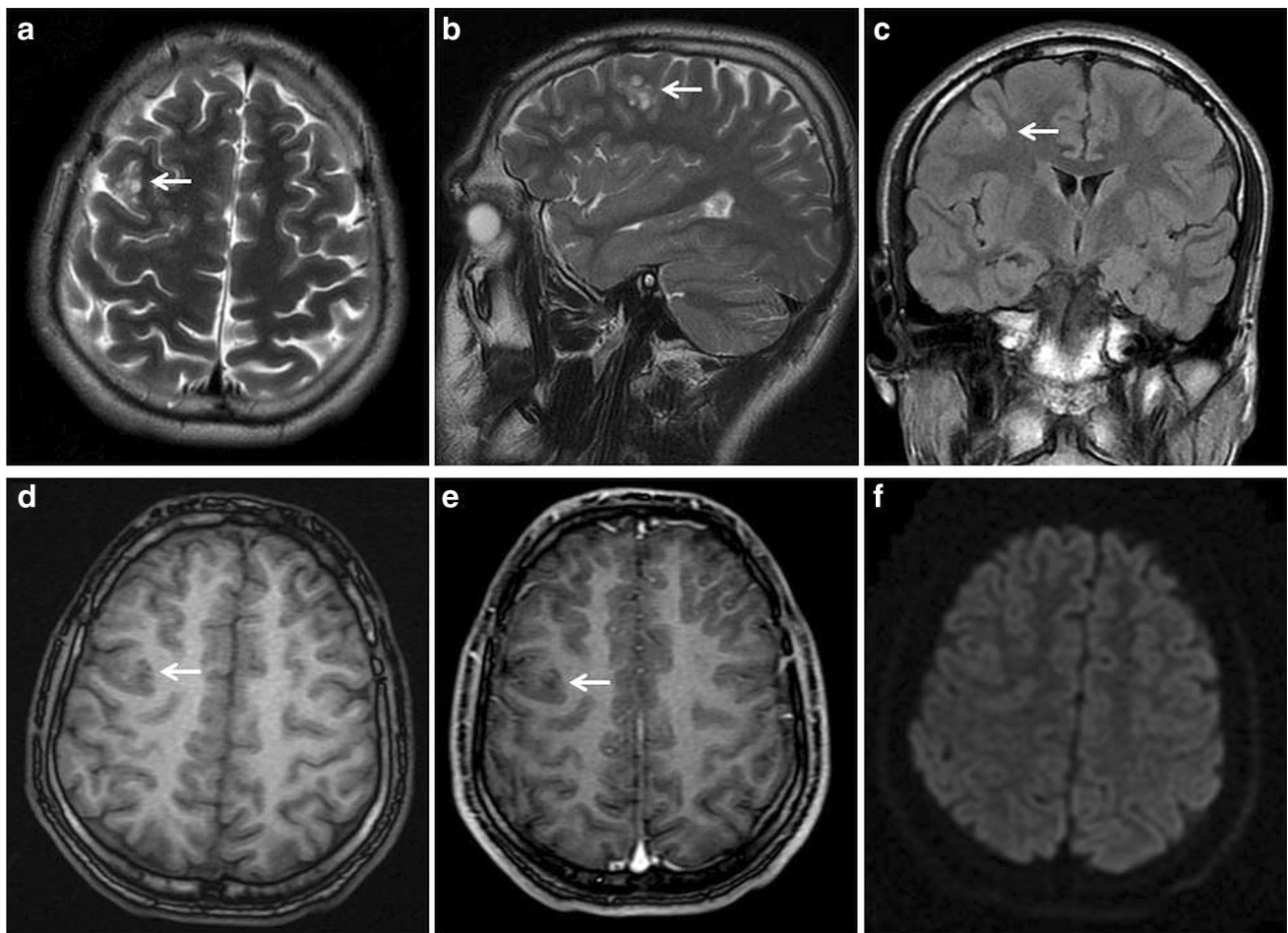


Fig. 3 Brain MRI of a 21-year-old male patient with epilepsy. **a** Axial, **b** Sagittal T2 weighted images of multinodular hyperintense lesion in cortical–subcortical area in right middle frontal gyrus. **c** Heterogeneous hyperintense appearance of the lesion on FLAIR

sequence. **d** Hypointense appearance of the lesion on T1 weighted image, **e** Non-enhancing lesion on contrast-enhanced image. **f** No diffusion restriction on diffusion weighted imaging

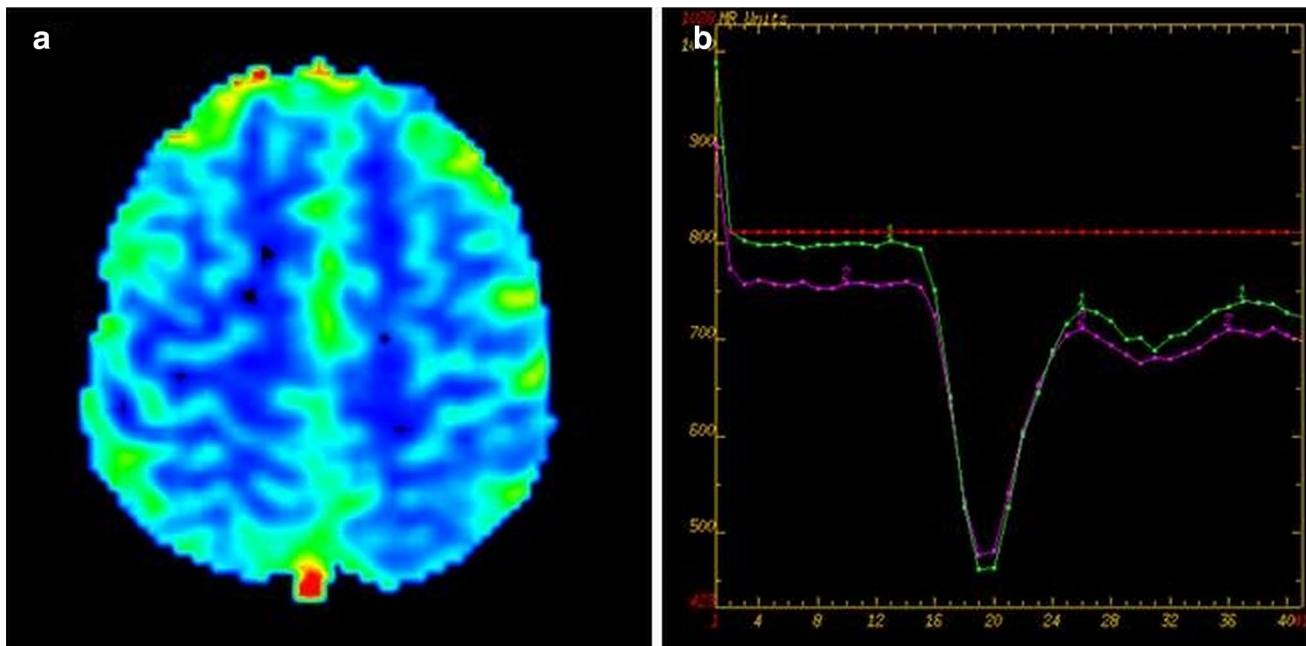


Fig. 4 DSC perfusion MR images of a 21-year-old male patient who had epilepsy. **a** A clear perfusion increase was not observed on colored rCBV map of lesion area. **b** Perfusion dynamic of the lesion was similar to that of normal parenchyma on perfusion graph

hypothesis that the lesion could represent a dysplastically early neuronal phenotype and could be categorized somewhere between cortical malformation and hamartomatous lesions of benign nature [5]. Characteristic modular changes such as IDH, 1p19q status and BRAF1,2,4 were not detected in genetic analyses except for one case in which a MEK1 mutation was found [1, 3, 8].

Radiological features of MVNTs are similar. It is difficult to identify small lesions on CT, but they appear as non-enhancing and non-calcifying low attenuation lesions in subcortical or juxtacortical white matter [8]. On MRI, on the other hand, they appear on T2 weighted and FLAIR series as clustering multinodular lesions in subcortical white matter without mass effect or peripheral edema [1–3, 5]. They appear hyperintense on T2 weighted, do not suppress on FLAIR series [5]. On contrast-enhanced series, they generally do not have enhancement, but there are some reports indicating weak and focal enhancement [1–3, 5]. Alsufayan et al. detected contrast-enhancement in a dotted and linear pattern in a total of three lesions in two out of 24 MVNT cases [6]. In MVNTs studied histopathologically and radiologically in literature, distinct and coalesced gray nodules were adjacent to deep cortex, but most lesions were subcortical. It was mentioned that this type of localization can also be seen in DNT, but it is more characteristic in MVNT [2]. In their radiology-based studies, Alsufayan et al. [6] reported that 43% of the lesions were in subcortical/juxtacortical white matter, while 57% were in cortical and subcortical white matter. In accordance with the literature, lesions

found in our cases did not have diffusion restriction [3, 5, 6]. Fukushima [1] and Huse et al. [2] reported relative increases in choline/NAA in one case each where they used MRS. Nagaishi et al. [7], on the other hand, reported increase in choline peak of their cases. In our cases, no clear changes were observed in metabolite levels on MRS.

MVNTs could be differentially diagnosed using entities with a neuronal component. Tumors of ganglion cells are solid masses with well circumscription or cystic lesions having a mural nodule. They contain disarrayed dysmorphic ganglion cells which may or may not have neoplastic glial components. Unlike ganglion cell tumors which often have EGBs, Rosenthal fibers, perivascular lymphatic infiltrate and microcalcifications in addition to neoplastic elements, MVNTs carries no such secondary characteristics [2, 7]. Dysembryoplastic neuroepithelial tumors (DNT) and similar tumors, focal cortical dysplasia (FCD) and perivascular spaces (PVS) should be considered radiologically in differential diagnosis of MVNTs. Although DNT is the tumor to be most probably confused with MVNTs, DNT has predominantly cortical, rather than subcortical, location. DNTs often have thickening in cerebral cortex and bright FLAIR rim without mass effect and edema. In previous cases studied by Huse et al. [1] and Bodi et al. [3], at least 3 out of 12 MVNT cases had radiological misdiagnoses of DNT [2]. In their study involving a case with Klinefelter syndrome, Monté et al. considered a lesion they detected on cerebral MRI as DNET first, but after a literature investigation, they concluded that the lesion was MVNT [9]. Similarly, we also had

specified in radiological reporting of our cases that lesions could primarily be DNT or similar tumors. FCD (Type II), on the other hand, has high T2 signal deep to cortex in the same location, but it is generally accompanied by a radial glial band (transmantle sign) and has a thickened abnormal overlying cortex [6]. PVSs could have similar localizations as MVNTs, but they are generally more elongated along the long axis of vessel. PVSs are observed isointense relative to cerebrospinal fluid on FLAIR [5, 6].

In terms of treatment and prognosis, MVNTs appear to be benign tumors. They are biologically very indolent and can only be followed through imaging when they are asymptomatic [1–3, 5]. In symptomatic patients with epilepsy, surgical resection often eliminates seizures without evident tumor regrowth [1–3]. In almost all cases reported in literature, lesions had stable prognoses albeit short follow-up periods [1, 3, 5, 6]. Slight progressions were reported only in two cases [1, 6].

Although the present study had the limitation that it is only radiology-based, characteristic MRI features of lesions and lack of nature or size changes in follow-up examinations suggested that they were MVNTs.

In conclusion, MVNTs are recently described neuronal tumors. As case reports and studies in the literature accumulate, MVNTs will be more frequently and more accurately diagnosed in daily clinical practice.

Funding This study was not funded by any organization.

Compliance with ethical standards

Conflict of interest I declare that I have no conflict of interest.

Ethical approval For this type of study, formal consent is not required. This article does not contain any studies with animals performed by any of the authors.

Informed consent No personally identifiable information is available in this study.

References

1. Huse JT, Edgar M, Halliday J, Mikolaenko I, Lavi E, Rosenblum MK (2013) Multinodular and vacuolating neuronal tumors of the cerebrum: 10 cases of a distinctive seizure-associated lesion. *Brain Pathol* 23(5):515–524. <https://doi.org/10.1111/bpa.12035>
2. Fukushima S, Yoshida A, Narita Y, Arita H, Ohno M, Miyakita Y, Ichimura K, Shibui S (2015) Multinodular and vacuolating neuronal tumor of the cerebrum. *Brain Tumor Pathol* 32(2):131–136. <https://doi.org/10.1007/s10014-014-0198-9>
3. Bodi I, Curran O, Selway R, Elwes R, Burrone J, Laxton R, Al-Sarraj S, Honavar M (2014) Two cases of multinodular and vacuolating neuronal tumour. *Acta Neuropathol Commun* 2:7. <https://doi.org/10.1186/2051-5960-2-7>
4. Louis DN, Perry A, Reifenberger G, von Deimling A, Figarella-Branger D, Cavenee WK, Ohgaki H, Wiestler OD, Kleihues P, Ellison DW (2016) The 2016 World Health Organization classification of tumors of the central nervous system: a summary. *Acta Neuropathol* 131(6):803–820. <https://doi.org/10.1007/s00401-016-1545-1>
5. Nunes RH, da Hsu CC, do Rocha AJ, Amaral LLF, Godoy LFS, Watkins TW, Marussi VH, Warmuth-Metz M, Alves HC, Goncalves FG, Kleinschmidt-DeMasters BK, Osborn AG (2017) Multinodular and vacuolating neuronal tumor of the cerebrum: a new, “Leave Me Alone” lesion with a characteristic imaging pattern. *AJNR Am J Neuroradiol* 38(10):1899–1904
6. Alsufayan R, Alcaide-Leon P, de Tilly LN, Mandell DM, Krings T (2017) Natural history of lesions with the MR imaging appearance of multinodular and vacuolating neuronal tumor. *Neuroradiology* 59(9):873–883. <https://doi.org/10.1007/s00234-017-1884-1>
7. Nagaishi M, Yokoo H, Nobusawa S, Fujii Y, Sugiura Y, Suzuki R, Tanaka Y, Suzuki K, Hyodo A (2015) Localized overexpression of alpha-internexin within nodules in multinodular and vacuolating neuronal tumors. *Neuropathology* 35(6):561–568. <https://doi.org/10.1111/neup.12217>
8. Yamaguchi M, Komori T, Nakata Y, Yagishita A, Morino M, Isozaki E (2016) Multinodular and vacuolating neuronal tumor affecting amygdala and hippocampus: a quasi-tumor? *Pathol Int* 66:34–41
9. Monté AMC, D’Arco F, De Cocker LJJ (2017) Multinodular and vacuolating neuronal tumor in an adolescent with Klinefelter syndrome. *Neuroradiology* 59(12):1187–1188. <https://doi.org/10.1007/s00234-017-1934-8>