

Eight-and-a-half syndrome caused by a pontine hemorrhage: a case report and review of the literature

Nian-ge Xia, Yan-yan Chen, Jia Li, Xi Chen, Zu-sen Ye, Si-yan Chen & Zhen-guo Zhu

To cite this article: Nian-ge Xia, Yan-yan Chen, Jia Li, Xi Chen, Zu-sen Ye, Si-yan Chen & Zhen-guo Zhu (2017): Eight-and-a-half syndrome caused by a pontine hemorrhage: a case report and review of the literature, International Journal of Neuroscience, DOI: [10.1080/00207454.2017.1418344](https://doi.org/10.1080/00207454.2017.1418344)

To link to this article: <https://doi.org/10.1080/00207454.2017.1418344>



Accepted author version posted online: 15 Dec 2017.



Submit your article to this journal [↗](#)



View related articles [↗](#)



View Crossmark data [↗](#)

Publisher: Taylor & Francis

Journal: *International Journal of Neuroscience*

DOI: <https://doi.org/10.1080/00207454.2017.1418344>

Eight-and-a-half syndrome caused by a pontine hemorrhage: a case report and review of the literature.

Nian-ge Xia^a, Yan-yan Chen^a, Jia Li^a, Xi Chen^b, Zu-sen Ye^a, Si-yan Chen^a, Zhen-guo Zhu^a

*

^a Department of Neurology, the First Affiliated Hospital of Wenzhou Medical University, Wenzhou City, Zhejiang province, China.

^b School of Sports Science, Wenzhou Medical University, Wenzhou, 325035, China

*Corresponding author: Zhen-guo Zhu. M.D., Department of Neurology, the First Affiliated Hospital of Wenzhou Medical University, Wenzhou City, Zhejiang province, China. Fax: +86(577)89618235, E-mail: dzhu zg@126.com .

Abstract

Background: Eight-and-a-half syndrome is caused by a lesion in the dorsal tegmentum of the caudal pons involving paraventricular reticular formation (PPRF) and the median longitudinal fasciculus (MLF), as well as the nucleus and/or the fasciculus of the facial nerve. It is characterized by one-and-a-half syndrome and an ipsilateral cranial nerve VII palsy. There are also many variants of eight-and-a-half syndrome has been described, including nine syndrome, thirteen-and-a-half syndrome, and fifteen-and-a-half syndrome. **Methods:** We describe a case of a 49-year-old man who presented with eight-and-a-half syndrome combined with contralateral hemiparesis. We reviewed the literature describing the related spectrum of eight-and-a-half syndrome associated with various etiologies. **Results:** Brain computed tomography (CT) scan revealed a hyperdensity located in the left paramedian aspect of the dorsal pons. T2 weighted MRI at the eleven-month follow-up showed hyperintensity and enlargement of the inferior olivary nuclei, which were compatible with a diagnosis of hypertrophic olivary degeneration. In light of our observations and cases reported in the literature, we categorize the spectrum of eight-and-a-half syndrome into three types, namely classic eight-and-a-half syndrome, eight-and-a-half syndrome variants and eight-and-a-half plus syndrome. Besides, the clinical feature and outcome of the three types are discussed in this article. **Conclusions:** Recognition of the spectrum of eight-and-a-half syndrome allows precise anatomic localization of the lesion to pontine tegmentum region.

Keyword: eight-and-a-half syndrome; pontine hemorrhage; hypertrophic olivary degeneration; nine syndrome; thirteen-and-a-half syndrome; fifteen-and-a-half syndrome.

Introduction

One-and-a-half syndrome was first coined by C. Miller Fisher to describe a combination of horizontal gaze palsy and internuclear ophthalmoplegia caused by a pontine tegmentum lesion involving the median longitudinal fasciculus (MLF) and parapontine reticular formation (PPRF)[1]. The combination of one-and-a-half syndrome plus ipsilateral cranial nerve VII palsy constitutes eight-and-a-half syndrome ($1\frac{1}{2} + 7 = 8\frac{1}{2}$), first described in 1998 by Eggenberger[2]. Various etiologies have been reported, including ischemic stroke[3-8], vasculitis[9], demyelination[10, 11] and brainstem tuberculoma[12]. There are also many variants of eight-and-a-half syndrome, such as nine syndrome[13], thirteen-and-a-half syndrome[14] and fifteen-and-a-half syndrome[15], have been described. In this article, we present an unusual case of eight-and-a-half syndrome combined with contralateral hemiparesis due to the pontine hemorrhage. In addition, we also discuss the related spectrum of eight-and-a-half syndrome through the literature review.

Case report

A 49-year-old man was admitted with a 6-hour history of sudden-onset horizontal diplopia and left hemiparesis. His past medical history included hypertension and type 2 diabetes mellitus. On neurological examination, the patient was alert, fully oriented, and collaborative. Pupils were symmetric (2.5 mm) and reactive to light. Assessment of ocular motility revealed a total right eye horizontal gaze palsy and limitation of adduction of the left eye with horizontal nystagmus on abduction, the left eye abduction and vertical eye movements were normal (Fig. 1a-d). Features consistent with a right sided internuclear ophthalmoplegia. Further examination revealed right lower motor neuron facial palsy (Fig. 1e) associated with upper motor neuron type hemiparesis of his left upper and lower limbs. Rest of the neurologic examination was normal. All serum laboratory values are normal. Brain computed tomography (CT) scan revealed a hyperdensity located in the left paramedian aspect of the dorsal pons (Fig. 1f). The evidence of CT angiography did not suggest the patient suffered from vascular malformations or aneurysms. No further neurological deterioration was documented afterward. On the basis of his clinical features and his neuroimaging, a diagnosis of eight-and-a-half syndrome was confirmed. Due to small size of the blood, only dehydration and blood pressure control were given as initial therapy. The left hemiparesis resolved after two weeks, the left adduction resolved after one month. The neurological examination including right horizontal gaze palsy and facial palsy at the six-month follow-up was mild. Eleven months after the initial stroke, MRI showed hyperintense T2 signal change and hypertrophy in the right inferior olivary nucleus, which was consistent with hypertrophic olivary degeneration (Fig. 2). No palatal tremor was observed.

Discussion

Classic eight-and-a-half syndrome is caused by a lesion in the dorsal tegmentum of the caudal pons involving the PPRF and the MLF, as well as the nucleus and/or the fasciculus of the facial nerve. It is characterized by one-and-a-half syndrome (internuclear ophthalmoplegia in addition to horizontal gaze palsy) and an ipsilateral cranial nerve VII palsy (lower motor neuron type). The affected nuclei may include either a combination of the ipsilateral seventh and sixth nerve nucleus and the ipsilateral MLF or a combination of ipsilateral seventh and ipsilateral PPRF along with the ipsilateral MLF[16]. The eight-and-a-half syndrome is most often caused by infarcts, multiple sclerosis, vasculitis, and brainstem tuberculoma. We report a case of a 49-year-old man who presented with eight-and-a-half syndrome in which brain CT scan revealed a pontine hemorrhage. In addition to eight-and-a-half syndrome, our patient also complained of contralateral hemiparesis may due to the involvement of corticospinal tract caused by the compression of the pontine hemorrhage.

Sometimes eight-and-a-half syndrome also accompanies with other clinical manifestations, such as vertical gaze palsy, hemiparesis or hemiataxia, ipsilateral fifth nerve palsy and contralateral seventh nerve palsy. In light of our observations and the cases reported in the literature, we categorize the spectrum of eight-and-a-half syndrome into three types, namely classic eight-and-a-half syndrome (without accompanied symptoms), eight-and-a-half syndrome variants and eight-and-a-half plus syndrome (Table 1). And eight-and-a-half plus syndrome includes nine syndrome, thirteen-and-a-half syndrome and fifteen-and-a-half syndrome as reported.

Eight-and-a-half syndrome variants includes eight-and-a-half syndrome with vertical gaze palsy and bilateral gaze palsy with unilateral peripheral facial palsy. Marquart et al. reported a case of eight-and-a-half syndrome combined with ipsilateral vertical gaze palsy, which was caused by the blood of the dorsal pons [17]. The ipsilateral vertical gaze palsy may be the result of the impairment of the midbrain reticular formation (MRF) incoming to the left third (subnucleus rectus superi or inferior) in the dorsal tegmentum of midbrain. In 2009, Felicio et al. documented a case of a patient with bilateral horizontal gaze palsy and unilateral peripheral facial paralysis caused by pontine tegmentum infarction. This variant was similar to the classic type of eight-and-a-half syndrome but developed bilateral horizontal gaze palsy [18].

A possible "nine" syndrome was described by Rosini et al. which comprised of eight-and-a-half syndrome with contralateral hemiparesis and hemihyesthesia due to the additional involvement of corticospinal tract and medial lemniscus by pontine infarction [13]. Some cases presented eight-and-a-half syndrome with transient hemiparesis due to the indirect compression of the medulla oblongata [17] or a transient extension of the peri-infarct edema as postulated [19]. In 2015, Mahale et al. reported two cases who presented with clinical features suggestive of eight-and-a-half syndrome along with hemiataxia [20]. One patient was caused by caudal pontine tegmental demyelination with additional involvement of inferior cerebellar peduncle in rostral dorsolateral medulla responsible for ipsilateral hemiataxia. And the other was caused by intracranial hemorrhage of pontine tegmentum with extension into midbrain tegmentum/red nucleus responsible for contralesional hemiataxia. Herein, we present another unusual case of eight and a half syndrome with contralateral hemiparesis due to the pontine hemorrhage. Our patient was similar to the second one of Mahale et al. reported. Therefore, we classify these clinical manifestations, which presented eight and a half syndrome with hemiparesis or hemiataxia, as "nine syndromes".

Combining eight-and-a-half syndrome with ipsilateral trigeminal (fifth) nerve palsy produces thirteen-and-a-half syndrome ($1\frac{1}{2} + 7 + 5 = 13\frac{1}{2}$). This syndrome was first described by Allbon et al. in 2016 [14]. They reported a 50-year-old man who presented with eight-and-a-half syndrome associated with an ipsilateral trigeminal nerve palsy, MRI revealed a lesion in the pons extending into the ipsilateral cerebellar peduncles around the trigeminal nerve, and histopathological examination further confirmed the diagnosis of a lymphoproliferative disorder. This report widened the spectrum of eight-and-a-half syndrome to include a thirteen-and-a-half syndrome variant.

In 2005, Bae et al documented a case of a patient with one-and-a-half syndrome with bilateral seventh nerve palsies caused by pontine infarction, and first described as fifteen-and-a-half syndrome ($1\frac{1}{2} + 7 + 7 = 15\frac{1}{2}$) [15]. They attribute these findings to a bilateral tegmental pontine lesion involving the abducens nucleus or fasciculus, bilateral medial longitudinal fasciculus, and bilateral of the facial nerve fasciculi. This case was similar to the 2001 report of Utku et al. of a case presented with bilateral persistent horizontal gaze palsy and bilateral facial palsy caused by pontine infarction [21]. In 2007, Lee et al also described a new variant of these syndromes in a patient with not only bilateral facial palsy but also complete loss of vertical saccades and pursuit with bilateral horizontal gaze palsy [22].

The outcome of the eight-and-a-half syndrome or its variants and the eight-and-a-half plus syndrome is usually good, with recovery in a few weeks to seven months, especially in the improvement of ocular movement disturbance [12, 15, 17-19, 22, 23]. With regard to our

patient, the adduction of left eye and hemiparesis resolved after one month. The neurological examination including right horizontal gaze palsy and facial palsy at the six-month follow-up was mild. However, only a few cases have no sensible change in the eye movement disorder after more than a half year[24, 25]. And the clinical symptom of the patient reported by Utku et al. was also unimproved after one month of treatment, which may need more times to rehabilitation[21]. Hypertrophic olivary degeneration (HOD) is secondary degeneration of the inferior olivary nucleus due to a primary lesion in the dentato-rubral-olivary pathway (Triangle of Guillain-Mollaret, showed in Fig. 2e). In our case, the hypertrophy of the inferior olivary nucleus is thought to result from the involvement of the central tegmental tract (showed in Fig. 2e). There are few reported cases in the literature, most after pontine hemorrhage but also in combination with eight-and-a-half syndrome and HOD [24, 25]

Conclusions

In conclusion, alongside classic eight-and-a-half syndrome, we should be also aware of its variants and eight-and-a-half plus syndrome. Recognition of the spectrum of eight-and-a-half syndrome allows precise anatomic localization of the lesion to pontine tegmentum region.

Declaration of Interest

There are no financial disclosures or conflict of interest to report. The authors alone are responsible for the content and writing of this paper.

ACCEPTED MANUSCRIPT

References

1. Fisher CM: **Some neuro-ophthalmological observations.** *Journal of neurology, neurosurgery, and psychiatry* 1967, **30**(5):383-392.
2. Eggenberger E: **Eight-and-a-half syndrome: one-and-a-half syndrome plus cranial nerve VII palsy.** *Journal of neuro-ophthalmology : the official journal of the North American Neuro-Ophthalmology Society* 1998, **18**(2):114-116.
3. Nandhagopal R, Krishnamoorthy SG: **Neurological picture. Eight-and-a-half syndrome.** *Journal of neurology, neurosurgery, and psychiatry* 2006, **77**(4):463.
4. Sarwal A, Garewal M, Sahota S, Sivaraman M: **Eight-and-a-half syndrome.** *Journal of neuroimaging : official journal of the American Society of Neuroimaging* 2009, **19**(3):288-290.
5. Kakar P, Brown Z, Banerjee S: **Eight-and-a-half syndrome: an unusual presentation of brainstem infarction.** *QJM : monthly journal of the Association of Physicians* 2013, **106**(3):273-276.
6. Sampath Kumar NS, Raju CG, Kiran PR, Kumar TA, Gopal BV, Khaseem DB: **Eight-and-a-half syndrome: a rare presentation of pontine infarction.** *Journal of stroke and cerebrovascular diseases : the official journal of National Stroke Association* 2014, **23**(8):e389-391.
7. Fernandez Menendez S, Redondo Pobles L, Lara Lezama LB, Tejada Garcia J: **[Eight and a half syndrome caused by a stroke].** *Medicina clinica* 2015, **144**(12):e23.
8. Bocos-Portillo J, Ruiz Ojeda J, Gomez-Beldarrain M, Vazquez-Picon R, Garcia-Monco JC: **Eight-and-a-Half Syndrome.** *JAMA neurology* 2015, **72**(7):830.
9. Zamarbide ID, Maxit MJ: **[Fisher's one and half syndrome with facial palsy as clinical presentation of giant cell temporal arteritis].** *Medicina* 2000, **60**(2):245-248.
10. Mortzos P, Nordling MM, Sorensen TL: **Eight-and-a-half syndrome as presenting sign of childhood multiple sclerosis.** *Journal of AAPOS : the official publication of the American Association for Pediatric Ophthalmology and Strabismus* 2014, **18**(5):490-492.
11. Wanono R, Daelman L, Maarouf A, Caucheteux N, Chaunu MP, Tourbah A: **[Eight and a half plus syndrome as a first presentation of multiple sclerosis].** *Revue neurologique* 2014, **170**(8-9):553-554.

12. van Toorn R, Schoeman JF, Donald PR: **Brainstem tuberculoma presenting as eight-and-a-half syndrome**. *European journal of paediatric neurology : EJPN : official journal of the European Paediatric Neurology Society* 2006, **10**(1):41-44.
13. Rosini F, Pretegiani E, Guideri F, Cerase A, Rufa A: **Eight and a half syndrome with hemiparesis and hemihypesthesia: the nine syndrome?** *Journal of stroke and cerebrovascular diseases : the official journal of National Stroke Association* 2013, **22**(8):e637-638.
14. Allbon DS, La Hood B: **Thirteen-And-A-Half Syndrome**. *Journal of neuro-ophthalmology , the official journal of the North American Neuro-Ophthalmology Society* 2016, **36**(2):191-192.
15. Bae JS, Song HK: **One-and-a-half syndrome with facial diplegia: the 15 1/2 syndrome?** *Journal of neuro-ophthalmology : the official journal of the North American Neuro-Ophthalmology Society* 2005, **25**(1):52-53.
16. Sharpe JA, Rosenberg MA, Hoyt WF, Daroff RB: **Paralytic pontine exotropia. A sign of acute unilateral pontine gaze palsy and internuclear ophthalmoplegia**. *Neurology* 1974, **24**(11):1076-1081.
17. Marquart C, Strauss C, Alfieri A: **Eight-and-a-half syndrome combined with an ipsilateral vertical gaze palsy: a pathophysiological explanation**. *Clinical neurology and neurosurgery* 2013, **115**(6):767-769.
18. Felicio AC, Bichuetti DB, Marin LF, dos Santos WA, Godeiro-Junior C: **Bilateral horizontal gaze palsy with unilateral peripheral facial paralysis caused by pontine tegmentum infarction**. *Journal of stroke and cerebrovascular diseases : the official journal of National Stroke Association* 2009, **18**(3):244-246.
19. Uysal S, Demirtas-Tatlidede A, Selcuk OY, Yayla V: **Diffusion-weighted imaging in eight-and-a-half syndrome presenting with transient hemiparesis**. *Clinical neuroradiology* 2013, **23**(3):235-236.
20. Mahale RR, Mehta A, John AA, Javali M, Abbas MM, Rangasetty S: **"Nine" syndrome: A new neuro-ophthalmologic syndrome: Report of two cases**. *Annals of Indian Academy of Neurology* 2015, **18**(3):335-337.
21. Utku U, Celik Y, Balci K: **Bilaterally persistent horizontal gaze palsy and facial palsy caused by pontine infarction**. *Journal of stroke and cerebrovascular diseases : the official journal of National Stroke Association* 2001, **10**(5):242-243.

22. Lee E, Kim JS, Kim JS, Song HS, Kim SM, Kwon SU: **A small dorsal pontine infarction presenting with total gaze palsy including vertical saccades and pursuit.** *Journal of clinical neurology* 2007, **3**(4):208-211.
23. Xie WJ, Yu HQ, Wang YH, Liu Q, Meng HM: **A case report of eight and a half syndrome.** *Neurological sciences : official journal of the Italian Neurological Society and of the Italian Society of Clinical Neurophysiology* 2016, **37**(5):821-822.
24. Bolen RD, Balakrishnan MDN: **Palatal myoclonus, eight-and-a-half syndrome, and Holmes tremor in a patient from a single brainstem lesion.** *Journal of the neurological sciences* 2014, **347**(1-2):411-412.
25. Wolin MJ, Trent RG, Lavin PJ, Cornblath WT: **Oculopalatal myoclonus after the one-and-a-half syndrome with facial nerve palsy.** *Ophthalmology* 1996, **103**(1):177-180.

ACCEPTED MANUSCRIPT

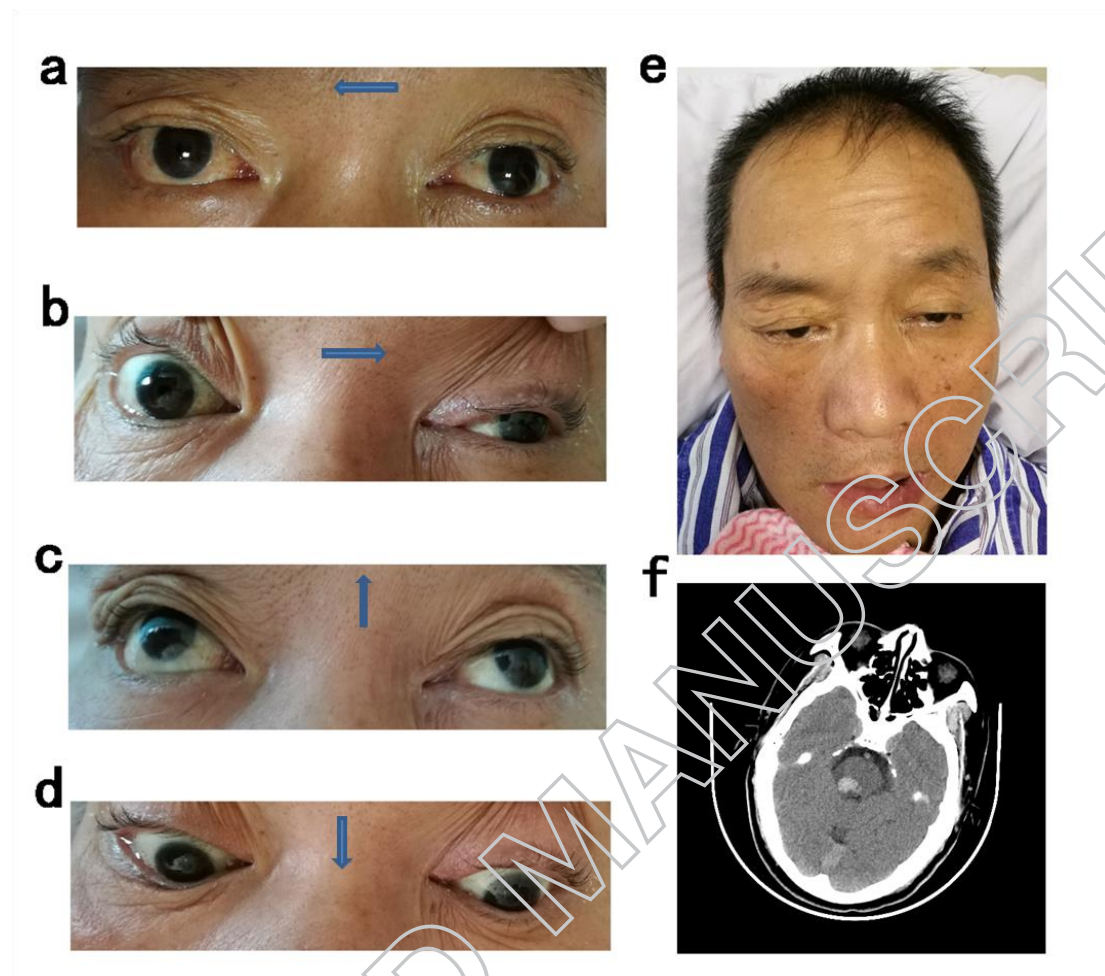


Figure 1 Clinical findings and brain CT imaging. (a–b) Combination of right gaze paresis along with adduction lag in right eye and unimpaired abduction in the left eye (with nystagmus) consistent with right one-and-half syndrome. (c–d) Vertical up and down movements are preserved. (e) Right facial weakness due to a right facial nerve palsy. (f) CT scan without contrast shows a hyperdensity in the right paramedian aspect of the dorsal pons.

ACCEPTED MANUSCRIPT

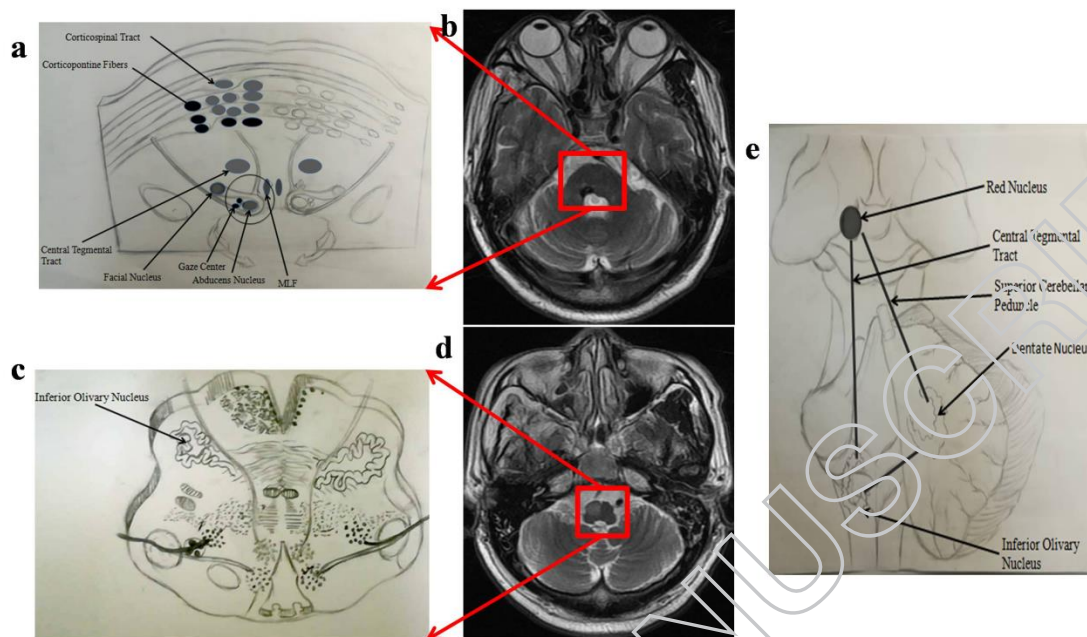


Figure 2 Location of the responsible lesion and Magnetic Resonance Imaging at the eleven-month follow-up. (a) Shown is the anatomical location of the lesion responsible for eight-and-a-half syndrome (round shadow). (b) T2 weighted MRI showed hypointensity of the right dorsal pons. (c, d) T2 weighted MRI showed hyperintensity and enlargement of the inferior olivary nuclei, which were compatible with a diagnosis of hypertrophic olivary degeneration. (e) Diagram of the Guillain-Mollaret Triangle. Interruption of the afferent pathways (central tegmental tract) to the inferior olive may cause hypertrophic olivary degeneration.

Table.1 Classification of the spectrum of eight-and-a-half syndrome. Note : PPRF: paramedian pontine reticular formation. MLF: medial longitudinal fasciculus. MRF, midbrain reticular formation.

Subtypes and variants	Lesion	Etiology
Classic eight-and-a-half syndrome		
One-and-a-half syndrome and ipsilateral facial palsy, $1\frac{1}{2} + 7 = 8\frac{1}{2}$	The dorsal tegmentum of the caudal pons involving the PPRF, MLF and the nucleus or the fasciculus of the facial nerve.	Ischemic stroke[3-8]; demyelinating[10, 11]; infection[12]; vasculitis[9].
Eight-and-a-half syndrome variants		
Eight-and-a-half syndrome with vertical gaze palsy	The dorsal tegmentum of pons and midbrain, involving the PPRF, MLF, MRF and the nucleus or the fasciculus of the facial nerve.	hemorrhage[17].
Bilateral gaze palsy with unilateral peripheral facial palsy.	The midline pontine tegmentum	Ischemic stroke[18].
Eight-and-a-half plus syndrome		
Nine syndrome: Eight and a half syndrome with hemiparesis or hemiataxia	the pons, additional involvement of corticospinal tract; or additional involvement of inferior cerebellar peduncle in the ipsilateral rostral dorsolateral medulla or midbrain tegmentum/red nucleus.	Ischemic stroke[13] ; Demyelination[20] ; Hemorrhage[20].
Thirteen-and-a-half Syndrome (eight-and-a-half syndrome plus ipsilateral fifth nerve palsy, $1\frac{1}{2} + 7 + 5 = 13\frac{1}{2}$)	the pons, extending into the ipsilateral cerebellar peduncles around the trigeminal nerve	Lymphoproliferative disorder[14]
Fifteen-and-a-half Syndrome (One-and-a-half syndrome with bilateral seventh nerve palsy, $1\frac{1}{2} + 7 + 7 = 15\frac{1}{2}$)	a bilateral tegmental pontine, involving the unilateral abducens nucleus or fasciculus, bilateral MLF and intraaxial fasciculi of the facial nerve	Ischemic stroke[15].
Fifteen-and-a-half Syndrome Variants		

<p>Bilaterally horizontal gaze palsy and facial palsy</p>	<p>paramedian tegmental region at the midpontine level involving the seventh cranial nerve nucleus and/or fascicle and sixth cranial nerve nuclei.</p>	<p>Ischemic stroke[21].</p>
<p>Bilaterally horizontal gaze palsy and facial palsy with vertical gaze palsy</p>	<p>the pons, the involvement of lesions of omnipause neurons in the nucleus raphe interpositus, bilateral fascicles of facial nuclei, MLF, bilateral abducens fascicles, and/or PPRF.</p>	<p>Ischemic stroke[22].</p>

ACCEPTED MANUSCRIPT