

Memory Functioning Following a Left Medial Thalamic Hematoma*

Gregory G. Brown, Stuart Kieran, and Suresh Patel

Departments of Psychiatry, Neurology, and Diagnostic Radiology,
Henry Ford Hospital, Detroit.

ABSTRACT

A patient with a discrete, left medial thalamic hematoma developed a severe anterograde amnesia. The memory deficit was most consistent for verbal materials, but was also observed on several tests of figural memory. The patient appeared to have a normal short-term memory (STM) capacity, performed normally on a STM distractor task and was not abnormally sensitive to proactive inhibition. This case is evidence that unilateral damage to the medial thalamus alone can produce a severe memory deficit.

Clinicopathological studies of patients with alcoholic Korsakoff syndrome suggest that damage to the medial thalamus, particularly the dorsomedial nucleus (DM) of the thalamus, might cause the amnesia seen in that disease (Martin, 1974; Victor, Adams, & Collins, 1971). Reports of memory impairments involving patients with a variety of focal lesions support the belief that damage to the medial thalamus can cause severe memory dysfunction (Ignelzi & Squire, 1976; Michel, Laurent, Foyatier, Blanc, & Portafaix, 1982). However, in reviewing cases of amnesia associated with thalamic damage, Markowitsch (1982) found that the lesions in most cases also involved cortical structures, other subcortical nuclei, or white-matter tracts surrounding the thalamus. For example, the well-known case of a fencing foil injury to the left DM probably also involved the orbital-frontal cortex, neostriatum, the rostrum of the corpus callosum and white matter near the thalamus (Squire & Moore, 1979). Patients with alcoholic Korsakoff syndrome also have lesions outside of the medial thalamus. Post-mortem studies have nearly always found extensive bilateral nerve cell loss and gliosis of the mammillary bodies, in addition to involvement of DM (Gamper, 1928; Victor, et al., 1971). In the two cases of alcoholic Korsakoff syndrome reported by Mair, Warrington, and Weiskrantz (1979), the mammillary bodies were involved to a greater extent than were the dorsomedial

* This study was in part supported by funds from NINCDS grant NS23393-01 to the Stroke Center, Henry Ford Hospital. We wish to thank Steven Levine for his helpful comments on an early draft and Lawrence M. Binder for scoring the Rey-Osterrieth Complex Figure.

Address correspondence to: Gregory G. Brown, Ph.D., Neuropsychology Division, Henry Ford Hospital (K-11), 2799 W. Grand Blvd., Detroit, MI 48202, USA.

nuclei. Since Markowitch's review, several cases of infarction of the medial thalamus have been reported (Graff-Radford, Damasio, Yamada, Eslinger, & Damasio, 1985; Michel et al., 1982; Rousseaux et al. 1986). Some of these reports are limited by the presence of lesions existing outside of the thalamus. Others are limited by a minimal behavioral analysis of the memory deficits observed. Two cases of material-specific memory deficits following unilateral infarction restricted to the medial thalamus were thoroughly studied by Speedie and Heilman (1982, 1983). But each patient had a history of psychopathology. The case with the left thalamic lesion was a paranoid schizophrenic, while the 64-year-old male with the right thalamic infarction had a long-standing depression. Since schizophrenia and depression can both impair memory functioning (Koh, 1978; Stromgren, 1977) the effects of neuropathology and psychopathology are confounded in each case. The material-specific nature of the memory dysfunction might appear to discount explanations based on psychopathology. However, some investigators have reported that schizophrenia might affect verbal functions more than visuospatial ones, while affective disorder might have the reverse effect (Flor-Henry, 1976).

Extrathalamic damage or psychopathology has been reported among virtually all previous cases of amnesia associated with lesions of the medial thalamus. Consequently, the relevance that damage to the medial thalamus has for amnesia remains uncertain. This paper is a report of memory functioning after a discrete, left-medial thalamic hematoma, occurring in a patient with no history of psychopathology. Memory for daily events was severely impaired and performance on verbal memory tasks that involved long-term memory processing was poor. To facilitate comparison with alcoholic Korsakoff syndrome, the patient was examined by methods used to study alcoholic Korsakoff patients. We also administered tests useful in investigating material-specific memory deficits.

CASE REPORT

History and Neurological Examination

J.E. was a 69-year-old, right-handed Black male with 12 years of education who was a retired postal clerk when he experienced a sudden onset of "confusion" on 1/3/86. The patient's wife noticed the confusion as she drove him home from an outpatient biopsy of the prostate. He was slightly drowsy and had memory problems throughout the day; his wife took him to the emergency room the following day. There was no previous history of neurologic disease. His medical history was significant only for glaucoma and urolithiasis. In particular he had no history of hypertension or heart disease; his prostate biopsy revealed normal tissue.

Initial examination showed him to be oriented to person and time, but not to place. He was slightly lethargic, but easily arousable. He was unable to

remember any of three objects in 5 minutes; did not remember the prostate biopsy from the previous day; and had a patchy memory for remote events in his life. Naming, repetition, fluency, comprehension, reading, and writing were all normal. Motor functioning was intact; he could distinguish left from right on his body. Although pain, touch, proprioception, graphesthesia, two-point discrimination, and stereognosis were intact, J.E. tended to ignore the right side of the body on double-simultaneous stimulation. The following day, his alertness and ability to recognize stimulation on the right side of the body improved. His memory deficits persisted.

An EEG performed on the day of admission was significant only for some depression of sleep spindle activity in the left hemisphere. This finding was interpreted as an underlying disturbance within the thalamocortical radiation system, possibly involving the thalamus. Other features of the EEG record were compatible with J.E.'s age.

Neuropsychological Assessment

General Neuropsychological Functioning. J.E.'s initial neuropsychological assessment was performed on 1/28/86, three and one-half weeks after the ictus. Form II of the WMS was administered on 3/5/86, the day of his nuclear magnetic resonance imaging study. On the WAIS-R this patient's FSIQ was 95, while his VIQ was 92 and his PIQ was 101. The patient performed consistently within the normal range across the various IQ subtests. All but two of the patient's age-corrected scores varied between 8 and 11. His Picture Arrangement score was 12, while his Comprehension score was a 7. On this latter subtest the patient's answers were often insufficiently specific to merit credit. J.E. performed well on the Wisconsin Card Sorting Test obtaining all 6 concepts and making only 14 errors. He also scored well on the Facial Recognition Test (Benton, Hamsher, Varney, & Spreen, 1983), where he obtained a projected, long-form score of 49. Using Taylor's criteria, J.E. obtained a score of 32 when copying the Rey-Osterrieth design (See Figure 1a). His performance placed him at the 40th to 50th centile (Lezak, 1983, p. 401), and was more typical of the performance of normal controls than of cases with right or left hemispheric stroke (Binder, 1982).

Language Functioning. J.E.'s speech was fluent with normal phrase length, prosody, and grammar. There were no paraphasias in his conversational speech. His auditory comprehension was normal; he scored at the 90th to 100th centile on three of the four components of the auditory comprehension subtest of the Boston Diagnostic Aphasia Examination (Goodglass & Kaplan, 1983). He scored only at the 65th centile on the complex ideational component, but his poor performance on that test occurred only for the comprehension of story paragraphs, where his memory deficit may have limited his performance. J.E.'s speech comprehension also fell within the normal range on the 36-item version of the Tokens Test (DeRenzi & Faglioni, 1978), where he obtained a score of 32

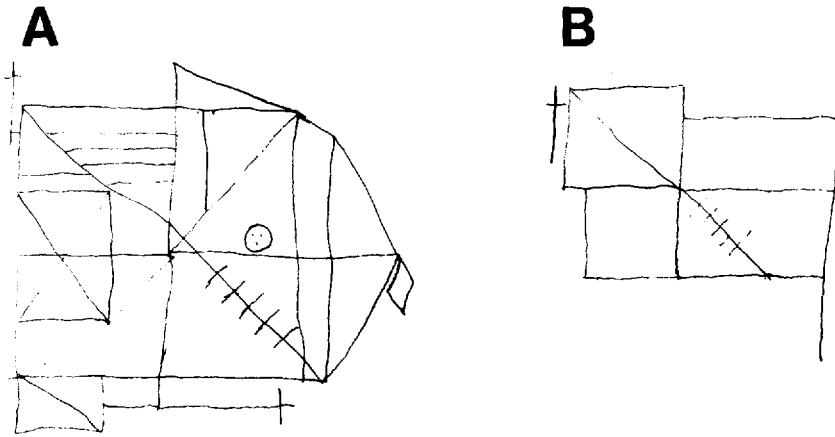


Fig. 1. J.E.'s performance on the Rey-Osterrieth Complex Figure Test (a) copy, (b) recall, 45-minute delay.

(adjusted for education). The patient's repetition was intact; he performed perfectly on both the low and high probability items of the repetition subtest of the Boston Diagnostic Aphasia Examination. J.E. earned a score of 32 (adjusted for age, sex, and education) on the FAS version of the Controlled Oral Word Association Test (Lezak, 1976). This performance placed him in the bottom quarter to one-third of the normal population. J.E. obtained a score of 55 on the Boston Naming Test, indicating intact confrontational naming (Kaplan, Goodglass, & Weintraub, 1983). Overall, the patient's language functioning was normal.

Memory Functioning. The patient's Wechsler Memory Quotient was 86. He was oriented to person, place, and time, but had some trouble remembering the President of the United States prior to Reagan and difficulty remembering the current Governor of Michigan. J.E. recalled 6 digits forward and 4 reversed. He recalled seven pieces of information from the Visual Reproduction subtest, an above average performance when his score is compared with individuals of similar age (Hulicka, 1966). His scores of 2.25 on the Logical Memory paragraphs and 4.5 on the Associative Learning items indicate a severe level of dysfunction, when compared with age-peers. After a 20-minute delay, the patient recalled only 33% of the original information that he remembered from the logical paragraphs, but 57% of the information from visual reproduction. J.E.'s scores on Form II of the WMS, performed on 3/5/86, were very similar to his Form I scores, from 1/28/86. He was severely impaired on the Immediate (3.5) and Delayed Recall of Prose (0%). He again recalled only easy word pairs, earning an impaired score of 4.0. His memory for geometric designs was again much better than his memory for verbal material with an Immediate Recall score

of 13 and a percentage retained of 54%.

His performance on Form 1 of Hannay and Levin's version of the Selective Reminding Task (Hannay & Levin, 1985) was also dramatically impaired. We analyzed these results both from Buschke's framework (Buschke, 1973) and from the framework of the Search of Associative Memory theory (Raaijmakers & Shiffrin, 1981). After correcting for age and sex, J.E. earned a score of 73 on the long-term store parameter and a score of 25 for consistent long-term memory retrieval. When compared with individuals age 60-64, these scores fell at the 4th and 2nd centile, respectively (Larabee & Levin, 1984). On later trials, J.E. typically retrieved three or four items from short-term memory, an abnormally large number of short-term memory retrievals. Together these results suggest that J.E. had a pathological tendency to rely on short-term memory mechanisms to retain items.

The results of the selective reminding task were also analyzed by fitting the parameters of a model based on the Search of Associative Memory theory to J.E.'s scores (Raaijmakers & Shiffrin, 1981). A simulation of performance on the selective reminding task was developed. We estimated the values of three parameters: r - the capacity of the short-term memory buffer, a - the increment in the strength of association between item and context during each rehearsal period, and $kmax$ - the maximum number of consecutive rehearsal failures a subject will tolerate before terminating memory retrieval. The parameter values were determined by a search through a large segment of three-parameter space. Performance on the Selective Reminding Task was simulated 100 times for each triplet of parameter values. Each simulation produced a matrix representing correct (scored 1) and incorrect (scored 0) recall for each of the 12 items on each of the 12 trials. The concordance between each cell of the matrix produced by a simulation and each cell from J.E.'s matrix was determined by performing an exclusive-or on the two values. When homologous cells from the two matrices agreed (0, 0 or 1, 1), the exclusive-or equaled 0, otherwise it equaled 1. The extent to which the two matrices agreed was determined by summing the results of the exclusive-or performed on each of the 144 pairs of cells. The values that minimized the average summed exclusive-or, computed for the 100 simulations, were chosen as the estimates of the three parameters. The average estimates for each parameter were: $r = 3.85$, $a = 0.04$, $kmax = 7.14$. While the result for r , the capacity of the STM buffer, was similar to 4, the value typically reported in the SAM literature for young, healthy subjects (Raaijmakers & Shiffrin, 1981), the values of the other two parameters are low. Low values on a and $kmax$ would suggest both a deficit in encoding contextual associations and a premature closure of memory search. The results from the model suggested that J.E. probably had a normal STM capacity, but was impaired on aspects of long-term memory functioning. These results converge with those from the analysis based on Buschke's framework.

The patient's short-term memory functioning was further studied on two short-term memory (STM) distractor tasks. The first required J.E. to recall

consonant trigrams after counting backwards by one for zero, three, nine, or eighteen seconds (Cermak, Butters, & Goodglass, 1971). The second fixed the counting interval at 9 seconds and required J.E. to recall three words from the same semantic category on four consecutive trials. The semantic category was switched on the fifth trial, permitting an assessment of the release from proactive inhibition (Cermak, Butters, & Moreines, 1974). Table 2 contains J.E.'s scores as well as those of eight aged-matched controls (mean age = 65.6 years, mean education = 11.6 years). The controls displayed a buildup of proactive inhibition (Pi) on trials 1 to 4, with a release from Pi on trial 5. J.E. performed normally for the memory of trigrams and showed no appreciable buildup of proactive inhibition. (See Table 1).

Table 1

Short-Term Memory Distractor Tasks

Consonant Trigrams		Replications Recalled ^a		Consonants Recalled ^b	
Interval		<i>JE</i>	<i>Controls</i>	<i>JE</i>	<i>Controls</i>
0s		10	7.9	30	25.5
3s		6	5.8	26	24.8
9s		7	3.3	26	17.2
18s		7	2.4	25	14.6
Pi Paradigm ^c		Words Recalled ^d			
Trial		<i>JE</i>	<i>Controls</i>		
1		15	13.2		
2		14	10.6		
3		13	8.4		
4		14	8.0		
5 (release trial)		12	12.5		

a - 10 trigrams at each distractor interval

b - 30 consonants total

c - the release from proactive inhibition (Pi) paradigm

d - 15 words total, 5 triads per trial

J.E. was given Rausch's version of Kimura's Recurring Figures Test, which omits the geometric designs from Kimura's stimuli (Personal Communication to K. M. Adams, June 28, 1984). J.E. obtained a score of 7, indicating a severely impaired performance; his errors were generally misses. His performance on the Rey-Osterrieth Designs was both sparse and inaccurate after a 45-minute delay (see Figure 1b).

J.E.'s remote memory was assessed on two subtests of the Boston Remote Memory Battery (Albert, Butters, & Levin, 1979). We compared J.E.'s scores with the healthy elderly controls from Wilson, Kaszniak, and Fox's (1981) study. These subjects were elderly, community volunteers with a mean age of 69.4

Table 2

Two Subtests of the Boston Remote Memory Battery

Difficulty Level	Percent Correct ^a	Decade					
		1920	1930	1940	1950	1960	1970
Famous Faces							
Easy	88 (60)	4	4	3	2	4	4
Hard	58 (35)	4	3	3	2	1	1
Verbal Recall							
Easy	42 (50)	2	1	1	4	1	1
Hard	33 (35)	2	2	0	1	1	2

Note. Maximum Score for each entry by decade = 4

a-the percentages in parentheses are values for age-matched controls (R. S. Wilson, personal communication, June, 1986).

years and an average educational attainment of 13.2 years. As reported in Table 2, J.E.'s scores were better than controls on both the easy and hard items from Famous Faces and similar to controls on Verbal Recall. J.E. appeared to have a gradient on the hard items of the Famous Faces Test, where his recall was progressively worse for more recent information.

In summary, J.E. demonstrated an anterograde memory deficit for verbal and geometric material, when the amount of material recalled was large relative to his short-term memory capacity or when he had to recall the material after the elapse of several minutes. In distinction, his verbal short-term memory functioning was intact. J.E. appeared to have no consistent remote memory deficit; despite the appearance of a gradient on the hard items of the Famous Faces Test, his overall scores on tests of remote memory were normal.

Neuroradiologic Findings

Computerized tomography (CT) of the head was performed on 1/6/86. It showed a left, medial thalamic hematoma, surrounded by minimal edema (see Figure 2). There was no contrast enhancement. Some blood was present in the body of the left lateral ventricle. The third ventricle and septum pellucidum fell along the midline; there was no obstructive hydrocephalus. A cerebral angiogram performed three days after admission showed no evidence of an arteriovenous malformation, aneurysm, or major vessel disease.

J.E. had a magnetic resonance imaging scan on 3/5/86, two months after his admission. The study was performed on a 1.5 tesla magnet. Serial T₁ weighted images (TR600, TE25) were obtained in the sagittal plane using a partial saturation technique. Subsequently, spin echo techniques were used to obtain T₂ weighted images (TR2500, TE25, 70, 75, 100) in coronal, axial, and sagittal planes. The T₁ weighted image showed a small, low-intensity lesion in the

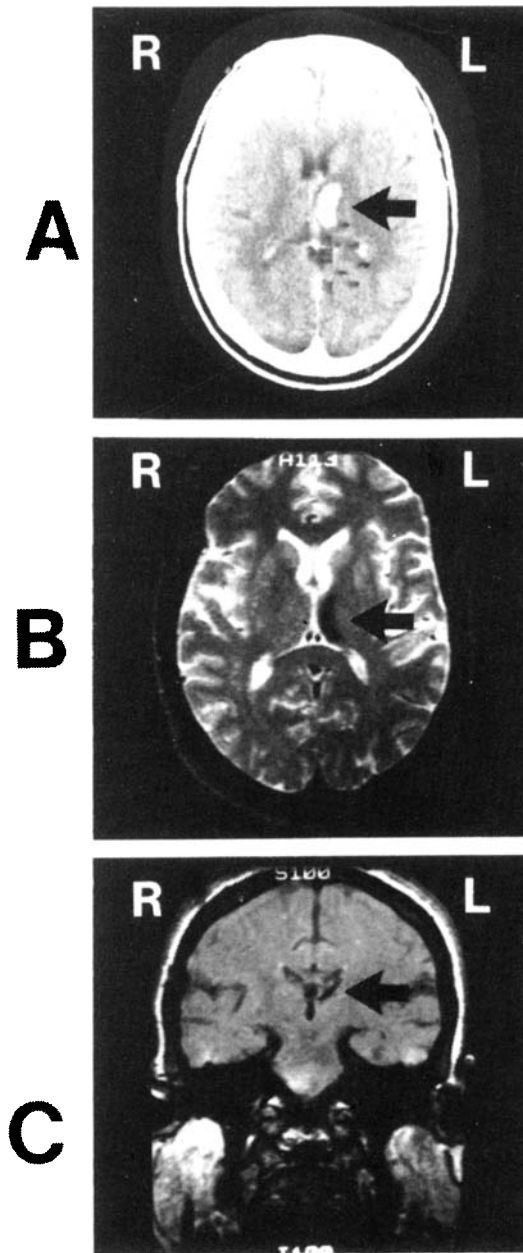


Fig. 2. (a) CT scan of medial thalamic hemorrhage, axial cut (b) NMR imaging scan showing involvement of anterior and dorsomedial thalamic nuclei, axial cut (c) NMR image of a coronal view of the left thalamus.

medial, superior thalamic region involving mainly the dorsomedial thalamic nucleus. On the T₂ weighted, axial images, a low intensity signal was seen in the same region of the medial left thalamic region as the T₁ weighted lesion. (See Figure 2.) Most of the lesion spans the dorsomedial thalamic nucleus, but some of the anterior nucleus is also involved. Much of the pulvinar was spared, as were more lateral nuclei. The findings were compatible with the resolved or resolving hematoma, with hemosiderin deposition, seen on the CT scan. Views of the hippocampus, mammillary bodies, and the region ventral to the anterior commissure (including the substantia innominata) appeared normal. There was no evidence of edema, mass effects, or blood in the ventricles.

DISCUSSION

This case supports the thesis that damage to the thalamus alone can produce a severe memory deficit. Although some edema of surrounding white matter was noted on the CT performed acutely, the magnetic resonance imaging studies performed two months later showed no chronic changes in the area of the edema. In reviewing cases of amnesia associated with thalamic damage, Markowitsch (1982) found that the lesions in most cases also involved cortical structures, other subcortical nuclei, or white matter tracts surrounding the thalamus. In our case, NMR imaging studies showed no abnormalities in the cortex, hippocampus, mammillary bodies, or the region ventral to the anterior commissure. Except during the acute period, the white matter surrounding the thalamus, including nearby segments of the fornix, also appeared normal. The area of damage in J.E. seemed well restricted to the thalamus.

The hematoma in this case primarily involved the dorsomedial thalamic nucleus. However, the anterior thalamic nucleus and part of the anterior portion of the internal medullary lamina were also involved. Whether damage occurred to adjacent pulvinar or adjacent intralaminar nuclei could not be determined and remains a possibility. The involvement of the anterior nucleus in this case is compatible with Markowitsch's view that memory impairment accompanies damage to dorsomedial thalamic nucleus only if some other limbic nucleus is involved. Involvement of both nuclei coincides with the results from animal studies, which show that combined lesions of anterior and posterior medial thalamic regions produce a greater impairment of visual object recognition than damage to either region alone (Appleton & Mishkin, 1983a, 1983b).

Markowitsch's hypothesis, based on anatomical data, may have a broader metabolic corollary. Some patients with subcortical lesions have a metabolic depression of ipsilateral caudate and cortex, as measured by the method of ¹⁸F-fluorodeoxyglucose, positron emission computed tomography (Metter et al., 1983). In particular, case N.A. with a fencing foil injury to the left dorsomedial thalamic nucleus showed a depression of glucose metabolism throughout the left hemisphere (Metter et al., 1983). Although our patient did not have

metabolic studies, sleep spindles occurring only in the left hemisphere were observed in his scalp EEG. These observations suggested a cortical effect of his thalamic lesion. Speedie and Heilman's (1983) case of right thalamic infarction also had asymmetrical slowing of his EEG on the side ipsilateral to his infarction. If this depression of cortical metabolism is associated with depression of cortical functioning, then extrathalamic metabolic effects could contribute to the memory deficit associated with thalamic damage.

Despite finding that J.E. was as impaired as patients with alcoholic Korsakoff syndrome on the logical memory and paired associates subtests of the WMS, his short-term memory functioning was normal. In particular, he rehearsed three to four words on a verbal, multi-trial, list-learning task; performed normally following 9 and 18 s of distracting activity on an STM distractor task; and was resistant to the buildup of proactive inhibition. Each of these three findings distinguishes him from many cases of alcoholic Korsakoff syndrome (Brown, Rosenbaum, Lewis, & Rourke, 1980; Cermak et al., 1971; Cermak et al., 1974; Cermak, Naus, & Reale, 1976). The differences between J.E. and alcoholic Korsakoff patients in short-term memory functioning cannot be explained by method variance. Both the STM trigram task and the release from proactive inhibition task followed the procedure used by Cermak and Butters in their studies of alcoholic Korsakoff patients (Cermak et al., 1971; Cermak et al., 1974). Rather, bilateral thalamic damage or lesions outside the medial thalamus might very well cause the poorer STM functioning of patients with alcoholic Korsakoff syndrome. In particular, Moscovitch (1982) has argued that an abnormal sensitivity to P1 can be found among patients with frontal-lobe dysfunction.

We found only weak evidence of a material-specific, anterograde, memory deficit. J.E. performed better on the visual reproduction subtest of the WMS, than on the recall of prose or word pairs. However, his delayed recall of geometric designs was impaired. Further, the patient was severely impaired on the Kimura Recurring Figures Task, a test performed well by Speedie and Heilman's case of left DM infarction. Although J.E. performed poorly, his error pattern was uncharacteristic of cases of right temporal lobectomy (Kimura, 1967). While lobectomy cases make a large number of false alarms, J.E.'s errors were misses. His poor performance on this task might be attributable to a conservative response bias, rather than a figural memory deficit. Consequently the basis of J.E.'s poor performance on some tests of figural memory was unclear.

J.E. had a gradient on the hard items from the Famous Faces Test. This finding is compatible with the view that damage to the medial thalamus might be responsible for the remote memory gradient observed in alcoholic Korsakoff syndrome. At least two factors vitiate this hypothesis. While patients with alcoholic Korsakoff syndrome show a gradient on both the easy and hard items of the Famous Faces and Verbal Recall tests, J.E. had a gradient on only one of these four conditions. Further, remote memory deficits have not been routinely

observed in other cases of left medial thalamic damage whose remote memory was studied (Cohen & Squire, 1981; Michel et al., 1982; Speedie & Heilman, 1982). The generality of the one gradient that we found is probably limited. J.E. did perform relatively worse on the Verbal Recall subtest than the Famous Faces subtest. This finding raises the possibility of a material-specific remote memory deficit.

Future studies of the effects of thalamic damage on memory should include measures of functional neuronal activity, in addition to an anatomical description of the lesion. Such studies are needed to understand the role that abnormalities in neuronal activity outside of the thalamus make to the amnesia associated with thalamic damage.

REFERENCES

- Appleton, J. P., & Mishkin, M. (1983a). Visual recognition impairment following medial thalamic lesions in monkeys. *Neuropsychologia*, *21*, 189-197.
- Appleton, J. P., & Mishkin, M. (1983b). Memory impairments following restricted medial thalamic lesions in monkeys. *Experimental Brain Research*, *52*, 199-209.
- Albert, M. S., Butters, N., & Levin, J. (1979). Temporal gradients in the retrograde amnesia of patients with alcoholic Korsakoff's disease. *Archives of Neurology*, *36*, 211-216.
- Benton, A. L., Hamsher, K. de S., Varney, N. R., & Spreen, O. (1983). *Contributions to neuropsychological assessment: A clinical manual* (pp. 30-43). New York: Oxford.
- Binder, L. M. (1982). Constructional strategies on complex figure drawings after unilateral brain damage. *Journal of Clinical Neuropsychology*, *4*, 51-58.
- Brown, G. G., Rosenbaum, G., Lewis, R., & Rourke, D. (1980). The effects of rehearsal rate on serial recall in Korsakoff amnesia. *Neuropsychologia*, *18*, 185-191.
- Buschke, H. (1973). Selective reminding for analysis of memory and learning. *Journal of Verbal Learning and Verbal Behavior*, *12*, 543-550.
- Cermak, L. S., Butters, N., & Goodglass, H. (1971). The extent of memory loss in Korsakoff patients. *Neuropsychologia*, *9*, 307-315.
- Cermak, L. S., Butters, N., & Moreines, J. (1974). Some analyses of the verbal encoding deficit of alcoholic Korsakoff patients. *Brain and Language*, *1*, 141-150.
- Cermak, L. S., Naus, M. J., & Reale, L. (1976). Rehearsal strategies of alcoholic Korsakoff patients. *Brain and Language*, *3*, 375-385.
- Cohen, N. J., & Squire, L. R. (1981). Retrograde amnesia and remote memory impairment. *Neuropsychologia*, *19*, 337-356.
- DeRenzi, E., & Faglioni, P. (1978). Normative data and screening power of a shortened version of the Token Test. *Cortex*, *4*, 41-49.
- Flor-Henry, P. (1976). Lateralized temporal-limbic dysfunction and psychopathology. *Annals of the New York Academy of Science*, *280*, 777-795.
- Gamper, E. (1928). Zur Frage der Polioencephalitis haemorrhagica der chronischen Alkoholiker. Anatomische Befunde beim chronischen Korsakow und ihre Beziehungen zum klinischen Bild. *Deutsche Zeitschrift für Nervenheilkunde*, *102*, 122-129.
- Goodglass, H., & Kaplan, E. (1983). *Assessment of aphasia and related disorders*. Philadelphia: Lea & Febiger.

- Graff-Radford, N. R., Damasio, H., Yamada, T., Eslinger, P. J., & Damasio, A. R. (1985). Non-haemorrhagic thalamic infarction: Clinical neuropsychological and electrophysiological findings in four anatomical groups defined by computerized tomography. *Brain*, *108*, 485-516.
- Hannay, H. J., & Levin, H. S. (1985). Selective Reminding Test: An examination of the equivalence of four forms. *Journal of Clinical and Experimental Neuropsychology*, *7*, 251-263.
- Hulicka, I. M. (1966). Age differences in Wechsler Memory Scales scores. *Journal of General Psychology*, *109*, 135-145.
- Ignelzi, R. J., & Squire, L. R. (1976). Recovery from anterograde and retrograde amnesia after precutaneous drainage of a cystic craniopharyngioma. *Journal of Neurology, Neurosurgery and Psychiatry*, *39*, 1231-1235.
- Kaplan, E., Goodglass, H., & Weintraub, S. (1983). *Boston Naming Test*. Philadelphia: Lea & Febiger.
- Kimura, D. (1967). Right temporal lobe damage. *Archives of Neurology*, *3*, 163-178.
- Koh, S. D. (1978). Remembering of verbal materials by schizophrenic young adults. In S. Schwartz (Ed.), *Language and cognition in schizophrenia* (pp. 55-89). New York: Lawrence Erlbaum Associates.
- Larrabee, G. J., & Levin, H. S. (1984, February). *Verbal, visual and remote memory test performance in a normal elderly sample*. Paper presented at the meeting of the International Neuropsychology Society, Houston, TX.
- Lezak, M. (1976). *Neuropsychological assessment*. New York: Oxford.
- Lezak, M. D. (1983). *Neuropsychological assessment* (2nd ed.) New York: Oxford.
- Mair, W. G. P., Warrington, E. K., & Weiskrantz, L. (1979). Memory disorder in Korsakoff's psychosis: A neuropathological and neuropsychological investigation of two cases. *Brain*, *102*, 749-783.
- Markowitsch, H. J. (1982). Thalamic mediodorsal nucleus and memory: A critical evaluation of studies in animals and man. *Neurosciences and Biobehavioral Reviews*, *6*, 351-380.
- Martin, J. J. (1974). Thalamic system atrophies in Gayet-Wernicke's polioencephalopathy. *Acta Neurologica Belgica*, *74*, 25-35.
- Metter, E. J., Riege, W. H., Hanson, W. R., Kuhl, D. E., Phelps, M. E., Squire, L. R., Wasterbain, C. G., & Benson, D. F. (1983). Comparison of metabolic rates, language, and memory in subcortical aphasias. *Brain and Language* *19*, 33-47.
- Michel, D., Laurent, B., Foyatier, N., Blanc, A., & Portafaix, M. (1982). Infarctus thalamique paramedian gauche. *Revue Neurologique*, *138*, 533-550.
- Moscovitch, M. (1982). Multiple dissociations of functions in amnesia. In L. S. Cermak (Ed.), *Human memory and amnesia* (pp. 337-370). Hillsdale, NJ: Lawrence Erlbaum Associates.
- Raaijmakers, J. G. W., & Shiffrin, R. M. (1981). Search of associative memory. *Psychological Review*, *88*, 93-134.
- Rousseaux, M., Cabaret, M., Lesoin, F., Devos, P., Dubois, F., & Petit, H. (1986). Bilan de l'amnesie des infarctus thalamiques restreints - 6 cas. *Cortex*, *22*, 213-228.
- Speedie, L., & Heilman, K. (1982). Amnesic disturbance following infarction of the left dorsomedial nucleus of the thalamus. *Neuropsychologia*, *20*, 597-604.
- Speedie, L., & Heilman, K. (1983). Anterograde memory deficits for visuospatial material after infarction of the right thalamus. *Archives of Neurology*, *49*, 183-186.
- Squire, L. R., & Moore, R. Y. (1979). Dorsal thalamic lesions in a noted case of chronic

- memory dysfunction. *Annals of Neurology*, 6, 503-506.
- Stromgren, L. S. (1977). The influence of depression on memory. *Acta Psychiatrica Scandinavica*, 56, 109-128.
- Victor, M., Adams, R. D., & Collins, G. H. (1971). *The Wernicke-Korsakoff Syndrome*. Philadelphia: F. A. Davis.
- Wilson, R. S., Kaszniak, A. W., & Fox, J. H. (1981). Remote memory in senile dementia. *Cortex*, 17, 41-48.