

CASE REPORT

Auditory agnosia caused by bilateral putamen haemorrhage

Tomohito Sugiura, Tsuyoshi Torii

Department of Neurology,
National Hospital Organization
Kure Medical Center, 3-1
Aoyama, Kure city, Japan

Correspondence to

Dr Tomohito Sugiura,
sugiurat@kure-nh.go.jp and Dr
Tsuyoshi Torii, toriit@kure-nh.
go.jp

Accepted 7 December 2017

SUMMARY

A 55-year-old right-handed man with a history of hypertension suddenly fell and developed right hemiparesis. Neurological examination revealed that he was alert, but did not appropriately respond to verbal questions and commands. Detailed examination revealed that he could correctly respond to written commands. His speech was almost fluent, showing no paraphasia and normal articulation. His written sentences were legible. Pure tone audiometry showed that his auditory acuity was relatively preserved. His brainstem auditory evoked potential components from I to V were recorded bilaterally with normal latency. Cerebral CT demonstrated fresh bleeding in the left putamen and an old haemorrhage on the opposite side. He was treated by antihypertensive therapy and rehabilitation. Although there remained mild sensory deficit on his right extremities and he felt a slight noise during conversation, he had little difficulty with verbal communication when he was transferred to another hospital on day 38.

BACKGROUND

This report highlights auditory agnosia caused by stroke. It is a rare manifestation and is easily misdiagnosed as sensory aphasia.

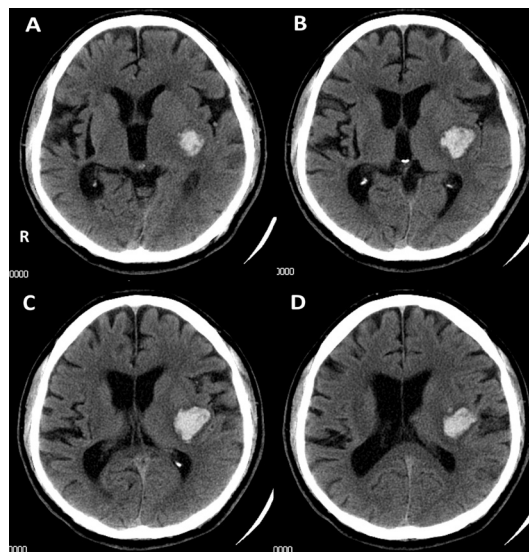


Figure 1 Brain CT image on admission. There was fresh haemorrhage in the left putamen. The bleeding expanded over the putamen slight posteriorly and laterally, but it did not apparently involve the transverse temporal or superior temporal gyri (A–D). An old haemorrhage in the right putamen was also apparent (A–C).

Auditory agnosia or cortical deafness generally refers to a condition that is characterised by defective comprehension of both verbal and environmental sounds despite a preserved hearing ability. Currently, auditory agnosia is divided into four categories: pure word deafness, pure auditory non-verbal agnosia, phonagnosia and pure amusia.¹ There may be one or a mixture of these deficits.

There have been some reports and studies about this interesting symptom,^{2,3} and the causative lesion is now thought to be bilateral transverse temporal gyri (Heschl's gyri) or auditory radiations. Cerebrovascular diseases are the most commonly reported cause.^{4,5} Among patients who had general stroke, however, auditory agnosia is a very rare manifestation.⁶

Here, we report a patient with auditory agnosia that involved word deafness, which was caused by bilateral putamen haemorrhage.

CASE PRESENTATION

A 55-year-old right-handed man with a history of hypertension suddenly fell and developed right hemiparesis, for which he was admitted to our hospital. He also had an old haemorrhage in the right putamen 7 years ago and had recovered without any disabilities. On admission, the general physical examination was normal except that his blood pressure was 144/88 mm Hg. Neurological examination revealed that he was alert, but did not appropriately respond to verbal questions and commands. Right mild hemiparesis and sensory deficit were apparent. Detailed examination revealed that he could correctly respond to written commands. His speech was almost fluent, showing no paraphasia and normal articulation. Repetition was difficult, but naming and reading were normal. He had messy writing because of right-sided weakness, although his written sentences were legible. There was no other abnormality including apraxia, visual agnosia and unilateral spatial neglect. He spoke about his own symptom as, 'I realise that someone has told me something, but I cannot understand what they said. It sounded like some noise'. He also mentioned that the ambulance ran without a siren during his transport.

INVESTIGATIONS

Auditory recognition tests showed that he was not able to discriminate most vowels such as 'a' or 'u'. Discriminating polysyllabic words was slight better than vowels because only one syllable of the word



To cite: Sugiura T, Torii T. *BMJ Case Rep* Published Online First: [please include Day Month Year]. doi:10.1136/bcr-2017-222535

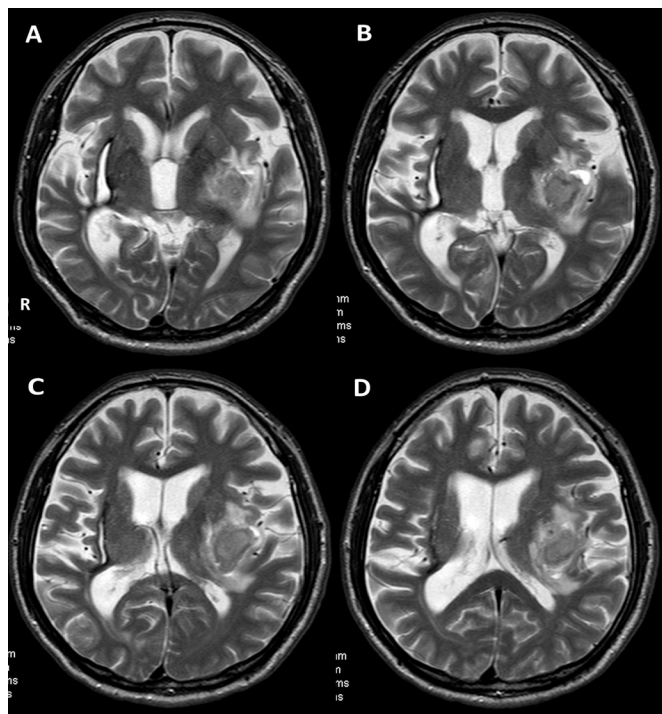


Figure 2 Brain MRI on day 9. There was subacute haemorrhage in the left putamen on T2-weighted image (A–D). The size of lesion was not so different from the CT image on admission. The mild surrounding oedema remained.

which he was able to recognise might help his understanding. In contrast to listening words, his auditory acuity seemed to be relatively preserved, for example, he responded well to a noise such as cracking a finger. His speech ability was almost spared. He was capable of explaining scenes of photo cards. Laboratory findings were almost normal. Cerebral CT demonstrated fresh bleeding in the left putamen and an old haemorrhage on the opposite side (figure 1).

TREATMENT

He was treated by antihypertensive therapy and rehabilitation.

OUTCOME AND FOLLOW-UP

His symptom gradually improved during the first week. A standard language test of aphasia (SLTA) on day 9 revealed that the percentage of correct answers was 95% in hearing but some repeats and cues were necessary for him to answer. Cerebral MRI on the same day showed subacute left putamen haemorrhage with mild surrounding oedema on T2-weighted image (figure 2). Subsequent otological examination revealed no abnormality in his tympanic membrane. Pure tone audiometry on day 10 showed a mild bilateral sensorineural hearing loss. His speech reception threshold and speech discrimination ability in the right and left ears were 37 dB and 50 dB, 60% and 20%, respectively. These results improved to 20 dB and 20 dB, 95% and 65%, respectively on day 30. His brainstem auditory evoked potential (BAEP) components from I to V were recorded bilaterally with normal latency.

Although there remained mild sensory deficit on his right extremities and he felt a slight noise during conversation, he had little difficulty with verbal communication when he was transferred to another hospital on day 38.

Learning points

- ▶ Auditory agnosia including word deafness may mimic sensory aphasia at initial presentation. Because reading ability is preserved, written commands help to distinguish these two symptoms.
- ▶ Agnosia of environmental sounds or music is not as apparent as word deafness. Active assessment may be required in these cases.
- ▶ Most cases of auditory agnosia are caused by bilateral temporal lobe lesion. However, bilateral putamen lesion may also cause this symptom.
- ▶ Prognosis of auditory agnosia which caused by stroke vary in patients. Long-term rehabilitation may be required for improvement.

DISCUSSION

The hearing problem in this patient was an impairment of understanding verbal sounds, whereas auditory acuity and BAEP response were relatively preserved. These findings indicated that this symptom was word deafness and was attributed to a cerebral auditory pathway, which involved primary auditory cortices, auditory radiations and medial geniculate bodies. Most cases of auditory agnosia were caused by bilateral temporal lobe lesion.⁷ However, the CT finding in this patient demonstrated bilateral putamen haemorrhage. This indicated that auditory radiations near putamen caused his symptom. There are few reports of image analysis about basal ganglia lesion and auditory agnosia.^{8,9} According to one report, the white matter immediately ventral and lateral to the posterior half of the putamen may be a causative lesion,⁹ and this patient seemed to have a similar condition (figure 1). It is possible that this region might be important to the neural network in auditory radiation and for word deafness.

His word deafness gradually improved and he was able to communicate verbally within 1 month. There are a few case reports which describe prognosis of auditory agnosia.^{5,6} Some patients do improve partially and others do not within several months. It is thought that the size of lesion and the surrounding oedema are related to the duration of the disability, permanent or non-permanent. However, the brain MRI in this case showed the oedema still remained despite beginning improvement on day 9. This implies the surrounding oedema is not so important for causing symptom.

This patient did not recognise some environmental sounds in the acute phase, for example, sirens of the ambulance or chimes in the hospital. This symptom disappeared in the first week and we could not test auditory recognition about environmental sounds before the recovery. He did not complain of phonagnosia or amusia. However, other than word deafness, patients are not often aware of the symptom of auditory agnosia, so that active assessment may be required.

In conclusion, bilateral putamen haemorrhage may cause auditory agnosia including word deafness. Close attention to the symptom and the brain image is important for appropriate diagnosis and treatment.

Contributors Both authors assessed and managed this case. TS conceived the idea of writing the case, obtained informed consent from the patient and drafted the first version of the manuscript. TT edited the article.

Competing interests None declared.

Patient consent Obtained.

Provenance and peer review Not commissioned; externally peer reviewed.

© BMJ Publishing Group Ltd (unless otherwise stated in the text of the article) 2017. All rights reserved. No commercial use is permitted unless otherwise expressly granted.

REFERENCES

- 1 Robert BD, Joseph J, John CM, *et al.* *Bradley's neurology in clinical practice*. 7th edn. Amsterdam: Elsevier, 2015.
- 2 Graham J, Greenwood R, Lecky B. Cortical deafness—a case report and review of the literature. *J Neurol Sci* 1980;48:35–49.
- 3 Dick F, Saygin AP, Galati G, *et al.* What is involved and what is necessary for complex linguistic and nonlinguistic auditory processing: evidence from functional magnetic resonance imaging and lesion data. *J Cogn Neurosci* 2007;19:799–816.
- 4 Shindo M. Cortical deafness and auditory agnosia. *Clin Neurosci* 2006;24:518–20.
- 5 Ishii K, Ueda Y, Ohkoshi N, *et al.* Cortical auditory disorder caused by bilateral temporal infarctions. *Intern Med* 1995;34:801–5.
- 6 Murayama H, Matsuo S, Nishimura N, *et al.* Two cases of cortical deafness and auditory agnosia with bilateral temporal lesions. *Jpn J Stroke* 2010;32:190–6.
- 7 Kaga K, Takegoshi H, Hayashi A. Central auditory information processing in patients with bilateral auditory cortex or auditory radiation – sounds of speech, music and environment. *Higher Brain Function Research* 2008;28:224–30.
- 8 Kaga K, Kurauchi T, Nakamura M, *et al.* Magnetoencephalography and positron emission tomography studies of a patient with auditory agnosia caused by bilateral lesions confined to the auditory radiations. *Acta Otolaryngol* 2005;125:1351–5.
- 9 Tanaka Y, Kamo T, Yoshida M, *et al.* 'So-called' cortical deafness. Clinical, neurophysiological and radiological observations. *Brain* 1991;114:2385–401.

Copyright 2017 BMJ Publishing Group. All rights reserved. For permission to reuse any of this content visit <http://group.bmj.com/group/rights-licensing/permissions>.

BMJ Case Report Fellows may re-use this article for personal use and teaching without any further permission.

Become a Fellow of BMJ Case Reports today and you can:

- ▶ Submit as many cases as you like
- ▶ Enjoy fast sympathetic peer review and rapid publication of accepted articles
- ▶ Access all the published articles
- ▶ Re-use any of the published material for personal use and teaching without further permission

For information on Institutional Fellowships contact consortiasales@bmjgroup.com

Visit casereports.bmj.com for more articles like this and to become a Fellow