

Symptomatic hemidystonia of delayed onset. Magnetic resonance demonstration of pathology in the putamen and the caudate nucleus

R. Midgard¹, J. A. Aarli¹, O.-J. Julsrud²,
H. Ødegaard³

Departments of Neurology, ¹University of Bergen,
²Molde County Hospital, ³Radiology,
Rogaland Central Hospital, Stavanger, Norway

ABSTRACT - We present a case of symptomatic hemidystonia of delayed onset. The primary disease was a perinatal, presumed cerebrovascular infarction brought about by febrile illness with convulsions 12 weeks after partus. After many years without neurological symptoms, the hemidystonia started in adolescence, and became stationary after 4 years of mild progression. Magnetic resonance imaging revealed atrophy of the right striatum including the caudate nucleus and putamen. The symptoms responded moderately to treatment with benzhexol.

Accepted for publication July 18, 1988

Dystonic movements are sustained, involuntary twisting contractions which distort limbs, trunk, neck, face, or mouth into characteristic postures (1). The movements can be generalized, segmental, or focal. They are initially brought out on action, but may after some time become continuous and even present at rest (2).

The dystonias are classified into idiopathic and symptomatic states (1, 3). The idiopathic conditions include hereditary torsion dystonia, dystonias associated with hereditary neurological diseases, and sporadic idiopathic dystonias. The symptomatic conditions include dystonias where the specific disease is known or suspected.

Dystonia of delayed onset in patients with "static" encephalopathy was described by Burke, Fahn, and Gold (4). They point out this entity as an important diagnostic alternative to dystonia musculorum deformans.

We report a case of delayed-onset hemidystonia secondary to a presumed cerebrovascular lesion in the basal ganglia in childhood. New imaging technique has enabled more accurate localization of the lesion.

Case Report

A 28-year-old man was submitted for diagnostic consideration due to persisting dystonic movements of his left arm and leg.

He was born at full term after a normal pregnancy. The delivery was uncomplicated. The family trees of parents revealed no inter-marriage, and there were no known family disorders of neurological or other nature.

At the age of 12 weeks he was seriously ill with a febrile disorder of unknown etiology. The illness lasted 3 weeks and included

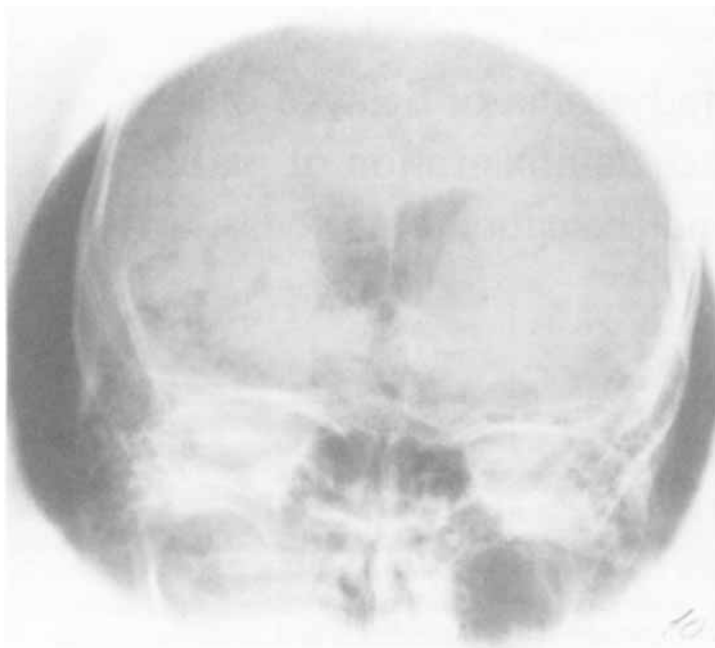


Fig. 1. Pneumoencephalography illustrating the increased septum-caudatus distance on the right side.

convulsions. Neurological deficits were not detected during the acute illness, and development was apparently normal thereafter.

At the age of 13 he gradually noticed increasing clumsiness of his left hand. He also noticed slow, involuntary movements of the fingers. When doing light exercises, his left foot became plantarflexed in an equinovarus posture.

The dystonic symptoms gradually increased, and minor muscular efforts would elicit alternating, slow involuntary movements of flexion and extension in his left shoulder girdle, arm, and fingers. Plantarflexion and inversion of his left foot became prominent on walking. The involuntary movements disappeared during rest. Diazepam was of no help, however, intake of alcohol reduced the movements.

After 4 years slow, gradual progression, the disease became stationary at the age of 17. He was then moderately disabled, and the involuntary sustained and twisting movements varied with physical activity, excitement, and rest/sleep.

A neurological examination at the age of 19 revealed involuntary, dystonic movements of his left arm and leg, and these increased during mild

exercise. Mental state, cranial nerves, speech, gait, cerebellar testing, deep tendon reflexes, and sensation were normal. Ophthalmological investigation revealed no Kayser-Fleischer rings. Psychiatric evaluation was normal. Biochemical routine studies including serum copper, complete blood count, cerebrospinal fluid, and urine analyses were normal. Electroencephalography was normal, while simultaneous electromyography of agonist and antagonist muscles of the leg showed lack of relaxation of the antagonist during contraction. No spontaneous activity could be detected.

Pneumoencephalography in July 1978 (Fig 1) showed an increased septum-caudatus distance on the right side, while sella media and the anterior and temporal horns on the left side were moderately enlarged. The third ventricle was dilated. Cerebral computer tomography in August 1978 showed slightly enlarged right anterior horn and sella media. A small area of low attenuation in the right temporo-parietal region was also seen.

Another neurological examination at the age of 27 revealed rigidity in his left arm and leg,

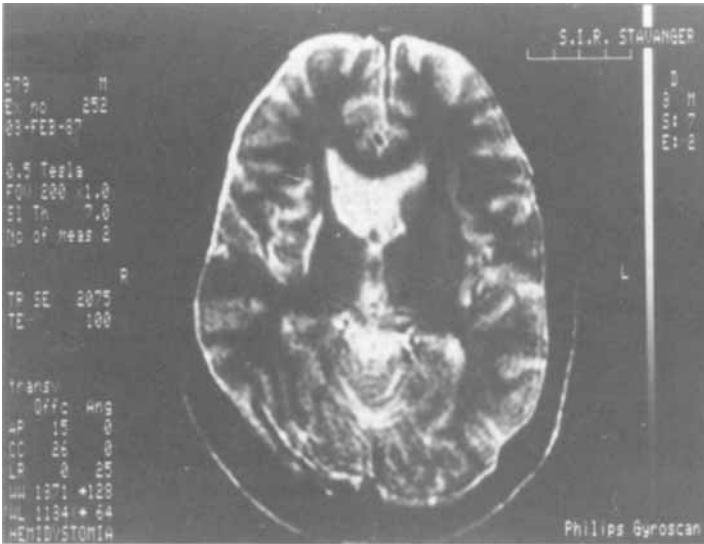


Fig. 2 A Magnetic resonance imaging showing localized atrophy of the head of the caudate nucleus.

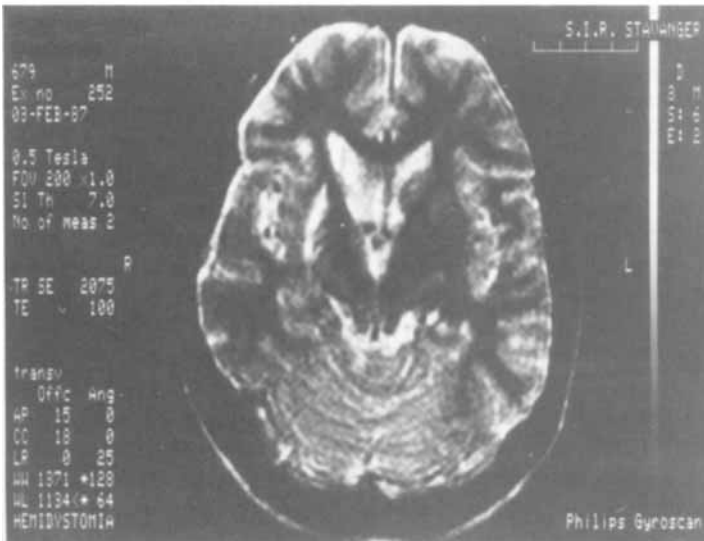


Fig. 2 B MRI showing localized atrophy of the putamen on the right side. Pontes grisei are clearly visualized.

with increased muscle tone most pronounced in his wrist, elbow, and shoulder muscles. Involuntary movements were not present at rest. The left foot was plantarflexed in equinovarus position, and there was a slight paresis on dorsiflexion in his left ankle. On walking, his equinovarus posturing became even more obvious, and his left arm was flexed at the elbow in a spastic manner. The examination did not reveal any other neurological deficits.

Magnetic resonance imaging of the brain (Figs. 2 A, B) showed localized atrophy of the right striatum. The process included the head of the caudate nucleus and the putamen, clearly visualizing the pontes grisei.

Propranolol (maximum dose 360 mg/24h) and tetrabenazine (maximum dose 75 mg/24 h) had little effect, while benzhexol/trihexyphenidyl (maximum dose 18 mg/24 h) in gradually increasing doses improved his condition slightly.

The muscle tone and the rigidity were reduced, and the dystonic movements were less prominent than prior to anticholinergic medication. Side effects were of no importance.

Discussion

Symptomatic hemidystonia may accompany various diseases in the basal ganglia. Zeman and Whitlock (5) and Roos and Bruyn (6) have reviewed the symptomatic dystonias, and included perinatal cerebral lesions, encephalitis, demyelinating disorders, trauma, cerebrovascular diseases, tumors, metabolic diseases, and drug-induced conditions as possible causes of secondary dystonia.

The most frequent causes are ischemic, vascular lesions (7-9). They may occur as results of a thrombotic event. Exact localization of the lesion responsible for dystonia was previously dependant upon post-mortem studies. Dooling and Adams (10) performed pathological anatomical studies in 5 patients with involuntary movements following hemiplegia. The stroke occurred in childhood, and was eventually followed by athetoid movements. The vascular lesion destroyed the dorsolateral part of the caudate nucleus, and the dorsolateral or lateral part of the putamen. Loss of striatopallidal fibres was a prominent feature.

Obliteration of the lenticulo-striate arteries leads to ischemia of the caudate nucleus, the putamen, and in some cases, also the anterior limb of the internal capsule. When the lesion is large, thalamus and the subthalamic nucleus may also be involved, giving rise to hemiplegia and hemiballism (syndrome of Déjerine-Roussy). More often, however, the lesions are relatively limited, and cause contralateral dystonia of focal or segmental distribution. This points to the fact that hemidystonia is connected with a lesion in the contralateral striatum (2). A febrile illness is often the preceding incident.

Leigh's disease (11), arteriovenous malformations (12), tumors (13), and migraine accompagnée (14) have all been reported to give hemidystonia.

The pathophysiological mechanisms behind the dystonias are presumably abnormal thalamic

input to the premotor cortex, due to lesions of the thalamus, striatum or its afferents (15). Relatively intact corticospinal pathways are necessary for the dystonic movements to take place.

Although the event leading to the disorder takes place in childhood, it is well known that the dystonia may appear gradually, often years later and in association with puberty. The delayed onset and persisting nature of the dystonia must be due to some morphological and neurochemical change which take place in the aftermath of the insult (4). Collateral sproutings in the CNS have been demonstrated in monoaminergic and cholinergic systems (16, 17), and this is possibly the cause of delayed-onset dystonia.

Classic neuroimaging techniques have usually been of little help in localizing the lesion *in vivo*. Magnetic resonance imaging offers new opportunities in visualizing the lesions in the brain (11).

Our patient underwent a presumed vascular lesion in the basal ganglia during childhood. The lesion came in connection with a febrile illness with convulsions. Some years later he developed a hemidystonic state. MRI localized the lesion precisely to the head of the nucleus caudatus and the putamen.

Earlier pathological-anatomical studies (10) connect lesions in the putamen, the caudate nucleus, the striatopallidal fibres, and partly the descending cortical motor pathways with movement disorders similar to dystonia. Computed imaging techniques mainly correlate lesions in the putamen with involuntary, dystonic movements (11, 18, 19). Our case shows lesions in the putamen as well as in the head of the caudate nucleus. This supports a hypothesis indicating that a lesion of the putaminal structure is an important part of the pathogenetic mechanism of dystonia.

References

1. Fahn S, Eldridge R. Definition of dystonias and classification of the dystonic states. In: Eldridge R, Fahn S, eds. *Advances in neurology*, Vol 14. New York: Raven Press, 1976: 1-5.
2. Marsden CD, Obeso JA, Zarranz JJ, Lang AE. The anatomical basis of symptomatic hemidystonia. *Brain* 1985;108:463-483.

3. Fahn S, Jankovic J. Classification of extrapyramidal disorders. *Neurologic Clinics* 1984;2:561-566.
4. Burke RE, Fahn S, Gold AP. Delayed-onset dystonia in patients with "static" encephalopathy. *J Neurol Neurosurg Psychiatry* 1980;43:789-797.
5. Zeman W, Whitlock CC. Symptomatic dystonias. In: Vinken RJ, Bruyn GW, eds. *Handbook of clinical neurology*, Vol 6. Diseases of the basal ganglia. Amsterdam: North-Holland, 1968: 544-566.
6. Roos RAC, Bruyn GW. Symptomatic dystonias. In: Vinken PJ, Bruyn GW, Klawans HL, eds. *Handbook in clinical neurology*, Vol 5 (49). Extrapyramidal disorders. Amsterdam: Elsevier, 1986: 541-547.
7. Demierre B, Rondot P. Dystonia caused by putamino-capsulocaudate vascular lesions. *J Neurol Neurosurg Psychiatry* 1983;46:404-409.
8. Russo LS. Focal dystonia and lacunar infarction of the basal ganglia. A case report. *Arch Neurol* 1983;40:61-62.
9. Grimes JD, Hassan MH, Quarrington AM, D'Alton J. Delayed-onset posthemiplegic dystonia: CT demonstration of basal ganglia pathology. *Neurology (Ny)* 1982;32:1033-1035.
10. Dooling EC, Adams RD. The pathological anatomy of posthemiplegic athetosis. *Brain* 1975;98:29-48.
11. Burton K, Farrell K, Li D, Calne DB. Lesions of the putamen and dystonia: CT and magnetic resonance imaging. *Neurology* 1984;34:962-965.
12. Friedman DI, Jankovic J, Rolak LA. Arteriovenous malformation presenting as hemidystonia. *Neurology* 1986;36:1590-1593.
13. Narbona J, Obeso J A, Tunon T, Martinez-Lage JM, Marsden CD. Hemidystonia secondary to localized basal ganglia tumor. *J Neurol Neurosurg Psychiatry* 1984;47:704-709.
14. Obeso JA, Martinez Vila E, Delgado G, Vaamonde J, Maravi E, Martinez-Lage JM. Delayed onset dystonia following hemiplegic migraine. *Headache* 1984;24:266-268.
15. Pettigrew LC, Jankovic J. Hemidystonia: a report of 22 patients and a review of the literature. *J Neurol Neurosurg Psychiatry* 1985;48:650-657.
16. Bjørklund A, Stenevi U. Nerve growth factor: stimulation of regenerative growth of central noradrenergic neurons. *Science* 1972;175:1251-1253.
17. Svendgaard N, Bjørklund A, Stenevi U. Regeneration of central cholinergic neurons in the adult rat brain. *Brain Res* 1976;102:1-22.
18. Fross RD, Martin WRW, Li D, et al. Lesions of the putamen: their relevance to dystonia. *Neurology* 1987;37:1125-1129.
19. Merchut MP, Brumlik J. Painful tonic spasms caused by putaminal infarction. *Stroke* 1986;6:1319-1321.

Address

Rune Midgard

Department of Neurology

Molde County Hospital

N-6400 Molde

Norway