

Improvement of Respiratory Depression in a Patient with Primary Medullary Hemorrhage Following Removal of Hematoma in the Half-sitting Position

Shinya Ichimura^{1,2} Helmut Bertalanffy² Masato Nakaya¹ Yoichi Mochizuki¹ Raita Fukaya¹
 Goroku Moriwaki³ Masahito Fukuchi¹ Koji Fujii¹

¹Department of Neurosurgery, Shizuoka City Shimizu Hospital, Shizuoka, Japan

²Department of Neurosurgery, International Neuroscience Institute Hannover, Hannover, Germany

³Department of Anesthesiology, Shizuoka City Shimizu Hospital, Shizuoka, Japan

Address for correspondence Shinya Ichimura, MD, Department of Neurosurgery, Shizuoka City Shimizu Hospital, 1231 Miyakami Shimizu-Ku Shizuoka-City, Shizuoka 424-8636, Japan (e-mail: shinya3917@gmail.com).

J Neurol Surg A

Abstract

Primary medullary hemorrhage is a rare event that may result in ataxic respiration. Although it remains controversial whether primary medullary hemorrhage should be managed conservatively or surgically, recent advancements in neuroimaging and microsurgical techniques have shown promise for improving outcomes and prognosis following surgery. The present report discusses the case of a 70-year-old woman admitted to our institution due to sudden-onset nausea and vomiting. The patient underwent surgical removal of a right medullary hematoma for the treatment of daytime respiratory depression and nocturnal apnea while in the half-sitting position. Following surgery, her spontaneous respiration improved, and she was discharged with independent gait. Despite the risk of venous air embolism, accumulating evidence suggests that the half-sitting position is suitable for brainstem surgery because gravity-assisted blood and irrigation drainage from the surgical field allows for cleaner dissection and reduces the need for bipolar coagulation.

Keywords

- ▶ primary medullary hemorrhage
- ▶ respiratory depression
- ▶ half-sitting position

Introduction

Spontaneous primary medullary hemorrhage is a rare event that may result in abnormal respiration due to damage of the respiratory center within the reticular formation of the medulla oblongata and pons.¹ We discuss the case of a patient with medullary hemorrhage whose respiratory depression improved following hematoma removal in the half-sitting position.

Patient

A 70-year-old woman was referred to our department due to sudden-onset nausea and vomiting. She reported no relevant

medical or surgical history, although she had not seen a doctor for quite some time. Neurologic examination revealed that the patient was alert and presented without motor paresis. However, right tongue deviation due to right hypoglossal nerve palsy was observed. Her blood pressure was 201/100 mm Hg. Computed tomography (CT) revealed hemorrhage in the right medulla (▶ Fig. 1).

Following admission, she developed daytime respiratory depression (< 10 breaths per minute) and nocturnal apnea. She was then intubated, and her breathing was managed using a ventilator. T2- and T2*-weighted magnetic resonance imaging (MRI) revealed no apparent causes of hemorrhage

received

June 19, 2017

accepted after revision

November 8, 2017

© Georg Thieme Verlag KG
 Stuttgart · New York

DOI <https://doi.org/10.1055/s-0037-1615296>.
 ISSN 2193-6315.

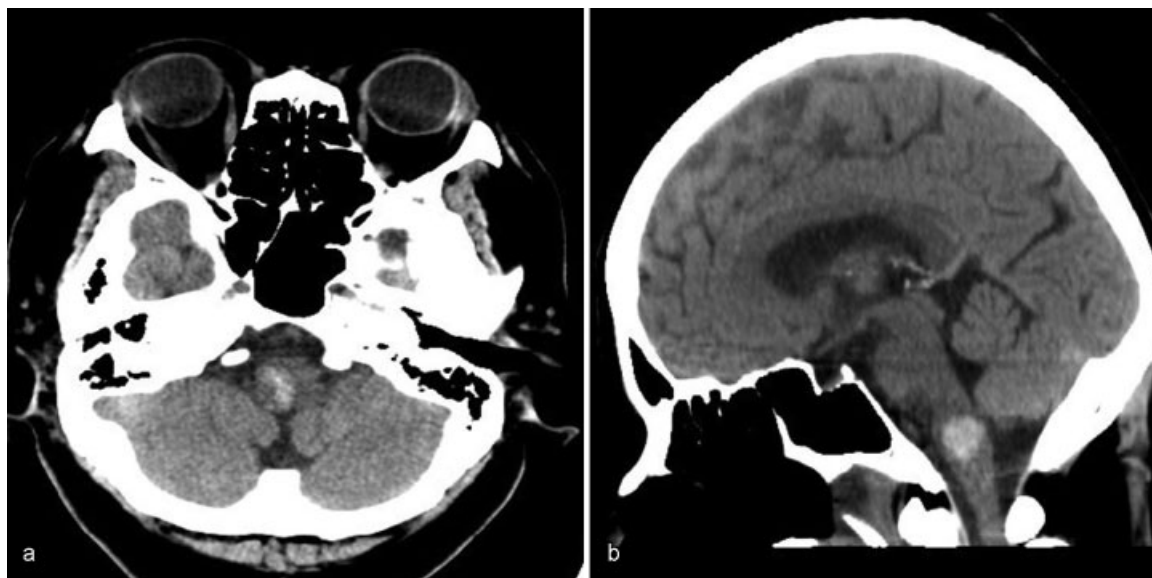


Fig. 1 Computed tomography images showing right medullary hemorrhage. (a) Axial. (b) Sagittal.

such as cavernous malformation, arteriovenous malformation, or tumor (►Fig. 2). The patient was subsequently diagnosed with primary medullary hemorrhage due to hypertension, following which she was treated via continuous intravenous administration of calcium channel blockers to lower her blood pressure. No improvement in the patient's respiratory depression was observed.

Therefore, she underwent surgery via a midline suboccipital approach in the half-sitting position 3 days after admission (►Fig. 3). Following suboccipital craniotomy, the cisterna magna was opened, and the tonsil and uvula of the vermis were retracted. A hematoma was observed in the right medulla oblongata (►Fig. 4a) and removed via irrigation. Following removal of the hematoma, the swelling in the medulla oblongata decreased (►Fig. 4b). Intraoperative neurophysiologic

monitoring (motor-evoked and sensory-evoked potentials) remained unchanged. There was no evidence of pathology such as cavernous malformation during the surgery. Postoperative CT revealed complete removal of the hematoma (►Fig. 5).

Following surgery, her spontaneous respiration improved to > 15 breaths per minute. She was weaned from ventilatory support on postoperative day 5 and extubated on postoperative day 6. Postoperative MRI 5 weeks after surgery showed no structural abnormality (►Fig. 6). Although she still exhibited right tongue deviation, she was discharged with independent gait following rehabilitation without further complications. She was alert and had no neurologic deficit except right tongue deviation at 3 months after surgery. She had been followed in our outpatient clinic for 3 months after discharge while undergoing outpatient rehabilitation.

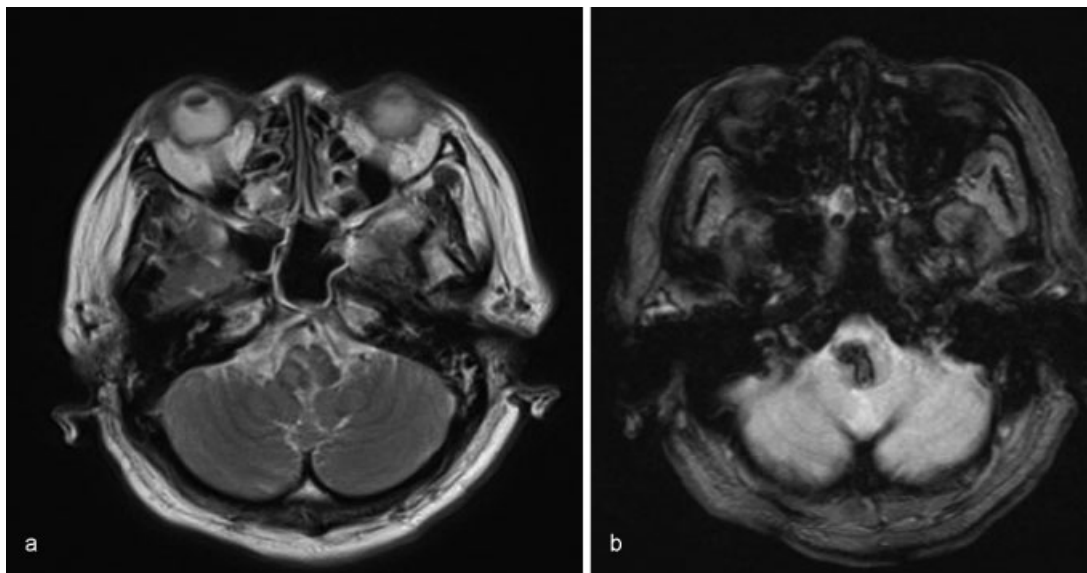


Fig. 2 Magnetic resonance images revealed no apparent pathologic causes of hemorrhage. (a) T2 weighted. (b) T2* weighted.

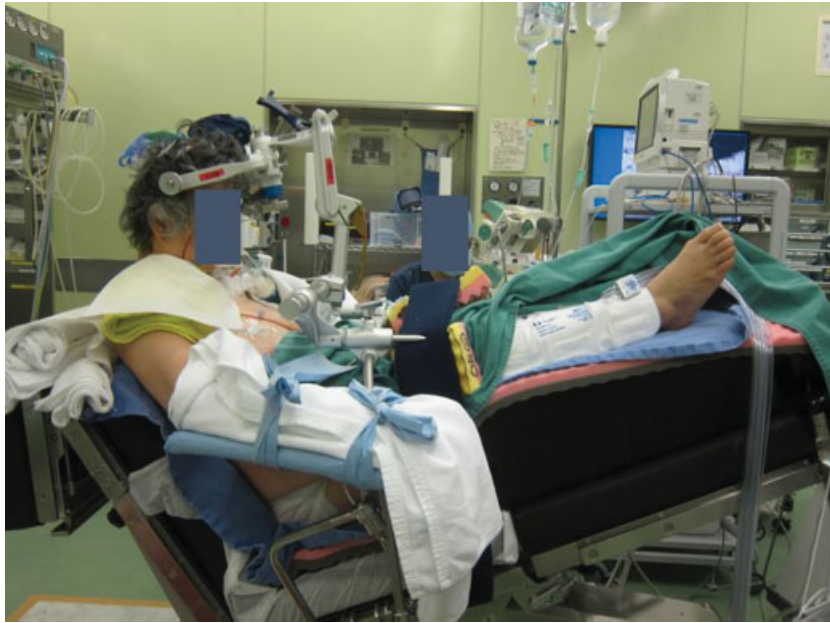

Fig. 3 A patient in the half-sitting position. In this position, the hip is flexed to a maximum of 90 degrees, and the legs are elevated with the toes positioned near the top of the head. The upper body is leaned back as far as possible while the head is flexed anteriorly.

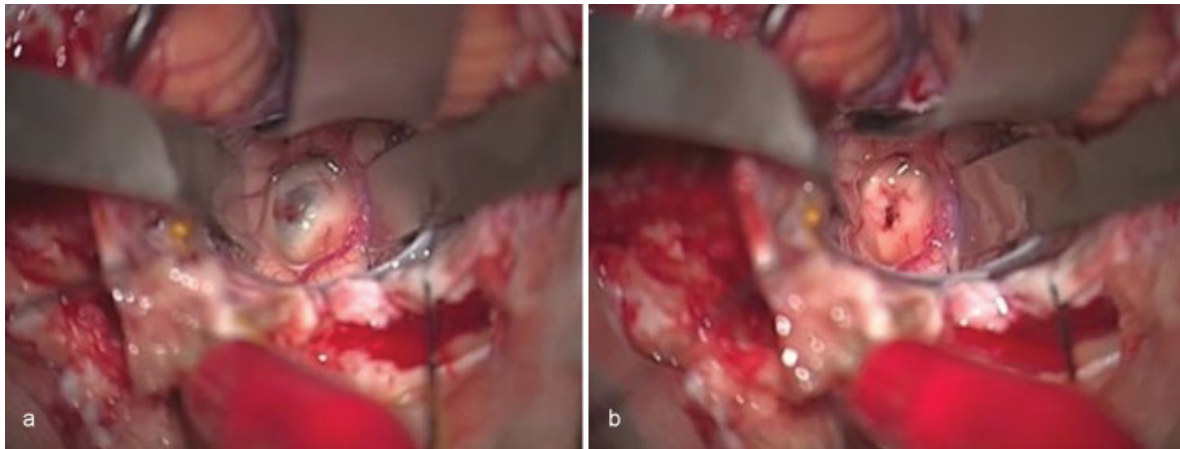


Fig. 4 Intraoperative findings. (a) Tension and hematoma were observed in the medulla oblongata. (b) Swelling decreased following removal of the hematoma.

Discussion

Intracerebral hemorrhage accounts for approximately 10% of stroke cases.^{1,2} Brainstem hemorrhages are often restricted to the pons, representing only 5 to 9% of parenchymatous hemorrhages,³ whereas such bleeding is rather uncommon in the medulla.¹ Only a few reports exist so far on the outcome and treatment of isolated medullary hemorrhage.

Barinagarrementeria and Cantú reported 16 cases of medullary hemorrhage including 12 literature cases.³⁻¹¹ Lee et al recently published a report on 11 cases of isolated medullary hemorrhage mostly caused by cavernous malformations including only one case of undetermined etiology.¹² The onset of medullary hemorrhage is usually sudden, with headache reported as the most common presenting symptom, followed by vertigo, palatal weakness, and sensory

disturbances.¹ The most common findings upon examination are palatal dysfunction and nystagmus, which are often associated with combinations of hypoglossal palsy, limb weakness, sensory disturbances, or cerebellar signs. In addition, many patients developed respiratory and cardiac disturbances, Horner's syndrome, or hiccups.³

The respiratory centers that ultimately regulate inspiration and expiration are located in the reticular formation of the dorsomedial region of the medulla and extend down to just below the obex. Lesions in this area often result in respiratory ataxia, and patients with such lesions tend to exhibit a progressive slowing of respiration, often leading to apnea. In patients with medullary compression, respiratory failure typically occurs well before circulatory failure.¹³

Although the decision to manage medullary hemorrhage via conservative treatment or prompt surgical evacuation of

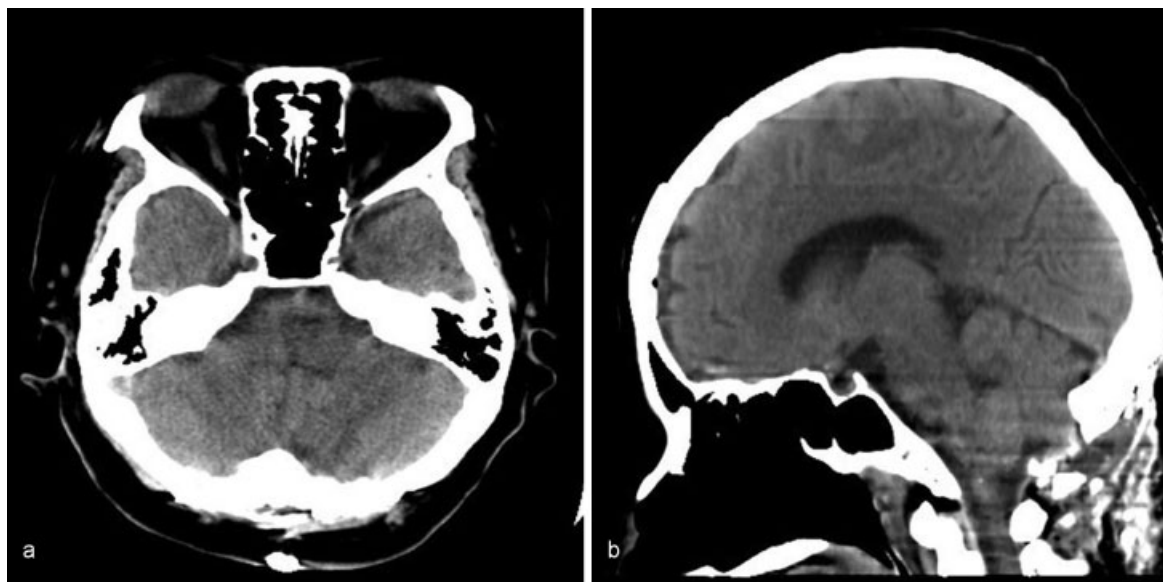


Fig. 5 Postoperative computed tomography showing complete removal of the hematoma in the medulla oblongata. (a) Axial. (b) Sagittal.

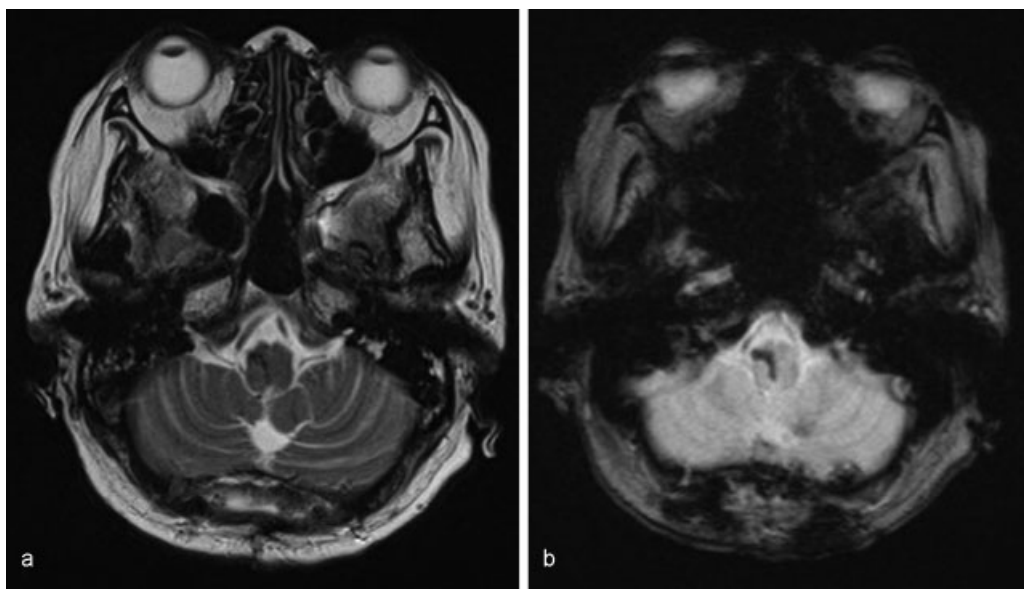


Fig. 6 Postoperative magnetic resonance images 5 weeks after surgery revealed no structural abnormality. (a) T2 weighted. (b) T2* weighted.

the hematoma remains controversial, advancements in microsurgical techniques and neuroimaging have shown promise for improving surgical outcomes and prognosis in patients undergoing such procedures.^{14,15} Such research has revealed that the “half-sitting” or “semi-sitting” position is associated with good surgical outcomes in patients with lesions of the posterior fossa.^{16,17} Despite the risk of venous air embolism and tension pneumocephalus, there are several obvious surgical advantages of using the half-sitting rather than the prone or lateral position. These advantages include improved anatomical orientation, cerebral venous decompression, and cerebrospinal fluid drainage that facilitate cerebellar retraction.¹⁷

Sufficient irrigation while removing the hematoma not only helps to flush out the residual hematoma but also improves anatomical exposure.¹⁴ Furthermore, failure to remove excess hemostatic materials may prevent proper closure of the cavity and hinder the reconnection of local circuits in the brainstem.¹⁴ Accumulating evidence has suggested that the half-sitting position is particularly useful in patients with brainstem lesions because the assistance of gravity in blood drainage and irrigation from the surgical field allows for cleaner dissection and reduces the need for bipolar coagulation. This reduced need for coagulation may significantly reduce the risk of injury to healthy tissue in the brainstem.

References

- 1 Kwon HM, Park JM, Lee JY, Yoon BW. Primary medullary hemorrhage associated with hypertension. *J Clin Neurol* 2005;1(02):177–179
- 2 Foulkes MA, Wolf PA, Price TR, Mohr JP, Hier DB. The Stroke Data Bank: design, methods, and baseline characteristics. *Stroke* 1988;19(05):547–554
- 3 Barinagarrementeria F, Cantú C. Primary medullary hemorrhage. Report of four cases and review of the literature. *Stroke* 1994;25(08):1684–1687
- 4 Biller J, Gentry LR, Adams HP Jr, Morris DC. Spontaneous hemorrhage in the medulla oblongata: clinical MR correlations. *J Comput Assist Tomogr* 1986;10(02):303–306
- 5 Cohen HCM, Tucker WS, Humphreys RP, Perrin RJ. Angiographically cryptic histologically verified cerebrovascular malformations. *Neurosurgery* 1982;10(6 Pt 1):704–714
- 6 Kempe LG. Surgical treatment of an intramedullary haematoma simulating Wallenberg's syndrome. *J Neurol Neurosurg Psychiatry* 1964;27:78–80
- 7 Lee CC, Ryu SJ. Primary medullary hemorrhage: report of a case. *J Formos Med Assoc* 1992;91(05):552–554
- 8 Mazagri R, Shuaib A, Denath FM. Medullary hemorrhage causing vertigo and gaze nystagmus. *Ear Nose Throat J* 1992;71(09):402–403
- 9 Mastaglia FL, Edis B, Kakulas BA. Medullary haemorrhage: a report of two cases. *J Neurol Neurosurg Psychiatry* 1969;32(03):221–225
- 10 Neumann PE, Mehler MF, Horoupian DS. Primary medullary hypertensive hemorrhage. *Neurology* 1985;35(06):925–928
- 11 Shuaib A. Benign brainstem hemorrhage. *Can J Neurol Sci* 1991;18(03):356–357
- 12 Lee SU, Kim HJ, Kang BS, Kim JS. Isolated medullary hemorrhage: clinical features in eleven consecutive patients. *J Stroke* 2017;19(01):111–114
- 13 Posner JB, Saper CB, Schiff N, Plum F. Plum and Posner's *Diagnosis of Stupor and Coma*. 4th ed. New York, NY: Oxford University Press; 2007:38–39
- 14 Shrestha BK, Ma L, Lan Z, Li H, You C. Surgical management of spontaneous hypertensive brainstem hemorrhage. *Interdiscip Neurosurg* 2015;2:145–148
- 15 Mangiardi JR, Epstein FJ. Brainstem haematomas: review of the literature and presentation of five new cases. *J Neurol Neurosurg Psychiatry* 1988;51(07):966–976
- 16 Ammirati M, Lamki TT, Shaw AB, Forde B, Nakano I, Mani M. A streamlined protocol for the use of the semi-sitting position in neurosurgery: a report on 48 consecutive procedures. *J Clin Neurosci* 2013;20(01):32–34
- 17 Saladino A, Lamperti M, Mangraviti A, et al. The semisitting position: analysis of the risks and surgical outcomes in a contemporary series of 425 adult patients undergoing cranial surgery. *J Neurosurg* 2017;127(04):867–876