



Contents lists available at ScienceDirect

## American Journal of Emergency Medicine

journal homepage: [www.elsevier.com/locate/ajem](http://www.elsevier.com/locate/ajem)

## Multiple cerebral infarct with cerebral vasculitis in a young patient with ulcerative colitis

Maeng Real Park, Mun Ki Min <sup>\*</sup>, Ji Ho Ryu, Dae Sub Lee, Kang Ho Lee

Department of Emergency Medicine, Pusan National University Yangsan Hospital, South Korea

### ARTICLE INFO

#### Article history:

Received 26 December 2017

Received in revised form 28 December 2017

Accepted 3 January 2018

Available online xxx

### ABSTRACT

Ulcerative colitis (UC) is a chronic and debilitating disorder, characterized by inflammation of the colonic mucosa. UC can be considered a systemic disorder but UC-related manifestations in the central nervous system (CNS) are quite rare.

A 29-year-old man was admitted to the emergency department with repeated generalized tonic-clonic (GTC) type seizures. Based on brain CT, brain metastasis or hemorrhagic infarct was suspected. Diffusion-weighted image of brain MRI showed high signal in the left thalamus and heterogenous enhancement in the right parietal and left frontal lobes. This image indicated a cerebral infarct, but could not completely rule out cerebral metastasis and vasculitis, or any other pathology. However, the brain biopsy revealed multiple thromboemboli with acute inflammation and necrosis. Thus, the patient was diagnosed with multiple cerebral infarcts with cerebral vasculitis, occurring as a complication of UC.

In conclusion, CNS manifestations of UC are rare. However, clinicians should consider uncommon diagnoses like vasculitis and thromboembolism in patients with UC presenting with seizures.

© 2017 Published by Elsevier Inc.

### 1. Introduction

Ulcerative colitis (UC) is a chronic and debilitating disorder, characterized by inflammation of the colonic mucosa. However, UC can be considered as a systemic disorder and a recent editorial in Gastroenterology states, “the effects of inflammatory bowel disease (IBD) extend to every corner of the body.” [1,2]. Extraintestinal manifestations include ocular (Uveitis and iritis), hepatic (primary sclerosing cholangitis and autoimmune hepatitis), arthritic, skeletal, hematologic, respiratory, and cutaneous manifestations [2,3].

However, UC-related manifestations in the central nervous system (CNS) are quite rare. Cerebrovascular disorders have been documented in 0.12 to 4% of all patients with IBD and they represent the most commonly described neurologic complications [4].

We report a case of UC where the patient presented to the emergency department for a seizure. Subsequently, the patient was diagnosed with multiple cerebral infarcts with cerebral vasculitis, caused by UC-related complications.

### 2. Case report

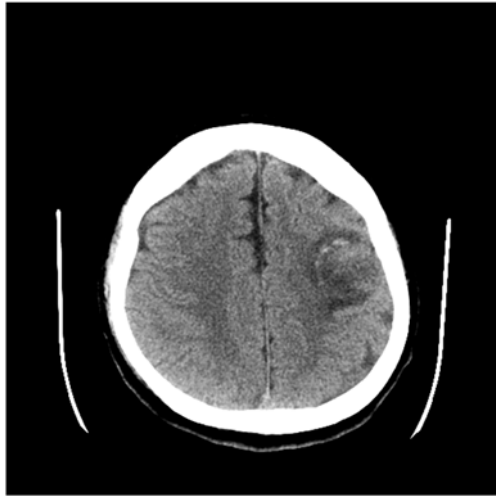
A 29-year-old man was admitted to the emergency department with repeated generalized tonic-clonic (GTC) type seizures. On arrival, he had an occurrence of the GTC-type seizure for 1 min and he was in a stupor. His vital signs showed blood pressure, 130/80 mm Hg; heart rate, 99 beats/min; respiratory rate, 18/min; and body temperature, 38.5 °C.

He had been diagnosed with UC 3 years ago. For differential diagnosis, computed tomography (CT) of the brain was performed. The CT scan revealed two low-density lesions with internal hemorrhage in the right parietal and left frontal lobes (this did not rule out tumor, infarction with hemorrhagic transformation, etc.) (Fig. 1).

Initial laboratory reports were as follows: arterial blood gas analysis (pH, 7.05; pCO<sub>2</sub>, 30; pO<sub>2</sub>, 117; base excess, −21.0; oxygen saturation, 96%); complete blood count (white blood cell count, 16,410/μL; hemoglobin, 12.0 g/dL); aspartate aminotransferase/alanine aminotransferase (AST/ALT), 43/49 IU/L; blood urea nitrogen/creatinine, 7.4/1.36 mg/dL; serum sodium/potassium/chloride (Na<sup>+</sup>/K<sup>+</sup>/Cl<sup>−</sup>), and 145/3.5/106 mmol/L. Chest CT revealed no remarkable findings and abdominal CT revealed ulcerative colitis in the active phase. Brain magnetic resonance imaging (MRI) was performed for additional differential diagnosis. Brain MRI showed heterogeneous, enhancing, T2-high-signal lesions in the right parietal and left frontal lobes, with internal diffusion restriction and hemorrhage, and focal diffusion restriction in the left thalamus (Fig. 2).

<sup>\*</sup> Corresponding author at: Pusan National University Yangsan Hospital, Beomeo-ri, Mulgeum-eup, Yangsan-si, Gyeongsangnam-do 626-770, South Korea.

E-mail address: [minmk99@pusan.ac.kr](mailto:minmk99@pusan.ac.kr) (M.K. Min).



**Fig. 1.** The brain CT showed two low-density lesions with internal hemorrhage in the right parietal and left frontal lobes. But, this CT couldn't rule out tumor, infarction with hemorrhagic transformation, etc.

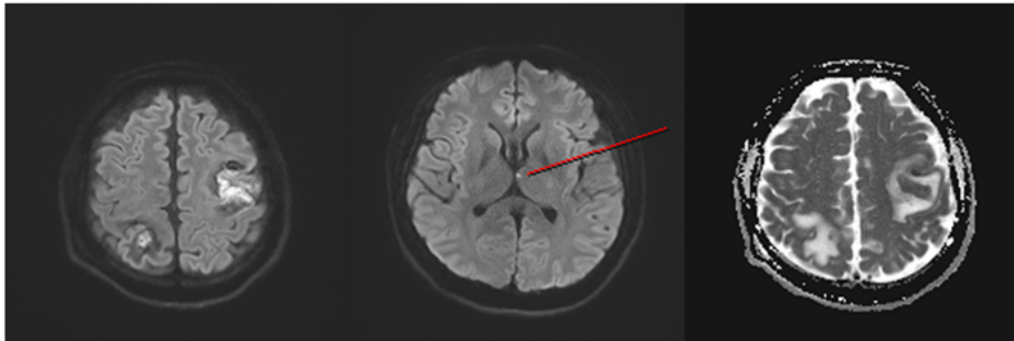
He improved from stupor to the drowsy state 10 h after admission. However, the brain MRI was unable to indicate the final diagnosis from among the several differential diagnoses (brain metastasis, cerebral infarct, vasculitis, etc.). Hence, the patient underwent brain biopsy. The biopsy revealed multiple thromboemboli, with acute inflammation

and necrosis. We obtained a thoracic echocardiogram to locate the source of emboli. The echocardiogram revealed normal heart function. There was no specific source of emboli as per the previously performed chest CT and abdominal CT. Since the specific source of emboli could not be found, multiple cerebral infarcts with cerebral vasculitis were thought to be a complication caused by UC, which could have led to seizures.

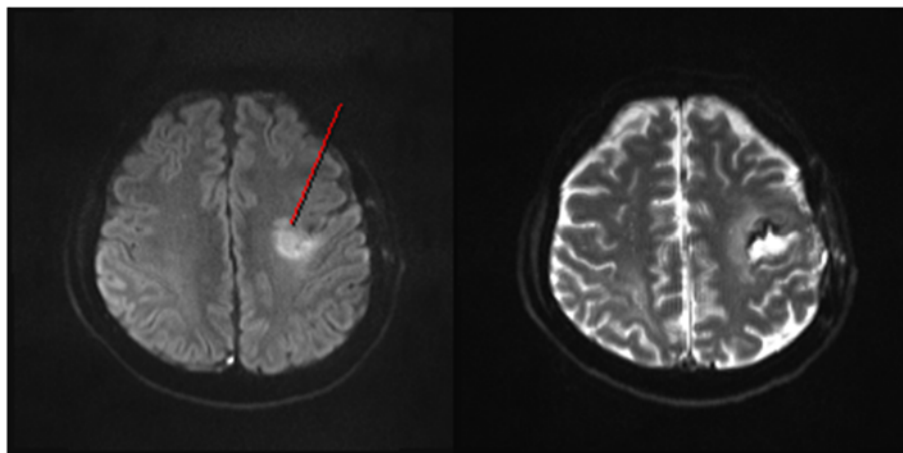
After brain biopsy, he was transferred to the gastroenterology unit for the treatment of UC. During hospitalization, he developed right facial palsy and involuntary movement of the right upper limb. On follow-up brain MRI, appearance of new diffusion restriction lesions was detected in the left middle cerebral artery region, near the previous infarct lesion. Diffuse narrowing of both cervical internal carotid, left vertebral, and common carotid arteries (vasculitis), along with subtle beaded appearance of both middle cerebral artery distal branches, and suspicious irregular susceptibility weighted image dark signal along the expected course of the vessel was seen (cerebral vasculitis) (Fig. 3). His condition improved after methylprednisolone administration, and he recovered from neurological deficits by the time of discharge.

### 3. Discussion

UC is an idiopathic chronic IBD, usually affecting patients between the age of 20 and 30 years, with a second peak age between the age of 70 and 80 years [5]. UC-associated vasculitis in the CNS is a rare neurological manifestation of systemic IBD. As mentioned earlier, cerebrovascular manifestations are seen in 0.12–4% of cases with irritable bowel syndrome [6]. CNS manifestations include arterial and venous



**Fig. 2.** Brain MRI showed heterogeneous, enhancing, T2-high-signal lesions in the right parietal and left frontal lobes, with internal diffusion restriction and hemorrhage, and focal diffusion restriction in the left thalamus.



**Fig. 3.** On follow-up brain MRI, appearance of new diffusion restriction lesions was detected in the left middle cerebral artery region, near the previous infarct lesion. Diffuse narrowing of both cervical internal carotid, left vertebral, and common carotid arteries (vasculitis), along with subtle beaded appearance of both middle cerebral artery distal branches, and suspicious irregular susceptibility weighted image dark signal along the expected course of the vessel was seen (cerebral vasculitis).

thrombosis, seizures, leukoencephalitis, and vasculitis [7]. Our patient presented with repeated GTC-type seizures. Based on brain CT, brain metastasis or hemorrhagic infarct was suspected. Diffusion-weighted image of brain MRI showed high signal in the left thalamus and heterogeneous enhancement in the right parietal and left frontal lobes. This image indicated a cerebral infarct, but could not completely rule out cerebral metastasis and vasculitis, or any other pathology. However, the brain biopsy revealed multiple thromboemboli with acute inflammation and necrosis. Thus, the patient was diagnosed with multiple cerebral infarcts with cerebral vasculitis, occurring as a complication of UC.

With respect to the pathogenesis of UC-associated vasculitis, most authors think it is an immune-mediated mechanism, possibly because of genetic susceptibility and human leukocyte antigen status, T-lymphocyte-mediated cytotoxicity, or immune complex deposition [2,8,9].

Regarding the pathogenesis of thromboembolism, a non-specific hypercoagulable state has been vaguely hypothesized. This state was associated with increased fibrinogen levels and factor VII activity, thrombocytosis, and shortened partial thromboplastin time [2]. Several studies have reported that patients with UC have a three-to four times increased risk of thromboembolism [2,10,11].

Patients of UC with concurrent cerebral vasculitis recovered from their neurological deficits with prednisolone treatment or prednisolone combined with cyclophosphamide treatment [7,12–14]. Our patient was treated with methylprednisolone and recovered from his neurologic deficit.

In conclusion, CNS manifestations of UC are rare. However, clinicians should consider uncommon diagnoses like vasculitis and thromboembolism in patients with UC presenting with seizures.

## References

- [1] Loftus Jr EV. Inflammatory bowel disease extending its reach. *Gastroenterology* 2005;129:1117–20.
- [2] Scheid R, Teich N. Neurologic manifestations of ulcerative colitis. *Eur J Neurol* 2007;14:483–93.
- [3] de Lau LM, de Vries JM, van der Woude CJ, Kuipers EJ, Siepman DA, Sillevs Smitt PA, et al. Acute CNS white matter lesions in patients with inflammatory bowel disease. *Inflamm Bowel Dis* 2009;15:576–80.
- [4] Houissa F, Salem M, Bouzaidi S, Rejeb MB, Mekki H, Debbeche R, et al. Cerebral thrombosis in inflammatory bowel disease: a report of four cases. *J Crohns Colitis* 2011;5:249–52.
- [5] Stam J. Thrombosis of the cerebral veins and sinuses. *N Engl J Med* 2005;352:1791–8.
- [6] Lossos A, River Y, Eliakim A, Steiner I. Neurologic aspects of inflammatory bowel disease. *Neurology* 1995;45:416–21.
- [7] Unnikrishnan A, Azodi S, Ansari N, Brown M, Kamnetz J, Uchiyama RC. PR3ANCA related cerebral vasculitis in ulcerative colitis presenting with orbital involvement: a case report with review of literature. *Case Rep Rheumatol* 2014;2014:582094.
- [8] Danese S, Semeraro S, Papa A, Roberto I, Scaldaferrri F, Fedeli G, et al. Extraintestinal manifestations in inflammatory bowel disease. *World J Gastroenterol* 2005;11:7227–36.
- [9] Snook JA, de Silva HJ, Jewell DP. The association of autoimmune disorders with inflammatory bowel disease. *Q J Med* 1989;72:835–40.
- [10] Bernstein CN, Blanchard JF, Houston DS, Wajda A. The incidence of deep venous thrombosis and pulmonary embolism among patients with inflammatory bowel disease: a population-based cohort study. *Thromb Haemostasis* 2001;85:430–4.
- [11] Miehsler W, Reinisch W, Valic E, Osterode W, Tillinger W, Feichtenschlager T, et al. Is inflammatory bowel disease an independent and disease specific risk factor for thromboembolism? *Gut* 2004;53:542–8.
- [12] Salvarani C, Brown Jr RD, Christianson TJ, Huston 3rd J, Giannini C, Miller DV, et al. Adult primary central nervous system vasculitis treatment and course: analysis of one hundred sixty-three patients. *Arthritis Rheumatol* 2015;67:1637–45.
- [13] Raj N, Arkebauer M, Waters B, Dickinson BA. Case of cerebral vasculitis associated with ulcerative colitis. *Case Rep Rheumatol* 2015;2015:598273.
- [14] Dejaco C, Fertl E, Prayer D, Oberhuber G, Wyatt J, Gasche C, et al. Symptomatic cerebral microangiopathy preceding initial manifestation of ulcerative colitis. *Dig Dis Sci* 1996;41:1807–10.