



Published in final edited form as:

Neurocase. 2018 February ; 24(1): 31–40. doi:10.1080/13554794.2018.1428352.

The neural substrates of improved phonological processing following successful treatment in a case of phonological alexia and agraphia

Andrew T. DeMarco^{1,*.§}, Stephen M. Wilson^{1,2}, Kindle Rising¹, Steven Z. Rapcsak^{1,2}, and Pélégie M. Beeson^{1,2}

¹Department of Speech, Language, and Hearing Sciences, University of Arizona, Tucson, AZ 85721

²Department of Neurology, University of Arizona, Tucson, AZ 85724

Abstract

Deficits in phonology are among the most common and persistent impairments in aphasia after left hemisphere stroke, and can have significant functional consequences for spoken and written language. While many individuals make considerable gains in response to treatment, the neural substrates supporting these improvements are poorly understood. To address this issue, we used BOLD fMRI to measure regional brain activation in an individual during pseudoword reading before and after treatment targeting phonological skills. After the first phase of treatment, significant improvement in pseudoword reading was associated with greater activation in residual regions of the left dorsal language network, as well as bilateral regions that support attention and cognitive effort outside of canonical language areas. Following a second treatment phase, behavioral gains were maintained, while brain activation returned to pre-treatment levels. In addition to revealing the neural support for improved phonological skills in the face of damage to critical brain regions, this case demonstrated that behavioral advances may ultimately be maintained without the need to sustain a marked increase in cognitive effort.

Keywords

acquired alexia; acquired agraphia; aphasia; functional MRI; phonological impairment; rehabilitation

Introduction

Damage to left perisylvian cortex often results in impaired phonological processing, evident by speech sound errors (phonological paraphasias) and reduced performance on phonological awareness and manipulation tasks (Fiez, Balota, Raichle, & Petersen, 1999; Henry, Beeson, Stark, & Rapcsak, 2007; Patterson & Marcel, 1992; Rapcsak et al., 2009). This central phonological deficit also manifests in written language processing impairments

*Corresponding author: Andrew T. DeMarco, Department of Speech, Language, and Hearing Sciences, University of Arizona, 1401 E. University Blvd., PO Box 210073, Tucson, AZ 85721-0073, Tel: 267-474-0513, demarco@email.arizona.edu.

§Now at Department of Neurology, Georgetown University, 4000 Reservoir Road NW, Washington, DC, 20007

known as phonological alexia and phonological agraphia, syndromes characterized by disproportionate difficulty reading or spelling novel sequences of phonemes or graphemes (i.e., pseudowords) relative to real words (Beauvois & Derouesne, 1979; Rapcsak et al., 2009; Shallice, 1981). Although this lexicality effect (real words > pseudowords) is the hallmark feature of phonological alexia/agraphia, impairments are typically evident in text-level reading and writing so that the functional consequences can be quite marked (Beeson, Rising, DeMarco, Foley, & Rapcsak, 2016; Friedman, 1996).

A number of behavioral treatment approaches have been shown to reduce the deficits underlying phonological alexia/agraphia. Positive outcomes have been reported from interventions focused on retraining letter-to-sound mappings and strengthening phonological manipulation skills (Beeson, Rising, Kim, & Rapcsak, 2010; Carlomagno & Parlato, 1989; Hillis Trupe, 1986; Kendall, Conway, Rosenbek, & Gonzalez-Rothi, 2003; Kiran, 2005; Luzzatti, Colombo, Frustaci, & Vitolo, 2000). Although phonological treatments have been shown to effect both task-specific and functional improvements in communication skills, the neural substrates and cognitive mechanisms underlying these gains are unclear. Indeed, the study of neural support for the rehabilitation of phonological processing is limited to a single case report published early in the imaging enterprise (Small, Flores, & Noll, 1998). Small and colleagues (1998) studied fMRI activation in an individual who relearned specific grapheme-to-phoneme correspondence rules for the “hard” and “soft” *c* and *g*. Activation after treatment showed reduced reliance on left angular gyrus and increased engagement of left lingual gyrus. The authors proposed that treatment effects were supported by increased perceptual analysis ability, but no changes appeared to be specific to phonological processing per se. To our knowledge, no other study has used functional imaging to explore the neural response to behavioral treatment for acquired impairment of phonological processing.

The growing cohort of studies that examine treatment-induced recovery using fMRI across a range of language tasks have found changes consistent with several potential mechanisms for recovery (for review, see Raymer et al., 2008; Thompson & den Ouden, 2008). The first relates to restitution of linguistic function supported by left hemisphere (domain-specific) regions, including residual components of the language network and perilesional areas. Recovery may also reflect a shift to reliance on right-hemisphere regions homotopic to damaged left-hemisphere language areas. Finally, there is evidence of recruitment of regions corresponding to domain-general cognitive control that also support the recovery process (Brownsett et al., 2014; Geranmayeh, Brownsett, & Wise, 2014).

Converging evidence from lesion-deficit correlation studies and functional neuroimaging studies in healthy adults suggest that phonological processing is supported by a distributed network of left perisylvian cortical regions, including posterior inferior frontal gyrus/operculum, precentral gyrus, anterior insula, superior temporal gyrus/sulcus, and supramarginal gyrus (Alexander, Friedman, Loverso, & Fischer, 1992; Henry et al., 2007; Rapcsak et al., 2009; Roeltgen, Sevush, & Heilman, 1983). Collectively, these regions constitute the dorsal language pathway that plays a critical role in speech production, phonological short-term memory, and phonological awareness (Hickok & Poeppel, 2007). The dorsal pathway is strongly left-lateralized, as is evident from meta-analyses of fMRI

studies with healthy adults (Vigneau et al., 2006, 2011). In fact, the right hemisphere appears to have relatively little natural capacity for phonological processing beyond the support of lexical items with strong semantic weight, as demonstrated by studies of sodium amytal infusion (WADA) (Fedio, August, Patronas, Sato, & Kufta, 1997; Wada, 1949; Wada & Rasmussen, 1960) and split-brain patients (Gazzaniga, 2000; Zaidel & Peters, 1981). Functional imaging studies have also provided evidence that during written language processing word and subword-level phonological-to-orthographic translations are mediated by interactions between the dorsal language pathway and the visual word-form area located within left mid-fusiform gyrus (Jobard, Crivello, & Tzourio-Mazoyer, 2003; Taylor, Rastle, & Davis, 2012).

When phonological processing tasks are challenging they are likely to recruit a broadly distributed network of cortical areas associated with top-down allocation of attention to external stimuli and task performance (Geranmayeh et al., 2014). This network includes bilateral intraparietal sulcus, inferior frontal sulcus, anterior insula, pre-supplementary motor area, and neighboring dorsal anterior cingulate. This system is often divided into subnetworks, including a fronto-parietal control network, a dorsal attention network, and a cingulo-opercular network (Dosenbach et al., 2007; Power et al., 2011; Power, Schlaggar, Lessov-Schlaggar, & Petersen, 2013; Vincent, Kahn, Snyder, Raichle, & Buckner, 2008). Although the exact roles of each subnetwork are still under investigation, together they are thought to direct attention and executive control for response selection, self-monitoring, and error-correction, processes that are clearly relevant to aphasia recovery (e.g., Brownsett et al., 2014). Furthermore, portions of these same networks have been shown to engage during reading tasks that require strategic direction of attentional resources toward phonological processing to perform a regularization pronunciation task (i.e., pronouncing “pint” so it rhymes with “mint”) (Ihnen, Petersen, & Schlaggar, 2015). These cognitive demands are similar to those of activities employed during phonological treatments, which typically require a participant to carefully attend to and modify their spoken or written output in order to overcome initial inaccurate responses.

In this study, we set out to examine the neural substrates of recovery of phonological skills following left perisylvian damage. To do so, we examined neural activation measured by BOLD fMRI in an individual with phonological impairment following a left hemisphere stroke. Imaging data were collected at several time points over the course of behavioral treatment. We expected positive treatment effects to be evident as increased BOLD signal driven by additional processing in regions supporting behavioral gains. Based on the strong lateralization of phonological processing we hypothesized that behavioral gains would be associated with changes in left hemisphere residual language regions involved in phonological processing in the healthy brain. We also anticipated the recruitment of brain regions corresponding to nonlinguistic domain-general systems given the attentional demands involved with the treatment procedures (e.g., strategic planning and self-monitoring).

Materials and Methods

Participants

Patient with aphasia—JW was a 51 year-old, right-handed male with 12 years of education who suffered a left middle cerebral artery stroke four months before evaluation began for this study. Structural brain scans showed a chronic lesion involving posterior inferior frontal gyrus extending posteriorly into left parietal lobe, with an island of spared Rolandic cortex where the lesion was limited to subcortical involvement (Figure 1). JW was independent in all activities of daily living with the exception of reading and writing. Prior to treatment the patient rated his premorbid reading and spelling on a 5 point scale with 5 being excellent, 4 being very good, and 3 being average. He rated his reading as 3 (average), and spelling as 4 (very good). The patient reported no history of neurodevelopmental disorder such as dyslexia prior to his stroke. His personal goals were to improve his ability to read and write personal e-mails, read magazines, and to return to work as a salesman where he was employed prior to his stroke. JW's spoken language profile was consistent with anomic aphasia, scoring an Aphasia Quotient of 82.2 on the Western Aphasia Battery (Kertesz, 1982). His mild naming impairment was evident by a score of 50/60 on the Boston Naming Test (Goodglass, Kaplan, & Weintraub, 1983). He did not present with concomitant cognitive or perceptual impairments such as hemispatial neglect. There was evidence of a mild apraxia of speech that was only evident on the repetition of complex pseudowords; this slight motor speech impairment did not interfere with his fluent speech production or with the treatment implementation.

A comprehensive language assessment revealed marked phonological impairment, with reading and spelling performance consistent with phonological alexia and phonological agraphia. Specifically, JW exhibited the hallmark lexicality effect, with reading and writing performance for pseudowords disproportionately impaired relative to real words (reading 25% vs. 97.5%, spelling 15% vs. 77.5%) (see Figure 1). Errors for pseudoword reading and spelling consisted of phonologically implausible responses (e.g., *prang* for *prane*) and lexicalizations (e.g., *globe* for *glope*).

Over the course of two months, JW was administered a battery of phonological tasks that required 1) phonological perception and production (repetition, minimal pair judgment, rhyme production/judgment), 2) transcoding between orthography and phonology (letter-to-sound, sound-to-letter conversion), and 3) phonological manipulation (sound deletion, blending, replacement, segmentation). JW exhibited moderate to severe impairments on tasks requiring transcoding between orthography and phonology ($M = 52.90\%$) and phonological manipulation ($M = 33.19\%$), while tests of phonological perception and production were relatively preserved ($M = 93.33\%$). Other linguistic domains were fairly well preserved relative to his phonological deficit, as evidenced by composite scores on tests of lexico-semantic knowledge ($M = 96.5\%$), visuo-orthographic skills ($M = 98.8\%$), and allographic-graphomotor skills ($M = 100\%$; see Supplemental Materials for details).

Control subjects—Seven healthy right-handed adults participated in the neuroimaging portion of the study to validate the task with respect to existing fMRI literature and to provide a basis of comparison for JW. The control group consisted of 4 males (3 females),

ranging from 58.5 to 74.6 years ($M = 64.1$, $SD = 6.2$) and education ranging from 12 to 18 years ($M = 15.6$, $SD = 2.5$). Although the control group is not an ideal match to the patient with regard to age and education, they offer empirical evidence of the network that supports phonological processing.

Behavioral Treatment—Given JW’s classic profile of phonological alexia and agraphia, he was considered a good candidate for treatment aimed at the rehabilitation of phonological processing. A two-phase treatment protocol was implemented as previously described by Beeson and colleagues (Beeson et al., 2010), and JW’s response to treatment is included in a recent case series report (Beeson et al., 2016). Treatment was implemented during hour-long sessions conducted twice weekly with daily homework. See Supplemental Materials for multiple baseline plot of direct treatment response.

The first phase of treatment began at about six months post stroke and focused on retraining and practicing the use of phonology-orthography relationships. Advancement through treatment was criterion-based, with mastery operationalized as at least 80% accuracy over two consecutive sessions for each stimulus set. Treatment progressed one set at a time through four sets of five consonants and two sets of six vowels. Once phonology-orthography relationships were relearned, written and spoken blending skills were targeted, with progress measured using four sets of five untrained CVC pseudowords. Over the course of 20 weeks of treatment JW ultimately achieved the criterion of 80% performance or better over two consecutive sessions for letter-to-sound and sound-to-letter relationships of four sets of five consonants, two sets of six vowels, and four sets of five untrained pseudowords.

The second phase of treatment, which lasted an additional 15 weeks, was considered interactive in the sense that JW was trained to integrate residual lexical knowledge with his improved phonological skills to assist in the self-detection and correction of errors in reading and spelling. This included training with an electronic speller to assist in problem-solving for difficult spellings as previously described (Beeson et al., 2010). Over the course of treatment, JW became competent with the electronic speller, which he used to check and self-correct spelling on structured paragraph-level writing tasks and in functional contexts.

As depicted in Figure 2, generalization of direct treatment effects was evident by robust improvements on composite scores on phonological tasks involving phoneme-grapheme conversion and sublexical phonological manipulation skills after phase one of treatment. While measures of generalization improved numerically after phase two relative to phase one, the increase was not statistically significant. Essentially, JW demonstrated good maintenance of gains after the first phase of treatment. Performance on tests of phonological perception and production remained stable and near ceiling over all phases of treatment.

Functional Imaging

Immediately before and after each of the treatment phases, JW was scanned using BOLD fMRI as he performed an overt pseudoword reading task. The task was dependent on phonological transcoding from letters to sounds and blending of sounds into pronounceable syllable strings, which were skills targeted in treatment. Over the course of the study, JW participated in six scanning sessions: two prior to treatment, two following the first phase of

treatment, and two following the second phase of treatment (Figure 3a). Each session consisted of two runs of pseudoword reading and one run of mixed pseudoword/word reading. Word trials from the mixed pseudoword/word task were excluded from all analyses, so that only pseudoword reading was examined. The mixed word-pseudoword run was acquired for another experiment, and the task parameters were identical to the pseudoword only runs, with the exception of the lexicality of half of the stimuli. Overall, the six scanning sessions included 12 runs of pseudoword reading and six runs of mixed pseudoword/word reading. The control subjects were each scanned on one occasion, completing two runs of overt pseudoword reading, and a structural scan was obtained to use for image registration and normalization purposes.

The imaging task consisted of reading aloud monosyllabic pseudowords presented for three seconds in black capital letters on a white background, followed by viewing a fixation point between stimuli (Figure 3b). JW was trained on the paradigm outside of the scanner at the beginning of each scanning session, and instructions were repeated over headphones immediately prior to each run. He was instructed to “read the made-up word out loud, nice and clear, one time.” He was reassured that it was okay if each response “wasn’t perfect” so as to minimize repetition and distraction by incorrect or incomplete responses. Each run lasted 6 minutes and consisted of 42 monosyllabic pseudowords with presentation jittered between 6 and 16 seconds. Four lists of pseudowords were developed for this experiment, including one practice list and three experimental lists. Lists were balanced so that there were no significant differences in orthographic neighborhood, mean bigram frequency, and letter length, (Kruskal & Wallis, 1952) (See Supplemental Materials for stimulus list and descriptive statistics). None of the target pseudowords used during scanning were used as stimuli during treatment or assessment. During fMRI scanning, audio and visual stimuli were presented using VisualStim headphones and goggles (Magnetic Resonance Technologies).

Overt spoken responses were recorded using an MRI compatible microphone (FOMRI; Optoacoustics) for offline coding of accuracy and response time. Response time was quantified as the time between the visual presentation of a stimulus and the initiation of its spoken response. All recorded responses were scored as correct or incorrect by two raters blinded to which phase of treatment they were evaluating. Inter-rater reliability for response accuracy was assessed using Cohen’s kappa statistic. Inter-rater reliability was calculated for the 1764 combined responses of the seven control subjects and JW ($K = .79$), for the 1008 responses from the seven control subjects ($K = .68$), and for JW’s 756 responses alone ($K = .79$). These values indicate that inter-rater reliability of responses collected in the scanner was good (Viera & Garrett, 2005).

Imaging Parameters—Images were acquired on a 3T GE Signa Excite scanner with an 8-channel head coil. Each functional run consisted of 180 blood oxygen level-dependent (BOLD) T2*-weighted volumes using a single-shot spiral-in/out pulse sequence (Glover & Law, 2001) with the following parameters: 30 AC-PC aligned axial slices acquired in sequential order; slice thickness = 4.0 mm with no slice gap; field of view = 240×240 mm; matrix = 64×64; repetition time (TR) = 2000 ms; echo time (TE) = 30 ms; flip angle = 90°;

voxel size = 3.75×3.75×4.0 mm; 180 volumes + 2 discarded. For anatomical reference, a high resolution T1-weighted 3D image was acquired with standard parameters.

Image Processing—Functional imaging data were preprocessed and normalized to standard space with standard methods as described previously (Wilson et al., 2014). The location and extent of JW's lesion was manually delineated on a Wacom tablet, and normalized using cost function masking (Andersen, Rapcsak, & Beeson, 2010).

Statistical Analysis

Patient (JW): Prior to statistical modeling of the data, all eighteen functional time-series were concatenated on the time dimension, resulting in a single time series containing 3240 volumes (18 runs, each consisting of 180 volumes) and resampled to 3 mm³ voxels. The functional data were analyzed using a general linear model fit at each voxel using the *fmriilm* procedure from FMRISTAT (Worsley et al., 2002). The design matrix contained 9 explanatory variables, including three EVs for real word trials from the mixed pseudoword/word runs (one for each phase of the study; excluded from the model) and six EVs corresponding to accurate or inaccurate trials at each phase of the study. All events were entered into the model with a duration of 3 seconds. Ten covariates were included per run (180 total): 6 head movement parameters, signal from white matter and CSF masks, and constant and linear terms. Two additional covariates were included per epoch (6 total), including a term for demeaned response time on accurate trials and inaccurate trials.

Contrasts were constructed to examine brain regions engaged by pseudoword reading and to reveal changes following treatment. Incorrect trials were excluded from the analysis. To contextualize changes over time and compare JW's results with the control group, the first contrast identified brain regions engaged by pseudoword reading, on average, at all scan times. A second contrast was constructed to identify regions of change during pseudoword reading following the first treatment (PostTx1 > PreTx). A third contrast was constructed to detect further increased activation following the second phase of treatment (PostTx2 > PostTx1). A fourth contrast was constructed to examine activation after the second phase of treatment relative to pre-treatment (PostTx2 > PreTx). Analyses were restricted to voxels significantly activated at $p < .05$ in the first term of each contrast to ensure that resulting regions reflected positive activation above baseline. Analyses were also restricted to the brain parenchyma with a mask of the skull-stripped structural image. All statistical maps for JW were thresholded voxelwise at $p < .005$, then corrected for multiple comparisons using Gaussian random field theory (GRFT) using the *multistat* function of the *FMRISTAT* package, $p < .05$ corrected.

Significant patterns of change over the two treatment phases were investigated by joining the results of the above contrasts via a conjunction. Specifically, areas of increased activation relative to baseline that persisted after both phases of treatment were identified by conjoining the results of contrasts of PostTx1 > PreTx and PostTx2 > PreTx. Areas of activation that exhibited an increase following phase one were identified by conjoining the results of contrasts of PostTx1 > PreTx and PostTx1 > PostTx2.

Data from the seven control participants were analyzed similarly, with incorrect trials excluded from the analysis (accuracy, $M = 91\%$, $SD = 9.3$). The pseudoword reading runs were combined in a fixed effects model, and then combined at the second level in a random effects analysis with *multistat*. One contrast was constructed to model the average activation during accurate pseudoword reading trials across the group. Resulting SPMs were thresholded voxelwise at $p < .005$, and then corrected for multiple comparisons based on Gaussian random field theory (GRFT), $p < .05$ corrected.

Behavioral performance

Behavioral dependent variables in the scanning task included response time and accuracy for pseudoword reading. JW's pseudoword reading accuracy was evaluated over the three scan sessions using an omnibus Cochran test (Cochran, 1952) followed by pairwise McNemar tests (McNemar, 1947). Because response time is a continuous variable as opposed to the binary accuracy, a different approach was used. A one-way ANOVA was first used to compare JW's response times to the control group. Then a repeated-measures ANOVA with Greenhouse-Geisser correction was used to identify significant changes in JW's response time over the three imaging sessions, followed by post-hoc pairwise tests using Bonferroni correction.

Results

Behavioral responses in the scanner

Response accuracy—As expected, the overall accuracy for the seven control subjects on the pseudoword reading task performed in the scanner was good, ranging from 72% to 99% ($M = 91.06$, $SD = 9.3$). JW was impaired on this task with an average of 26% ($SD = 8\%$) correct prior to treatment, and 53.67% ($SD = 5\%$) and 56.8% ($SD = 4\%$) after the first and second phases of treatment, respectively. The changes in accuracy over time were significant, as shown by the omnibus Cochran test, $Q(2,123) = 53.6$, $p < .001$, with significant improvement after the first phase of treatment (53.67% vs. 26%), pairwise McNemar test (one-tailed). Performance after the second phase of treatment remained significantly better than pre-treatment (56.8% vs. 26%), but it was not significantly different from accuracy following the first phase of treatment.

Response time—A repeated-measures ANOVA with Greenhouse-Geisser correction was used to examine reaction time following each phase of treatment. As depicted in Figure 4, JW's mean response time differed significantly across treatment phases, $F(1.79, 373.33) = 8.233$, $p < .001$. Post-hoc tests with Bonferroni correction revealed that response time was significantly faster following phase one of treatment ($M = 814.9$ ms, $SD = 268.6$ ms, $p < .001$) relative to pre-treatment ($M = 735.1$ ms, $SD = 208.6$). Following phase two of treatment, response time was also significantly faster relative to pre-treatment ($M = 747.5$, $SD = 207.1$ ms, $p = .016$), although it was not significantly different from phase one ($p = 1.00$). Response time for control subjects was on average 1025.9 ms ($SD = 372.8$, median = 958.3).

fMRI Results

Whole brain analysis—As depicted in Figure 5A, significant regions of activation for the control group during pseudoword reading are outlined in white. This included left inferior frontal gyrus (pars triangularis and pars opercularis), bilateral sensorimotor cortex (pre-central gyrus, central sulcus, and post-central gyrus), left posterior insula, bilateral supplementary motor area, bilateral posterior superior temporal gyrus/sulcus, bilateral inferior occipital lobes, left mid-fusiform gyrus, and bilateral cerebellum. There was also activation in bilateral intraparietal sulci that did not quite meet the minimum cluster extent, indicated by white dotted lines (left: MNI = -35, -60, 53, maximum $t = 6.82$, $p = .081$ corrected, .005 a priori; right: MNI = 32, -69, 52, maximum $t = 5.96$, $p = .81$ corrected, .013 a priori). These regions are consistently identified as involved with pseudoword reading in the literature. See Supplemental Materials for full table of activation regions.

Figure 5A (hot scale) also shows a contrast of JW's average activation at all scan times indicating consistent activation of a cortical network similar to the control group. These regions included bilateral sensorimotor cortex (pre-central gyrus, central sulcus, and post-central gyrus) with the left hemisphere extent limited by the lesion, right inferior frontal gyrus (pars triangularis, opercularis, and orbitalis), right insula, bilateral supplementary motor area, bilateral posterior middle temporal gyrus, bilateral inferior occipital gyri, left mid-fusiform gyrus, and bilateral intraparietal sulci. Despite the similarity of the networks, the control group activated some areas that were damaged in JW, including left inferior frontal gyrus, left insula, left ventral pre-central and ventral post-central gyri. Regions of activation in JW not activated by the control group included bilateral posterior middle temporal gyri, right inferior frontal gyrus, and right insula. See Supplemental Materials for full table of activation regions.

Effect size maps for average activation for JW at each scanning time point are shown in Figures 5B, 5C, and 5D, respectively. These illustrate the similarity between activation patterns at each phase of treatment, and provide a backdrop to interpret regions of activation change.

Conjunction analysis—As depicted in Figure 5C (green) and listed in Table 1, a conjunction analysis of PostTx1 > PreTx and PostTx1 > PostTx2 revealed seven brain regions that showed significantly increased activation following phase one, which then decreased to pre-treatment levels after phase two of treatment. Regions demonstrating this pattern included left Rolandic cortex (precentral gyrus/central sulcus), left intraparietal sulcus, right intraparietal sulcus (two clusters), right transverse occipital sulcus extending to V1, and right ventral post-central gyrus and neighboring Sylvian fissure, bilateral supplementary motor area/pre-supplementary motor area, and right fusiform gyrus. A conjunction analysis of PostTx1 > PreTx and PostTx2 > PreTx revealed that no regions of increased activation after phase one of treatment persisted following phase two of treatment. In other words, the regions that showed increased activation after phase one of treatment did not exhibit continued increased activation after the second treatment phase.

Discussion

In this study we examined the neural correlates of improved phonological processing in an individual with chronic aphasia and phonological alexia/agraphia using repeated BOLD fMRI before and after two phases of behavioral treatment. At the outset, JW was able to correctly read pseudowords presented in the scanner with about 25% accuracy, so the initial fMRI offers insight regarding what cortical regions supported these residual phonological abilities. He made significant gains in phonological skills and pseudoword reading after the first phase of treatment that were maintained following the second phase of treatment, so that the functional imaging results were expected to show the cortical areas associated with the improvement.

Prior to treatment, JW engaged several brain regions that were also activated in the healthy controls, including the left precentral gyrus, left mid-fusiform gyrus, bilateral supplementary motor area, and bilateral intraparietal sulcus. The left precentral gyrus was the residual portion of the dorsal pathway in JW, with the left inferior frontal gyrus and left insula damaged. The left mid-fusiform gyrus, pre-supplementary motor area/supplementary motor area, and bilateral intraparietal sulci were intact in JW, and were engaged during pseudoword reading as they were in the control group. Thus, it appeared that neural support for sublexical phonological-to-orthographic translation was similar to the typical network engaged by healthy adults minus the damaged portions of the left posterior inferior frontal cortex. In contrast to controls, JW showed bilateral engagement of posterior superior temporal sulcus, possibly indicating greater difficulty/reduced efficiency in constructing phonological representations for nonword stimuli. JW also showed activation in right inferior frontal gyrus and right insula that was not evident in the controls. This activation could be interpreted as a compensatory engagement of a homotopic right hemisphere region to support phonological processing. An alternative explanation would be that the right inferior frontal gyrus and insula were engaged as part of the bilateral, domain-general multiple demand network (Fedorenko, Duncan, & Kanwisher, 2013).

Turning our attention to JW's response to treatment, after the first phase he demonstrated significant improvement on measures of phonological transcoding and manipulation administered outside of the scanner. The improvement was also evident on pseudoword reading performed both outside of the scanner and during the fMRI task. The improved performance was associated with increased activation in the left precentral gyrus, which was the residual portion of the dorsal language network that is typically involved in phonological processing (Hickok & Poeppel, 2007; Saur et al., 2008). The other regions of increased activation included portions of the dorsal attention network. Specifically, the widespread increase of activation seen in bilateral intraparietal sulci strongly resembles the parietal components of a dorsal attention network, which has been implicated in selective attention and executive control during nonword reading (Binder, Medler, Desai, Conant, & Liebenthal, 2005; Graves, Desai, Humphries, Seidenberg, & Binder, 2010; Ihnen et al., 2015; Mechelli et al., 2005). The work by Ihnen and colleagues is particularly relevant because they documented engagement of these regions in healthy adults as they performed the cognitively/attentionally demanding task of generating a "regularized" spoken production of written words with atypical letter-sound correspondences. In addition to the

parietal components of the dorsal attention network, Ihnen and colleagues noted engagement of the pre-supplementary motor area/supplementary motor area as part of a cingulo-opercular/dorsal attention network, regions that were also activated by JW in this study.

In the right hemisphere, there was activation that extended into the vertical occipital sulcus, which has also been associated with the dorsal attention network (Vincent et al., 2008). The increased activation in this region may relate to the enhancement of visual representations through additional attentional support, which has been proposed as a mechanism by which the dorsal attention network can aid with domain-specific processes in difficult conditions (Fedorenko et al., 2013). The right ventral post-central gyrus also showed additional engagement after the first phase of treatment. This region codes tactile and proprioceptive sensory feedback from the articulators to support speech production bilaterally, and plays a central role in feedback control during self-generated speech (Golfinopoulos, Tourville, & Guenther, 2010; Guenther, 2006). JW had unilateral activation in the right hemisphere due to left hemisphere damage to this region. Increased engagement of this somatosensory feedback loop may reflect top-down attention to correctly produce the novel phonological strings or to prevent or correct errors during the challenging pseudoword reading task.

Overall, it appeared that behavioral gains were supported by engagement of residual left-hemisphere dorsal language network associated with phonological processing, phonological short-term memory, and articulatory mapping, in concert with the dorsal attention network. It was surprising that the increased activation declined to pre-treatment status after the second phase of treatment, despite the fact that JW maintained the behavioral gains. To be clear, over the course of the second phase of treatment, JW improved his ability to spell untrained words and nonwords and he demonstrated self-detection and correction of spelling errors; however, he did not show measurable improvement on the battery of tests that probed phonological skills. Rather, he maintained the improvements achieved after the first phase of treatment, and there was a significant decrease in activation of brain regions that had increased after the first phase of treatment. We propose that the reduced activation may reflect improved automaticity or stability of the phonological skills, thus requiring less effort to perform at the same level of accuracy. Our interpretation warrants caution, however, because the reduced activation after the second treatment phase could relate to another unknown mechanism. The likelihood that the changes related to a natural recovery mechanism seem unlikely because treatment was initiated after six months post-stroke and the multiple baseline treatment data showed stable baselines prior to targeting each set in therapy (see Supplemental materials). Our proposed interpretation that JW was performing the reading tasks with less effort were consistent with the subjective view of JW's performance at the end of treatment. From a therapeutic standpoint, these findings are consistent with the rationale of training beyond initial mastery of skills in order to increase automaticity and/or generalization (see, for example, Lott, Carney, Glezer, & Friedman, 2010; Lott & Friedman, 1999). In that vein, the first phase of treatment served to re-establish letter-to-sound and sound-to-letter relations and the application to regularly spelled words and pseudoword spelling. The second phase of treatment focused on applying the retrained phonological skills in a more dynamic context with the goal of establishing strategies for the self-detection and correction of errors in text-level writing and reading. The added benefit from the second phase of treatment was not readily apparent from the behavioral post-

testing, but was revealed by the reduced neural metabolic demand as measured by the fMRI. This observation is particularly intriguing because the imaging data captured a phenomenon that was otherwise not detectable from our behavioral data.

It is difficult to make a direct comparison between the present study and the previous work on treatment-induced recovery of phonology, which is limited to Small et al., 1998. From a methodological perspective, Small and colleagues (1998) were progressive in their attempt to use functional imaging to examine neural changes in response to treatment. However, limitations in image processing and statistical modelling approaches prevented a true direct comparison of pre- and post-treatment activation which was accomplished in the current study. That study simply showed the activation pattern before and after treatment, but did not model a statistical comparison of the data collected at different time points. The region of significant activation following retraining of letter-sound associations for *c* and *g* in specific contexts was limited to the left lingual gyrus, suggesting greater engagement of visual processing areas. There was no apparent change in activation that might relate specifically to phonological processing, such as the left dorsal pathway, but it is not possible to determine whether these regions were engaged both before and after treatment.

As we consider the findings from this study, we acknowledge that the results cannot be generalized to other individuals because of variations in the lesion location and extent as well as the viability of residual portions of the relevant cortical network. In the case of JW, it appeared that he relied on the left precentral gyrus to perform phonological processing with some success and that he performed better after treatment which appeared to more strongly engage that region and the bilateral dorsal attention network. In fact, it appeared that the attention network served to potentiate the function of the residual phonological processing network. Again, the surprising result was JW's ability to maintain the improved performance without the "overactivation" of those regions after the second phase of treatment was complete. This finding is counter to the typical assumption that rehabilitation effects will be in the direction of increased activation of cortical regions that support performance. Indeed it will be interesting to explore whether other individuals demonstrate an analogous pattern of increase followed by decreased activation when treatment serves to improve and then maintain improved performance.

Conclusions

In this study we showed that relearning phonological skills was supported by residual language regions along with the recruitment of non-language regions within the dorsal attention network. It is not surprising that rehabilitation relied on these preserved regions, as phonology is a strongly left-lateralized language domain and the pseudoword reading task was challenging in the face of damage to the dorsal language pathway. It was surprising, however, that increased activation of these regions returned to initial levels after the second phase of treatment. Overall, it is encouraging to observe that improved performance can be maintained with less apparent effort. This notion has practical implications for treatment, suggesting that training performance beyond initial mastery is valuable. Finally, our study showed that the contribution of non-language cognitive support may vary over the course of treatment, which highlights the importance of examining performance and imaging at

various time points throughout the rehabilitation program to understand how language and non-language domains interact to promote treatment-induced recovery.

Supplementary Material

Refer to Web version on PubMed Central for supplementary material.

Acknowledgments

This work was supported by the National Institute on Deafness and Other Communication Disorders (DC007646 to P.M.B., DC010878 to S.M.W, and DC014389 to A.T.D) and the University of Arizona. We thank Scott Squire for assistance with imaging data collection, and the individuals who participated in our study.

References

- Alexander MP, Friedman RB, Loverso F, Fischer RS. Lesion localization of phonological agraphia. *Brain and Language*. 1992; 43(1):83–95. [PubMed: 1643513]
- Andersen SM, Rapcsak SZ, Beeson PM. Cost function masking during normalization of brains with focal lesions: still a necessity? *NeuroImage*. 2010; 53(1):78–84. <https://doi.org/10.1016/j.neuroimage.2010.06.003>. [PubMed: 20542122]
- Beauvois MF, Derouesne J. Phonological alexia: three dissociations. *Journal of Neurology, Neurosurgery & Psychiatry*. 1979; 42(12):1115–1124.
- Beeson PM, Rising K, DeMarco AT, Foley T, Rapcsak SZ. The nature and treatment of phonological text agraphia. *Neuropsychological Rehabilitation*. 2016:1–21.
- Beeson PM, Rising K, Kim ES, Rapcsak SZ. A treatment sequence for phonological alexia/agrapia. *Journal of Speech, Language, and Hearing Research: JSLHR*. 2010; 53(2):450–468. [https://doi.org/10.1044/1092-4388\(2009/08-0229\)](https://doi.org/10.1044/1092-4388(2009/08-0229)).
- Binder JR, Medler DA, Desai R, Conant LL, Liebenthal E. Some neurophysiological constraints on models of word naming. *NeuroImage*. 2005; 27(3):677–693. <https://doi.org/10.1016/j.neuroimage.2005.04.029>. [PubMed: 15921937]
- Brownsett SLE, Warren JE, Geranmayeh F, Woodhead Z, Leech R, Wise RJS. Cognitive control and its impact on recovery from aphasic stroke. *Brain*. 2014; 137(1):242–254. <https://doi.org/10.1093/brain/awt289>. [PubMed: 24163248]
- Carlomagno S, Parlato V. Writing rehabilitation in brain damaged adult patients: A cognitive approach. *Cognitive Approaches in Neuropsychological Rehabilitation*. 1989:175–209.
- Cochran WG. The χ^2 test of goodness of fit. *The Annals of Mathematical Statistics*. 1952:315–345.
- Dosenbach NUF, Fair DA, Miezin FM, Cohen AL, Wenger KK, Dosenbach RAT, ... Petersen SE. Distinct brain networks for adaptive and stable task control in humans. *Proceedings of the National Academy of Sciences*. 2007; 104(26):11073–11078. <https://doi.org/10.1073/pnas.0704320104>.
- Fedio P, August A, Patronas N, Sato S, Kufta C. Semantic, phonological, and perceptual changes following left and right intracarotid injection (Wada) with a low amytal dosage. *Brain and Cognition*. 1997; 33(1):98–117. <https://doi.org/10.1006/brcg.1997.0886>. [PubMed: 9056278]
- Fedorenko E, Duncan J, Kanwisher N. Broad domain generality in focal regions of frontal and parietal cortex. *Proceedings of the National Academy of Sciences of the United States of America*. 2013; 110(41):16616–16621. <https://doi.org/10.1073/pnas.1315235110>. [PubMed: 24062451]
- Fiez JA, Balota DA, Raichle ME, Petersen SE. Effects of lexicality, frequency, and spelling-to-sound consistency on the functional anatomy of reading. *Neuron*. 1999; 24(1):205–218. [PubMed: 10677038]
- Friedman RB. Phonological text alexia: Poor pseudoword reading plus difficulty reading functors and affixes in text. *Cognitive Neuropsychology*. 1996; 13(6):869–885.
- Gazzaniga MS. Cerebral specialization and interhemispheric communication: Does the corpus callosum enable the human condition? *Brain*. 2000; 123(7):1293–1326. <https://doi.org/10.1093/brain/123.7.1293>. [PubMed: 10869045]

- Geranmayeh F, Brownsett SLE, Wise RJS. Task-induced brain activity in aphasic stroke patients: what is driving recovery? *Brain*. 2014; 137(10):2632–2648. <https://doi.org/10.1093/brain/awu163>. [PubMed: 24974382]
- Glover GH, Law CS. Spiral-in/out BOLD fMRI for increased SNR and reduced susceptibility artifacts. *Magnetic Resonance in Medicine: Official Journal of the Society of Magnetic Resonance in Medicine/Society of Magnetic Resonance in Medicine*. 2001; 46(3):515–522.
- Golfinopoulos E, Tourville JA, Guenther FH. The integration of large-scale neural network modeling and functional brain imaging in speech motor control. *NeuroImage*. 2010; 52(3):862–874. <https://doi.org/10.1016/j.neuroimage.2009.10.023>. [PubMed: 19837177]
- Goodglass, H., Kaplan, E., Weintraub, S. *The Boston Naming Test*. Philadelphia: Lea & Febiger; 1983.
- Graves WW, Desai R, Humphries C, Seidenberg MS, Binder JR. Neural Systems for Reading Aloud: A Multiparametric Approach. *Cerebral Cortex*. 2010; 20(8):1799–1815. <https://doi.org/10.1093/cercor/bhp245>. [PubMed: 19920057]
- Guenther FH. Cortical interactions underlying the production of speech sounds. *Journal of Communication Disorders*. 2006; 39(5):350–365. <https://doi.org/10.1016/j.jcomdis.2006.06.013>. [PubMed: 16887139]
- Henry ML, Beeson PM, Stark AJ, Rapcsak SZ. The role of left perisylvian cortical regions in spelling. *Brain and Language*. 2007; 100(1):44–52. [PubMed: 16890279]
- Hickok G, Poeppel D. The cortical organization of speech processing. *Nature Reviews Neuroscience*. 2007; 8(5):393–402. <https://doi.org/10.1038/nrn2113>. [PubMed: 17431404]
- Hillis Trupe E. Effectiveness of retraining phoneme to grapheme conversion. *Clinical Aphasiology*. 1986; 16:163–171.
- Ihnen, SKZ., Petersen, SE., Schlaggar, BL. Separable roles for attentional control sub-systems in reading tasks: a combined behavioral and fMRI study. *Cerebral Cortex*. 2015. <https://doi.org/10.1093/cercor/bht313>
- Jobard G, Crivello F, Tzourio-Mazoyer N. Evaluation of the dual route theory of reading: a meta-analysis of 35 neuroimaging studies. *Neuroimage*. 2003; 20(2):693–712. [PubMed: 14568445]
- Kendall D, Conway T, Rosenbek J, Gonzalez-Rothi L. Case study Phonological rehabilitation of acquired phonologic alexia. *Aphasiology*. 2003; 17(11):1073–1095.
- Kertesz, A. *The Western Aphasia Battery*. New York: Grune & Stratton; 1982.
- Kiran S. Training phoneme to grapheme conversion for patients with written and oral production deficits: A model-based approach. *Aphasiology*. 2005; 19(1):53–76.
- Kruskal WH, Wallis WA. Use of Ranks in One-Criterion Variance Analysis. *Journal of the American Statistical Association*. 1952; 47(260):583–621. <https://doi.org/10.1080/01621459.1952.10483441>.
- Lott SN, Carney AS, Glezer LS, Friedman RB. Overt use of a tactile/kinaesthetic strategy shifts to covert processing in rehabilitation of letter-by-letter reading. *Aphasiology*. 2010; 24(11):1424–1442. <https://doi.org/10.1080/02687030903580333>. [PubMed: 21170161]
- Lott SN, Friedman RB. Can treatment for pure alexia improve letter-by-letter reading speed without sacrificing accuracy? *Brain and Language*. 1999; 67(3):188–201. [PubMed: 10210630]
- Luzzatti C, Colombo C, Frustaci M, Vitolo F. Rehabilitation of spelling along the sub-word-level routine. *Neuropsychological Rehabilitation*. 2000; 10(3):249–278.
- McNemar Q. Note on the sampling error of the difference between correlated proportions or percentages. *Psychometrika*. 1947; 12(2):153–157. [PubMed: 20254758]
- Mechelli A, Crinion JT, Long S, Friston KJ, Lambon Ralph MA, Patterson K, McClelland JL, Price CJ. Dissociating reading processes on the basis of neuronal interactions. *Journal of Cognitive Neuroscience*. 2005; 17(11):1753–1765. <https://doi.org/10.1162/089892905774589190>. [PubMed: 16269111]
- Patterson, K., Marcel, A. Phonological ALEXIA or PHONOLOGICAL alexia?. 1992. Retrieved from <http://doi.apa.org/psycinfo/1992-98724-015>
- Power JD, Cohen AL, Nelson SM, Wig GS, Barnes KA, Church JA, Vogel AC, Laumann TO, Miezin FM, Schlagger BL, Petersen SE. Functional Network Organization of the Human Brain. *Neuron*. 2011; 72(4):665–678. <https://doi.org/10.1016/j.neuron.2011.09.006>. [PubMed: 22099467]

- Power JD, Schlaggar BL, Lessov-Schlaggar CN, Petersen SE. Evidence for Hubs in Human Functional Brain Networks. *Neuron*. 2013; 79(4):798–813. <https://doi.org/10.1016/j.neuron.2013.07.035>. [PubMed: 23972601]
- Rapcsak SZ, Beeson PM, Henry ML, Leyden A, Kim E, Rising K, Andersen S, Cho HS. Phonological dyslexia and dysgraphia: Cognitive mechanisms and neural substrates. *Cortex*. 2009; 45(5):575–591. [PubMed: 18625494]
- Raymer AM, Beeson P, Holland A, Kendall D, Maher LM, Martin N, Murray L, Rose M, Thompson CK, Turkstra L, Altmann L, Boyle M, Conway T, Hula W, Kearns K, Rapp B, Simmons-Mackie N, Gonzalez Rothi LJ. Translational research in aphasia: from neuroscience to neurorehabilitation. *Journal of Speech, Language, and Hearing Research: JSLHR*. 2008; 51(1):S259–275. [https://doi.org/10.1044/1092-4388\(2008/020\)](https://doi.org/10.1044/1092-4388(2008/020)).
- Roeltgen DP, Sevush S, Heilman KM. Phonological agraphia: writing by the lexical-semantic route. *Neurology*. 1983; 33(6):755–765. [PubMed: 6682519]
- Saur D, Kreher BW, Schnell S, Kümmerer D, Kellmeyer P, Vry MS, Umarova R, Musso M, Glauche V, Abel S, Huber W, Rijntjes M, Hennig J, Weiller C. Ventral and dorsal pathways for language. *Proceedings of the National Academy of Sciences*. 2008; 105(46):18035–18040.
- Shallice T. Phonological agraphia and the lexical route in writing. *Brain: A Journal of Neurology*. 1981; 104(3):413. [PubMed: 7272708]
- Small SL, Flores DK, Noll DC. Different Neural Circuits Subserve Reading before and after Therapy for Acquired Dyslexia. *Brain and Language*. 1998; 62(2):298–308. <https://doi.org/10.1006/brln.1998.1951>. [PubMed: 9576825]
- Taylor, JSH., Rastle, K., Davis, MH. Can cognitive models explain brain activation during word and pseudoword reading? A meta-analysis of 36 neuroimaging studies. *Psychological Bulletin*. 2012. <https://doi.org/10.1037/a0030266>
- Thompson CK, den Ouden DB. Neuroimaging and recovery of language in aphasia. *Current Neurology and Neuroscience Reports*. 2008; 8(6):475–483. [PubMed: 18957184]
- Viera AJ, Garrett JM. Understanding interobserver agreement: the kappa statistic. *Fam Med*. 2005; 37(5):360–363. [PubMed: 15883903]
- Vigneau M, Beaucousin V, Hervé PY, Duffau H, Crivello F, Houdé O, Mazoyer B, Tzourio-Mazoyer N. Meta-analyzing left hemisphere language areas: phonology, semantics, and sentence processing. *NeuroImage*. 2006; 30(4):1414–1432. <https://doi.org/10.1016/j.neuroimage.2005.11.002>. [PubMed: 16413796]
- Vigneau M, Beaucousin V, Hervé PY, Jobard G, Petit L, Crivello F, Mellet E, Zago L, Mazoyer B, Tzourio-Mazoyer N. What is right-hemisphere contribution to phonological, lexico-semantic, and sentence processing? Insights from a meta-analysis. *NeuroImage*. 2011; 54(1):577–593. <https://doi.org/10.1016/j.neuroimage.2010.07.036>. [PubMed: 20656040]
- Vincent JL, Kahn I, Snyder AZ, Raichle ME, Buckner RL. Evidence for a frontoparietal control system revealed by intrinsic functional connectivity. *Journal of Neurophysiology*. 2008; 100(6):3328–3342. <https://doi.org/10.1152/jn.90355.2008>. [PubMed: 18799601]
- Wada J. A new method for the determination of the side of cerebral speech dominance: a preliminary report on the intracarotid injection of sodium amytal in man. *Igaku Seibutsugaku*. 1949; 14:221–222.
- Wada J, Rasmussen T. Intracarotid injection of sodium amytal for the lateralization of cerebral speech dominance: experimental and clinical observations. *Journal of Neurosurgery*. 1960; 17(2):266–282.
- Wilson SM, DeMarco AT, Henry ML, Gesierich B, Babiak M, Mandelli ML, Miller BL, Gorno-Tempini ML. What Role Does the Anterior Temporal Lobe Play in Sentence-level Processing? Neural Correlates of Syntactic Processing in Semantic Variant Primary Progressive Aphasia. *Journal of Cognitive Neuroscience*. 2014; 26(5):970–985. https://doi.org/10.1162/jocn_a_00550. [PubMed: 24345172]
- Worsley KJ, Liao CH, Aston J, Petre V, Duncan GH, Morales F, Evans AC. A general statistical analysis for fMRI data. *Neuroimage*. 2002; 15(1):1–15. [PubMed: 11771969]

Zaidel E, Peters AM. Phonological encoding and ideographic reading by the disconnected right hemisphere: Two case studies. *Brain and Language*. 1981; 14(2):205–234. [https://doi.org/10.1016/0093-934X\(81\)90077-8](https://doi.org/10.1016/0093-934X(81)90077-8). [PubMed: 7306782]

Author Manuscript

Author Manuscript

Author Manuscript

Author Manuscript

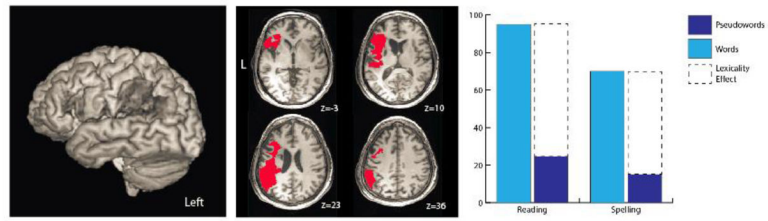


Figure 1.

JW's lesion and behavioral profile. Surface rendering of JW's lesion (left); axial slices depicting JW's lesion in red ($z = -3, 10, 23, 36$; center). JW's profile of phonological alexia/agraphia accompanied by the hallmark reading/spelling lexicality effect (right) with words > pseudowords.

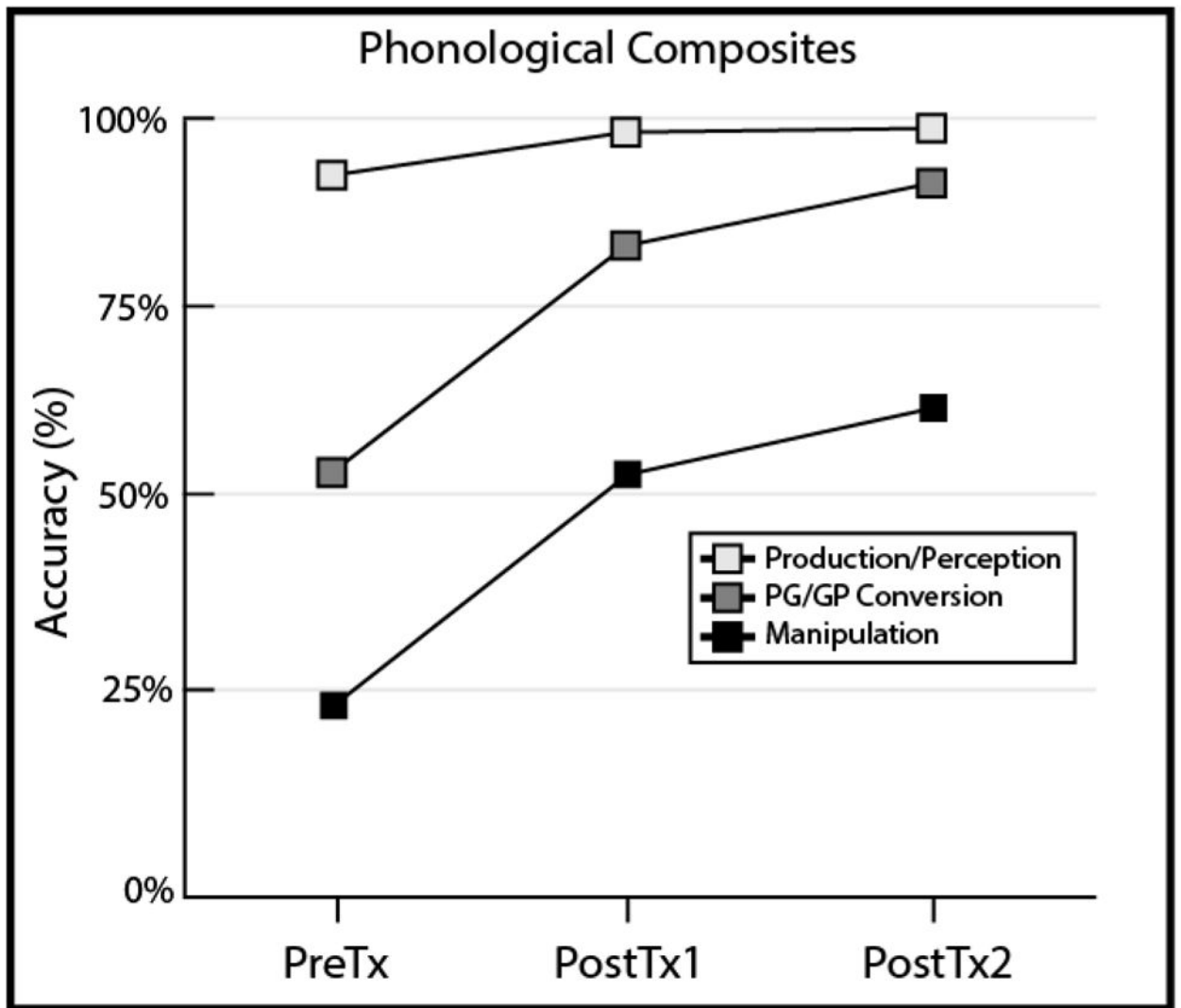
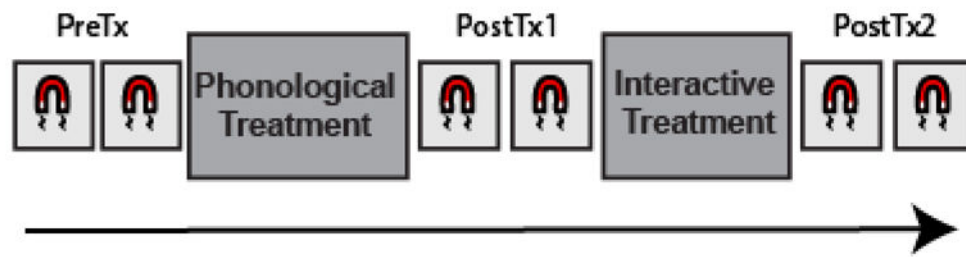


Figure 2.

Figure showing behavioral generalization from treatment to three composites of phonological tests, including tests of phonological perception and production (light gray), tests of transcoding between graphemes and phonemes, and vice versa (dark gray), and tests of phonological processing that require manipulation (black).

a Overview of imaging schedule



b Reading aloud to activate phonology

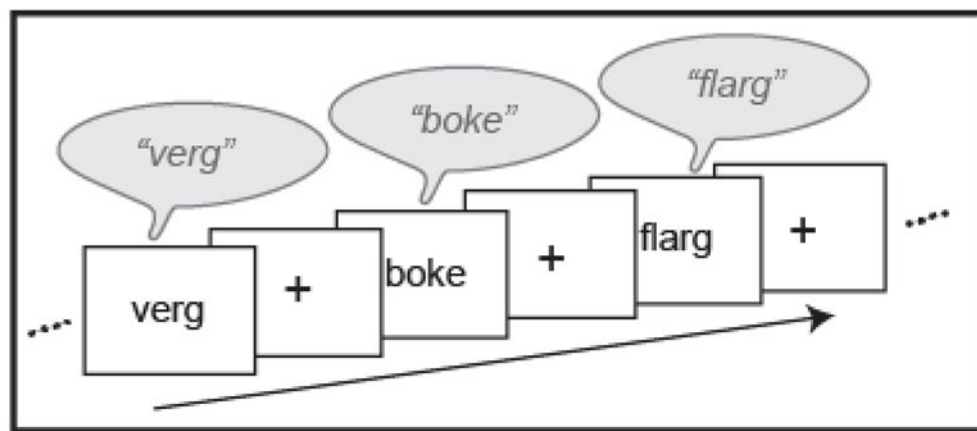


Figure 3. Schematic overview of the study, which consisted of two pre-treatment imaging sessions, two imaging sessions following phase one of treatment, and finally two more imaging sessions following phase two of treatment.

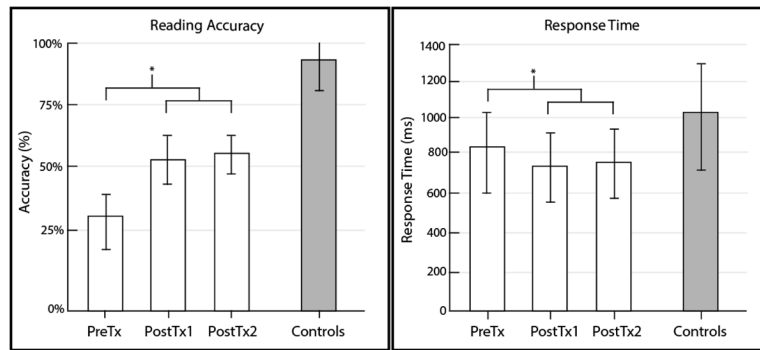


Figure 4. Mean and SEM for reading accuracy (left) and response time (right) for overt pseudoword reading in the scanner for JW at each phase of treatment (white). Control subjects shown to right in gray for comparison. * = $p < 0.05$.

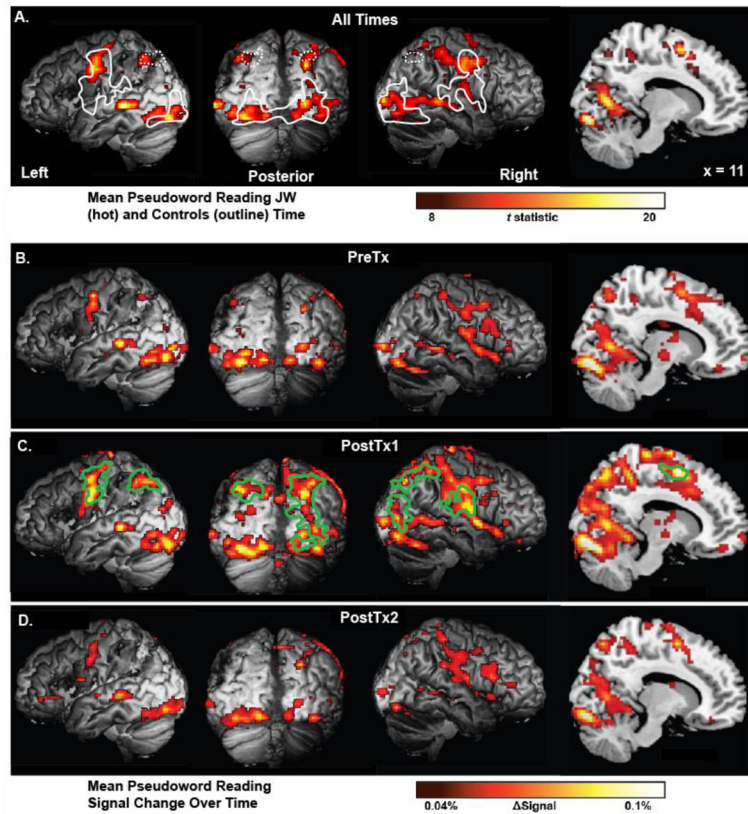


Figure 5.

Top pane showing (A) t -map of regions engaged during accurate pseudoword reading (thresholded at $t > 8$ for illustration). Regions of significant activation for the control group are outlined in white to illustrate the similarities between the patient's and controls' activation patterns (corrected voxelwise $p < .005$, corrected for cluster extent, $p < .05$). White dotted lines indicate *a priori* regions of interest that did not meet full cluster correction for our control group. Lower series of panes show effect size maps of regions engaged during accurate pseudoword reading prior to treatment (B), following phase one of treatment (C), and following phase two of treatment (D). Uncorrected signal change is plotted to illustrate the similarities between activation patterns at each phase of treatment. Green outlines in pane C indicate regions of significant increase following phase one of treatment which returned to baseline following phase two of treatment (via conjunction, each contrast corrected voxelwise $p < .005$ and for cluster extent $p < .05$)

Table 1

Whole brain activation in pseudoword reading for controls ($N=7$), $p < .001$

Brain Region	MINI Coordinates			Extent (mm ³)	Max <i>T</i>	<i>P</i> value
	x	y	z			
Bilateral inferior occipital gyri, cerebellum, right posterior middle temporal gyrus				49,368		< .001
Left inferior occipital	-26	-94	-7		12.39	
Right inferior occipital	30	-94	-9		9.97	
Left inferior occipital	-37	-56	-17		6.69	
Right vertical occip. Sulcus	33	-81	24		12.54	
Right cerebellum	15	-64	-24		3.99	
Left cerebellum	-32	-57	-26		4.44	
Right mid-posterior temporal	52	-46	-3		5.13	
Left frontal, parietal, temporal lobes, insula, basal ganglia				47,824		< .001
Left frontal lobe						
pIFG, pars triangularis	-46	26	17		5.54	
pIFG, pars opercularis	-52	9	19		7.73	
Dorsal precentral sulcus	-41	3	52		11.08	
Central sulcus	-57	-4	39		10.56	
Left parietal lobe						
Post-central sulcus	-55	-16	38		10.76	
Supramarginal gyrus	-56	-43	36		11.64	
Left temporal lobe						
Posterior STS	-50	-33	8		9.71	
Left basal ganglia	-20	-8	4		10.76	
Left insula	-41	-4	-8		7.01	
Right frontal, parietal, temporal lobes, insula				27,400		< .001
Right frontal lobe						
Pre-central sulcus	59	-1	25		11.85	
Central sulcus	51	-7	40		13.54	
Right parietal lobe						

Brain Region	MNI Coordinates			Extent (mm ³)	Max <i>T</i>	<i>P</i> value
	<i>x</i>	<i>y</i>	<i>z</i>			
Post-central sulcus	60	-12	26		10.53	
Right temporal lobe						
Posterior STS	52	-36	9		10.04	
Sylvian fissure	56	-23	16		9.59	
Right Insula	45	1	5		12.75	
Posterior cingulate/supplementary motor area				7,576		0.005
Right SMA	8	6	59		6.25	
Left posterior cingulate	-4	-2	50		5.61	
Left SMA	-5	-8	68		8.91	
Left intraparietal sulcus*	-35	-60	53	3,928	6.82	0.005 (unc.) 0.081 (corr)
Right intraparietal sulcus*	32	-69	52	2,944	5.96	0.013 (unc.) 0.81 (corr)

MNI coordinates for multiple regions within a cluster are local maxima.

* Indicates a region did not meet full cluster correction, but was treated as an a priori region of interest.