

# Activation of disease during therapy with alemtuzumab in 3 patients with multiple sclerosis

Thomas Wehrum, MD,\* Lena-Alexandra Beume, MD,\* Oliver Stich, MD, Irina Mader, MD, Mathias Mäurer, MD, Adam Czaplinski, MD, Cornelius Weiller, MD, and Sebastian Rauer, MD

*Neurology*® 2018;90:e1-e5. doi:10.1212/WNL.0000000000004950

## Correspondence

Dr. Wehrum  
thomas.wehrum@  
uniklinik-freiburg.de

## Abstract

### Objective

To report 3 patients with multiple sclerosis showing severe activation of disease during immunotherapy with alemtuzumab.

### Methods

Retrospective case series.

### Results

Patient 1, a 21-year-old woman, developed severe cognitive impairment, sight deterioration, severe gait ataxia, urinary retention, and extensive progression of cerebral lesion load, including new lesions that exhibited gadolinium ring enhancement and dominance of CD19/20-positive B lymphocytes, 6 months after induction of alemtuzumab. Patient 2, a 28-year-old man, developed left-sided hemihypesthesia and ~60 new cerebral and spinal lesions including lesions with gadolinium ring enhancement 6 months after induction of alemtuzumab. Patient 3, a 37-year-old woman, developed ataxia and numbness of the left thigh, 16 new gadolinium-positive supratentorial lesions, and partly ring-enhancing and dominance of CD19/20-positive B lymphocytes 6 months after induction of alemtuzumab.

### Conclusion

This is a case series reporting severe activation of disease during immunotherapy with alemtuzumab. All patients showed onset of symptoms 6 months after induction of alemtuzumab, strikingly similar MRI lesion morphology, and unexpected high total B cell count, which may suggest a B-cell-mediated activation of disease. Whether this is due to different rates of B- and T cell repopulation has to be the subject of further research. Moreover, further effects on the interactions between the adaptive and innate immunity as well as between B and T cell lineages might explain the observed disease activation.

## RELATED ARTICLE

### Editorial

Defining response profiles after alemtuzumab Rare paradoxical disease exacerbation

Page 309

\*These authors contributed equally to this work.

From the Departments of Neurology and Neuroscience (T.W., L.-A.B., O.S., C.W., S.R.) and Neuroradiology (I.M.), Medical Center—University of Freiburg, Faculty of Medicine, University of Freiburg; Department of Neurology (M.M.), Stiftung Juliusspital Würzburg, Germany; and Neurozentrum Bellevue (A.C.), Zürich, Switzerland.

Go to [Neurology.org/N](http://Neurology.org/N) for full disclosures. Funding information and disclosures deemed relevant by the authors, if any, are provided at the end of the article.

# Glossary

MS = multiple sclerosis; RRMS = relapsing-remitting multiple sclerosis.

Alemtuzumab is a humanized monoclonal antibody that targets the CD52 antigen on the surface of most lymphocyte lineages, leading to rapid and prolonged lymphocyte depletion. It is administered over 2 IV treatment courses at a 12-month interval<sup>1</sup> and is currently considered to be one of the most effective immunotherapeutics for relapsing-remitting multiple sclerosis (RRMS).<sup>2</sup> Treatment with alemtuzumab can be associated with serious side effects, among them an increased risk of developing autoimmune disorders.<sup>1</sup> Two recent articles report a total of 11 cases of disease activation following treatment with alemtuzumab.<sup>3,4</sup> We present 3 additional cases with strikingly similar features (i.e., time of onset of disease activation, lesion morphology, and response to B-cell-depleting therapy).

## Methods

We present a retrospective case series of 3 patients with RRMS showing severe activation of disease during immunotherapy with alemtuzumab.

## Results

Our patients had a long history of RRMS (7–15 years) with multiple relapses and had previously received treatment with different disease-modifying drugs. Details on each patient are given in the table. The decision to start the treatment with alemtuzumab was made after the previous treatments either failed or had to be discontinued because of side effects. Baseline MRI (1–4 weeks before first dose) showed multiple sclerosis (MS)–typical lesions (Magnetic Resonance Imaging in Multiple Sclerosis [MAGNIMS] criteria) in the deep and peripheral white matter (~50 including 4 gadolinium-enhancing lesions in patient 1; ~30 and ~40 without gadolinium enhancement in patients 2 and 3), 2 lesions in thalamus and midbrain in patient 1, and 3 and ~10 lesions (2 with gadolinium enhancement) in the cervical and thoracic medulla in patients 1 and 2. The optic nerves were not affected. Strikingly, the symptoms of all 3 patients deteriorated 6 months after the first course of alemtuzumab. The Expanded Disability Status Scale increased by 0.5–6.0 points.

**Table** Characteristics of the 3 presented cases

	Patient 1	Patient 2	Patient 3
<b>Age, y/sex</b>	21/F	28/M	37/F
<b>Diagnosis of RRMS, y</b>	2008	2011	2010
<b>Case history</b>	Multiple relapses with cognitive impairment, sight deterioration, gait ataxia, and severe fatigue since 2008	Multiple relapses with spinal para- and left-sided hemihypesthesia, fine motor impairment, and optic neuritis since 2003	2 Relapses in 2010 with ataxia and hypesthesia of the left thigh
<b>Medication history (reasons for change of medication)</b>	4 Months interferon- $\beta$ (elevated liver enzymes), 6 months glatiramer acetate (treatment failure), 5 years natalizumab (seroconversion to anti-JCV+), fingolimod (allergic reaction on first dose), 6 months dimethyl fumarate (treatment failure), alemtuzumab first dose October 2014	3 Years fingolimod (treatment failure), 1 year dimethyl fumarate (treatment failure), alemtuzumab first dose March 2015	3 Years natalizumab (seroconversion to anti-JCV+), 1 year fingolimod (treatment failure), alemtuzumab first dose July 2014
<b>EDSS before alemtuzumab</b>	1.0	1.5	2.0
<b>Symptom onset</b>	6 Months after alemtuzumab	6 Months after alemtuzumab	6 Months after alemtuzumab
<b>Clinical presentation (initial symptoms)</b>	Cognitive impairment, sight deterioration, gait ataxia, and urinary retention (EDSS 7.0)	Left-sided hemihypesthesia (EDSS 2.0)	Ataxia, numbness left thigh (EDSS 2.5)
<b>Lymphocyte phenotyping</b>	Dominance of CD19/20-positive B lymphocytes	Not performed	Dominance of CD19/20-positive B lymphocytes
<b>Therapy</b>	Plasmapheresis for 7 days and repeated high-dose methylprednisolone treatment (1,000 mg/day), induction of rituximab (375 mg/m <sup>2</sup> BSA)	High-dose methylprednisolone treatment (1,000 mg/day), induction of rituximab (375 mg/m <sup>2</sup> BSA)	High-dose methylprednisolone treatment (1,000 mg/day), induction of rituximab (375 mg/m <sup>2</sup> BSA)
<b>Course after rituximab</b>	No new relapses (clinically or on MRI) during 18 months follow-up (EDSS 1.0)	No new relapses (clinically or on MRI) during 12 months follow-up (EDSS 1.5)	No new relapses (clinically or on MRI) during 12 months follow-up (EDSS 2.0)

Abbreviations: BSA = body surface area; EDSS = Expanded Disability Status Scale; JCV = JC virus; RRMS = relapsing-remitting multiple sclerosis.

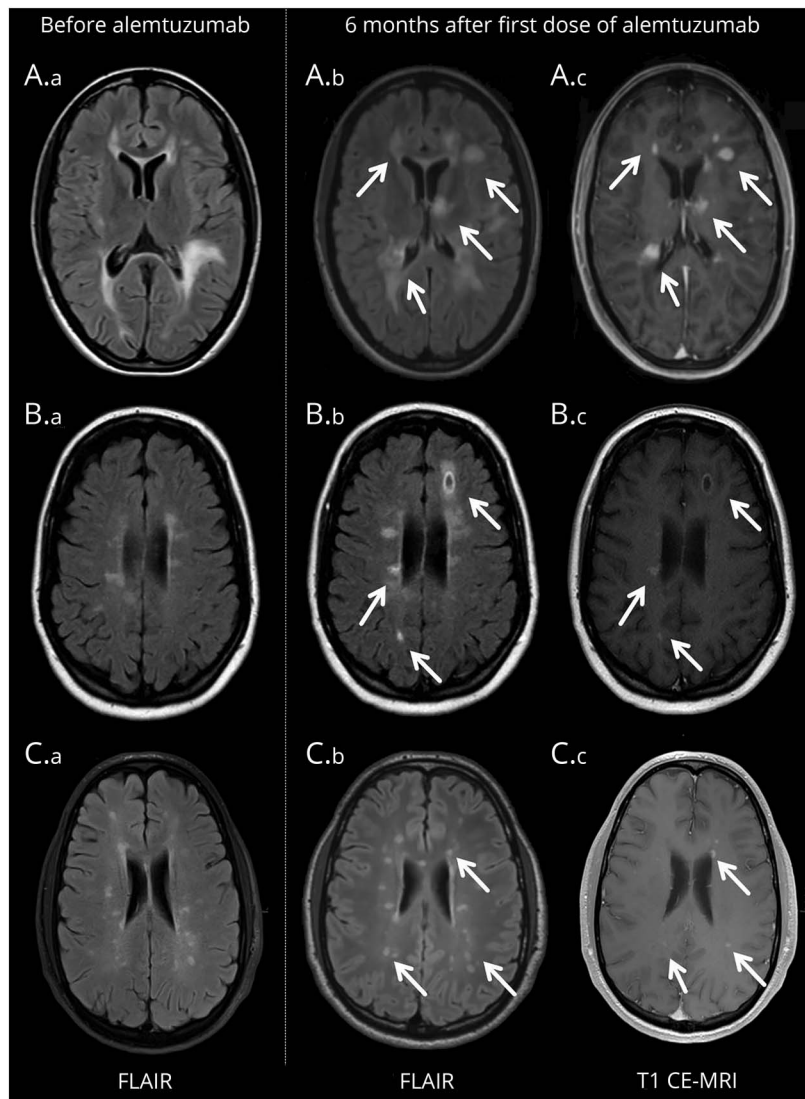
Cerebral MRI showed extensive progression of lesion load (figure 1): 15, ~60, and 16 new lesions in the deep and peripheral white matter of both hemispheres, including 14, ~20, and 2 with gadolinium enhancement (some solid appearing, some with ring enhancement) in patients 1–3. New spinal lesions (~30) were only present in patient 2. The optic nerves were not affected. CSF analysis ruled out JC virus and other viral, bacterial, parasitic, and fungal infections as well as lymphoma; no autoantibodies (e.g., thyroid) were detected in the patients. Furthermore, serum lymphocyte phenotyping revealed dominance of CD19/20-positive B lymphocytes in 2 cases. All patients improved clinically after plasmapheresis (7 days) or treatment with high-dose methylprednisolone. The disease activity stabilized (clinically and on MRI) under B-cell-depleting treatment with rituximab, which was initiated 1 to 2 months after deterioration

and resulted in sufficient B cell depletion. No relapses were reported after a follow-up period of at least 1 year.

## Discussion

The authors of one recent case series in *The Lancet Neurology*<sup>3</sup> presenting also with rapid clinical deterioration 6 months after the initial course of alemtuzumab hypothesized a B-cell-mediated pathogenesis of disease activation. Due to the striking similarity of our reported cases, we discuss the facts favoring this hypothesis but also present alternative explanations. First, the pharmacodynamics of alemtuzumab support a B-cell-mediated pathogenesis in our cases: alemtuzumab leads to a CD52-selective depletion of B and T lymphocytes.<sup>5</sup> Reconstitution of T cells is slow, with CD4+ T cells and CD8+ T cells reaching 9% and 13% of baseline levels after 3

**Figure 1** Cerebral MRI before and after alemtuzumab



Images before and after alemtuzumab are provided for cases 1–3 (A–C). Fluid-attenuated inversion recovery (FLAIR) images (A.a, B.a, C.a) were obtained directly before the first dose of alemtuzumab. FLAIR images (A.b, B.b, C.b) were obtained 6 months after the first dose, when a relapse occurred, and show massive progression of lesion load (white arrows) including gadolinium ring enhancement (A.c, B.c, C.c).

months and 36% and 71% after 12 months. Repopulation of B lymphocytes, on the other hand, usually occurs more rapidly, with a return of the total B cell count to normal levels after 3 months and to above normal values (165% of baseline) after 12 months.<sup>6</sup> In one of our patients, details regarding the lymphocyte count were available at different points in time. In line with the literature,<sup>6</sup> CD4+ T cells and CD8+ T cells were slow to reconstitute, reaching 23% and 19% by month 6. However, the total B cell count (baseline  $0.28 \times 10^9/L$ ) had risen to  $0.72 \times 10^9/L$  (257%) after 6 months, and accordingly was more than twice as high as the B cell count reported in the literature<sup>6</sup> by month 6 (figure 2). The reconstituting B cell pool is initially dominated by mature naive cells,<sup>6</sup> possibly responsible for the B-cell-mediated autoimmunity in alemtuzumab treatment (e.g., idiopathic thrombocytopenic purpura, Goodpasture syndrome, thyroid disease).<sup>1</sup> Yet it is currently not understood why B-cell-mediated autoimmunity does not lead to an exacerbation of MS. B cell counts at the time of disease activation were not provided in the 2 other recent case series on disease activity during immunotherapy with alemtuzumab.<sup>3,4</sup> However, in one series, the authors state that in 4 patients lymphocytes reconstituted more rapidly than expected (3 months),<sup>4</sup> which may be a sign of overshooting B cell response. Also, the gadolinium ring-enhancing cerebral lesions, which are seen in other B-cell-mediated diseases involving the CNS, may be further evidence of a B-cell-mediated pathogenesis<sup>7</sup> and were also reported or depicted in the case series.<sup>3,4</sup> However, ring-enhancing lesions may not be exclusive to B-cell-mediated disease<sup>8</sup>; therefore their value as a biomarker may be limited. Finally, clinical observations support a B-cell-mediated pathogenesis. In one case, plasmapheresis led to a significant reduction of symptoms in the acute phase, which suggests that humoral factors may have played a crucial role in the pathophysiology; interestingly, plasmapheresis in the acute phase of deterioration was also applied in 1 of the 2 cases published in

*The Lancet Neurology* and led to marked clinical improvement.<sup>3</sup> In all cases, B-cell-depleting therapy with rituximab was initiated and stabilized the course of the disease, which was also true for 2 patients in 1 of the 2 other case series.<sup>3</sup> However, it remains unclear if a further early alemtuzumab course would have been another possible treatment option, as it also results in B cell depletion and according to the literature some patients need more than 2 courses to achieve disease stability.<sup>9</sup>

Although these observations may support a B-cell-mediated pathogenesis, disease activation could also be explained by a compartment problem, seeing that all patients had received fingolimod in the past. A substantial number of lymphocytes could remain hidden from the intravascular therapeutic effects of alemtuzumab as a result of selective lymphoid sequestration and may later egress from lymph nodes and initiate rebound inflammatory activity, as suggested by a case series on disease activation after switching from fingolimod to alemtuzumab.<sup>4</sup> Interestingly, all of our patients received fingolimod prior to alemtuzumab, although only one patient switched directly from fingolimod to alemtuzumab (patient 3) and treatment with fingolimod was stopped on day 1 in patient 1. Similarly, 10 out of the 11 published cases<sup>3,4</sup> had also received fingolimod prior to alemtuzumab, undermining this hypothesis.

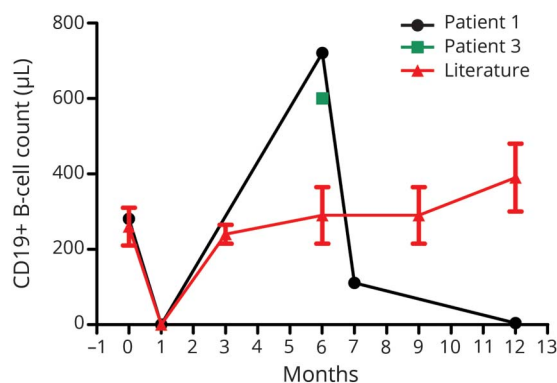
Also, alemtuzumab has been shown to exacerbate neuro-myelitis optica spectrum disorder in single patients. This finding was interpreted as indicative for a suppression of the adaptive immunity and possible activation of monocytes by alemtuzumab, reflecting on the fact that CDS2 is also expressed at lower levels on monocytes as well as natural killer cells and macrophages.<sup>10</sup> Alemtuzumab might thus have further effects on the interactions between the adaptive and innate immunity as well as interaction between B and T cell lineages than known so far, which might explain the observed disease activation.

When discussing treatment options with the patient, practitioners should consider not only nonresponse, but also the potential reactivation of disease treated with alemtuzumab. Identifying patients at risk of disease activation using reliable biomarkers (i.e., lymphocyte phenotyping and specific MRI features) remains a major challenge. Finally, the pathogenesis of disease activation after alemtuzumab needs further study, including identification of specific targets of treatment in this subgroup of patients at risk of disease activation.

### Author contributions

Each author contributed significantly to the submitted work: Drs. Wehrum, Beume, Stich, Weiller, and Rauer treated the case patient at the Freiburg center, conceived the study, analyzed the data, and drafted the manuscript. Dr. Mader evaluated the MRI, analyzed the data, and revised the manuscript. Dr. Mäurer treated the case patient at the Würzburg center, conceived the study, analyzed the data, and revised the

**Figure 2** B cell count during alemtuzumab treatment



B cell count at baseline (before alemtuzumab), at month 6 (onset of disease activity), at month 7 (after first course of rituximab), and at month 11 (during therapy with rituximab) in patient 2 (dark, dots); B cell count after 6 months (onset of disease activity) in patient 3 (green, square); and B cell count ( $\pm$ SD) at baseline and months 3, 6, 9, and 12 as reported in the literature<sup>6</sup> (red, triangle).

manuscript. Dr. Czaplinski treated the case patient at the Zürich center, conceived the study, analyzed the data, and revised the manuscript.

### Acknowledgment

The authors thank Dr. Konrad Whittaker for proofreading the final version of this manuscript.

### Study funding

No targeted funding reported.

### Disclosure

T. Wehrum and L. Beume report no disclosures relevant to the manuscript. O. Stich reports receiving consulting and lecture fees and grant and research support from Baxter, Bayer Vital GmbH, Biogen Idec, Genzyme, Merck Serono, Novartis, Sanofi-Aventis, and Teva. I. Mader received a lecture fee from UCB Pharma, Monheim, Germany. M. Mäurer reports receiving consulting and lecture fees and grant and research support from Baxter, Bayer Vital GmbH, Biogen Idec, Genzyme, Merck Serono, Novartis, Sanofi-Aventis, and Teva. A. Czaplinski and C. Weiller report no disclosures relevant to the manuscript. S. Rauer reports receiving consulting and lecture fees and grant and research support from Baxter, Bayer Vital

GmbH, Biogen Idec, Genzyme, Merck Serono, Novartis, Sanofi-Aventis, and Teva. Go to [Neurology.org/N](http://Neurology.org/N) for full disclosures.

Received April 8, 2017. Accepted in final form October 18, 2017.

### References

1. Lemtrada [prescribing information]. Cambridge, MA: Genzyme; 2016.
2. Cohen JA, Coles AJ, Arnold DL, et al. Alemtuzumab versus interferon beta 1a as first-line treatment for patients with relapsing-remitting multiple sclerosis: a randomised controlled phase 3 trial. *Lancet* 2012;380:1819–1828.
3. Haghikia A, Dendrou CA, Schneider R, et al. Severe B-cell-mediated CNS disease secondary to alemtuzumab therapy. *Lancet Neurol* 2017;16:104–106.
4. Willis M, Pearson O, Illes Z, et al. An observational study of alemtuzumab following fingolimod for multiple sclerosis. *Neurol Neuroimmunol Neuroinflamm* 2017;4:e320.
5. Cox AL, Thompson SAJ, Jones JL, et al. Lymphocyte homeostasis following therapeutic lymphocyte depletion in multiple sclerosis. *Eur J Immunol* 2005;35:3332–3342.
6. Thompson SAJ, Jones JL, Cox AL, Compston DAS, Coles AJ. B-cell reconstitution and BAFF after alemtuzumab (Campath-1H) treatment of multiple sclerosis. *J Clin Immunol* 2010;30:99–105.
7. Slone HW, Blake JJ, Shah R, Guttikonda S, Bourekas EC. CT and MRI findings of intracranial lymphoma. *Am J Roentgenol* 2005;184:1679–1685.
8. Schwartz KM, Erickson BJ, Lucchinetti C. Pattern of T2 hypointensity associated with ring-enhancing brain lesions can help to differentiate pathology. *Neuroradiology* 2006;48:143–149.
9. Menge T, Stüve O, Kieseier BC, Hartung HP. Alemtuzumab: the advantages and challenges of a novel therapy in MS. *Neurology* 2014;83:87–97.
10. Freedman MS, Kaplan JM, Markovic-Plese S. Insights into the mechanisms of the therapeutic efficacy of alemtuzumab in multiple sclerosis. *J Clin Cell Immunol* 2013;4:1000152.