

Recovery of injured Broca's portion of arcuate fasciculus in the dominant hemisphere in a patient with traumatic brain injury

Sung Ho Jang, MD^a, Ji Wan Ha, PhD^b, Hyun Young Kim, MS^b, You Sung Seo, MS^{a,*}

Abstract

Rationale: Recovery of injured AF in patients with traumatic brain injury (TBI) has not been reported. In this study, we report on a patient with TBI who recovered from an injury to Broca's portion of AF in the dominant hemisphere, diagnosed by diffusion tensor tractography (DTT).

Patient concerns: A 28-year-old right-handed male patient suffered head trauma resulting from sliding while riding a motorcycle.

Diagnoses: He was diagnosed with a traumatic contusional hemorrhage in the left frontal lobe, subarachnoid hemorrhage, and subdural hemorrhage in the left fronto-temporal lobe.

Interventions: He underwent craniectomy on the left fronto-temporal area, and hematoma removal for the subdural hemorrhage in the neurosurgery department of a university hospital. Two weeks after the injury, he was transferred to the rehabilitation department of another university hospital. He showed severe aphasia and brain MRI showed leukomalactic lesion in the left frontal lobe.

Outcomes: The result WAB for the patient showed severe aphasia, with an aphasia quotient of 45.3 percentile. However, his aphasia improved rapidly by 9 months with an aphasia quotient at the 100.0 percentile. 2-week DTT detected discontinuity in the subcortical white matter at the branch to Broca's area of left AF. By contrast, on 9-month DTT, the discontinued portion of left AF was elongated to the left Broca's area.

Lessons: Recovery of injured Broca's portion of AF in the dominant hemisphere along with excellent improvement of aphasia was demonstrated in a patient with TBI. This study has important implications in brain rehabilitation because the mechanism of recovery from aphasia following TBI has not been elucidated.

Abbreviations: AF = arcuate fasciculus, DTI = diffusion tensor imaging, DTT = diffusion tensor tractography, ROI = regions of interest, TBI = traumatic brain injury, WAB = Western Aphasia Battery.

Keywords: arcuate fasciculus, diffusion tensor imaging, diffusion tensor tractography, head trauma, language

1. Introduction

Traumatic brain injury (TBI) is a leading cause of death and disability worldwide; incidence of TBI per 100,000 person-years is as high as 790.^[1] Eighty to 100% of patients with TBI had some form of language deficit.^[2,3] Although much is known about the

epidemiology and symptomatology of language deficit following TBI, little is known about the mechanism for recovery.^[2-6]

The arcuate fasciculus (AF), connecting Broca's and Wernicke's areas, is a main neural tract for language function.^[7] Injury of the AF causes a number of language problems, including conduction aphasia, apraxia of speech, paraphasia, and anomia.^[8-10] Diffusion tensor tractography (DTT), derived from diffusion tensor imaging (DTI), enables 3-dimensional reconstruction and estimation of the AF.^[10,11] DTT has been used to demonstrate injury of the AF in various brain pathologies.^[10,12,13] Although a recent study reported the recovery of an injured AF in the dominant hemisphere in a stroke patient,^[14] there is no report of recovery of an injured AF in patients with TBI.

In the current study, we report on a patient with TBI who showed the recovery of Broca's portion of an injured AF in the dominant hemisphere in a patient with TBI, using DTT.

2. Case report

A 28-year-old right-handed male patient suffered head trauma resulting from a sliding fall while riding a motorcycle. He was diagnosed with traumatic contusional hemorrhage in the left frontal lobe, subarachnoid hemorrhage, and subdural hemorrhage in the left fronto-temporal lobe (Fig. 1A). He underwent craniectomy on the left fronto-temporal area, and hematoma removal for subdural hemorrhage at the neurosurgery department of a university hospital. The patient lost consciousness and

Editor: N/A.

Funding: This work was supported by the National Research Foundation (NRF) of Korea Grant funded by the Korean Government (MSIP) (2015R1A2A2A01004073).

The authors have no conflicts of interest to disclose.

^a Department of Physical Medicine and Rehabilitation, College of Medicine, Yeungnam University, ^b Department of Speech Pathology, Daegu University, Daegudae-gil, Namseong-ri, Yeongcheon-si, Gyeongsangbuk-do, Republic of Korea.

* Correspondence: You Sung Seo, Department of Physical Medicine and Rehabilitation, College of Medicine, Yeungnam University, Daemyungdong, Namku, Taegu, Republic of Korea (e-mail: yousung1008@daum.net).

Copyright © 2017 the Author(s). Published by Wolters Kluwer Health, Inc. This is an open access article distributed under the terms of the Creative Commons Attribution-Non Commercial-No Derivatives License 4.0 (CCBY-NC-ND), where it is permissible to download and share the work provided it is properly cited. The work cannot be changed in any way or used commercially without permission from the journal.

Medicine (2017) 96:51(e9183)

Received: 9 August 2017 / Received in final form: 16 November 2017 /

Accepted: 18 November 2017

<http://dx.doi.org/10.1097/MD.00000000000009183>

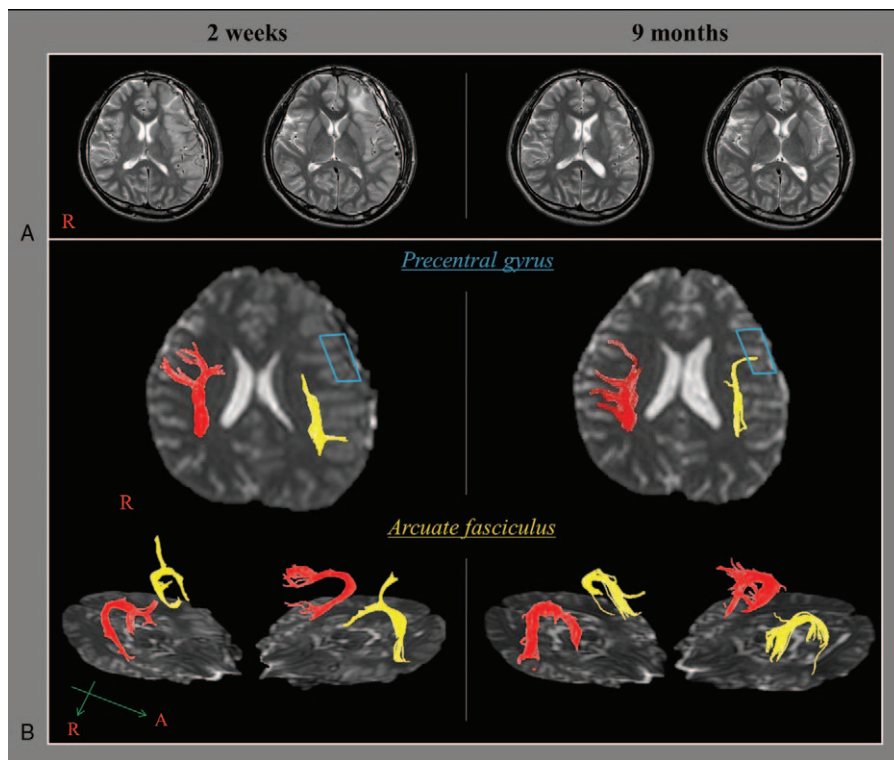


Figure 1. (A) Brain MR images at 2 weeks after injury show leukomalactic lesion in the left frontal lobe. (B) Diffusion tensor tractography for the arcuate fasciculus (AF, right AF: red color, left AF: yellow color). On 2-week DTT, the branch to Broca's area (sky-blue lined box) of the left AF is discontinued at the subcortical white matter (green arrow). By contrast, on 9-month DTT, the discontinued portion of the left AF is elongated to the left Broca's area (sky-blue lined box). AF=arcuate fasciculus, DTT=diffusion tensor tractography, MR=magnetic resonance.

experienced post-traumatic amnesia for approximately 5 minutes at the time of the crash. His Glasgow Coma Scale score was 15 when he arrived at the hospital. Two weeks after the injury, he was transferred to the rehabilitation department of another university hospital. He presented with severe aphasia and brain MRI showed leukomalactic lesion in the left frontal lobe (Fig. 1B).

Language function was evaluated with the Western Aphasia Battery (WAB).^[15] The result showed severe aphasia, with an aphasia quotient of 45.3 percentile (spontaneous speech: 35.0 percentile, auditory comprehension: 83.9 percentile, repetition: 24.5 percentile, and naming: 67.2 percentile). After 1 month of rehabilitation, including speech therapy at the university hospital, he was discharged to his home, and received similar rehabilitative management at the outpatient clinic until 4 months after the crash. His aphasia improved to the 100.0 percentile on the WAB at 9 months (spontaneous speech: 100.0 percentile, auditory comprehension: 100.0 percentile, repetition: 100.0 percentile, and naming: 100.0 percentile). The patient provided signed, informed consent, and our institutional review board approved the study protocol.

2.1. Diffusion tensor imaging

DTIs were obtained twice (2 weeks and 9 months after the initial injury). DTI was performed using a sensitivity-encoding head coil on a 1.5-T Philips Gyroscan Intera (Hoffman-LaRoche Ltd, Best, The Netherlands) with single-shot echo-planar imaging and navigator echo. Sixty contiguous slices (acquisition matrix=96 × 96; reconstruction matrix=192 × 192; field of view=240 ×

240 mm²; TR=10,726 ms; TE=76 ms, b=1000 s/mm², NEX=1, and thickness=2.5 mm) were acquired for each of the 32 noncollinear diffusion-sensitizing gradients. Fiber tracking was performed using the fiber assignment continuous tracking (FACT) algorithm implemented within the DTI task card software (Philips Extended Magnetic Resonance Work Space 2.6.3). Each of the DTI replications was intra-registered to the baseline "b0" images to correct for residual eddy-current image distortions and head motion effect, using a diffusion registration package (Philips Medical Systems). The AF was reconstructed using fibers passing through 2 regions of interest (ROIs) on the color map. We placed the region of interest (ROI) for tracking of the AF (the seed ROI in the posterior parietal area of the superior longitudinal fascicle and the target ROI in the posterior temporal lobe). The seed ROI was shown in green and the target ROI was blue on DTI-based color-coded maps. Termination criteria used for fiber tracking was fractional anisotropy (FA) < 0.15 and angle < 60°.^[16]

On the 2-week DTT, the branch to Broca's area of the left AF was discontinued at the subcortical white matter. By contrast, the DTT at 9 months depicted the discontinued portion of the left AF elongated to the left Broca's area (Fig. 1B).

3. Discussion

Using follow up DTT, we demonstrated the recovery of injured AFs in the dominant hemisphere over 8.5 months in a patient with TBI. It appears that the injury of Broca's portion of the left AF was caused by contusional hemorrhage.^[7,17–20] The patient showed improvement of severe aphasia from 45.3‰ (2 weeks) to 100.0‰ (9 months) as an aphasia quotient on the WAB. Along

with the AF, neural tracts involved in language function are the superior longitudinal fasciculus, inferior longitudinal fasciculus, inferior fronto-occipital fasciculus, and uncinata fasciculus.^[7,17-20] These neural tracts for language are classified into 2 categories: the dorsal stream for phonation and the ventral stream for comprehension. The AF is regarded as the major fiber tract of the dorsal stream.^[19,20] Although many neural tracts are involved in language function, we believe that the improvement of aphasia in this patient was at least partly attributable to the recovery of injured Broca's portion of the left AF.^[7,17-20]

Several mechanisms for recovery from aphasia in patients with brain injury have been suggested.^[14,21-24] These include the contribution of either the peri-lesional brain region in the affected hemisphere or homologous language regions in the unaffected hemisphere, facilitation of the AF in the nondominant hemisphere, and recovery of an injured AF.^[14,21-24] A right-handed patient completely recovered from a discontinued left AF over 21 months, concurrent with marked clinical recovery from aphasia following intracerebral hemorrhage.^[14] However, no study on recovery of an injured AF in patients with TBI, like this study, has been reported.

In conclusion, recovery of injured Broca's portion of the AF in the dominant hemisphere with excellent improvement of aphasia was demonstrated in a patient with TBI. This study has important implications in brain rehabilitation, because the mechanism of recovery from aphasia following TBI has not been elucidated. Therefore, conduct of further studies for the pathogenetic mechanisms and recovery mechanism of language deficit involving a large number of patients with TBI should be encouraged. In addition, the limitation of DTI, that it may underestimate the fiber tracts because regions of fiber complexity and crossing can prevent full reflection of the underlying fiber architecture by DTI, should be considered.^[12]

References

- [1] Andelic N. The epidemiology of traumatic brain injury. *Lancet Neurol* 2013;12:28–9.
- [2] Samo MT. The nature of verbal impairment after closed head injury. *J Nerv Ment Dis* 1980;168:685–92.
- [3] Rabinowitz AR, Levin HS. Cognitive sequelae of traumatic brain injury. *Psychiatr Clin North Am* 2014;37:11.
- [4] Levin HS, Grossman RG, Kelly PJ. Aphasic disorder in patients with closed head injury. *J Neurol Neurosurg Psychiatry* 1976;39:1062–70.
- [5] Sarno MT, Buonaguro A, Levita E. Characteristics of verbal impairment in closed head injured patients. *Arch Phys Med Rehabil* 1986;67:400–5.
- [6] Menon EB, Ravichandran S, Tan ES. Speech disorders in closed head injury patients. *Singapore Med J* 1993;34:45–8.
- [7] Geschwind N. The organization of language and the brain. *Science* 1970;170:940–4.
- [8] Anderson JM, Gilmore R, Roper S, et al. Conduction aphasia and the arcuate fasciculus: a reexamination of the Wernicke–Geschwind model. *Brain Lang* 1999;70:1–2.
- [9] Bernal B, Ardila A. The role of the arcuate fasciculus in conduction aphasia. *Brain* 2009;132:2309–16.
- [10] Kim SH, Jang SH. Prediction of aphasia outcome using diffusion tensor tractography for arcuate fasciculus in stroke. *AJNR Am J Neuroradiol* 2013;34:785–90.
- [11] Nucifora PG, Verma R, Melhem ER, et al. Leftward asymmetry in relative fiber density of the arcuate fasciculus. *Neuroreport* 2005;16:791–4.
- [12] Yamada K, Nagakane Y, Mizuno T, et al. MR tractography depicting damage to the arcuate fasciculus in a patient with conduction aphasia. *Neurology* 2007;68:1789–1799.
- [13] Hosomi A, Nagakane Y, Yamada K, et al. Assessment of arcuate fasciculus with diffusion-tensor tractography may predict the prognosis of aphasia in patients with left middle cerebral artery infarcts. *Neuroradiology* 2009;51:549–55.
- [14] Jang SH, Lee HD. Recovery of injured arcuate fasciculus in the dominant hemisphere in a patient with an intracerebral hemorrhage. *Am J Phys Med Rehabil* 2014;93:E15–8.
- [15] Kim H, Na DL. Normative data on the Korean version of the Western Aphasia Battery. *J Clin Exp Neuropsychol* 2004;26:1011–20.
- [16] Lee AY, Shin DG, Park JS, et al. Neural tracts injuries in patients with hypoxic ischemic brain injury: diffusion tensor imaging study. *Neurosci Lett* 2012;528:16–21.
- [17] Catani M, Jones DK, Ffytche DH. Perisylvian language networks of the human brain. *Ann Neurol* 2005;57:8–16.
- [18] Saur D, Kreher BW, Schnell S, et al. Ventral and dorsal pathways for language. *Proc Natl Acad Sci U S A* 2008;105:18035–40.
- [19] Axer H, Klingner CM, Prescher A. Fiber anatomy of dorsal and ventral language streams. *Brain Lang* 2013;127:192–204.
- [20] Jang SH. Diffusion tensor imaging studies on arcuate fasciculus in stroke patients: a review. *Front Hum Neurosci* 2013;7.
- [21] Thulborn KR, Carpenter PA, Just MA. Plasticity of language-related brain function during recovery from stroke. *Stroke* 1999;30:749–54.
- [22] Saur D, Lange R, Baumgaertner A, et al. Dynamics of language reorganization after stroke. *Brain* 2006;129:1371–84.
- [23] Raboyeau G, De Boissezon X, Marie N, et al. Right hemisphere activation in recovery from aphasia—lesion effect or function recruitment? *Neurology* 2008;70:290–8.
- [24] Schlaug G, Marchina S, Norton A. Evidence for plasticity in white-matter tracts of patients with chronic Broca's aphasia undergoing intense intonation-based speech therapy. *Ann N Y Acad Sci* 2009;1169:385–94.