

*Letter to the Editor**Amnesia due to the Injury of Papez Circuit Following Isolated Fornix Column Infarction***Dear Editor,**

Fornix column infarction is a rare type of cerebral infarction. The presumed anatomic etiology is the occlusion of the perforating branches of the anterior communicating artery (AcoA) complex, and the clinical manifestation is characterized by cognitive changes and disturbances of memory, including Korsakoff syndrome, transient global amnesia (TGA), and long-term amnesic syndrome.<sup>1</sup> In many cases, fornix lesions are associated with infarction in other regions such as the cingulate cortex and corpus callosum.<sup>1,2</sup> However, our case demonstrated pure fornix columns infarction and the focus of our research is the isolated lesion linked to the Papez circuit.

A 51-year-old right-handed woman with a 3-year history of type 2 diabetes mellitus, who developed sudden anterograde and retrograde amnesia, was finally diagnosed with acute fornix column infarction and was treated with antiplatelet therapy and high dose of statin. Six hours before her admission, the patient was shopping with her family members and her son noticed that she repeatedly paid the cashier. On admission, the neurological examination was normal except for tests of memory functions, which revealed a symptom of both anterograde and retrograde amnesia. This was manifested in her repetition of the same questions, her inability to recall incidents of the immediate past, and her confusion over plans made the day before. She scored 25 of 30 on the Montreal Objective Cognitive Assessment (MOCA), with deficits in recall (0 of 5). Cranial computed tomography performed 3 hours after onset showed lacunar infarction in bilateral basal ganglia. She was admitted with differential diagnoses including TGA, acute ischemic stroke, seizure (transient epileptic amnesia), Wernicke encephalopathy, Herpes encephalitis, Alzheimer disease, and Creutzfeldt-Jakob disease. Searches for alternative etiology of her acute onset of confusion and amnesia, including infectious and metabolic workup, were both negative. The 24-hour electroencephalogram monitoring revealed no epileptiform activity. Magnetic resonance imaging of the brain performed 48 hours after admission was reported unremarkable. However, on closer review, it demonstrated bilateral isolated hyper signal intensity lesions in

fornix columns on T2-weighted image and diffusion-weighted imaging with low value on apparent diffusion coefficient map (Fig 1), which was consistent with acute infarction. The patient was seen to have a slight improvement in remembering things in the follow-up 3 months. Her MOCA score was 28 of 30, with deficits in recall (3 of 5).

The fornix columns are supplied by the subcallosal artery (ScA) from the AcoA. Usually, the unilateral ScA supplies the bilateral subcallosal regions including fornix columns, genu of the corpus callosum, and anterior septum pellucidum.<sup>1</sup> As a result, bilateral fornix infarctions are more common than unilateral. In a previous report, the author concluded that the fornix body was irrigated by the medial posterior choroidal artery.<sup>3</sup>

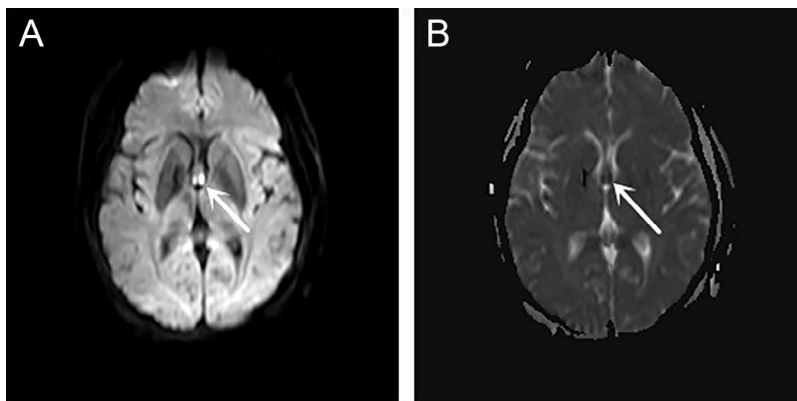
In Dan Meila's study, the presumed pathophysiology was microangiopathy, which followed by iatrogenic vascular injury after treatment of AcoA aneurysms.<sup>1</sup> In our case, the patient had no hypertension, cardiogenic disease, or other risk factors except the history of type 2 diabetes mellitus. We conclude that small-vessel disease is responsible for the occlusion of perforating branches from the ScA and the bilateral isolated fornix infarction in our patient, which is in accordance with previous literatures.

Amnesia syndrome was characterized by impairment in episodic memory with the preserved immediate recall, semantic, and procedural memory. In 1937, Papez, an American neuroanatomist, hypothesized a circuit that described a neural pathway in the brain which thought to be involved in the control of emotion expression and is responsible for the memory. Anatomically, the Papez circuit starts and ends in the hippocampus traveling by way of fornix, mammillary body, mammillothalamic tracts, anterior thalamic nucleus, and cingulate gyrus.<sup>4</sup> The fornix serves as the major efferent pathway connecting the hippocampus with the mammillary body and is thought to play a critical role in the efficient encoding and normal recall of new episodic information.<sup>5</sup> However, lesions of Papez circuit, which followed with the amnesia syndrome, are not limited to fornix and have been reported in other memory-related brain regions, including the anterior thalamic nucleus, mammillary body, cingulate gyrus, and hippocampus (Table 1). In addition, more rare regions associated with memory have been reported, such as the basal forebrain and genu of the internal capsule, which demonstrated the complex of the associative memory of the neural network. Our literature review revealed 5 other typical cases of memory

---

1052-3057/\$ - see front matter

© 2017 National Stroke Association. Published by Elsevier Inc. All rights reserved.



**Figure 1.** Diffusion-weighted imaging showed high signal intensity in bilateral fornix columns, particularly in the right (A, arrows), and corresponding hypointensity on apparent diffusion coefficient map (B, arrows).

**Table 1.** Summary of patients with memory deficits with the isolated infarction occurring in the Papez circuit

Age/Sex	Lesion	Location (loop)	Symptoms	Blood supply	Study
56/F	Infarction (left)	ATN (MMT)	Acute global amnesia	Paramedian or polar artery territory	Clarke et al, 1994 <sup>6</sup>
53/M	Infarction (left)	MB	Anterograde and retrograde amnesia	Perforators originating from proximal PCA (P1 segment) or posterior communicating artery	Male and Zand, 2017 <sup>7</sup>
50/M	Infarction (left)	MB	Anterograde amnesia	Perforating branches of the P1 segment of the PCA	Amuluru et al, 2015 <sup>8</sup>
62/M	Infarction (right)	Cingulate Gyrus	TGA	Not described	Gallardo-Tur et al, 2014 <sup>9</sup>
41/?	Infarction (left)	Dorsolateral hippocampal body	TGA plus syndrome	Most distal PCA branches (middle or posterior hippocampal artery)	Carota et al, 2012 <sup>10</sup>
51/F	Infarction (bilateral)	Fornix columns	Anterograde and retrograde amnesia	Perforating branches of the anterior communicating artery complex	Present case

Abbreviations: ATN, anterior thalamic nuclei; MB, mammillary body; MMT, mammillothalamic tract; TGA, transient global amnesia.

deficits caused by the isolated lesion of Papez circuit as confirmed by magnetic resonance imaging (Table 1).<sup>6-10</sup>

The isolated unilateral fornix infarction was reported to be associated with TGA in Mihir Gupta's study.<sup>11</sup> In contrast, the case from Kojiro Korematsu's report presented persisted amnesia with poor improvement.<sup>12</sup> Furthermore, in the previous reports, fornix infarctions demonstrated different prognosis and recovery in memory deficits. The extent to what integrity of the fornix is essential for memory is still unclear now. Yeo and Jang described a patient who showed recovery of injured fornix after stroke. The diffusion tensor tractography demonstrated an unusual neural connection between the injured fornix and the thalamus, which allowed the injured fornix and the medial temporal lobe to obtain cholinergic innervation from cholinergic nuclei in the brainstem rather than from cholinergic nuclei in the basal forebrain.<sup>13</sup> So the differences in prognosis may be relevant to plasticity of structure and function in memory circuit. In addition, the size and location of the lesion, type of memory tested,

and whether the lesion is unilateral or bilateral may cause the variability.

In summary, amnesia syndrome can occur in lesions of fornix columns or other regions restricted to Papez circuit. Although rare, small and strategic infarction of the fornix should be considered when we encounter patients with acute pure memory deficits.

**Acknowledgment:** The authors thank the patient and her family for the cooperation in this study.

Jianping Wang, PhD  
Junji Ke, MS  
Chenguang Zhou, MS  
Chunmao Yin, MS

Department of Neurology, The Fifth Affiliated Hospital of Zhengzhou University, Zhengzhou, Henan 450052, China  
E-mail: [wjpwfy666@126.com](mailto:wjpwfy666@126.com)

<https://doi.org/10.1016/j.jstrokecerebrovasdis.2017.12.040>

**References**

1. Meila D, Saliou G, Krings T. Subcallosal artery stroke: infarction of the fornix and the genu of the corpus callosum. The importance of the anterior communicating artery complex. Case series and review of the literature. *Neuroradiology* 2015;57:41-47.
2. Moudgil SS, Azzouz M, Al-Azzaz A, et al. Amnesia due to fornix infarction. *Stroke* 2000;31:1418-1419.
3. Mugikura S, Takahashi S. Fornix infarction due to involvement of posterior circulation. *J Stroke Cerebrovasc Dis* 2015;24:2883-2885.
4. Papez JW. A proposed mechanism of emotion. *Arch Neurol Psychiatry* 1937;38:725-733.
5. Aggleton JP, Brown MW. Episodic memory, amnesia, and the hippocampal-anterior thalamic axis. *Behav Brain Sci* 1999;22:425-444.
6. Clarke S, Assal G, Bogousslavsky J, et al. Pure amnesia after unilateral left polar thalamic infarct: topographic and sequential neuropsychological and metabolic (PET) correlations. *J Neurol Neurosurg Psychiatry* 1994;57:27-34.
7. Male S, Zand R. Isolated mammillary body infarct causing global amnesia: a case report. *J Stroke Cerebrovasc Dis* 2017;26:e50-e52.
8. Amuluru K, Filippi CG, Lignelli A. Acute amnesia due to isolated mammillary body infarct. *J Stroke Cerebrovasc Dis* 2015;24:e303-e305.
9. Gallardo-Tur A, Romero-Godoy J, de la Cruz Cosme C, et al. Transient global amnesia associated with an acute infarction at the cingulate gyrus. *Case Rep Neurol Med* 2014;2014:418180.
10. Carota A, Lysandropoulos AP, Calabrese P. Pure left hippocampal stroke: a transient global amnesia-plus syndrome. *J Neurol* 2012;259:989-992.
11. Korematsua K, Hori T, Morioka M, et al. Memory impairment due to a small unilateral infarction of the fornix. *Clin Neurol Neurosurg* 2010;112:164-166.
12. Gupta M, Kantor MA, Tung CE, et al. Transient global amnesia associated with a unilateral infarction of the fornix: case report and review of the literature. *Front Neurol* 2015;5:291.
13. Yeo SS, Jang SH. Recovery of an injured fornix in a stroke patient. *J Rehabil Med* 2013;45:1078-1080.