



Contents lists available at ScienceDirect

Journal of Clinical Neuroscience

journal homepage: [www.elsevier.com/locate/jocn](http://www.elsevier.com/locate/jocn)

## Case study

## Successful deep brain stimulation for central post-stroke pain and dystonia in a single operation

Marshall T. Holland<sup>a</sup>, Mario Zanaty<sup>a</sup>, Luyuan Li<sup>a</sup>, Teri Thomsen<sup>b</sup>, James H. Beeghly<sup>c</sup>, Jeremy D.W. Greenlee<sup>a,\*</sup>, Chandan G. Reddy<sup>a</sup><sup>a</sup> Department of Neurosurgery, University of Iowa Carver College of Medicine, Iowa City, IA, United States<sup>b</sup> Department of Neurology, University of Iowa Carver College of Medicine, Iowa City, IA, United States<sup>c</sup> Department of Psychiatry, University of Iowa Carver College of Medicine, Iowa City, IA, United States

## ARTICLE INFO

## Article history:

Received 12 July 2017

Accepted 8 January 2018

Available online xxxxx

## Keywords:

Neuromodulation

Ventral capsule/ventral striatum

Programming

Globus pallidus

## ABSTRACT

**Background:** Central post-stroke pain is known to be refractory to medications and difficult to manage. We present a case of central post-stroke pain associated with dystonia. Both conditions were successfully treated with a single deep brain stimulation (DBS) operation.

**Case Description:** A 60-year-old female suffered a right posterior cerebral artery stroke following emergent clipping of a ruptured posterior cerebral artery aneurysm resulting in central post-stroke pain. This manifested as delayed left face and hemibody allodynia and hyperesthesia. The patient also developed marked left-sided dystonia. These progressive symptoms were disabling and refractory to conservative management. The patient underwent a single-stage DBS surgery with stereotactic targeting and implantation of two leads. One lead was placed in the right-sided ventral capsule/ventral striatum for treatment of pain and a second lead in the right-sided globus pallidus interna for treatment of dystonia.

The surgical implantation proceeded without complication. The patient's dystonia markedly improved following surgery. While her pain improved, she required multiple, meticulous programming sessions to achieve significant pain relief and decrease in pain medication use. Overall, the patient was satisfied with the results of her intervention. She did, however, have occasional intermittent spells of severe pain on top of her residual discomfort throughout her treatment course. Unfortunately, she died from small cell lung carcinoma a year after her DBS surgery.

**Conclusions:** Deep brain stimulation targeting multiple brain networks in one operation is feasible and safe. Deep brain stimulation may be considered in some refractory cases of central post-stroke pain; however, it requires meticulous programming.

© 2018 Published by Elsevier Ltd.

## 1. Introduction

Pain of central origin is notorious for being refractory to medical treatment, as documented in several studies [1–3]. Central post-stroke pain (CPSP) is characterized by allodynia or hyperesthesia that is chronic with associated continuous numbness typically involving one side of the face and hemibody. The pain is unrelenting, refractory, and extraordinarily frustrating for patients and

treating physicians. It occurs in approximately 8% of all stroke patients but may be as high as 18% in those with sensory deficits [4]. While a prior case abstract reported improvement of tremor following DBS of the periventricular grey matter (PVG) and ventro-posterolateral thalamic nucleus (VPL), to our knowledge we present here the first report of a post-stroke patient with CPSP and co-morbid dystonia treated with a single deep brain stimulation procedure with one lead implanted in the globus pallidus interna (GPi) for dystonia and one lead placed in the ventral capsule/ventral striatum (VC/VS) for pain [5].

## 2. Case description

A 60-year-old female first presented to the neurosurgical service with acute subarachnoid hemorrhage due to a ruptured right posterior cerebral artery aneurysm. She underwent emergent

*Abbreviations:* AC-PC, anterior commissure-posterior commissure; DBS, deep brain stimulation; GPi, globus pallidus interna; Hz, Hertz; IPG, impulse generator; MCP, mid-commissural point; PCA, posterior cerebral artery; PVG, periventricular gray region; CPSP, central post-stroke pain; V, volts; VC/VS, ventral internal capsule/ventral striatum; VS, ventral striatum;  $\mu$ s, microseconds.

\* Corresponding author at: Department of Neurosurgery University of Iowa Hospitals and Clinics, 200 Hawkins Drive, Iowa City, IA 52242, United States.

E-mail address: [jeremy-greenlee@uiowa.edu](mailto:jeremy-greenlee@uiowa.edu) (J.D.W. Greenlee).

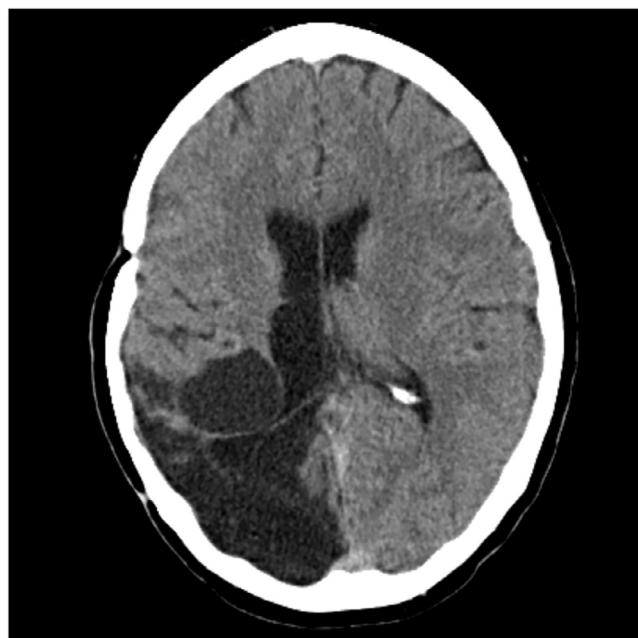<https://doi.org/10.1016/j.jocn.2018.01.036>

0967-5868/© 2018 Published by Elsevier Ltd.

microsurgical clipping of the aneurysm. This procedure was complicated by a right posterior cerebral artery stroke that involved her thalamus. (Fig. 1) Postoperatively, she had residual deficits including a dense left homonymous hemianopsia, hemiparesis, and numbness of the face and hemibody. Seven years after the initial stroke, she began to develop left-sided pain, allodynia, and hyperesthesia involving her face and hemibody that were previously numb. With the development of the pain came associated dystonia. Her pain was progressive and refractory to medical management. She required multiple classes of pain medication, including amitriptyline (which helped with the pain but led to hypertension), baclofen, gabapentin, carbamazepine, oxcarbazepine, duloxetine, pregabalin, and propoxyphene. She was significantly affected by her pain. This hampered her post-stroke recovery and rehabilitation, resulting in a depressed mood with social isolation. She experienced intermittent insomnia, decreased ability to concentrate, and mild anhedonia. Despite these experiences she did not meet the diagnostic criteria for depression, anxiety, or post-traumatic stress disorder that would require formal psychiatric treatment. Ultimately, she was diagnosed with psychological factors affecting a physical illness. After her case was discussed at a multidisciplinary conference including neurosurgery, psychiatry, and pain colleagues, IRB approval was obtained for placement of a deep brain stimulation (DBS) lead in the VC/VS for her pain. The patient decided to proceed with DBS to address both her dystonia and pain syndrome.

### 2.1. Surgical technique

The patient underwent right-sided DBS lead (model 3391, Medtronic, Minneapolis, MN) implantation in the VC/VS for pain and right-sided GPi lead (model 3387, Medtronic, Minneapolis, MN) implantation for dystonia. The GPi target was chosen based on the extensive literature showing improvements of focal and generalized dystonia with GPi DBS [6]. VC/VS was selected based on reports of improved pain [7] and depression [8]. Our center has considerable experience with GPi targeting for the treatments of

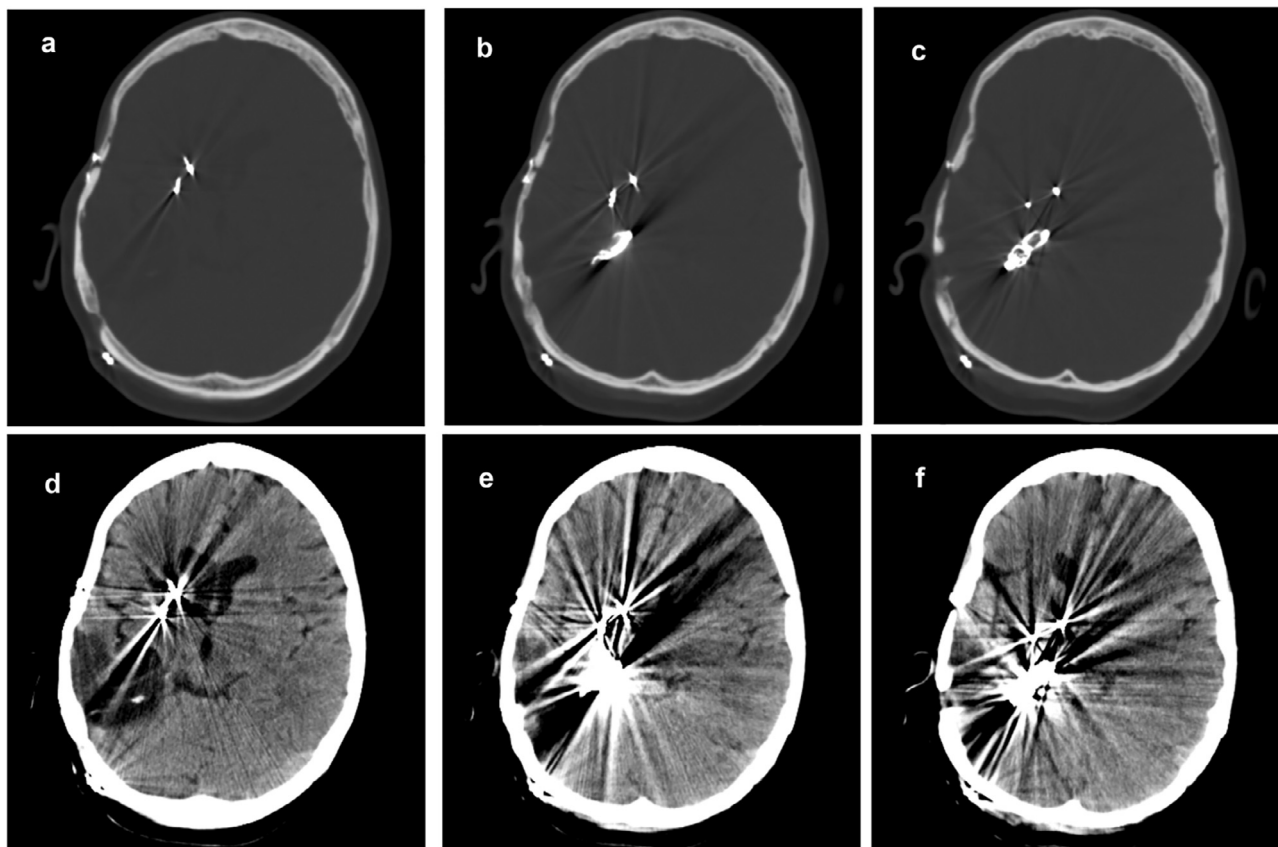


**Fig. 1.** Right Posterior Cerebral Artery Stroke Axial head CT without contrast obtained 6 years after neurosurgical clipping of right posterior cerebral artery (PCA) showing diffuse hypodensity and encephalomalacia in the right PCA vascular territory.

Parkinson's disease and dystonia and VC/VS targeting for refractory obsessive-compulsive disorder under IRB approvals. Prior to surgery, a high-resolution volumetric brain MRI was obtained (1-mm slices). The morning of surgery, the patient was brought into the operating room, placed under general anesthesia, placed in a stereotactic ring (CRW, Integra, Plainsboro, NJ) and a volumetric CT scan was obtained. The two scans were merged for targeting and trajectory planning on a workstation (Stealth, Medtronic, Minneapolis, MN). Direct targeting was used to obtain coordinates for the VC/VS on the right side and were deduced as 9 mm lateral, 11 mm anterior, and 4 mm deep to mid-commissural point (MCP) of the anterior commissure-posterior commissure (AC-PC) line. A trajectory was chosen so that the electrode traveled down the anterior limb of the internal capsule. Indirect targeting was used to obtain starting coordinates for the right GPi nucleus and were 21 mm lateral, 2 mm anterior, and 4 mm deep to MCP. Planned incisional markings were placed at 3.5 cm and 5.3 cm lateral to the midline and along the coronal suture for the GPi and VC/VS burr holes respectively. Both trajectories were planned to avoid prominent sulci, ventricles, and the head of the caudate. Intraoperative physiology was used to determine ultimate lead positioning for each target. For VC/VS, macrostimulation was performed. At target depth, a transient increase of heart rate of 10 beats per minute was noted with stimulation of the deepest contact (i.e. contact 0) and no adverse effects were evident with stimulation up to 5 V. For GPi target refinement, microelectrode recordings were obtained under propofol and remifentanyl anesthesia and defined the superior and inferior borders of GPi. No photic response was noted. The DBS lead was placed with contact 0 at the inferior border of GPi. Macrostimulation was performed and revealed a transient release of dystonia in the left hand without evident side effects up to 5 V. Following implantation of both leads, the stereotactic frame was removed, the patient repositioned, and an impulse generator (Activa PC, Medtronic, Minneapolis, MN) was placed in the right chest and connected to the electrodes with extension wires. The operation proceeded without complication and the patient was able to be discharged home on postoperative day 2. Postoperative imaging is shown in Fig. 2.

### 2.2. Post-surgical course

Immediately after surgery there was a micro-lesional effect noted with some improvement of the patient's dystonia prior to stimulator activation. The following day, the patient underwent initial programming by a fellowship-trained movement disorder neurologist highly experienced in DBS. The dystonia responded well to GPi DBS with improvements in her ability to walk with the use of a left leg straightener and decreased left sided toe curling. The patient reported decreased tightness on her left side. On the other hand, her pain was significantly more difficult to control with VC/VS DBS. Eventually, after multiple meticulous programming sessions the patient did find relief and was able to reduce her pain medication requirements. Her pain visual analogue scores improved from 8 out of 10 pre-operatively to 5 out of 10 six months post-operatively. Her final stimulation settings are summarized in Tables 1 and 2. Despite the overall improvement in her pain, she continued to have intermittent bouts of severe pain and some residual discomfort. The patient also reported significant improvement in her mood and she was also able to successfully reintegrate into society. During a postoperative visit with her psychiatrist, the patient denied having any depressive symptoms or alterations in mood. Objectively, her Inventory of Depressive Symptomatology score decreased from 13 preoperatively to 2 two months postoperatively. Her affect pain score from the McGill Pain Questionnaire-2 decreased from 34 preoperatively to 10 over the course of one year. She was overall satisfied with the results,



**Fig. 2.** Postoperative placement of deep brain stimulation leads. Serial axial head CT without contrast images (a) – (f) demonstrating the placement of two DBS leads at right globus pallidus interna and ventral capsule/ventral striatum respectively.

**Table 1**  
Stimulator settings by contact.

VC/VS	GPI
C+	C+
0	8-
1-	9
2	10
3	11

**Table 2**  
Stimulation parameters.

Electrode	Amplitude (V)	PW ( $\mu$ s)	Frequency (Hz)
VC/VS	1.9 (1.5–2.1) <sup>*</sup>	300	180
GPI	1.5	300	180

<sup>\*</sup> The patient had the ability to adjust voltage up or down using her access device.

albeit frustrated with the intermittent bouts of pain. Her family concurred that her quality of life had significantly improved following the operation. Unfortunately, she developed metastatic small cell carcinoma of the lung that impaired further recovery. She succumbed to her cancer approximately a year after her DBS surgery.

### 3. Discussion

This case report shows that implanting both the VC/VS and GPI simultaneously is safe, feasible, and can be efficacious. Our patient suffered from severe and refractory pain after thalamic infarction

with a strong affective component to her symptomatology. She also had significant dystonia in the left hemibody which was felt to be contributing to her pain. Finally, her mood was being affected by her pain syndrome and decreasing her overall quality of life. As a result, our multi-disciplinary team felt it was reasonable to try a unique combination of DBS targets (GPI and VC/VS) to try to relieve some of her symptoms.

Multiple brain areas have been targets of stimulation for the treatment of pain. DBS has been used via leads placed in the septal area, posterior limb of the internal capsule, centromedian and parafascicular nuclei, ventralis caudalis of the thalamus, and periventricular gray region (PVG) [3,9]. Cortical stimulation of motor cortex has been utilized via subdural and epidural electrodes [10]. Repetitive transcranial magnetic stimulation is a non-invasive treatment option for central post-stroke pain where the precentral cortex of the hemisphere contralateral to the pain side is targeted [11].

Targeting the PVG or ventralis caudalis is relatively straightforward and safe; however the failure rate for the treatment of central poststroke pain utilizing these targets ranges from 33% to 82% [12,13]. Our approach to this patient was guided by the fact that she had severe allodynia associated with a major affective/depressive component. Given the potential of VC/VS as a target for the treatment of both refractory depression and central post-stroke pain [7,14], our multidisciplinary team felt that this target would be appropriate. Regrettably, it is not uncommon for patients with central post stroke pain to suffer from a learned behavior in which disability is exacerbated by pain anticipation. The nucleus accumbens, part of the VS that is involved in reward processing, has been found to be an effective DBS target for depression and obsessive-compulsive disorder [15,16]. DBS modulation of VC/VS may modify

learned affective behavioral responses, as in obsessive-compulsive disorder and depression, and may potentially be more effective in mitigating pain-related disability [8,17,18].

Dystonia is an abnormal movement disorder characterized by sustained muscular contraction, often resulting in painful postures. DBS targeting GPi has become the treatment of choice for medically refractory primary dystonia [6,19]. The effect of pallidal DBS on secondary dystonias tends to be more varied, likely due to the heterogeneous diseases in this population [20]. Secondary dystonia has been reported in about 1% of post-stroke patients [21]. Importantly, Slow et al. showed that deep brain stimulation of GPi to be an efficacious treatment for medically refractory dystonia secondary to stroke [22].

DBS therapy is often thought of as a modulation of a network rather than an anatomical target. This concept may explain why different anatomical centers can be utilized to treat the same disease (i.e., GPi versus subthalamic nucleus for Parkinson's disease). Future DBS may be based on probabilistic targeting using tractography for mapping [23]. Here, we modulate two presumably distinct brain circuits simultaneously in order to treat different aspects of a severe pain syndrome. Providers may often find it difficult to objectively separate and quantify both the physical and the emotional aspects of pain as patients often experience them as one. By involving experts familiar with both the diseases and DBS, we were able to provide this patient meaningful pain relief.

#### 4. Conclusion

This unique case illustrates that DBS can be a safe and effective treatment option for medically refractory central post-stroke pain.

#### References

- [1] Kumar K, Toth C, Nath RK. Deep brain stimulation for intractable pain: a 15-year experience. *Neurosurgery* 1997;40:736–46. discussion 46–7.
- [2] Levy RM, Lamb S, Adams JE. Treatment of chronic pain by deep brain stimulation: long term follow-up and review of the literature. *Neurosurgery* 1987;21:885–93.
- [3] Rasche D, Rinaldi PC, Young RF, Tronnier VM. Deep brain stimulation for the treatment of various chronic pain syndromes. *Neurosurg Focus* 2006;21:E8.
- [4] Klit H, Finnerup NB, Jensen TS. Central post-stroke pain: clinical characteristics, pathophysiology, and management. *Lancet Neurol* 2009;8:857–68.
- [5] Papuc E, Obszanska K, Trojanowski T, Szczepanska-Szerej H, Rejdak K, Stelmasiak Z. Reduction of thalamic tremor with deep brain stimulation performed for post stroke chronic central pain. *Ann Agric Environ Med* 2013 (Spec no. 1):45–7.
- [6] Coubes P, Cif L, El Fertit H, Hemm S, Vayssiere N, Serrat S, et al. Electrical stimulation of the globus pallidus internus in patients with primary generalized dystonia: long-term results. *J Neurosurg* 2004;101:189–94.
- [7] Plow EB, Malone Jr DA, Machado A. Deep brain stimulation of the ventral striatum/anterior limb of the internal capsule in thalamic pain syndrome: study protocol for a pilot randomized controlled trial. *Trials* 2013;14:241.
- [8] Malone Jr DA, Dougherty DD, Rezai AR, Carpenter LL, Friehs GM, Eskandar EN, et al. Deep brain stimulation of the ventral capsule/ventral striatum for treatment-resistant depression. *Biol Psychiatry* 2009;65:267–75.
- [9] Young RF, Kroening R, Fulton W, Feldman RA, Chambi I. Electrical stimulation of the brain in treatment of chronic pain. Experience over 5 years. *J Neurosurg* 1985;62:389–96.
- [10] Sokal P, Harat M, Zielinski P, Furtak J, Paczkowski D, Rusinek M. Motor cortex stimulation in patients with chronic central pain. *Adv Clin Exp Med* 2015;62:289–96.
- [11] Lefaucheur JP, Andre-Obadia N, Antal A, Ayache SS, Baeken C, Benninger DH, et al. Evidence-based guidelines on the therapeutic use of repetitive transcranial magnetic stimulation (rTMS). *Clin Neurophysiol* 2014;125:2150–206.
- [12] Owen SL, Green AL, Nandi DD, Bittar RG, Wang S, Aziz TZ. Deep brain stimulation for neuropathic pain. *Acta Neurochir Suppl* 2007;97:111–6.
- [13] Owen SL, Green AL, Stein JF, Aziz TZ. Deep brain stimulation for the alleviation of post-stroke neuropathic pain. *Pain* 2006;120:202–6.
- [14] Mallory GW, Abulseoud O, Hwang SC, Gorman DA, Stead SM, Klassen BT, et al. The nucleus accumbens as a potential target for central poststroke pain. *Mayo Clin Proc* 2012;87:1025–31.
- [15] Franzini A, Messina G, Gambini O, Muffatti R, Scarone S, Cordella R, et al. Deep-brain stimulation of the nucleus accumbens in obsessive compulsive disorder: clinical, surgical and electrophysiological considerations in two consecutive patients. *Neurol Sci* 2010;31:353–9.
- [16] Hauptman JS, DeSalles AA, Espinoza R, Sedrak M, Ishida W. Potential surgical targets for deep brain stimulation in treatment-resistant depression. *Neurosurg Focus* 2008;25:E3.
- [17] Greenberg BD, Gabriels LA, Malone Jr DA, Rezai AR, Friehs GM, Okun MS, et al. Deep brain stimulation of the ventral internal capsule/ventral striatum for obsessive-compulsive disorder: worldwide experience. *Mol Psychiatry* 2010;15:64–79.
- [18] Machado A, Haber S, Sears N, Greenberg B, Malone D, Rezai A. Functional topography of the ventral striatum and anterior limb of the internal capsule determined by electrical stimulation of awake patients. *Clin Neurophysiol* 2009;120:1941–8.
- [19] Kupsch A, Benecke R, Muller J, Trottenberg T, Schneider GH, Poewe W, et al. Pallidal deep-brain stimulation in primary generalized or segmental dystonia. *N Engl J Med* 2006;355:1978–90.
- [20] Eltahawy HA, Saint-Cyr J, Giladi N, Lang AE, Lozano AM. Primary dystonia is more responsive than secondary dystonia to pallidal interventions: outcome after pallidotomy or pallidal deep brain stimulation. *Neurosurgery* 2004;54:613–9. discussion 9–21.
- [21] Alarcon F, Zijlmans JC, Duenas G, Cevallos N. Post-stroke movement disorders: report of 56 patients. *J Neurol Neurosurg Psychiatry* 2004;75:1568–74.
- [22] Slow EJ, Hamani C, Lozano AM, Poon YY, Moro E. Deep brain stimulation for treatment of dystonia secondary to stroke or trauma. *J Neurol Neurosurg Psychiatry* 2015;86:1046–8.
- [23] Pouratian N, Zheng Z, Bari AA, Behnke E, Elias WJ, Desalles AA. Multi-institutional evaluation of deep brain stimulation targeting using probabilistic connectivity-based thalamic segmentation. *J Neurosurg* 2011;115:995–1004.