

# Diaphragmatic flutter

Dean Walton, Michael Bonello, Malcolm Steiger

Department of Neurology, The Walton Centre NHS Foundation Trust, Liverpool, UK

## Correspondence to

Dr Michael Bonello, Department of Neurology, The Walton Centre NHS Foundation Trust, Liverpool L9 7LJ, UK; [michael.bonello@thewaltoncentre.nhs.uk](mailto:michael.bonello@thewaltoncentre.nhs.uk)

Accepted 4 January 2018

## ABSTRACT

A 78-year-old woman presented with involuntary movements of her abdomen, which started after a right hemispheric stroke. She had irregular, variable, hyperkinetic predominantly right-sided abdominal wall movements. MR scan of brain confirmed a recent infarct in the right occipitotemporal lobe and the right cerebellum. Diaphragmatic fluoroscopy confirmed high-frequency flutter as the cause of her abdominal movements and confirmed the diagnosis of van Leeuwenhoek's disease. Anthonie van Leeuwenhoek first described this condition in 1723 and had the condition himself. He was a Dutch businessman who is often acknowledged as the first microscopist and microbiologist. He disagreed with his physician who attributed his ailment as being of cardiac origin. Diaphragmatic flutter is a rare disorder that requires a high index of suspicion with symptoms including abnormal abdominal wall movements, dyspnoea and respiratory distress. Despite medical treatment, the patient was still highly symptomatic, so she is currently being considered for a phrenic nerve crush.

## CASE PRESENTATION

### History

A 78-year-old woman presented with involuntary movements of her abdomen. This had begun 1 year earlier after an admission with a sudden loss of her left-sided visual field from a right hemispheric ischaemic stroke. The abdominal movements were paroxysmal, made worse by stress and relieved on falling asleep. They did not affect her chewing or swallowing, nor impact her bowel function. They were accompanied by slight lip puckering and smacking, and lateral head movements.

She had a history of rheumatic fever with valve sequelae, type 2 diabetes mellitus and polymyalgia rheumatica, and several previous abdominal surgeries for ovarian, bowel and bladder pathologies. Her medications included apixaban, metformin, bisoprolol, prednisolone, furosemide, mebeverine, pravastatin and alendronic acid. She had never taken neuroleptic or dopaminergic medications.

She was an ex-smoker of 20 years and occasionally drank alcohol.

On examination, she had occasional lip movements and a 'no-no' head turn. The abdominal movements were irregular, variable, hyperkinetic and predominantly right sided ([video 1](#)). Limb examination was normal with normal tone and power and no tremor or bradykinesia. Abdominal examination was otherwise normal.

Routine haematological and biochemical tests and routine 12-lead ECG were normal.

An MR brain scan 2 years before symptom onset had showed a left parietal infarct. CT scan of head on admission with her left visual field loss confirmed her old infarct and showed a new established infarction of the right occipital lobe. An MR scan of brain 1 year after onset confirmed areas of established infarction within the left parietal lobe, right occipitotemporal lobe and the right cerebellum. There was deep white matter signal hyperintensity with pontine signal hyperintensity, which was probably ischaemic.

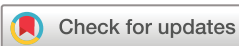Diaphragmatic fluoroscopy confirmed high-frequency flutter of the right haemidiaphragm with very minor high-frequency movement of the left, indicating diaphragmatic flutter.

The movements persisted despite treatment with baclofen, sodium valproate and carbamazepine. She is currently being considered for a phrenic nerve crush.

## DISCUSSION

Diaphragmatic flutter (diaphragmatic myoclonus) is a rare condition originally coined by Porter in 1936,<sup>1</sup> characterised by high-frequency, involuntary contractions of the diaphragmatic muscles. It is often accompanied by contractions of accessory respiratory muscles and is then known as respiratory myoclonus.<sup>2</sup>

The first description was from Anthonie van Leeuwenhoek ([Figure 1](#)), a draper who was renowned for his microscopy work. He himself presented in February 1723 with 'a violent movement around the large and vital organ we call the

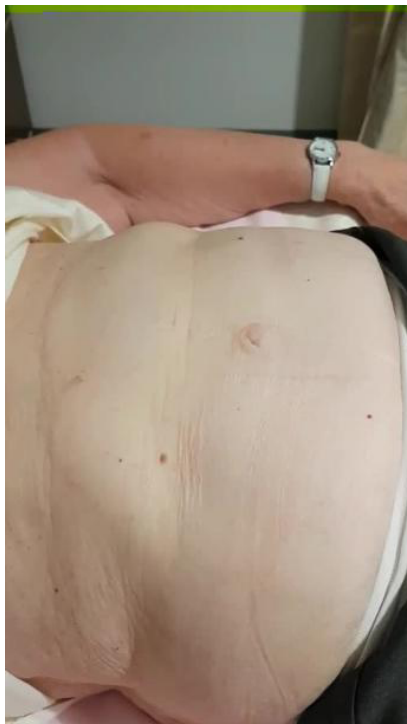

**To cite:** Walton D, Bonello M, Steiger M. *Pract Neurol* Epub ahead of print: [please include Day Month Year]. doi:10.1136/practneurol-2017-001830

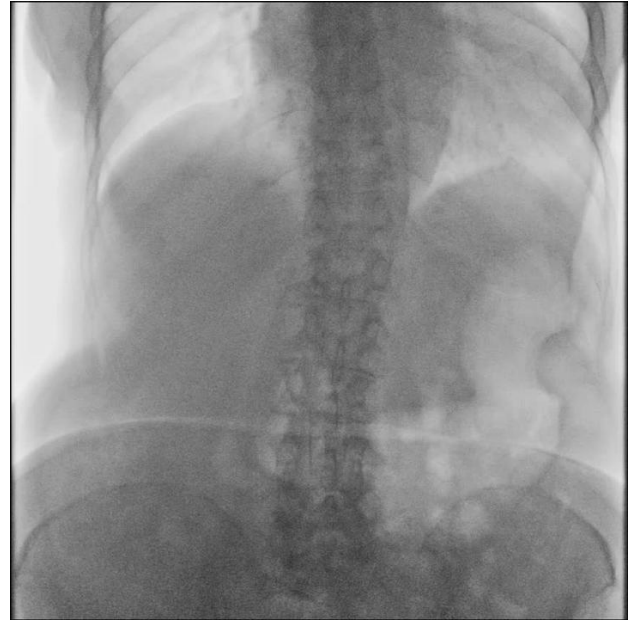


**Figure 1** Portrait of Antonie van Leeuwenhoek (1632–1723) sitting at a writing desk. At his side, one can see a record of his appointment as a member of the Royal Society of Physicians of London. Painter: Jan Verkolje (1680–1686). Exhibited at the Rijksmuseum Amsterdam.

diaphragm'. Van Leeuwenhoek's doctor attributed the symptoms to a palpitation of the heart. The empirically minded van Leeuwenhoek dismissed this view, as on feeling his pulse during an attack he 'did not feel any acceleration'. He self-medicated with port wine and nutmeg with limited effect and continued to suffer.<sup>1</sup> Even on his deathbed in August 1723, he



**Video 1** Video showing the variable, irregular and predominantly right-sided abdominal movements.



**Video 2** Videofluoroscopy of thoracic region showing high-frequency flutter of the right haemidiaphragm (and minor high-frequency flutter on the left).

still vehemently believed the symptoms were diaphragmatic rather than cardiac in origin.

Two brief paragraphs in a letter entitled *De globulorum sanguineorum magnitudine* (On the size of the particles of the blood) to the *Philosophical Transactions* describe his recent state of health:

Not long ago, after January finished, I was seized by a violent movement around that large and vital organ we call the diaphragm, so much indeed that those standing around were not a little alarmed. When the movement eased off, searching for a name for this illness, the doctor, who was there, answered it to be a palpitation of the heart. I think the doctor was in fact wrong. For although while the movement was happening I several times felt the arterial pulse with my hand, I did not feel any acceleration. Starting up again every now and then, the violent movement lasted about 3 days, during which time my stomach and intestine ceased to function. I thought I was at death's door. I am of the opinion an obstruction was stuck in my diaphragm, not smaller than an imperial penny.<sup>1</sup>

Time would vindicate van Leeuwenhoek as these descriptions are now considered the first of diaphragmatic flutter, earning the eponym Leeuwenhoek's syndrome or disease.<sup>1</sup>

Due to its rarity and heterogeneous presentation, the diagnosis of diaphragmatic flutter is often difficult and delayed. Most descriptions are as case reports in both women and men from a wide age range, including children.<sup>1 2</sup> The presenting symptoms may involve several systems: respiratory (dyspnoea, hyperventilation, sniffing), abdominal (abdominal pain, borborygmi, abdominal contractions, reflux) and

cardiac (palpitations and chest pain).<sup>2</sup> It is typically worse during waking hours, is provoked by stress and is relieved by sleep. As a consequence, the condition is often misdiagnosed as a psychiatric manifestation; its inability to desist or reduce on distraction argues against this.

Diaphragmatic flutter should be distinguished from 'belly dancer's dyskinesia'. Diaphragmatic flutter causes a semirhythmic jerking of the abdominal wall and displacement of the wall by the diaphragmatic activity. In 'belly dancer's dyskinesia', the abdominal wall movements are writhing and contorting, slowly displacing the umbilicus through contraction of the recti and oblique muscles.<sup>2</sup>

Diaphragmatic flutter has been associated with many central and peripheral disorders including, but not limited to, encephalitis, stroke, osmotic demyelination, metabolic abnormalities, trauma and phrenic nerve irritation. In our case, the symptoms coinciding temporally with the stroke makes a central vascular cause likely.

Diaphragmatic flutter was initially considered as a variant of palatal myoclonus, thus implicating the brainstem and particularly the dentate-rubro-olivary pathway. This is unsurprising given the similarities of myoclonic frequencies and structures involved. However, diaphragmatic flutter has its own distinct identity due to its presence in isolation and characteristics that are not evident in palatal myoclonus, such as its cessation during sleep and lack of involvement of the dentate-rubro-olivary pathway on imaging.<sup>2</sup>

The diagnosis of diaphragmatic flutter requires a high index of suspicion. If the symptom frequency allows, then thoracic videofluoroscopy is usually diagnostic; real-time imaging of the two haemidiaphragms may show the characteristic fluttering ([Video 2](#)). Electromyography can confirm the flutter frequency (0.5–8.0 Hz) of the diaphragmatic muscles and surrounding musculature.<sup>1</sup>

Treatment is mainly guided by case reports and expert advice. Patients may already have tried several medications based on other working diagnoses before seeing a neurologist. Treatments mostly include antiepileptic

and antipsychotic medications, such as phenytoin, carbamazepine and haloperidol. For refractory cases, damaging the responsible phrenic nerve gives varied results. Pharmacological block of the phrenic nerve provides short-lived relief; crushing or clipping of the nerve typically provides a longer-lasting relief, but symptoms can recur, presumably with nerve regeneration. Transecting the phrenic nerve has produced longer-lasting relief but leaves the patient with a paralysed haemidiaphragm.

Although rare, diaphragmatic flutter is probably under-reported due to its varied symptoms and its presentation to chest and cardiac clinics rather than to neurologists. Despite this, it is readily and strikingly identifiable on videofluoroscopy.

### Key points

- ▶ Diaphragmatic flutter is a rare but characteristic condition
- ▶ Thoracic videofluoroscopy is the usual diagnostic test. It should be differentiated from Belly Dancer's dystonia/dyskinesia.
- ▶ Treatment includes a number of antiepileptics and antipsychotic medication with variable response.

**Contributors** DW and MB were responsible for drafting the manuscript and subsequent revisions and are guarantors of the paper. MS provided critical revision for intellectual content.

**Competing interests** None declared.

**Patient consent** Obtained.

**Provenance and peer review** Commissioned; externally peer reviewed. This paper was reviewed by Jeremy Stern, London, UK.

© Article author(s) (or their employer(s) unless otherwise stated in the text of the article) 2017. All rights reserved. No commercial use is permitted unless otherwise expressly granted.

### REFERENCES

- 1 Larnar AJ. Antony van Leeuwenhoek and the description of diaphragmatic flutter (respiratory myoclonus). *Mov Disord* 2005;20:917–8.
- 2 Illiceto G, Thompson PD, Day BL, *et al.* Diaphragmatic flutter, the moving umbilicus syndrome, and "belly dancer's" dyskinesia. *Mov Disord* 1990;5:15–22.



## Diaphragmatic flutter

Dean Walton, Michael Bonello and Malcolm Steiger

*Pract Neurol* published online February 1, 2018

---

Updated information and services can be found at:

<http://pn.bmj.com/content/early/2018/01/31/practneurol-2017-001830>

---

*These include:*

### References

This article cites 2 articles, 0 of which you can access for free at:

<http://pn.bmj.com/content/early/2018/01/31/practneurol-2017-001830#ref-list-1>

### Email alerting service

Receive free email alerts when new articles cite this article. Sign up in the box at the top right corner of the online article.

---

### Notes

---

To request permissions go to:

<http://group.bmj.com/group/rights-licensing/permissions>

To order reprints go to:

<http://journals.bmj.com/cgi/reprintform>

To subscribe to BMJ go to:

<http://group.bmj.com/subscribe/>