

Akinetic mutism following prefrontal injury by an electrical grinder a case report

A diffusion tensor tractography study

Sung Ho Jang, MD^a, Seong Ho Kim, MD^b, Han Do Lee, MS^{a,*}

Abstract

Rationale: A 72-year-old male had suffered from head trauma resulting from injury to his frontal area by an electrical grinder while working at his home.

Patient concerns: He lost consciousness for approximately 10 minutes and experienced continuous post-traumatic amnesia.

Diagnoses: He was diagnosed as traumatic intracerebral hemorrhage in both frontal lobes, intraventricular hemorrhage, and subarachnoid hemorrhage, and underwent decompressive craniectomy and hematoma removal.

Interventions: The patient's Glasgow Coma Scale score was 5. At 2 months after onset, when starting rehabilitation, he showed no spontaneous movement or speech; he remained in a lying position all day with no spontaneous activity.

Outcomes: On 2-month diffusion tensor tractography, decreased neural connectivity of the caudate nucleus to the medial prefrontal cortex (PFC, Broadmann area [BA]: 10 and 12) and orbitofrontal cortex (BA 11 and 13) was observed in both hemispheres.

Lessons: Akinetic mutism following prefrontal injury.

Abbreviations: AM = akinetic mutism, BA = broadmann area, CN = caudate nucleus, DTT = diffusion tensor tractography, PFC = prefrontal cortex.

Keywords: caudate nucleus, diffusion tensor imaging, Glasgow Coma Scale, stroke

1. Introduction

A 72-year-old man had suffered from head trauma resulting from injury to his frontal area by an electrical grinder while working at his home. He was diagnosed as traumatic intracerebral hemorrhage in both frontal lobes, intraventricular hemorrhage, and subarachnoid hemorrhage, and underwent decompressive craniectomy and hematoma removal (Fig. 1A). He lost consciousness for approximately 10 minutes and experienced continuous posttraumatic amnesia. The patient's Glasgow Coma Scale score was 5. At 2 months after onset, when starting rehabilitation, he showed no spontaneous movement or speech;

he remained in a lying position all day with no spontaneous activity. Brain magnetic resonance imaging at 2 months after onset showed leukomalactic lesions in both frontal lobes (Fig. 1B). The patient's wife provided signed, informed consent, and our institutional review board approved the study protocol.

Diffusion tensor imaging data were acquired at 2 months after onset using a 6-channel head coil on a 1.5T Philips Gyroscan Intera (Philips, Ltd., Best, the Netherlands) with 32 diffusion gradients by single-shot echo-planar imaging. Imaging parameters were as follows: acquisition matrix = 96×96 ; reconstructed to matrix = 192×192 ; field of view = $240 \times 240 \text{ mm}^2$; repetition time = 10,398 ms; echo time = 72 ms; parallel imaging reduction factor = 2; echo-planar imaging factor = 59; $b = 1000 \text{ s/mm}^2$; and a slice thickness of 2.5 mm. Head motion effect and image distortion due to eddy current were corrected by affine multiscale two-dimensional registration. Fiber tracking was performed using probabilistic tractography, and applied in the default tractography option in the Oxford Centre for Functional Magnetic Resonance Imaging of the Brain (FMRIB) Diffusion Software (5000 streamline samples, 0.5 mm step lengths, curvature thresholds = 0.2). For reconstruction of the connectivity of the caudate nucleus (CN), the seed region of interest: the CN which was isolated by adjacent structures—the lateral ventricle (medial boundary), the anterior limb of the internal capsule (lateral boundary).^[1] The threshold of 10 streamlines was applied for the results of fiber tracking.

On 2-month diffusion tensor tractography (DTT), decreased neural connectivity of the CN to the medial prefrontal cortex (PFC, Broadmann area [BA]: 10 and 12) and orbitofrontal cortex (BA 11 and 13) was observed in both hemispheres (Fig. 1C).

In this study, the patient lost the majority of both medial and orbitofrontal prefrontal cortex by an electrical grinder injury.

Editor: Massimo Tusconi.

Funding: This work was supported by the Medical Research Center Program (2015R1A5A2009124) through the National Research Foundation of Korea (NRF) funded by the Ministry of Science, ICT and Future Planning.

The authors have no conflicts of interest to disclose.

^a Department of Physical Medicine and Rehabilitation, ^b Department of Neurosurgery, College of Medicine, Yeungnam University, Republic of Korea.

* Correspondence: Han Do Lee, Department of Physical Medicine and Rehabilitation, College of Medicine, Yeungnam University 317-1, Daemyungdong, Namku, Taegu, 705-717, Republic of Korea (e-mail: lhd890221@hanmail.net).

Copyright © 2018 the Author(s). Published by Wolters Kluwer Health, Inc. This is an open access article distributed under the terms of the Creative Commons Attribution-Non Commercial-No Derivatives License 4.0 (CCBY-NC-ND), where it is permissible to download and share the work provided it is properly cited. The work cannot be changed in any way or used commercially without permission from the journal.

Medicine (2018) 97:6(e9845)

Received: 31 May 2017 / Received in final form: 3 January 2018 / Accepted: 21 January 2018

<http://dx.doi.org/10.1097/MD.00000000000009845>

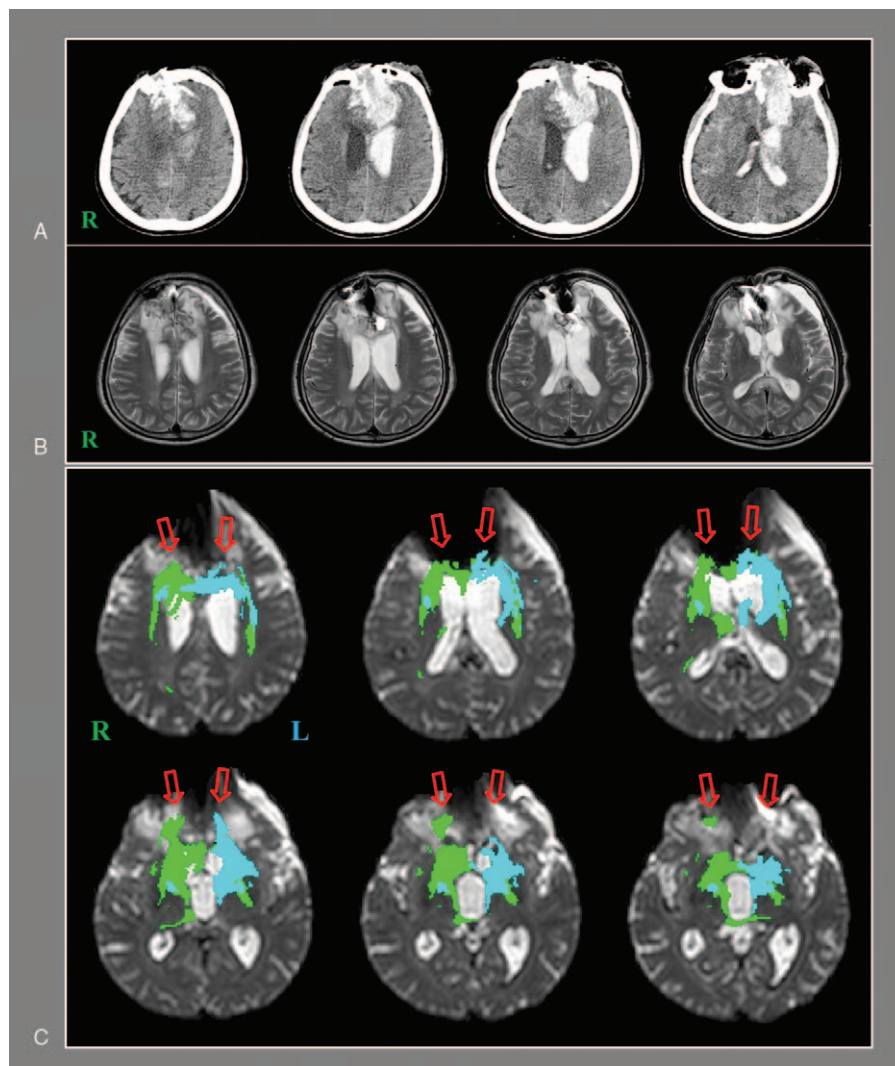


Figure 1. (A) Brain computed tomography images at onset show traumatic intracerebral hemorrhage in both frontal lobes and intraventricular hemorrhage. (B) T2-weighted brain MR images at 2 months after onset show leukomalactic lesions in both frontal lobes. (C) On 2-month diffusion tensor tractography, the neural connectivity of the caudate nucleus to the medial prefrontal cortex (PFC, Brodmann area [BA]: 10 and 12) and orbitofrontal cortex (BA 11 and 13) is decreased (arrows) in both hemispheres.

The PFC is involved in various cognitive functions including working memory, attention, decision-making, execution, behavior inhibition, and motivation.^[2,3] The PFC consists of 4 subregions, each of which is known to have specific roles in cognition: dorsolateral prefrontal cortex attention, planning, working memory and mood control, ventrolateral prefrontal cortex—deliberation of decision-making, behavior regulation, trial-and-error learning, and goal-directed behavior, orbitofrontal cortex—emotional control and inhibitory control of behavior, and the medial PFC—motivation and initiation of activity.^[3–5] The PFC receives afferent fibers from the thalamic mediodorsal nucleus through the prefronto-thalamic tract and the CN through the prefronto-caudate tract.^[4–9] In this patient, the neural connectivity from the CN to the medial and orbitofrontal prefrontal cortices was decreased in both hemispheres. This result indicated severe injury of both prefronto-caudate tracts. Akinetic mutism (AM) is characterized by a complete absence of spontaneous behavior and speech.^[10,11] Bilateral disruption of the fronto-subcortical circuit has been suggested as a pathogenetic mechanism of AM.^[10–12] In particular, the neural tract

connected to the medial PFC is associated with motivation among the neural tracts in the fronto-subcortical circuit.^[12–15] Thus, the patient's AM appeared to be ascribed, at least in part, to injury of the prefronto-caudate tract in both hemispheres.

In conclusion, using DTT, injuries of the prefronto-caudate tract were demonstrated in a patient who developed AM following severe traumatic brain injury. We believe that injury of the prefronto-caudate tract might be a pathogenetic mechanism of AM in patients with brain injury. However, because this study was conducted retrospectively and the patient showed severe mutism, we could not perform other neuropsychological tests. Therefore, our results suggest the necessity of evaluation of the fronto-subcortical circuit in patients who develop AM after brain injury.

References

- [1] Leh SE, Ptito A, Chakravarty MM, et al. Fronto-striatal connections in the human brain: a probabilistic diffusion tractography study. *Neurosci Lett* 2007;419:113–8.
- [2] Mesulam MM. *Principles of Behavioral and Cognitive Neurology*. 2nd ed. Oxford University, New York: 2000.

- [3] Cummings JL. Frontal-subcortical circuits and human behavior. *Arch Neurol* 1993;50:873–80.
- [4] Duffy JD, Campbell JJJ3rd. The regional prefrontal syndromes: a theoretical and clinical overview. *J Neuropsychiatry Clin Neurosci* 1994;6:379–87.
- [5] Jang SH, Yeo SS. Thalamocortical connections between the mediodorsal nucleus of the thalamus and prefrontal cortex in the human brain: a diffusion tensor tractographic study. *Yonsei Med J* 2014;55:709–14.
- [6] Jang SH, Kim SH, Lee HD. Recovery of an injured prefronto-caudate tract in a patient with traumatic brain injury: a diffusion tensor tractography study. *Brain Inj* 2017;31:1548–51.
- [7] Jang SH, Kwon HG. Akinetic mutism in a patient with mild traumatic brain injury: a diffusion tensor tractography study. *Brain Inj* 2017;31:1159–63.
- [8] Kito S, Jung J, Kobayashi T, et al. Fiber tracking of white matter integrity connecting the mediodorsal nucleus of the thalamus and the prefrontal cortex in schizophrenia: a diffusion tensor imaging study. *Eur Psychiatry* 2009;24:269–74.
- [9] Jang SH, Yi JH, Kwon HG. Injury of the dorsolateral prefronto-thalamic tract in a patient with depression following mild traumatic brain injury: a case report. *Medicine (Baltimore)* 2016;95:e5009.
- [10] Mega MS, Cohenour RC. Akinetic mutism: disconnection of frontal-subcortical circuits. *Neuropsychiatry Neuropsychol Behav Neurol* 1997;10:254–9.
- [11] Marin RS, Wilkosz PA. Disorders of diminished motivation. *J Head Trauma Rehabil* 2005;20:377–88.
- [12] Nagaratnam N, Nagaratnam K, Ng K, et al. Akinetic mutism following stroke. *J Clin Neurosci* 2004;11:25–30.
- [13] Psarros T, Zouros A, Coimbra C. Bromocriptine-responsive akinetic mutism following endoscopy for ventricular neurocysticercosis. Case report and review of the literature. *J Neurosurg* 2003;99:397–401.
- [14] Levy R, Dubois B. Apathy and the functional anatomy of the prefrontal cortex-basal ganglia circuits. *Cereb Cortex* 2006;16:916–28.
- [15] Fuster JM. *The Prefrontal Cortex: Anatomy, Physiology, and Neuropsychology of the Frontal Lobe*; Chapter 5: Human Neuropsychology. 4th ed. Lippincott-Raven, Philadelphia: 2008.