

Multiple cranial neuropathies as a presentation of spontaneous internal carotid artery dissection: A case report and literature review



Stephen W. English^a, Theodore J. Passe^b, E. Paul Lindell^b, James P. Klaas^{a,*}

^a Department of Neurology, Mayo Clinic, Rochester, MN 55905, USA

^b Department of Radiology, Mayo Clinic, Rochester, MN 55905, USA

ARTICLE INFO

Article history:

Received 16 November 2017

Accepted 8 January 2018

Keywords:

Carotid dissection

Cranial neuropathy

Compressive hypoglossal neuropathy

T1-weighted fat saturation MRI

ABSTRACT

Cervical artery dissection is an underrecognized cause of lower cranial neuropathies and diagnosis can remain elusive if not properly investigated. We present a case of an internal carotid artery dissection that was initially missed in a 48-year-old man who presented with subacute-onset of dysarthria, dysphagia, and unilateral tongue weakness. Knowledge of the most common presenting symptoms, relevant neuroanatomy, and neuroimaging techniques is essential to avoid misdiagnosis. Pseudoaneurysm formation from subadventitial carotid artery dissection may result in compressive neuropathies of cranial nerves IX, X, XI, and XII without associated cerebral ischemia. The absence of intraluminal narrowing on CT or MR angiography should not dissuade the clinician; T1-weighted axial cervical MRI with fat-saturation provides the highest sensitivity and specificity to identify these lesions.

© 2018 Elsevier Ltd. All rights reserved.

1. Case description

A 48-year-old man presented to an outside hospital one-day after developing progressive left-sided tongue weakness, dysarthria, dysphagia, and left arm incoordination. He described onset of headache, sore throat, and malaise three days prior to presentation.

Initial evaluation included computerized topography (CT), CT angiogram (CTA), and magnetic resonance imaging (MRI). These studies were reportedly unremarkable, except for an incidental 5-mm pituitary stalk lesion. Cerebrospinal fluid (CSF) and serologic testing was unrevealing, including screening for infectious, metabolic, autoimmune, paraneoplastic, connective tissue, and vasculitic disorders. Electromyography (EMG) found decreased recruitment of the left genioglossus muscle and associated spontaneous insertional activity. The patient was discharged without a diagnosis.

He presented to our institution two months later for further evaluation. Physical examination revealed mild left-sided tongue weakness. Neuroimaging was reviewed by our radiologist; initial CTA demonstrated mild luminal irregularity of the left cervical internal carotid artery (ICA) at the skull base, with a ring of surrounding soft tissue density material suggestive of an arterial dissection (Fig. 1). MRI confirmed the left ICA dissection, revealing intramural hematoma causing mass effect upon the left internal jugular vein in the region of the expected course of the left hypoglossal nerve (Fig. 2). Follow-up CTA 3 months later demonstrated resolving intramural hematoma, resolution of mass effect on the left internal jugular vein and resolution of the previously demonstrated left ICA luminal irregularity with no pseudoaneurysm formation (Fig. 3).

2. Discussion

Cervical artery dissection (CAD) is a well-recognized cause of ischemic stroke, but it is an underrecognized cause of lower brainstem cranial neuropathies. Incidence of CAD in the general popula-

tion is estimated to be approximately 2.6 per 100,000 per year with a mean age at presentation of 45.8 years [1]. While the pathophysiology is poorly understood, patients with connective tissue disease and concomitant arterial anomalies such as fibromuscular dysplasia are at higher risk [2,3]. Additional environmental factors including chiropractic manipulation and antecedent infection have also been reported [2,4].

Neck pain and headache are the most common initial symptoms, with focal neurologic deficits arising over minutes to weeks later [2,5]. Arterial dissections can be subintimal or subadventitial, and clinical presentation varies based on location and severity of dissection. Subintimal dissections are more likely to cause luminal narrowing, thrombus formation, and subsequent cerebral ischemia from thromboembolism or hypoperfusion. Subadventitial dissections typically result in aneurysm formation through outpouching of the arterial wall or pseudoaneurysm formation through breaching of the adventitia [6]. Subadventitial dissections are more likely to result in Horner's syndrome via disruption of the sympathetic fibers traversing the carotid sheath and cranial neuropathies via direct compression of nearby nerves [2,5,6].

The extracranial ICA is most vulnerable to dissection, particularly 2–3 cm above the carotid bifurcation where it is susceptible to shear stress [2,6]. At this level, the ICA is in close proximity to multiple cranial nerves (CN). CN IX, X, and XI exit the skull base through the jugular foramen and pass through the retropharyngeal space in close proximity to CN XII, which exits the skull base medially in the hypoglossal foramen. Multiple studies have implicated cranial neuropathies in ICA dissections in anywhere from 7% to 12% of cases [5,7]. Hypoglossal nerve involvement is the most common cranial nerve palsy, followed by CN IX, X, and XI [5,8–10]. Involvement of more rostral cranial nerves including oculomotor, trigeminal, and facial nerves have been described [5,11–13], but these are exceptionally rare.

Our patient's presentation was explained by mass effect from the intramural blood products related to the left ICA dissection within the retropharyngeal space. This case highlights the importance of MRI in evaluation of carotid dissection, as angiography can miss subadventitial dissections due to the absence of luminal narrowing. We prefer the use of T1-weighted axial cervical MRI with fat-saturation due to the high sensitivity and specificity for CAD [14]. Ultimately, CAD should be considered in young patients

* Corresponding author at: Department of Neurology, Mayo Clinic, 200 First Street Southwest, Rochester, MN 55905, USA.

E-mail address: Klaas.James@mayo.edu (J.P. Klaas).

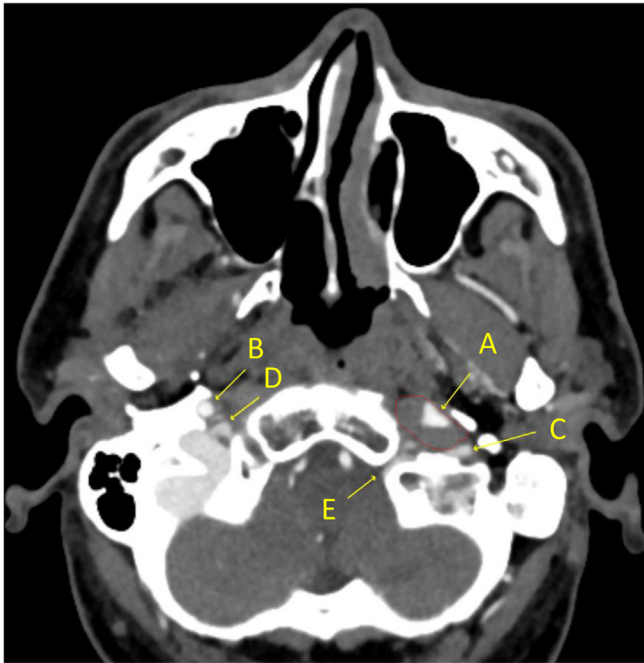


Fig. 1. CTA at the time presentation: Source image at the level of the skull base demonstrates deformity of the left ICA lumen (A) which is partially encased by soft tissue density material (red outline) consistent with arterial dissection. Partial effacement of the internal jugular vein (C) just below the jugular bulb. The close relationship of the dissection to the left hypoglossal canal (E) is also demonstrated. Normal contralateral right ICA (B) and jugular bulb (D).

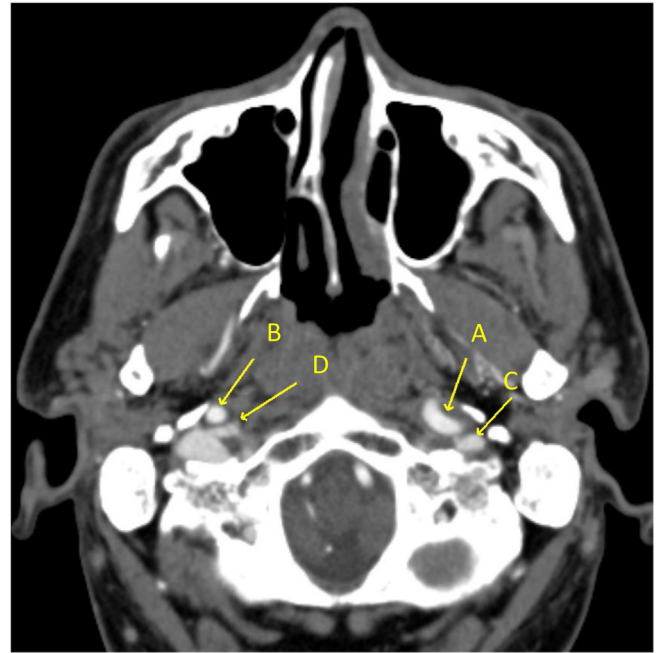


Fig. 3. Follow up CTA approximately 3 months after presentation: Source image demonstrates resolving intramural blood products around the left ICA (A) and resolution of mass effect upon the left internal jugular vein (C) and along the path of the hypoglossal nerve. Normal contralateral right ICA (B) and internal jugular vein (D).

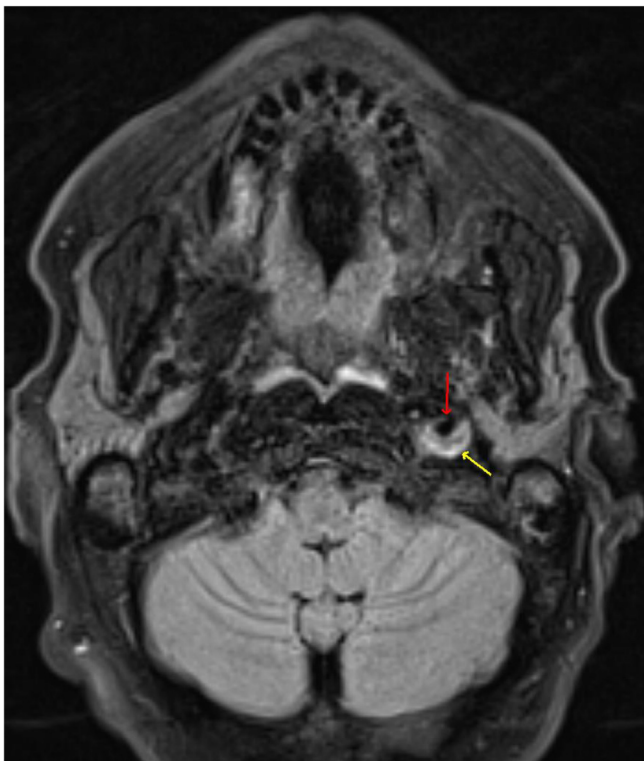


Fig. 2. Head MRI at presentation: Axial fat-saturated FLAIR (Fluid-Attenuated Inversion-Recovery) image at the level of the skull base demonstrate intramural blood products consistent with arterial dissection (yellow arrow) along the posterior aspect of the left ICA (red arrow), corresponding to the abnormal soft tissue density on the CTA source images.

with isolated lower cranial nerve palsies, particularly if accompanied by prodromal headache and neck pain.

Sources of support

This research did not receive any specific grant from funding agencies in the public, commercial, or not-for-profit sectors.

Conflict of interest

The authors declare no conflicts of interest.

Appendix A. Supplementary data

Supplementary data associated with this article can be found, in the online version, at <https://doi.org/10.1016/j.jocn.2018.01.056>.

References

- [1] Lee VH et al. Incidence and outcome of cervical artery dissection: a population-based study. *Neurology* 2006;67(10):1809–12.
- [2] Debette S, Leys D. Cervical-artery dissections: predisposing factors, diagnosis, and outcome. *Lancet Neurol* 2009;8(7):668–78.
- [3] Brandt T, Grond-Ginsbach C. Spontaneous cervical artery dissection: from risk factors toward pathogenesis. *Stroke* 2002;33(3):657–8.
- [4] Rubinstein SM et al. A systematic review of the risk factors for cervical artery dissection. *Stroke* 2005;36(7):1575–80.
- [5] Mokri B et al. Cranial nerve palsy in spontaneous dissection of the extracranial internal carotid artery. *Neurology* 1996;46(2):356–9.
- [6] Caplan LR, Gonzalez RG, Buonanno FS. Case records of the Massachusetts General Hospital. Case 18-2012. A 35-year-old man with neck pain, hoarseness, and dysphagia. *N Engl J Med* 2012;366(24):2306–13.
- [7] Arnold M et al. Gender differences in spontaneous cervical artery dissection. *Neurology* 2006;67(6):1050–2.
- [8] Waespe W et al. Lower cranial nerve palsies due to internal carotid dissection. *Stroke* 1988;19(12):1561–4.
- [9] Sturzenegger M, Huber P. Cranial nerve palsies in spontaneous carotid artery dissection. *J Neurol Neurosurg Psychiatry* 1993;56(11):1191–9.

- [10] Cruciata G et al. Internal carotid artery dissection and pseudoaneurysm formation with resultant ipsilateral hypoglossal nerve palsy. *Radiol Case Rep* 2017;12(2):371–5.
- [11] Gobert M et al. Cranial nerve palsies due to internal carotid artery dissection: seven cases. *Acta Neurol Belg* 1996;96(1):55–61.
- [12] Santos T et al. Isolated oculomotor nerve palsy: a rare manifestation of internal carotid artery dissection. *BMJ Case Rep* 2014.
- [13] Naik VD, Shah JV. A rare combination of facial and hypoglossal nerve palsies following post-traumatic internal carotid artery dissection. *BMJ Case Rep* 2015.
- [14] Bisseret D et al. Spontaneous cervical artery dissection: Role of a SE-T1-weighted fat-sat volume acquisition. *Diagn Interv Imaging* 2014;95(4):443–6.

<https://doi.org/10.1016/j.jocn.2018.01.056>

Novel SGCE mutation in a patient with myoclonus-dystonia syndrome – Diagnostic delay of more than 40 years



Dorothee Kübler^{a,*}, Friederike Borngräber^a, Katja Lohmann^b, Andrea A. Kühn^a

^aCharité – Universitätsmedizin Berlin, Corporate Member of Freie Universität Berlin, Humboldt-Universität zu Berlin, and Berlin Institute of Health, Movement Disorders Section, Campus Virchow Klinikum and Campus Mitte, Department of Neurology, Charitéplatz 1, 10119 Berlin, Germany

^bInstitute of Neurogenetics, University of Lübeck, Maria-Goeppert-Straße 1, 23562 Lübeck, Germany

ARTICLE INFO

Article history:

Received 24 October 2017

Accepted 8 January 2018

Keywords:

Myoclonus dystonia

DYT11

SGCE gene

Novel mutation

Psychiatric symptoms

ABSTRACT

We present a case of myoclonus-dystonia syndrome illustrated by three videos in which we found a novel SGCE mutation. As the patient described here was suffering from predominant psychiatric comorbidities it took more than 40 years from the first manifestation of the disease until the diagnosis. Having detected the genetically proven cause for his motor and non-motor symptoms was an enormous relief to our patient. We want to share this instructive case in order to prompt neurologists and psychiatrists to look closely at both movement disorders and neuropsychiatric signs in order to diagnose and treat patients to the latest standard.

© 2018 Elsevier Ltd. All rights reserved.

1. Case report

Myoclonus-dystonia syndrome (M-D) is a rare movement disorder characterized by myoclonic jerks and dystonic symptoms, typically writer's cramp and cervical dystonia. Here we present a case of a novel SGCE mutation with prominent psychiatric comorbidity including videos of this typical presentation of M-D.

The movement disorder presents in the first or second decade with an estimated prevalence of 1–9/1,000,000 in Europe [1]. In 40–50% of cases a mutation in the SGCE gene is found (DYT-SGCE, formerly DYT11, OMIM#159900) encoding the epsilon-sarcoglycan protein, a transmembrane glycoprotein that mediates the stability of the plasma membrane [2]. More than 100 SGCE mutations have been described, with the majority of mutations leading to premature protein truncation, i.e. nonsense, splicing or frameshift mutations (<http://www.hgmd.cf.ac.uk/ac/gene.php?gene=SGCE>). Psychiatric comorbidities include depression, anxiety and obsessive-compulsive disorders as well as alcohol abuse [3] as myoclonic jerks are typically responsive to alcohol. They are considered part of the DYT-SGCE phenotype though it is not clear if this reflects a pleiotropic function of SGCE within the CNS causing primary psychiatric disorders or a secondary effect of the movement disorder [4].

A 54-year old male of European descent from non-consanguineous parents presented in our movement disorders outpatient clinic. He reported involuntary movements since childhood. The patient exhibited complex bilateral myoclonic jerks mainly involving the upper trunk and neck, a lateral shift of the head to the right and a writer's cramp. Three videos (coordination,

handwriting and walking) are accompanying the online version of this manuscript. Importantly, he reported mild depressive symptoms, obsessive thoughts and actions for more than 20 years as well as nightly panic attacks. These psychiatric symptoms were interfering with his activities of daily living triggering psychiatric consultations during adulthood.

Neuropsychological testing had always been normal. Routine laboratory tests including blood, urine and CSF performed repeatedly showed unremarkable results. Various MRI scans of the brain indicated no abnormalities. Repetitive EEGs did not reveal signs of increased cortical excitability. During childhood, the diagnosis of Dyssynergia Cerebellaris Myoclonica (Ramsay Hunt syndrome) was made but no epileptic seizures were reported. Later differential diagnosis comprised a tic disorder because of the reported ability to suppress the involuntary movements for several seconds and the prominent obsessive thoughts and compulsions. Moreover, a psychogenic movement disorder was taken into account as movements were considered bizarre. Medication trials included valproate, primidone and clozapine without beneficial effects. Only clonazepam led to a reduction in myoclonus but was not tolerated because of excessive sleepiness. Amelioration of the symptoms could only be achieved by drinking alcohol. After his divorce at the age of 32 years, he became alcohol dependent. Following several withdrawal treatments he finally managed to become abstinent one year prior to his first appointment in our department.

The family history was unremarkable except for alcohol dependency in his father with whom he had not been in contact for 20 years. His mother and two maternal half siblings were reported healthy. The patient himself did not have children of his own.

Due to the characteristic presentation of myoclonic jerks predominantly at the upper limbs and trunk starting in early child-

* Corresponding author.

E-mail address: dorothee.kuebler@charite.de (D. Kübler).