

# Neurocase

## The Neural Basis of Cognition

ISSN: 1355-4794 (Print) 1465-3656 (Online) Journal homepage: <http://www.tandfonline.com/loi/nncs20>

# Unilateral Apraxic Agraphia without Ideomotor Apraxia from a callosal lesion in a patient with Marchiafava-Bignami disease

T. Kesayan & K.M. Heilman

To cite this article: T. Kesayan & K.M. Heilman (2018): Unilateral Apraxic Agraphia without Ideomotor Apraxia from a callosal lesion in a patient with Marchiafava-Bignami disease, *Neurocase*, DOI: [10.1080/13554794.2018.1444780](https://doi.org/10.1080/13554794.2018.1444780)

To link to this article: <https://doi.org/10.1080/13554794.2018.1444780>



Published online: 26 Feb 2018.



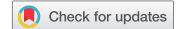Submit your article to this journal [↗](#)



View related articles [↗](#)



View Crossmark data [↗](#)



# Unilateral Apraxic Agraphia without Ideomotor Apraxia from a callosal lesion in a patient with Marchiafava-Bignami disease

T. Kesayan<sup>a,b</sup> and K.M. Heilman<sup>c,d</sup>

<sup>a</sup>Department of Neurology, University of South Florida Morsani College of Medicine, Tampa, FL, USA; <sup>b</sup>Department of Neurology, James A. Haley Veteran's Affairs Hospital, Tampa, FL, USA; <sup>c</sup>Neurology Service and GRECC, Malcom Randall Veterans Affairs Medical Center, Gainesville, FL, USA; <sup>d</sup>Department of Neurology, University of Florida College of Medicine, Gainesville, FL, USA

## ABSTRACT

Apraxic agraphia can be caused by left hemispheric cerebral lesions in the area that contains the spatial representations of the movements required to write, from a lesion in, or connections to, the frontal premotor cortex that converts these spatial representations to motor programs (Exner's area). A right-handed woman with Marchiafava Bignami disease and lesions of the genu and splenium of her corpus callosum had apraxic agraphia without ideomotor apraxia of her left. A disconnection of Exner's area in the left hemisphere from the right hemisphere's premotor and motor areas may have led to her inability to write with her left hand.

## ARTICLE HISTORY

Received 2 December 2017  
Accepted 19 February 2018

## KEYWORDS

Agraphia; Apraxia;  
callosal disconnection;  
Marchiafava-Bignami

## Introduction

Marchiafava-Bignami (MB) disease was first described in 1903 as a rare and fatal disease in Italians who heavily drank wine (Marchiafava & Bignami, 1903). MB disease is characterized by demyelination and later necrosis of the corpus callosum seen mainly in people who are alcoholics, but is also very rarely seen in other conditions, such as diabetes mellitus (Lakatos et al., 2014). Patients with MB typically present with cognitive impairments, hypertonia, gait abnormalities, and dysarthria, and some may develop seizures (Heinrich, Runge, & Khaw, 2004). Recently, Heinrich and colleagues categorized patients with MB into two types (Heinrich et al., 2004). Type A often presents with coma or stupor and is often associated with disability, with about a 21% death rate. In contrast, Type B is less commonly associated with disability, and patients with this disorder rarely die. These two subtypes often also differ in the forms of damage to the corpus callosum. Whereas the patients with Type A have most of their corpus callosum damaged, those with Type B often have focal corpus callosum injury, the most common areas being the splenium and the genu (Delangre et al., 1986).

An inability to perform skilled and purposeful actions in the absence of weakness, sensory loss, movement disorders, or any other confounding medical complications limiting fine motor movements is termed apraxia. The term apraxia was first used by Steinthal to describe an inability to correctly perform purposeful movements in the absence of weakness (Steinthal, 1871). Although Steinthal is credited for the term, it was Hugo Liepmann who made many of the first major contributions to the understanding of apraxia. In a series of papers, (Liepmann, 1905, 1920; Liepmann & Maas, 1907), Liepmann described ideomotor apraxia (IMA) where patients often make postural errors such as using body part as a tool (Goodglass & Kaplan, 1963) as well as making incorrect movements of their joints in relation to

their body and in relation to objects with which they are interacting (Poizner, Mack, Verfaellie, Rothi, & Heilman, 1990; Rothi, Mack, Verfaellie, Brown, & Heilman, 1988). Liepmann and Maas (1907) described a patient with a lesion of the corpus callosum who revealed an IMA of his left upper limb; however, this patient had a prior right hemiparesis from a pontine lesion as well as a medial left frontal lesion. As medial left frontal injury may produce an IMA of both hands and this patient's right hand could not be tested, it is not clear if this patient had a unilateral callosal ideomotor apraxia (Watson, Fleet, Gonzalez-Rothi, & Heilman, 1986). However, subsequently, unilateral left upper limb IMA induced by a callosal lesion has been reported (Graff-Radford, Welsh, & Godersky, 1987; Watson & Heilman, 1983).

Patients with limb kinetic apraxia (LKA), as described by Liepmann (1920), have a loss of deftness with an impaired ability to make independent and precise coordinated movements with their hand and fingers. Kleist also described patients with a similar disorder that he called "innovatory apraxia." (Heilman & Watson, 2008; Kleist, 1934). Verstichel and Meyrignac described a patient with an infarct involving the anterior and middle parts of the corpus callosum who had an impairment in the ability to make fast and deft movements with his left hand (Verstichel & Meyrignac, 2000). Acosta, Bennett, and Heilman also described a patient with a lesion in the body of the corpus callosum who had an IMA, as well as LKA of his left hand, when tested with the coin rotation test (Acosta, Bennett, & Heilman, 2014).

Apraxic agraphia is a disorder where a person is impaired in making the finger, hand, and arm movements needed to correctly write in the absence of primary sensorimotor disorders as well as without impaired language, spelling, or typing abilities (Heilman, Coyle, Gonyea, & Geschwind, 1973; Heilman, Gonyea, & Geschwind, 1974; Heilman & Watson, 2008; Valenstein & Heilman, 1979). Patients have been described who have apraxic

agraphia without other forms of limb apraxia. For example, Roeltgen and Heilman (1983) described a 75-year old right-handed man with a right parietal lesion who demonstrated agraphia with preserved spelling, and was without any form of limb apraxia (Roeltgen & Heilman, 1983). These authors suggested that this right-handed man with crossed aphasia had apraxic agraphia because the movement representations for writing were located in the damaged right hemisphere, but his non-damaged left hemisphere was mediating the movement representations for other forms of purposeful movements. Coslett and colleagues described two right-handed patients with left hemisphere language dominance who suffered from left middle cerebral artery (MCA) territory infarcts in whom praxis and writing were affected differently (Coslett, Gonzales Rothi, Valenstein, & Heilman, 1986). One patient had apraxic agraphia without language impairments or other types of limb apraxia; whereas, the other patient had linguistic agraphia and an ideomotor apraxia, with no impairment in grapheme production (1986). These authors suggested that like the dissociation between linguistic and motoric components of writing (1986), these cases illustrate that IMA and apraxic agraphia can be dissociated and therefore are separate entities.

The reports demonstrate that apraxic agraphia can occur in the absence of other forms of limb apraxia, aphasia, or linguistic agraphia. This dissociation suggests that different movement representations are essential for writing and for performing other transitive and intransitive movements of the upper limb and that these two different types of movement representations are stored in different parts of the brain (Coslett et al., 1986; Heilman & Watson, 2008; Roeltgen & Heilman, 1983). There have also been reports of patients with apraxic agraphia from callosal lesions (Falchook, Watson, & Heilman, 2016; Liepmann & Maas, 1907; Watson & Heilman, 1983); however, these patients also had IMA. In addition, there have been reports of patients with callosal lesions who revealed left upper limb IMA and LKA, but without apraxic agraphia (Acosta et al., 2014). These reports of dissociation between the hemispheric and callosal lesions that induce an IMA or LKA, without an apraxic agraphia, and vice versa, provide support for the postulate that the graphemic movement representations are stored in different areas than those that store other transitive and intransitive movement representations. In addition, these graphemic movement representations are also transferred across the corpus callosum in a different area than the one that transfers other movement representations. To the best of our knowledge, however, there has

been no report of a patient with unilateral (left-handed) apraxic agraphia in the absence of an IMA. In addition, we are unaware of any reports of patients with MB who revealed a unilateral apraxic agraphia.

### Case report

Our patient is a 38-year-old right-handed Caucasian woman with 1 year of declining cognition and a 2-week history of difficulty with speech and inability to walk prior to hospitalization. Over the past year, she has had a progressive decrease in her appetite. She had worked as a propane delivery truck driver up until 3 weeks prior to presentation.

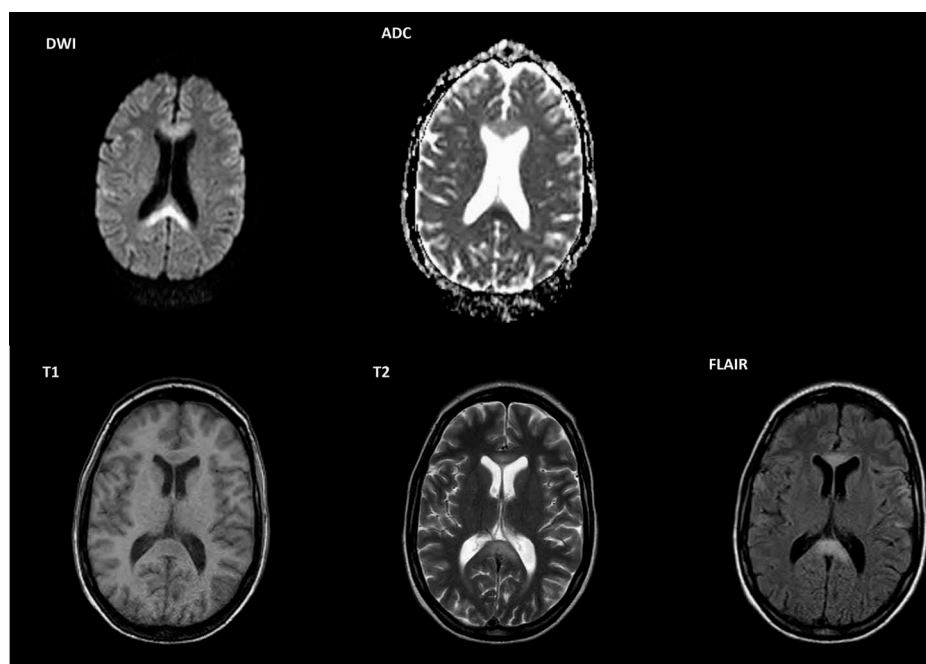
On her initial physical examination, she was awake, agitated, could intermittently follow simple commands, had a spastic dysarthria, and was only able to say several words. On cranial nerve examination, her extraocular movements were full and without nystagmus. Her pupils were round and reactive to light and accommodation. Her face was symmetric, and her palate elevated symmetrically. On motor examination, she was cachectic, had a fine high frequency tremor in both hands and all fingers with arms outstretched, had an increased spastic tone in her limbs, and a mild ataxia with movements of arms and legs. Her deep tendon reflexes were 3+ and symmetrical at biceps, brachioradialis, patella, and Achilles tendon. Initially, a sensory examination could not be adequately performed owing to her cognitive and speech difficulties. She was also unable to safely stand or walk.

Laboratory evaluation including a complete blood count and comprehensive metabolic panel was within norms except for a low albumin level of 2.6 mg/dL (normal 3.5–5.0 mg/dL). Her vitamin B12 level was 1146 pg/mL. It was not known if she was recently given vitamin B12 supplementation. Her vitamin B1 level was below 7 nmol/L (8–30 nmol/L), the lowest detectable level for the testing laboratory. Analysis of the cerebrospinal fluid (CSF) revealed a colorless fluid with 4 red blood cells (RBC), 1 nucleated cell, a protein of 37 (15–45 mg/dL), and a glucose of 54 (40–70 mg/dL). Table 1 provides the results of her serum and CSF laboratory evaluations.

In addition to the tests depicted in Table 1, a urine drug screen was also conducted on the day of presentation, and was only positive for cannabinoids. An MRI of her brain showed restricted diffusion in the genu and splenium of

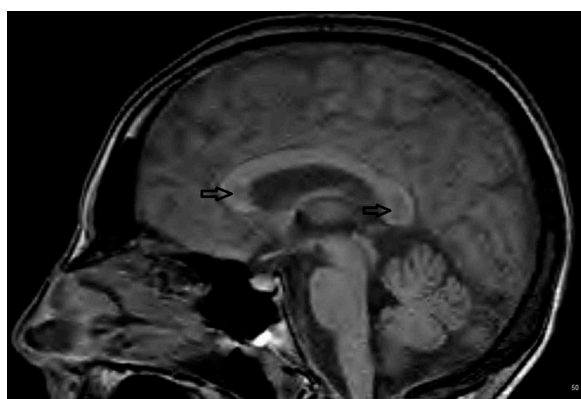
**Table 1.** Serum and cerebrospinal fluid (CSF) laboratory evaluations.

SERUM		CSF	
Homocysteine	7.9 (nl 5.1–15.4 umol/L)	CSF Color	Colorless
Vitamin B12	1146 (nl 189–883 pg/mL)	CSF Nucleated cells	1 (<5/uL)
Folate	14.9 (nl 7.0–31.4 ng/mL)	CSF RBCs	4
Methylmalonic acid	75 (nl 87–318 nmol/L)	CSFS Lymphocytes	15%
Ceruloplasmin	19 (nl 20–60 mg/dL)	CSF Glucose	54 (40–70mg/dL)
Vitamin B1	<7 (nl 8–30 nmol/L)	CSF Protein	37(15–45mg/dL)
Vitamin B6	2.3 (nl 2.1–21.7ng/mL)	VDRL	Nonreactive
Vitamin D	19.8 (nl 13.0–47.8 ng/mL)	RPR	Nonreactive
Alpha-tocopherol	7.3 (nl 5.7–19.9 mg/L)	Lyme	Undetected
Beta-gamma tocopherol	<1.0 (nl > 4.3 mg/L)	CMV	Undetected
TSH	0.77 (nl 0.35–4.94 UIU/mL)	Herpes Simplex I+II	Negative
Albumin	2.6 (nl 3.5–5.0 mg/dL)		
Calcium	8.3 (nl 8.5–10.5 mg/dL)		
Phosphorus	2.5 (nl 2.7–4.5 mg/dL)		

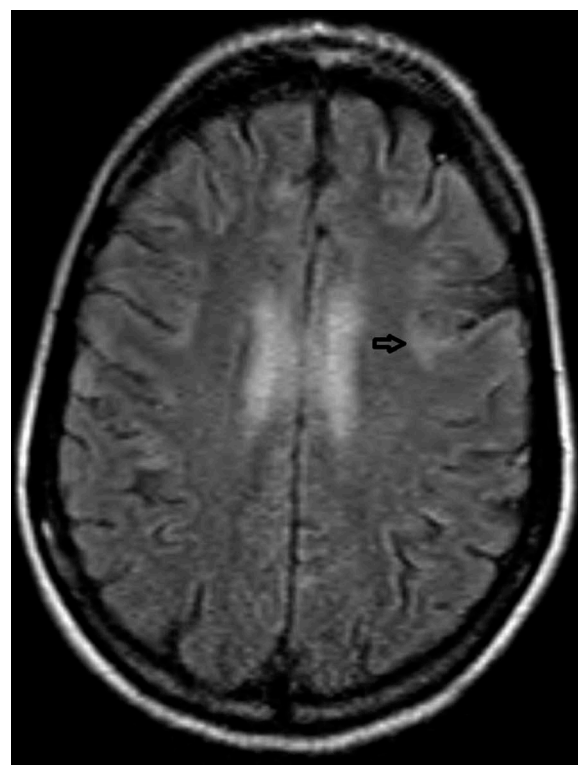


**Figure 1.** MRI of the brain with DWI sequence showing restricted diffusion in the genu and splenium of the corpus callosum with a corresponding hypo-intense region on ADC sequence. T1 sequence with hypo-intensity in the genu and splenium with corresponding hyper-intensity on T2 and FLAIR. A contrasted study did not show enhancements (not shown).

the corpus callosum on diffusion weighted images (DWI) and a corresponding hypo-intense region on apparent diffusion coefficient (ADC) sequences (Figure 1), as well as T1 sequence with hypo-intensity in the genu and splenium with corresponding hyper-intensity on T2 and FLAIR (Figures 2 and 3). MRI findings in MB have been reported to include T1-weighted hypo-intensity and T2-weighted and FLAIR hyper-intensity within the corpus callosum, specifically of the splenium. Acute cases of MB also show restricted diffusion on DWI sequence (Logan et al., 2016). MRI brain imaging revealed abnormalities compatible with MB. In regard to other possible disorders that may reveal similar images and a similar clinical presentation, she had no risk factors for stroke; there was no trauma or other disorders that could have produced diffuse axonal injury. Her CSF evaluation revealed no oligoclonal bands nor



**Figure 2.** T1 sagittal sequence demonstrating abnormal signal in genu and splenium of the CC.



**Figure 3.** FLAIR sequence demonstrating a possible lesion within the frontal lobe corresponding to Exner's area.

elevated IgG index, as well as no prior neurological symptoms, and she had no other MRI lesions consistent with a diagnosis of multiple sclerosis. CSF was also without atypical cells on cytometry or flow cytology, which would have raised concern for central nervous system (CNS) lymphoma.

When the diagnosis of MB disease was made she was treated with a 5-day course of intravenous methylprednisolone 1 g/day and with 500 mg IV thiamin daily for 5 days, followed by a 21 day course of daily IV multivitamin cocktail, which contained 100 mg thiamin and 1 mg folic acid. After several days of treatment, she improved, was more verbal, and explained that she drank at least one bottle of red wine every day for the past year or so.

After several weeks, examination revealed an alert woman, who was oriented to herself, the date, her location, and the circumstances of her hospitalization. She was able to follow complex commands without difficulty, and spoke in sentences fluently without paraphasic errors or other deficits; her repetition was also intact. She knew her left from her right, and correctly identified the examiner's left from his right. She could name her fingers. Examination of her cranial nerves revealed no deficits. On motor examination, she was thin, and had a faint high frequency fine tremor in her hands and fingers when her arms were extended in front of her at 90°. Her tone was normal. She had full strength throughout. Minimal endpoint ataxia was noted on finger-to-nose testing in both hands, and with heel-to-shin testing in her feet. There was a decrease to fine touch, temperature, vibration, and pinprick in her feet and ankles, extending to several inches above her ankles in both lower extremities. Her reflexes bilaterally were 3+ at the biceps, brachioradialis, patella, and at the Achilles tendon. Her stance was slightly wide, and her walking was cautious but without an obvious deficit.

Testing of praxis, graphesthesia, writing, and stereognosis were conducted during the 26th day of the patient's hospitalization after her cognitive status had significantly improved. Her performance was videotaped by T.K and scored by T.K and K.M.H. Permission for videotaping was obtained via Tampa General Hospital Standard Medical Media Consent for Education and Research. When testing her for graphesthesia, her left hand was tested first. With this woman's eyes closed, the examiner wrote eight different numbers on each the patient's palms, and she was asked to identify each number after it was written. She identified all numbers correctly. The examiner also placed the following objects in the patient's hand, while her eyes were closed, and asked her to identify them: pencil, bottle cap, paper clip, credit card, scissors, screw,

and a size AAA battery. Both hands were used in random order. She identified each item correctly in both hands.

Writing was tested by asking the patient to write her name and the numbers 4, 8, 65, 792 with her left and right hands. She was also asked to write the sentence "Today is a beautiful day" with her right hand and the sentence "I am going home today" with her left hand. The patient's handwriting sample is shown in Figure 4. Prior to writing with her left hand, she placed the paper at an angle such that the right top corner of the paper was higher than the left. There was a large difference between her writing performance with her right and left hands. Whereas, for the most part the words, numbers, and letters written with the right hand can be recognized, only a few letters and numbers written with the left are legible. It is also apparent that with her left hand she repeatedly attempted to correct her errors.

To learn if this patient, who appeared to have a splenic lesion had hemialexia, the patient was also asked to read a set of 16 compound words, for example "doghouse" and "keyboard," which were presented to her at eye level, in her midline, and at about 2 feet away from her eyes. She read all correctly. She was also asked to spell her name and several words, which she performed correctly. She was also able to recognize words spelled aloud by the examiner.

LKA was tested in both her right and left hands by having her perform a coin rotation (Hanna-Pladdy, Mendoza, Apostolos, & Heilman, 2002), using the method described by Falchook (2015) and Hill et al., (2010) (Falchook et al., 2015; Hill et al., 2010). She was first shown how to rotate a nickel between her thumb, forefinger, and middle finger, and was asked to rotate this coin as rapidly as possible for 10 s. Each hand was tested five times. The score was the number of 180-degree rotation of the nickel in 10 s. With her left hand, she rotated the nickel to an average of 7.4 times (trials: 6,7,8,8 rotations), and with her right hand to an average of 6.4 rotations (trials: 4,10,7,5,7). She dropped the nickel once during the fourth trial. Standardized data using a U.S. quarter shows that during a 10-s period the dominant hand performs an average of 13 rotations and the nondominant hand too has an average of about 12 rotations (Hill et al., 2010). Therefore, this patient's performance on this task was somewhat impaired, suggesting that she has an LKA of her right and left hands.




Figure 4. The patient's handwriting sample. The patient's name is blocked in the handwriting sample of both hands.

[To view this figure in color, please see the online version of this journal.]

IMA was tested by using the Apraxia Screen of TULIA (AST) (Vanbellingen et al., 2011, 2010). In addition to the test items on the AST, the patient was also asked to make believe to pantomime the movements made when she was scrambling eggs and slicing a loaf of bread with a knife using her left and right hand. She was also asked to imitate pantomimes performed by the examiner, who performed the actions described in the TULIA screen and the two additional actions mentioned above.

The patient did not have IMA; she was able to correctly pantomime to command and imitate the use of a hammer, a knife, a toothbrush, and a whisk along with correctly doing the remainder of tasks in the AST. However, when pantomiming how to use a pair of scissors, as if she was holding them in her hand, to cut a piece of paper, she briefly held her index and middle finger as if they were the blades of the scissors, and made a cutting motion with her fingers. She made this error with her left and her right hand until eventually changing the position of her hand to resemble a correct position for holding a pair of scissors. However, healthy participants often initially make this body part as object error, until corrected (Raymer, Maher, Foundas, Heilman, & Rothi, 1997).

To test for conceptual apraxia, the patient was shown pictures of four uncompleted tasks (e.g., a screw is half way screwed into a piece of wood), and was also shown several pictures of different tools, one of which is the correct tool (screwdriver) and was asked to pick the correct tool to complete the job. She was also asked to pick the tool to complete tasks that were verbally described to her. She performed these tasks without errors.

The patient was examined by T.K. again, approximately 1 year after she was initially evaluated by him. This follow-up examination was again videotaped, and was afterward reviewed by T.K. and K.M.H. She was oriented to her herself, the date, her location, and circumstance. She correctly followed three step commands, could normally repeat sentences, and had fluent speech without paraphasic errors. Her recent and remote memory was intact, and she could recall two of three words after a 5-min delay. Her cranial nerve examination was normal. She had no tremor of her hands or fingers at rest or when extended outward at 90° from her torso. Her strength was intact in her fingers and wrists, as well as the remainder of her upper limbs. No ataxia or dysmetria was noted with finger-to-nose testing. Sensation was intact to fine touch pinprick, vibration, and temperature in both of her upper limbs.

LKA was again tested with the coin rotation test, as described above. With the right hand, she had an average of 8.2 rotations in 10 s (trials: 6,7,9,9,10), and with the left hand an average of 8.4 rotations (7,9,8,10,8). In addition, repeated testing again revealed that she did not have an IMA.

Her ability to write with the right and left hands was again tested, but in a more comprehensive manner. Spontaneous writing with her left hand was tested by presenting her with the “cookie theft” picture from the Boston Diagnostic Aphasia Examination and asking her to write a sentence about what she sees (Roth, 2011). Spontaneous writing with her right hand was assessed by showing her the “picnic scene” picture from the Western Aphasia Battery and asking her to write a sentence about what she sees (Kertesz, 1982). As she verbally explained, with the left hand she intended to write “A family is doing dishes and mom made a mess” and with the right hand she

wrote, “A Family is picnicking + Flying Kites with the Family dog.” The writing with the left hand, for the most part, is totally illegible, with impaired production of spatial features of the letters. Her writing with her right hand was legible. Several words were incorrectly capitalized, and she wrote using a combination of print and cursive letters. She used the plus sign, +, instead of the word “and” when writing with both hands.

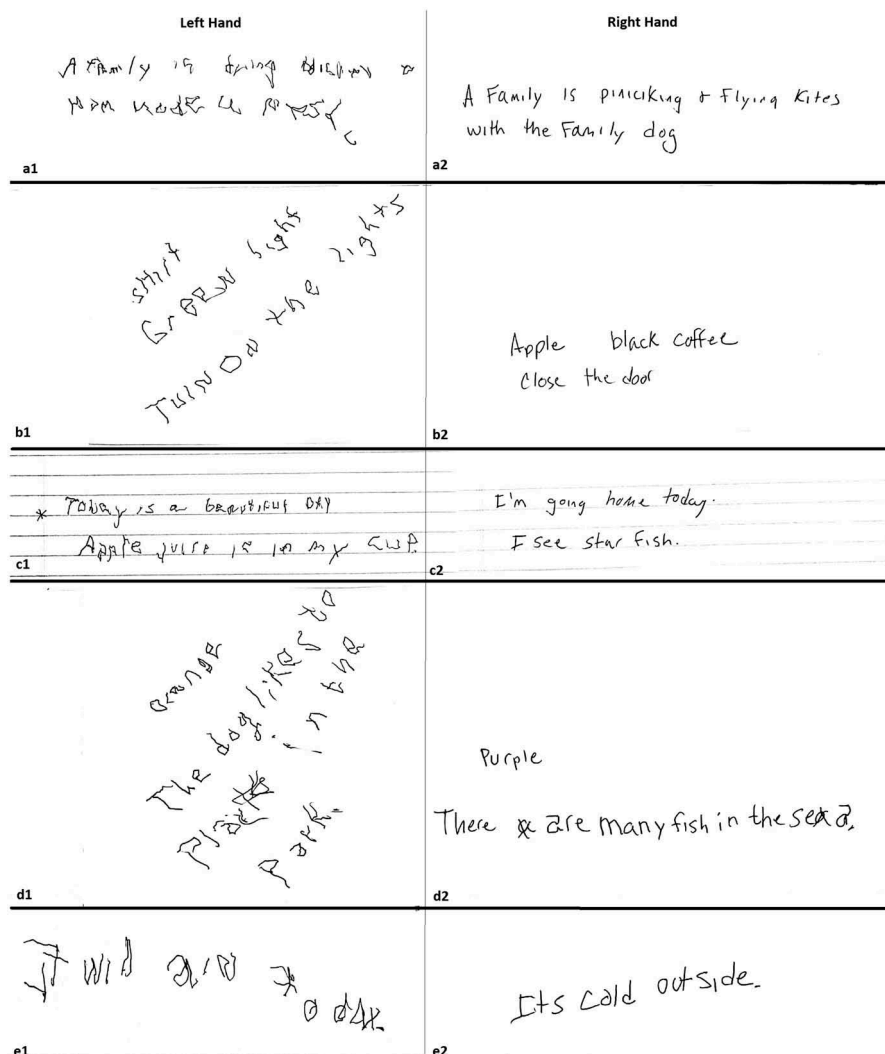
She was also asked to write to dictation with the right hand the word “apple”, the phrase “black coffee,” and the sentence “Close the door.” She was asked to write with her left hand the word “shirt” the phrase “green light,” and the sentence “Turn on the lights.” During this writing to dictation task, she again revealed impaired grapheme production when writing with her left hand. Although severely impaired, the left hand writing to dictation appears to be less impaired than her spontaneous writing (Figure 5).

Spatial agraphia is characterized by an impairment of visuospatial skills. For example, patients with spatial agraphia might write only on one side of a paper. They might be impaired in writing horizontally in respect to the top and bottom edges of the paper and the might improperly space their letters or words (Ullrich & Roeltgen, 2012). When our patient attempted to write with her left hand (Figure 4) as she moved her hand across the page from left to right, her writing progressively moved upward, toward the top of the page. Thus, it appears that in addition to the apraxia agraphia of her left hand, she also had a form of spatial agraphia with her left hand.

She was asked to write with her left hand on paper that had horizontal lines (Figure 5(e,f)) (Ullrich & Roeltgen, 2012), “Today is a beautiful day.” and with her right hand she was asked to write, “I’m going home today. She was also asked to write any sentence she wishes with each hand on the lined paper. With her left hand she attempted to write “Apple juice is in my cup.” and with her right hand she wrote “I see star fish.” When writing with her left hand she continued to make errors in the constructions of graphemes (apraxic agraphia). However, her attempted writing was now horizontal, and there were no obvious inappropriate insertions of blank spaces between graphemes. The writing with her right hand on these horizontal lines remained horizontal. On the examination 1 year after, she also positioned the paper at an angle prior to writing with her left hand on several trials (Figure 5), and while writing, there did not appear to be any sloping upward.

To evaluate her ability to copy written material, she was asked to copy a word with each hand presented to her from 1 foot away in 14 point type, as well as a sentence presented to her from 6 feet away in 50 point type. With the left hand, she was asked to copy the word “orange” and the sentence, “The dog likes to play in the park.” With her right hand, she was asked to copy the word “purple” and the sentence, “There are many fish in the sea.” Although copying with her left hand is impaired, her copying with her left hand is more legible than her spontaneous writing with her left hand. In addition, when copying with her right hand, she twice crossed out the letter “a” that she initially wrote in cursive and replaced these cursive letters with a copy of the letter “a” as it appeared on the typed paper.

She was able to spell the words “pen, foot, finger, computer” aloud without any errors. She was also able to type, without errors, on a wireless computer keyboard “television”



**Figure 5.** a1. The patient was shown the 'cookie theft' picture from the Boston Diagnostic Aphasia manual, and asked to write a sentence about what she sees with her left hand. a2: She was shown the 'Picnic scene' picture from Western Aphasia Battery and asked to write a sentence about what she sees with her right hand. b1: The patient was asked to write down the word or phrase the examiner said with her left hand, and dictated the following: "shirt; green light; turn on the lights". b2: The patient was asked to write on paper with horizontal lines; with her left hand she was asked to write the sentence "today is a beautiful day" and also any sentence she would choose; she wrote "Apple juice is in my cup." c2: she was asked to write the sentence "I'm going home today" and another sentence of her choosing with the right hand on paper with horizontal lines; she wrote "I see star fish." d1: She was asked to copy the word "orange" which was presented one foot away from her eyes and was typed in 14 point font with the left hand. Also with the left she was asked to copy the sentence "The dog likes to play in the park" which was presented to her from six feet away typed in 50 point font. d2, similar to d1 she was asked to copy with the right hand "purple" presented one foot away typed in 14 point font, and the sentence "There are many fish in the sea" presented to her from six feet away typed in 50 point font. e1: The patient was asked to close her eyes and write the sentence "It will rain today" with the left hand. e2: She was asked to close her eyes and write the sentence "It is cold outside."

and "nice to meet you" with her left hand and "camera" and "I want to go home" with her right hand.

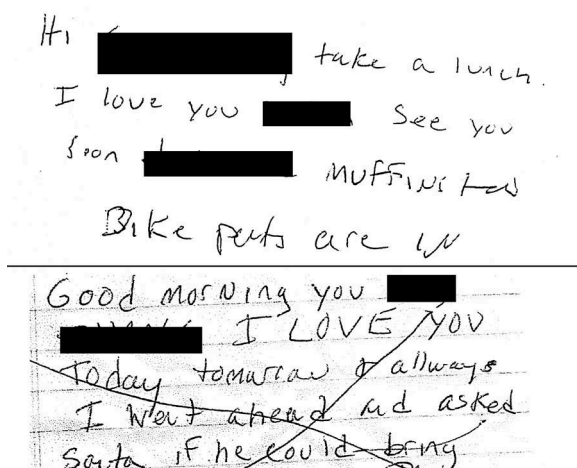
We examined several examples of our patient's handwriting with the right hand from the year prior to her hospitalization (Figure 6). She did not have any examples of her handwriting with her left hand from prior to her hospitalization. Her writing with the right hand prior to her hospitalization appears to be similar to the writing with the right hand tested 1 year after her hospitalization.

## Discussion

This right-handed woman with Type B MB disease who on brain imaging revealed damage to the genu and the splenium

of her corpus callosum revealed an apraxic agraphia of her left but not her right hand. She produced poorly formed graphemes, and demonstrated an inability to make accurately sequenced motions to form these graphemes. She demonstrated apraxic agraphia with her left hand when writing spontaneously, to dictation, when copying, when writing on a horizontal line, as well as when writing with her eyes closed. There does not appear to be a significant difference in her writing ability with nouns compared to verbs. She was able to type and spell aloud without any impairment; she had no evidence for a linguistic agraphia.

She appeared to perform slightly better when copying text with her left hand compared to writing to dictation, and even better when compared to spontaneously writing with her left



**Figure 6.** Handwriting samples of the right hand from prior her presentation with MB disease.

hand. People can copy written languages, such as Arabic or Hebrew, without knowledge of the shape of the graphemes in these languages or the knowledge of how to program the movements need to make these graphemes. Copying, in some respects would be more like drawing than writing, and this improvement in writing with copying has been shown in prior reports of patients with apraxic agraphia (Valenstein & Heilman, 1979).

She had intact graphesthesia and stereognosis of both hands and did not have an IMA of either hand. She was able to correctly read compound words, spell, and type. Although our patient appeared to have some evidence of an LKA initially, it was her right hand performance that was poorer than her left hand, but she had apraxic agraphia only of her left hand suggesting that her apraxic agraphia could not be attributed to an LKA. In addition, on the follow-up examination, both of her hands performed equally on the coin rotation task, and there was no tremor noted with this task. She did have intermittent tremor with her left hand when writing, but not during other portions of her examination. This tremor was not present during all parts of her left hand writing examination, and therefore, it does not appear to have contributed to her impaired construction of written graphemes.

Margolin and Binder (1984) described a left-handed man who had an extensive right hemisphere stroke and in addition to an apraxic agraphia also revealed spatial agraphia. On our patient's initial evaluation, when attempting to write with her left hand, this patient demonstrated aberrant spatial orientation of her writing on the paper, but she did not demonstrate this spatial agraphia when writing with her right hand. As mentioned, on the initial examination of her handwriting with the left hand, prior to writing she placed the paper at an angle, with the top of the paper placed rightward, in respect to her body and her writing sloped upwards. On the examination 1 year after, she also positioned the paper at an angle prior to writing with her left hand on several trials (Figure 5); however, while writing, there did not appear to be any upward sloping. This dissociation suggests that it was not the placement of the paper that induced her spatial agraphia with upward sloping. When providing horizontal lines on the paper, the patient did not show this upward

sloping of her writing, suggesting that this upward deviation may have been related to inattention. When writing with her left hand perhaps she did not attend to the edges of the paper. Her failure to attend to the edges of the paper might be related to her difficulty in writing with her left hand. As she is aware of her impairment, perhaps she increases the focus of her attention to the actions performed by her left hand and this increase in focused attention led to a decrease in global attention with unawareness of the paper's edges. This hypothesis, however, cannot explain why she deviated upward and further research is essential to learn if there are hand-hemispheric up-down action biases.

Several reports of agraphia of the left hand in the absence of aphasia have been described. For example, Liepmann and Maas (1907) described a patient who developed left upper limb IMA as well as agraphia with the left hand, and on postmortem examination was found to have a lesion in the anterior four fifths of the corpus callosum. These authors postulated that this lesion disconnected the left hemisphere mediated movement formulas from the right hemisphere's motor control of the left arm, hand, and fingers (Liepmann & Maas, 1907). However, Liepmann and Maas's patient also had a left frontal lesion and his right arm was hemiparetic and thus could not be tested to learn if this was a callosal disconnection apraxia. There have been several other similar reports of left hand apraxia and agraphia with a callosal lesion (Dejerine & Andre-Thomas, 1912; Geschwind & Kaplan, 1962). Unfortunately, the agraphia in these cases was not fully described, and thus it is unclear if the agraphia was apraxic or linguistic. The patient with a callosal disconnection described by Watson and Heilman (1983), however, did reveal an IMA and apraxic agraphia of her left upper limb (Watson & Heilman, 1983). Different from the case reported by Watson and Heilman whose callosal lesion injured most of the anterior two-thirds of her corpus callosum, the woman described in this report had her lesions restricted to the genu and splenium of the corpus callosum and had an apraxic agraphia in the absence of an IMA.

Heilman and colleagues (1973) described a left-handed man who had used his right hand for writing and who had a lesion in the right hemisphere of his brain with a left hemiplegia. He had preserved language, but did reveal an IMA and LKA of the left hand, as well as a left hand agraphia with preserved spelling (Heilman et al., 1973). The authors posited that although this left-handed man used his right arm and hand for writing, his right hemisphere was dominant for motor programming and the lesion in this hemisphere damaged or disconnected these motor programs from the intact left hemisphere. The following year they described a right-handed man who had a stroke of his left hemisphere. He had a right hemiparesis and an IMA. In spite of having intact speech, he had inability to write with his left hand (Heilman et al., 1974). This patient had preserved ability to spell, and his agraphia was somewhat improved when copying letters (1974). Imaging confirmed a left MCA territory infarction. As in their paper published the prior year, the authors again argued that the lesion destroyed the movement representation important in programming the production of written letters and words, an apraxic agraphia. Later Valenstein and Heilman described



another patient who was left handed and developed a lesion in the right parietal lobe who had agraphia as well as apraxia, but not aphasia. His spelling and his ability to correctly type words when using a typewriter were intact (Valenstein & Heilman, 1979).

Prior research on patients with IMA suggests that the supramarginal gyrus contains the spatial-temporal representation for transitive and intransitive movements and lesions of this area cause IMA (Heilman & Rothi, 2012). However, these spatial-temporal representations have to be transcoded into movement programs. Moreover, the convexity premotor cortex, as well as the supplementary area, appears to be important in converting the spatial representations of transitive and intransitive movements, stored in the left inferior parietal lobe, into motor programs. Therefore, lesions in the premotor cortex or the connecting fasciculi can also cause an IMA. As discussed above, apraxic agraphia can occur in the absence of IMA, and IMA can occur in the absence of apraxic agraphia. This dissociation provides evidence that these two movement programming networks are, at least in part, independent. However, these two networks may have a similar organization.

Pure apraxic agraphia has been reported with injury to the parietal lobe graphemic area (Ullrich & Roeltgen, 2012). Support for the postulate that this area stores the spatial grapheme representations used to program motor-writing patterns of letters comes from observation that with damage to this area writing with the hand and fingers is impaired, but writing using a typewriter or anagram letters is preserved. In addition, with injury to this area there is defective letter imagery (Crary & Heilman, 1988). Like the other purposeful movements mentioned above, the spatial-temporal representations of letter and words have to be transcoded into movement programs. In 1881, Sigmund Exner described an area in the left middle frontal gyrus that he thought plays a critical role in writing. He called this area the “graphic motor image center” (Exner, 1881). Cortical electrical stimulation of this area produces impairment in handwriting without interfering with other hand movements, and functional MRI has shown activation of the left Brodmann’s Area (BA) 6 with handwriting (Roux et al., 2009). Furthermore, fMRI has revealed that Exner’s area, or the graphemic/motor frontal area, appears to be the only one of several areas thought to play a role in writing (Planton, Longcamp, Péran, Démonet, & Jucla, 2017). Thus, it appears that this graphemic/motor frontal area is provided with the spatial-temporal information about the structure of letters from the left parietal lobe, and this frontal area converts these representations into motor programs that sequentially activate the specific areas of the motor cortex important for making the movements required for written letter production. Therefore, with damage to this area patients have been reported to have an inability to write but have preserved ability to correctly spell words (Keller & Meister, 2014). Although these patients had a greater impairment when writing with her left than right hand, this patient did exhibit some deficits when writing with her right hand. There are alterations in graphic strokes as well as changes in letter size and a mix of print and cursive components in both the

patient’s original and follow-up hand writing samples. These errors, however, were present in the sample of writing performed prior her hospitalization and therefore were not likely the result of MB disease.

The midbody of the corpus callosum transmits the motor programming information from the left hemisphere to the right hemisphere that is important for making transitive and intransitive movements of the left upper limb (Acosta et al., 2014). However, when writing with left upper limb, the letter movement programs stored in Exner’s area of the left hemisphere are probably transmitted through the genu of the corpus callosum. Therefore, this woman’s injury to the genu of the corpus callosum may have been responsible for the agraphic apraxia of her left upper limb. However, additional studies are essential to further test this hypothesis.

## Disclosure statement

No potential conflict of interest was reported by the authors.

## References

- Acosta, L. M., Bennett, J. A., & Heilman, K. M. (2014). Callosal disconnection and limb-kinetic apraxia. *Neurocase*, 20(6), 599–605. doi:10.1080/13554794.2013.826683
- Coslett, H. B., Gonzales Rothi, L. J., Valenstein, E., & Heilman, K. M. (1986). Dissociations of writing and praxis: Two cases in point. *Brain and Language*, 28(2), 357–369. doi:10.1016/0093-934X(86)90111-2
- Crary, M. A., & Heilman, K. M. (1988). Letter imagery deficits in a case of pure apraxic agraphia. *Brain and Language*, 34(1), 147–156. doi:10.1016/0093-934X(88)90128-9
- Dejerine, J., & Andre-Thomas, J. (1912). Contribution a l’etude de l’aphasie chez les gauchers. *Revue Neurologique*, 24, 213–226.
- Delangre, T., Hannequin, D., Clavier, E., Denis, P., Mihout, B., & Samson, M. (1986). [Marchiafava-Bignami disease with favorable development]. *Revue Neurologique*, 142(12), 933–936.
- Exner, S. (1881). *Untersuchungen über die Lokalisation der Funktionen in der Großhirnrinde des Menschen*. Vienna: Wilhelm Braunmüller.
- Falchook, A. D., Porges, E. C., Nadeau, S. E., Leon, S. A., Williamson, J. B., & Heilman, K. M. (2015). Cognitive-motor dysfunction after severe traumatic brain injury: a cerebral interhemispheric disconnection syndrome. *Journal Of Clinical And Experimental Neuropsychology*, 37(10), 1062–73. doi:10.1080/13803395.2015.1077930
- Falchook, A. D., Porges, E. C., Nadeau, S. E., Leon, S. A., Williamson, J. B., & Heilman, K. M. (2015). Cognitive-motor dysfunction after severe traumatic brain injury: A cerebral interhemispheric disconnection syndrome. *Journal of Clinical and Experimental Neuropsychology*, 37(10), 1062–1073. doi:10.1080/13803395.2015.1077930
- Falchook, A. D., Watson, R. T., & Heilman, K. M. (2016). Callosal apraxia: A 34-year follow-up study. *Neurocase*, 22(3), 306–311. doi:10.1080/13554794.2016.1148743
- Geschwind, N., & Kaplan, E. (1962). A human cerebral disconnection syndrome: A preliminary report. *Neurology*, 12, 675. doi:10.1212/WNL.12.10.675
- Goodglass, H., & Kaplan, E. (1963). Disturbance of gesture and pantomime in aphasia. *Brain : A Journal of Neurology*, 86, 703–720. doi:10.1093/brain/86.4.703
- Graff-Radford, N. R., Welsh, K., & Godersky, J. (1987). Callosal apraxia. *Neurology*, 37(1), 100–105. doi:10.1212/WNL.37.1.100
- Hanna-Pladdy, B., Mendoza, J. E., Apostolos, G. T., & Heilman, K. M. (2002). Lateralised motor control: Hemispheric damage and the loss of deftness. *Journal of Neurology, Neurosurgery, and Psychiatry*, 73(5), 574–577. doi:10.1136/jnnp.73.5.574
- Heilman, K. M., Coyle, J. M., Gonyea, E. F., & Geschwind, N. (1973). Apraxia and agraphia in a left-hander. *Brain : A Journal of Neurology*, 96(1), 21–28. doi:10.1093/brain/96.1.21

- Heilman, K. M., Gonyea, E. F., & Geschwind, N. (1974). Apraxia and agraphia in a right-hander. *Cortex; a Journal Devoted to the Study of the Nervous System and Behavior*, 10(3), 284–288. doi:10.1016/S0010-9452(74)80021-3
- Heilman, K. M., & Rothi, L. (2012). Apraxia. In: K. Heilman & E. Valenstein (Eds.), *Clinical Neuropsychology* (5th ed., pp. 214–236). New York: Oxford University Press.
- Heilman, K.M., & Watson, R. (2008). The disconnection apraxias. *Cortex*, 44(8), 975–982. doi:10.1016/j.cortex.2007.10.010
- Heinrich, A., Runge, U., & Khaw, A. (2004). Clinicoradiologic subtypes of Marchiafava-Bignami disease. *Journal of Neurology*, 251(9), 1050–1059. doi:10.1007/s00415-004-0566-1
- Hill, B. D., Barkemeyer, C. A., Jones, G. N., Santa Maria, M. P., Minor, K. S., & Brownlydyke, J. N. (2010). Validation of the coin rotation test. *The Neurologist*, 16(4), 249–253. doi:10.1097/NRL.0b013e3181b1d5b0
- Keller, C., & Meister, I. G. (2014). Agraphia caused by an infarction in Exner's area. *Journal of Clinical Neuroscience*, 21(1), 172–173. doi:10.1016/j.jocn.2013.01.014
- Kertesz, A. (1982). *The Western aphasia battery*. New York: Grune & Stratton.
- Kleist, K. (1934). *Gehirnpathologie*. Leipzig: Barth.
- Lakatos, A., Kosta, P., Konitsiotis, S., Zikou, A. K., Astrakas, L. G., & Argyropoulou, M. I. (2014). Marchiafava-Bignami disease: An acquired callosotomy. *Neurology*, 83(13), 1219. doi:10.1212/WNL.0000000000000811
- Liepmann, H. (1905). Die linke Hemisphere und das Handeln. *Munchner Medizinische Wochenschrift*, 49, 2235–2375.
- Liepmann, H. (1920). Apraxia. *Ergebnisse Der Gesamten Medizin*, 1, 516–543.
- Liepmann, H., & Maas, O. (1907). Fall von linksseitiger Agraphie und Apraxie bei rechtsseitiger Lahmung. *Zeitschrift Fur Psychologie Und Neurologie*, 10, 214–227.
- Logan, C., Asadi, H., Kok, H. K., Looby, S. T., Brennan, P., O'Hare, A., & Thornton, J. (2016). Neuroimaging of chronic alcohol misuse. *Journal of Medical Imaging and Radiation Oncology* 61(4), 435–440.
- Marchiafava, E., & Bignami, A. (1903). Sopra un alterazione del corpo calloso osservata in soggetti alcoolisti. *Rivista Di Patologia Nervosa E*, 8, 544.
- Margolin, D. I., & Binder, L. (1984, May). Multiple component agraphia in a patient with atypical cerebral dominance: An error analysis. *Brain and Language*, 22(1), 26–40. doi:10.1016/0093-934X(84)90077-4
- Planton, S., Longcamp, M., Péran, P., Démonet, J.-F., & Jucla, M. (2017). How specialized are writing-specific brain regions? An fMRI study of writing, drawing and oral spelling. *Cortex*, 88, 66–80. doi:10.1016/j.cortex.2016.11.018
- Poizner, H., Mack, L., Verfaellie, M., Rothi, L. J., & Heilman, K. M. (1990). Three-dimensional computergraphic analysis of apraxia. Neural representations of learned movement. *Brain : A Journal of Neurology*, 113, 85–101. doi:10.1093/brain/113.1.85
- Raymer, A. M., Maher, L. M., Foundas, A. L., Heilman, K. M., & Rothi, L. J. (1997). The significance of body part as tool errors in limb apraxia. *Brain and Cognition*, 34(2), 287–292. doi:10.1006/brcg.1997.0919
- Roeltgen, D. P., & Heilman, K. M. (1983). Apractic agraphia in a patient with normal praxis. *Brain and Language*, 18(1), 35–46. doi:10.1016/0093-934X(83)90004-4
- Rothi, C. (2011). Boston diagnostic Aphasia examination. In J. S. Kreutzer, J. DeLuca, & B. Caplan (Eds.), *Encyclopedia of clinical neuropsychology* (pp. 428–430). New York, NY: Springer New York.
- Rothi, L. J. G., Mack, L., Verfaellie, M., Brown, P., & Heilman, K. M. (1988). Ideomotor apraxia: Error pattern analysis. *Aphasiology*, 2(3/4), 281–287.
- Roux, F.-E., Dufor, O., Giussani, C., Wamain, Y., Draper, L., Longcamp, M., & Démonet, J.-F. (2009). The graphemic/motor frontal area Exner's area revisited. *Annals of Neurology*, 66(4), 537–545. doi:10.1002/ana.21804
- Steinthal, P. (1871). *Abriss der Sprachwissenschaft*. Berlin: Ferdinand Dummler.
- Ullrich, L., & Roeltgen, D. P. (2012). Agraphia. In K. M. Heilman & E. Valenstein (Eds.), *Clinical Neuropsychology* (5th ed., pp. 130–151). New York: Oxford University Press.
- Valenstein, E., & Heilman, K. M. (1979). Apraxic agraphia with neglect-induced paraphasia. *Archives of Neurology*, 36(8), 506–508. doi:10.1001/archneur.1979.00500440076016
- Vanbellingen, T., Kersten, B., Van de Winkel, A., Bellion, M., Baronti, F., Muri, R., & Bohlhalter, S. (2011). A new bedside test of gestures in stroke: The apraxia screen of TULIA (AST). *Journal of Neurology, Neurosurgery & Psychiatry*, 82(4), 389–392. doi:10.1136/jnnp.2010.213371
- Vanbellingen, T., Kersten, B., Van Hemelrijk, B., Van de Winkel, A., Bertschi, M., Müri, R., ... Bohlhalter, S. (2010). Comprehensive assessment of gesture production: A new test of upper limb apraxia (TULIA). *European Journal of Neurology*, 17(1), 59–66. doi:10.1111/j.1468-1331.2009.02741.x
- Verstichel, P., & Meyrignac, C. (2000). [Left unilateral melokinetic apraxia and left dynamic apraxia following partial callosal infarction]. *Revue Neurologique*, 156(3), 274–277.
- Watson, R. T., Fleet, W. S., Gonzalez-Rothi, L., & Heilman, K. M. (1986). Apraxia and the supplementary motor area. *Archives of Neurology*, 43(8), 787–792. doi:10.1001/archneur.1986.00520080035016
- Watson, R. T., & Heilman, K. M. (1983). Callosal apraxia. *Brain : A Journal of Neurology*, 106(Pt 2), 391–403. doi:10.1093/brain/106.2.391