

CASE REPORT

Thrombectomy for late occlusion of high flow extracranial–intracranial saphenous vein bypass graft after 27 years of patency

Michael A Silva, Rodolfo E Alcedo Guardia, Mohammad Ali Aziz-Sultan, Nirav J Patel

Department of Neurosurgery,
Brigham and Women's Hospital,
Harvard Medical School, Boston,
Massachusetts, USA

Correspondence to

Dr. Nirav J Patel,
npatel40@bwh.harvard.edu

Accepted 16 January 2018

SUMMARY

High flow extracranial–intracranial (EC-IC) bypass with a saphenous vein graft (SVG) has been used for more than 40 years in patients with giant aneurysms of the posterior circulation refractory to medical management, and has demonstrated high long term patency rates. We report the case of a patient treated with external carotid artery (ECA)–posterior cerebral artery SVG bypass in 1989 who presented 27 years later with paresthesias and confusion, and was found to have partial occlusion of her SVG bypass graft and a basilar occlusion. She was treated with mechanical thrombectomy of the basilar occlusion via the partially thrombosed graft, the first report of such a procedure through a high flow posterior circulation EC-IC SVG, resulting in improvement of the patient's neurologic examination. At 27 years, this is the longest reported delay in thrombosis of a high flow SVG bypass graft, highlighting the long term patency of these grafts and the feasibility of thrombectomy through occluded bypass grafts.

BACKGROUND

High flow extracranial–intracranial (EC-IC) bypass is a treatment option for patients with giant aneurysms or advanced occlusive disease of the posterior circulation refractory to medical management. Without intervention, these patients have a high risk of recurrent stroke, severe disability, and death, and medical management is not sufficient for many patients.¹ Since its introduction four decades ago, EC-IC bypass has been an important treatment modality for patients with severe posterior circulation disease who have failed medical therapy.²

We report the case of a patient with a history of external carotid artery (ECA) to posterior cerebral artery (PCA) bypass via saphenous vein bypass graft (SVG) performed by Dr. Sundt, the pioneer of high flow EC-IC bypass, that thrombosed 27 years after the initial procedure, on whom we performed a mechanical thrombectomy with good clinical results. To the best of the authors' knowledge, this is the longest period of patency reported before occlusion of a high flow EC-IC SVG graft, and it is the first reported mechanical thrombectomy through a thrombosed EC-IC bypass graft.

CASE PRESENTATION

A 46-year-old woman who had undergone Hunterian ligation of a giant basilar aneurysm and right ECA to

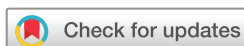right PCA bypass with a SVG in 1989 presented with left sided paresthesias and confusion. She had a past medical history notable for myasthenia gravis, seizure disorder, Sjogren's syndrome, lupus, migraines with visual aura, and a stroke in 2006, which was presumed to be embolic from her SVG and placed on warfarin. On the day of presentation, she was last seen well at 10:00 am when she developed acute onset numbness and paresthesias on the left side of her face, which subsequently spread to her left arm and leg within seconds. When she attempted to stand, she fell to the ground. Her family found her and noticed that she seemed confused and brought her to the emergency department.

INVESTIGATIONS

On initial exam in the ED, she was found to have a fluctuating gaze impairment consistent with bilateral third nerve palsies and internuclear ophthalmoplegia (INO). GCS was 15. A CTA was performed and revealed absent flow through the ECA-PCA bypass graft and a patent basilar artery ([figure 1A](#)). The stroke team was activated, and no TPA was given because the patient was anticoagulated on warfarin for her prior stroke. An MRI performed on the day after presentation demonstrated a stroke in the right posterior thalamus in the distribution of P1 perforators ([figure 1B](#)). A cerebral angiogram was performed, which demonstrated slow flow through the graft ([figure 1C](#)) and ample collateral circulation to the basilar from the vertebral artery and posterior inferior cerebellar artery (PICA) ([figure 1D](#)). At this time, she had intermittent dysarthria, left upper extremity dysmetria, and left upper and lower extremity pronator drift.

TREATMENT

The patient was continued on warfarin and her INR maintained within therapeutic range, and she had an uneventful clinical course over the next 24 hours. Despite appropriate medical therapy, she developed a significant decline in her neurologic exam notable for worsened weakness, slurred speech, and somnolence, as well as worsening of her pronator drift, prompting repeat angiography and more aggressive intervention. She was taken back to the angiography suite, and a repeat cerebral angiogram via catheterization of the patent graft revealed occlusion at the top of the basilar, as well as occlusion in the distal PCA ([figure 2A](#)). partial occlusion of the SVG and basilar



To cite: Silva MA, Alcedo Guardia RE, Aziz-Sultan MA, et al. *BMJ Case Rep* Published Online First: [please include Day Month Year]. doi:10.1136/bcr-2017-013670

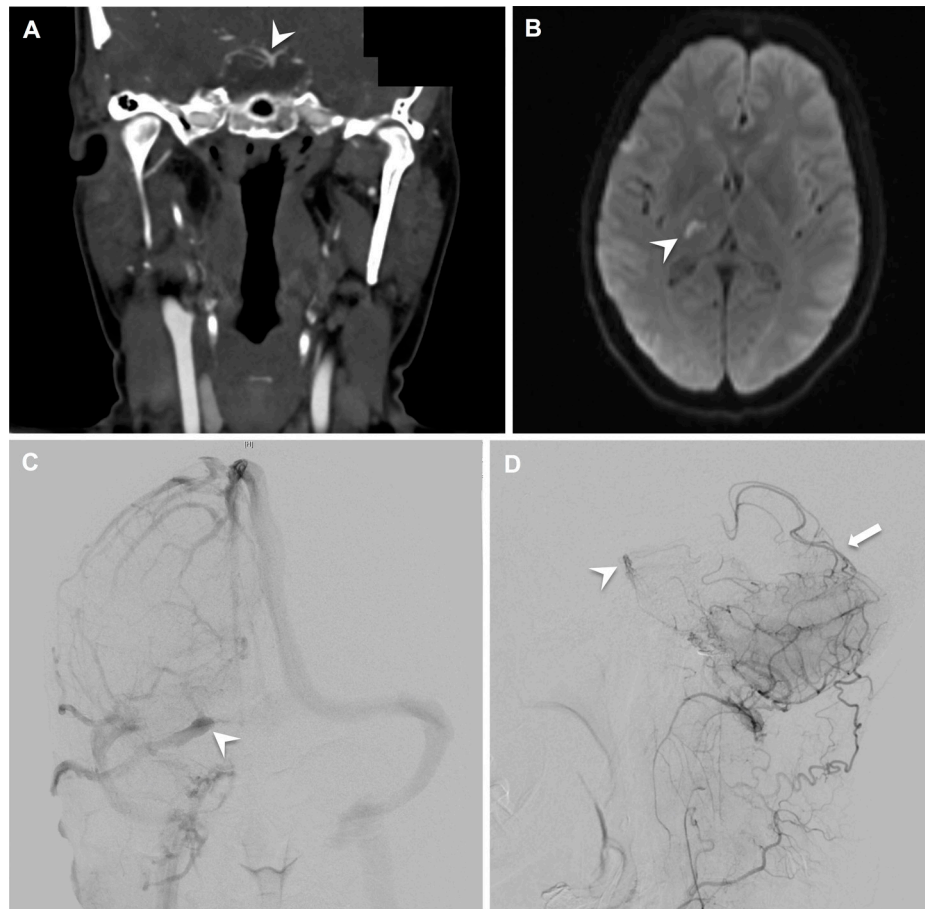


Figure 1 Preoperative imaging. (A) Coronal CT angiography (CTA) taken on presentation to the emergency department demonstrated that the basilar artery and proximal posterior cerebral artery (PCA) were patent (*white arrowhead*). The ECA-PCA graft was not visualised. (B) Axial diffusion-weighted imaging (DWI) revealed a stroke in the right posterior thalamus (*white arrowhead*). (C) Digital subtraction angiography (DSA) showed visualisation of the graft (*white arrowhead*) in the venous phase of the study, demonstrating that the graft was patent but with slow flow. (D) DSA also demonstrated ample collateral perfusion (*white arrow*) of the basilar artery (*white arrowhead*) from vertebral artery and PICA branches.

terminus occlusion. A mechanical thrombectomy was performed via right femoral artery access. A microcatheter was advanced through the SVG and into the right PCA across the basilar terminus clot (*figure 2B*). A Solitaire stent was deployed and, after 5 min, retrieved with minimal interval change in the clot at the basilar terminus. 2 mg of intra-arterial tPA was administered and a second Solitaire stent was then advanced through the clot, deployed,

and retrieved with good revascularisation of the basilar terminus (*figure 2C*). Following thrombectomy, there were no filling defects in the SVG graft (*figure 2C*).

OUTCOME AND FOLLOW-UP

The patient tolerated the procedure well, and her neurologic exam improved in the immediate postoperative period with mild

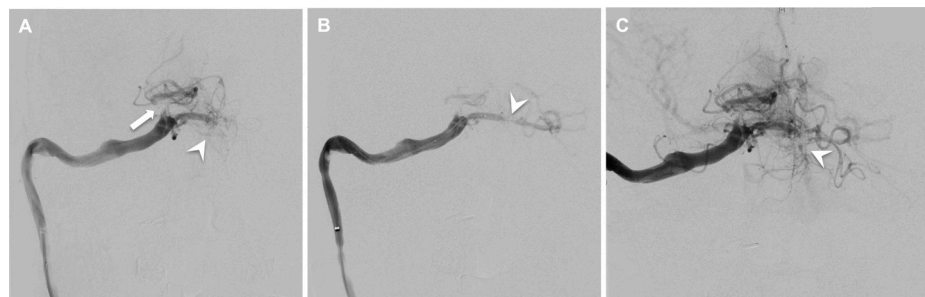

Figure 2 Thrombectomy. (A) Lateral DSA showed that the graft was largely patent, despite slow filling. However, there was absent filling of the basilar artery (*white arrowhead*), as well as occlusion of the more distal PCA (*white arrow*). (B) A Solitaire stent was deployed across the occlusion at the top of the basilar (*white arrowhead*). (C) Lateral DSA after two rounds of mechanical thrombectomy demonstrated flow through the basilar (*white arrowhead*), as well as collateral vessels to the distal PCA. Perfusion of the bilateral superior cerebellar arteries (SCA) is also seen off of the reperfused basilar artery.

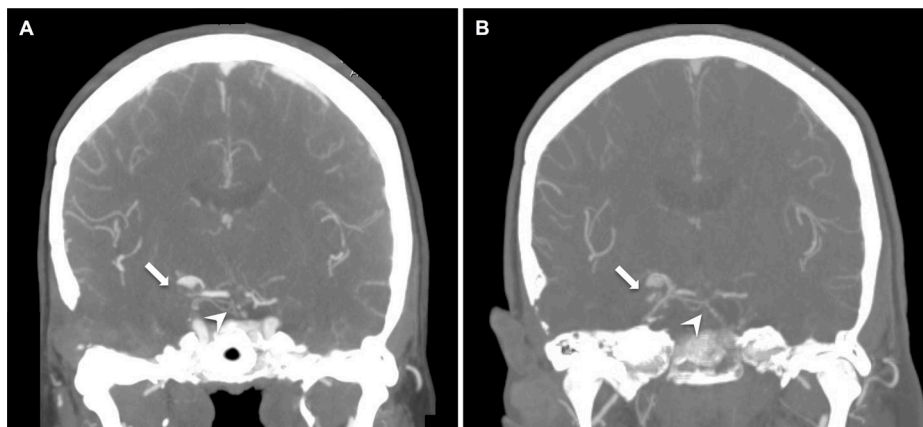


Figure 3 Postoperative imaging. (A) On postoperative day 4, coronal CTA showed flow through the basilar (white arrowhead) but absent filling of the graft (white arrow). (B) At most recent postoperative follow-up (15 months), the basilar artery remained patent while the graft failed to demonstrate flow.

residual pronator drift in the left upper extremity, as well as mild weakness in the left hand and foot, and left perioral hyperesthesias thought to be residual deficits from her right thalamic infarct. A follow-up CTA performed on postoperative day four demonstrated complete nonvisualization of the SVG graft, but improved flow in the basilar artery and right PCA due to collateral circulation (figure 3A). Her neurologic exam remained stably improved at discharge despite the complete graft occlusion. A CTA at postoperative month 15 revealed persistent occlusion of the graft but improved flow through the basilar artery (figure 3B). At most recent clinic follow-up of 15 months, the patient's motor symptoms had nearly resolved completely and she was ambulating with a cane.

DISCUSSION

Giant aneurysms of the posterior circulation present a unique and complex challenge without a clear consensus for optimal management. These aneurysms have a poor natural history, with an 80% rate of mortality or severe disability at 5 years.¹ There are several treatment modalities available to these patients, including Hunterian ligation for aneurysms that cannot be directly clipped. However, successful aneurysm thrombosis is only achieved in 78% of these patients, and bypass is often needed to maintain adequate perfusion.¹ Recently, endovascular intervention with the Pipeline Embolization Device (PED) has been used to treat posterior circulation aneurysms.^{3–5} While technically feasible, successful posterior circulation aneurysm occlusion with PED is achieved in only 57% of patients, and is associated with high mortality.^{4,5}

High flow EC-IC bypass has been used for nearly four decades as therapy for patients with giant aneurysms or severe posterior circulation disease refractory to medical management. Sundt and colleagues demonstrated the feasibility of high flow bypass in the early 1980s using several different conduits, suggesting that the technique may be useful in select patients who are acutely ill and who have failed medical therapy.⁶ They found high rates of patency and symptomatic improvement using SVG bypass for posterior circulation giant aneurysms and advanced occlusive disease.^{2,7} Since Dr. Sundt's initial reports, several series have demonstrated the efficacy of high flow bypass for these pathologies, with long-term patency rates of 82% to 94%^{7–14} and case reports of grafts remaining patent at 10 years,⁸ 11 years,⁹ 13 years,¹³ and 15 years.¹⁰ Although the procedure is rarely used, its utility for select

patients demonstrates that there is still a need for this skillset. In fact, Dr. Sundt, the originator of the technique, performed this patient's initial SVG bypass 27 years prior, and this is the longest published follow-up of a patient of Dr. Sundt's early high flow bypass cohort.

Thrombosis of these grafts, while rare, most often occurs in the immediate postoperative period.^{13,14} A series of 202 high flow SVG bypass procedures from the Mayo Clinic, many of which were performed by Dr. Sundt, found that 76% of all SVG graft failures occurred within 1 year after surgery, including 42% within the first 24 hours, and showed an annual graft failure rate of 1% to 1.5% after the first year.¹³

Late thrombosis is rare, and may remain clinically silent due to the development of collateral circulation, and may go undetected.¹⁵ In the aforementioned Mayo Clinic study, 80% of patients with late graft occlusion had no clinical neurologic evidence of occlusion.¹³

Our patient presented with neurologic deterioration, likely secondary to emboli from the stagnant flow through the failing graft. She improved clinically after thrombectomy of the clot in the basilar artery, which also improved patency of the graft. However, complete occlusion of the graft was demonstrated on subsequent postoperative imaging with no deterioration in her neurologic exam. Her postoperative neurologic improvement was likely the result of revascularisation of the basilar artery after thrombectomy of the basilar clot rather than temporary revascularisation of the graft, which had largely been bypassed over a period of years by ample collateralization that developed as the graft slowly occluded. Revascularisation of the basilar clot perhaps restored perfusion through the posterior circulation sufficiently to diminish the need for flow through the bypass graft, promoting occlusion of the graft seen at discharge. Her neurologic exam remained stably improved at most recent follow-up despite persistent graft thrombosis, suggesting that, in the absence of her basilar occlusion, there was sufficient collateral flow to compensate for the graft thrombosis. It is thought that the development of collaterals as these grafts gradually thrombose compensates for the diminished graft flow and allows graft occlusion to remain clinically silent.¹⁵

To the best of our knowledge, in addition to being the longest reported latency period for SVG thrombosis, this case is the first reported thrombectomy through a high flow EC-IC SVG graft. There is one prior report by Maselli *et al* of delayed

partial SVG thrombosis treated with endovascular stenting, in which the stented SVG remained patent at 36 month follow-up. However, to the best of our knowledge, mechanical thrombectomy through an SVG after delayed thrombosis has not been reported. Although our procedure failed to revascularize the graft beyond the initial postoperative period, it did revascularize the basilar clot, and our experience demonstrates the feasibility of mechanical thrombectomy through a bypass graft for patients with few alternative options. In this patient, the presence of the basilar clot and the contraindications to tPA were sufficient indications for thrombectomy, and the patient improved clinically following the procedure. Giant posterior circulation aneurysms are challenging to treat, and, despite being a highly morbid procedure, high flow EC-IC bypass is a feasible operative approach for severe, medically refractory disease.

Learning points

- The management of giant posterior circulation aneurysms is complex, however, given their poor natural history, operative intervention should be considered in patients refractory to medical management
- High flow EC-IC bypass is rarely employed due to its high morbidity and technical challenge, but it is a safe and effective treatment option for patients with giant posterior circulation aneurysms and has demonstrated high rates of long term patency
- This is the first report of mechanical thrombectomy through a thrombosed SVG bypass graft, and we found it to be a safe and feasible intervention

Contributors MAS analyzed the data, compiled the figures, and drafted and revised the paper. REAG treated the patient in the study, collected and analyzed the data, and revised the manuscript. MAA-S treated the patient and revised the paper. NJP oversaw the study, treated the patient in the study, collected and analyzed the data, compiled the figures, and revised the manuscript.

Competing interests None declared.

Patient consent Obtained.

Provenance and peer review Not commissioned; externally peer reviewed.

Data sharing statement The technical methodology has been disclosed in its entirety within the case report. The representative case images are not relevant for data sharing.

© BMJ Publishing Group Ltd (unless otherwise stated in the text of the article) 2018. All rights reserved. No commercial use is permitted unless otherwise expressly granted.

REFERENCES

- 1 Steinberg GK, Drake CG, Peerless SJ. Deliberate basilar or vertebral artery occlusion in the treatment of intracranial aneurysms. Immediate results and long-term outcome in 201 patients. *J Neurosurg* 1993;79:161–73.
- 2 Sundt TM, Piepgras DG, Houser OW, et al. Interposition saphenous vein grafts for advanced occlusive disease and large aneurysms in the posterior circulation. *J Neurosurg* 1982;56:205–15.
- 3 Natarajan SK, Lin N, Sonig A, et al. The safety of Pipeline flow diversion in fusiform vertebrobasilar aneurysms: a consecutive case series with longer-term follow-up from a single US center. *J Neurosurg* 2016;125:111–9.
- 4 Toth G, Bain M, Hussain MS, et al. Posterior circulation flow diversion: a single-center experience and literature review. *J Neurointerv Surg* 2015;7:574–83.
- 5 Bhogal P, Pérez MA, Ganslandt O, et al. Treatment of posterior circulation non-saccular aneurysms with flow diverters: a single-center experience and review of 56 patients. *J Neurointerv Surg* 2017;9:471–81.
- 6 Sundt TM, Smith HC, Piepgras DG, et al. Bypass and transluminal dilatation procedures for advanced occlusive disease of the posterior circulation. *Neurosurg Rev* 1982;5:65–72.
- 7 Sundt TM, Piepgras DG, Marsh WR, et al. Saphenous vein bypass grafts for giant aneurysms and intracranial occlusive disease. *J Neurosurg* 1986;65:439–50.
- 8 Jafar JJ, Russell SM, Woo HH. Treatment of giant intracranial aneurysms with saphenous vein extracranial-to-intracranial bypass grafting: indications, operative technique, and results in 29 patients. *Neurosurgery* 2002;51:138–46. discussion 44–6.
- 9 Yanagisawa T, Kinouchi H, Sasajima T, et al. Long-Term Follow-Up for a Giant Basilar Trunk Aneurysm Surgically Treated by Proximal Occlusion and External Carotid Artery to Posterior Cerebral Artery Bypass Using a Saphenous Vein Graft. *J Stroke Cerebrovasc Dis* 2016;25:e212–e213.
- 10 Russell SM, Post N, Jafar JJ. Revascularizing the upper basilar circulation with saphenous vein grafts: operative technique and lessons learned. *Surg Neurol* 2006;66:285–97.
- 11 Gobble RM, Hoang H, Jafar J, et al. Extracranial-intracranial bypass: resurrection of a nearly extinct operation. *J Vasc Surg* 2012;56:1303–7.
- 12 Park EK, Ahn JS, Kwon DH, et al. Result of extracranial-intracranial bypass surgery in the treatment of complex intracranial aneurysms : outcomes in 15 cases. *J Korean Neurosurg Soc* 2008;44:228–33.
- 13 Regli L, Piepgras DG, Hansen KK. Late patency of long saphenous vein bypass grafts to the anterior and posterior cerebral circulation. *J Neurosurg* 1995;83:806–11.
- 14 Ramanathan D, Temkin N, Kim LJ, et al. Cerebral bypasses for complex aneurysms and tumors: long-term results and graft management strategies. *Neurosurgery* 2012;70(6):1442–57. discussion 57..
- 15 Matsukawa H, Tanikawa R, Kamiyama H, et al. Graft Occlusion and Graft Size Changes in Complex Internal Carotid Artery Aneurysm Treated by Extracranial to Intracranial Bypass Using High-Flow Grafts with Therapeutic Internal Carotid Artery Occlusion. *Neurosurgery* 2017;81:672–679.

Copyright 2018 BMJ Publishing Group. All rights reserved. For permission to reuse any of this content visit <http://group.bmj.com/group/rights-licensing/permissions>.
BMJ Case Report Fellows may re-use this article for personal use and teaching without any further permission.

Become a Fellow of BMJ Case Reports today and you can:

- Submit as many cases as you like
- Enjoy fast sympathetic peer review and rapid publication of accepted articles
- Access all the published articles
- Re-use any of the published material for personal use and teaching without further permission

For information on Institutional Fellowships contact consortiasales@bmjgroup.com

Visit casereports.bmj.com for more articles like this and to become a Fellow