



Passive accessory joint mobilization in the multimodal management of chronic dysesthesia following thalamic stroke

Kristina Griffin, Michael O'Hearn, Carla C. Franck & Carol A. Courtney

To cite this article: Kristina Griffin, Michael O'Hearn, Carla C. Franck & Carol A. Courtney (2018): Passive accessory joint mobilization in the multimodal management of chronic dysesthesia following thalamic stroke, *Disability and Rehabilitation*, DOI: [10.1080/09638288.2018.1450453](https://doi.org/10.1080/09638288.2018.1450453)

To link to this article: <https://doi.org/10.1080/09638288.2018.1450453>



Published online: 20 Mar 2018.



Submit your article to this journal [↗](#)

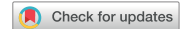

View related articles [↗](#)



View Crossmark data [↗](#)

CASE REPORT



Passive accessory joint mobilization in the multimodal management of chronic dysesthesia following thalamic stroke

Kristina Griffin^{a,b}, Michael O'Hearn^{b,c}, Carla C. Franck^b and Carol A. Courtney^b

^aOutpatient Orthopedics, Shirley Ryan Ability Lab, Chicago, IL, USA; ^bDepartment of Physical Therapy, University of Illinois at Chicago, Chicago, IL, USA; ^cOutpatient Orthopedics, Lakeland Health, St. Joseph, MI, USA

ABSTRACT

Study design: Case Report.

Purpose: Stroke is the most common cause of long-term disability. Dysesthesia, an unpleasant sensory disturbance, is common following thalamic stroke and evidence-based interventions for this impairment are limited. The purpose of this case report was to describe a decrease in dysesthesia following manual therapy intervention in a patient with history of right lacunar thalamic stroke.

Case description: A 66-year-old female presented with tingling and dysesthesia in left hemisensory distribution including left trunk and upper/lower extremities, limiting function. Decreased left shoulder active range of motion, positive sensory symptoms but no sensory loss in light touch was found. She denied pain and moderate shoulder muscular weakness was demonstrated. Laterality testing revealed right/left limb discrimination deficits and neglect-like symptoms were reported. Passive accessory joint motion assessment of glenohumeral and thoracic spine revealed hypomobility and provoked dysesthesia. Interventions included passive oscillatory joint mobilization of glenohumeral joint, thoracic spine, ribs and shoulder strengthening.

Results: After six sessions, shoulder function, active range of motion, strength improved and dysesthesia decreased. Global Rating of Change Scale was +5 and QuickDASH score decreased from 45% to 22% disability. Laterality testing was unchanged.

Conclusion: Manual therapy may be a beneficial intervention in management of thalamic stroke-related dysesthesia.

ARTICLE HISTORY

Received 18 July 2017
Revised 28 February 2018
Accepted 7 March 2018

KEYWORDS

Manual therapy; stroke rehabilitation; somatosensation; quantitative sensory testing; thalamic pain syndrome; central post-stroke pain

► IMPLICATIONS FOR REHABILITATION

- While pain is common following thalamic stroke, patients may present with chronic paresthesia or dysesthesia, often in a hemisensory distribution.
- Passive movement may promote inhibition of hyperexcitable cortical pathways, which may diminish aberrant sensations.
- Passive oscillatory manual therapy may be an effective way to treat sensory disturbances such as paresthesias or dysesthesia.

Introduction

Stroke is a major health issue and a leading cause of long-term disability around the world [1]. Sensory impairment can be as high as 50% to 85% in stroke survivors [2], and is particularly common following a lacunar thalamic stroke, typically resulting in a clear cut division at mid-line with hemisensory distribution [3]. Conventional rehabilitative management of stroke has focused on interventions that promote return to function [4] and motor relearning [5], with significant evidence supporting this approach. However, sensory impairment has been correlated to functional deficits, including decreased balance and movement dysfunction [6,7], as well as longer hospital stays and loss of independence with activities of daily living (ADLs) [1]. While studies have investigated interventions which promote normalization of altered somatosensation [8], these methods for the most part, have not translated into clinical practice [9]. A recent study found that most rehabilitative specialists (97.7%) addressed sensory impairments found in patients following stroke, however, the source of these

management strategies was often advised from a colleague rather than research evidence [10].

Pain and altered somatosensation poststroke may occur due to deafferentation, resulting from damage to the spinothalamocortical pathways [11]. However, other studies have suggested that loss of intracortical inhibition may be the source of dysesthesia [12], which may progress to central poststroke pain [13]. Passive movement may promote inhibition of hyperexcitable cortical pathways. Lewis et al. [14] found that slow passive oscillatory limb movement dampened cortical excitability, and proposed that input from muscle spindle may mediate these effects. Earlier studies have suggested that peripheral sensory input can inhibit central nervous system excitability [15,16], however, the underlying mechanisms of this phenomenon are not fully understood.

Alternatively, passive oscillatory joint mobilization is a standard rehabilitative intervention for painful musculoskeletal conditions. Studies have demonstrated that joint mobilization results in a dampening of nociceptive excitability as measured by the nociceptive reflex [17,18] and it may facilitate descending inhibitory

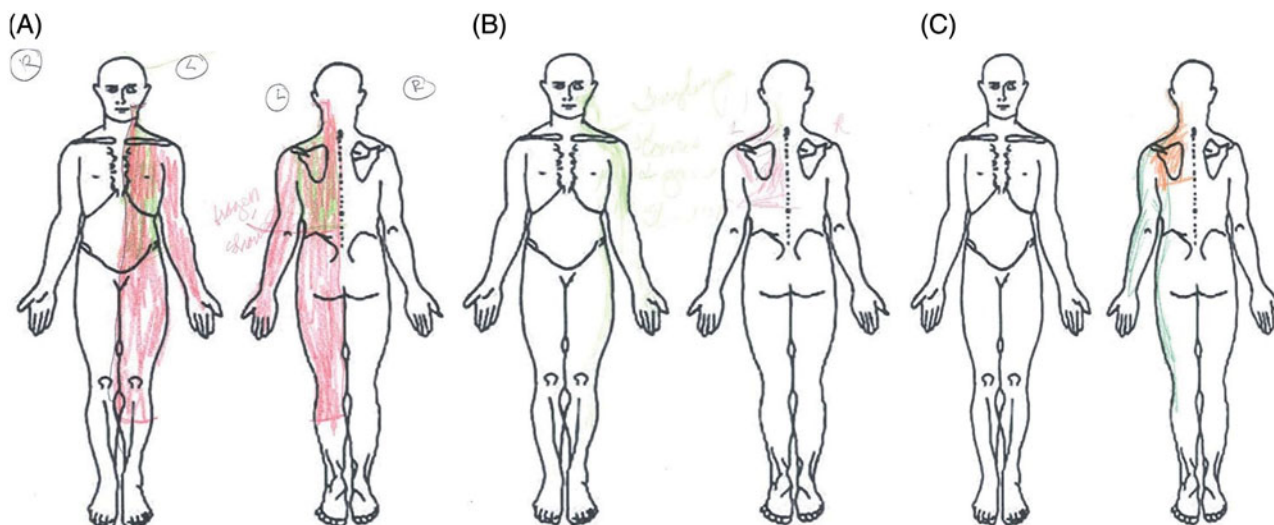


Figure 1. (A)–(C) Symptom diagrams completed by the patient at (A) initial evaluation, (B) visit 3, and (C) visit 6. In (A) red color represents tingling and green color represents the “heavy metal” brace sensation. In (B) the patient chose to draw her tingling in green and metal brace sensation in red. In (C) the patient drew the metal brace sensation in red and the tingling in green.

mechanisms [19]. However, this intervention, commonly used in orthopedic rehabilitation, has not typically been utilized in a neurologic rehabilitation setting. The purpose of this case report was to describe the use of joint mobilization in an individual following a thalamic stroke, with reported hemisensory dysesthesia but no pain. The result was a telescoping, or reduction in the distribution of the persistent sensory symptoms the patient had experienced since her stroke.

Case description

Patient description and history

A 66-year-old female was referred to outpatient physical therapy with a diagnosis of “stroke, left hemiparesis, low back pain with sciatica, left frozen shoulder and thalamic pain syndrome”, however, on initial evaluation, the patient denied any pain. At that first visit, she was 8 months status-post lacunar thalamic stroke. Directly after her stroke, the patient was referred for outpatient physical therapy elsewhere for 8 weeks. Her rehabilitation was focused on gait training, lower extremity functional movement and strength. Physical therapy at that time did not focus on the dysesthesias, which began one week post-stroke. The patient reported she was “unhappy” with this treatment because the arm tingling and metal brace sensation around her trunk were not addressed. The patient reported functional limitations with typing, manipulating objects overhead and making a meal with the left upper extremity. The patient did not receive physical therapy again until she was 8 months post stroke. The patient’s medical history also included type II diabetes and hypertension, placing her at higher risk for the lacunar stroke. Medications included Lyrica (Pregabalin); the dosage and usage of this medication did not change throughout the episode of care.

Examination

While no pain was reported at initial evaluation, she did describe an unpleasant left unilateral tingling of the inferior face, left upper extremity, lower extremity and trunk, both anteriorly and posteriorly was noted. She also described a “metal brace” sensation around the left trunk (Figure 1(A)). Intensity of the tingling sensation was captured using the Numeric Pain Rating Scale (NPRS) [7],

rating tingling rather than pain. Intensity of tingling was rated at 8/10, with 10 signifying the worst tingling imaginable. The dysesthesia worsened shortly after the stroke and had remained unchanged the last several months. Red flag questions were negative, including denial of headaches, diplopia, blurred vision, tinnitus, night pain, stumbling during gait, dizziness, dysarthria or nausea. Along with dysesthesia, the patient reported neglect-like symptoms [20], and described the left lower extremity as feeling tight and heavy.

The patient lived alone, was independent with all ADLs, and received assistance from family members with grocery shopping and errands. Hobbies included reading and typing papers on the computer. Her goals were to reach overhead with the left upper extremity, type at the computer for enjoyment and prepare a meal with ease.

Outcome measures taken at evaluation

The patient completed a symptom diagram (Figure 1(A)). The Quick Disability of the Arm, Shoulder, Hand (QuickDASH) [21] was 45.45% disability, indicating moderate disability. This instrument has been found reliable and valid [21].

Observation

Postural impairments included kyphotic posture throughout the thoracic spine, forward internally rotated shoulders, protracted scapulae and mild forward head posture [22]. In standing and during ambulation with rolling walker, she maintained weight distributed to the right. When cued to bear weight equally, standing posture improved, however, forward shoulders and increased thoracic/lumbar kyphosis were maintained. Following gait and balance assessment, the rolling walker, prescribed previously, was deemed not necessary, however, she continued its use for long distances.

Neurological exam

Light touch [23] was tested using a cotton tipped applicator in both upper and lower extremities. Although some inconsistency in response was found bilaterally, light touch was determined to be intact. Other neurological testing was performed (Table 1). Sympathetic slump [24] exam was positive on the left, exacerbating

Table 1. Examination findings.

	Left	Right
Active range of motion		
Shoulder		
Flexion	140°	165°
Abduction	105°	150°
Internal rotation	45°	55°
External rotation	80°	92°
Thoracic spine		
Flexion	No deficits	
Extension	Moderately limited	
Lateral flexion	No deficits	
Rotation	No deficits	
<i>Manual muscle testing^a</i>		
Shoulder		
Flexion	4/5	4/5
Extension	5/5	5/5
Abduction	3/5	3/5
Internal rotation	5/5	5/5
External rotation	4/5	5/5
<i>Special tests at the shoulder</i>		
Hawkins Kennedy [26,27]	Negative	
Painful arc [26]	Negative	
Empty can [26,28]	Negative	
Neer's impingement test [27]	Negative	
Drop arm [29]	Negative	
Cross body adduction [30]	Negative	
Biceps load [31]	Negative	
Crank [32]	Negative	
<i>Neurological examination</i>		
Upper motor neuron reflex tests ^b		
	Negative for hyperreflexia bilaterally	
Deep tendon reflexes		
Biceps reflex	3+	2+
Triceps reflex	2+	2+
Achilles tendon reflex	1+	1+
Patellar tendon reflex	1+	1+
Myotomal testing		
	Diminished bilaterally at C5; all others intact	
Sensation		
Light touch ^c (upper/lower extremity)	Intact	Intact
Vibration detection	Equal bilaterally	

^aKendall et al. [25].

^bHoffman's reflex, inverted supinator reflex, Babinski reflex, clonus [33].

^cStatic mechanical detection.

the "metal brace" sensation. Isometric manual muscle testing of shoulder strength was performed in sitting position (Table 1) [25].

Joint range of motion

Shoulder

All shoulder active range of motion measurements were tested and measured in supine (Table 1). Internal and external rotation was measured in 90° shoulder abduction [34]. Shoulder active range of motion revealed left shoulder flexion and abduction limitation with 3/10 and 4/10 end range discomfort, respectively [35]. Several diagnostic special tests at the shoulder were performed and found negative (Table 1). Acromioclavicular, sternoclavicular, and scapulothoracic joint mobility were normal and equal bilaterally. Anterior and posterior glenohumeral accessory joint motions were hypomobile on the left.

Cervical and thoracic spine

Cervical active range of motion in all planes was deemed within normal limits for the patient's age and produced no shoulder pain. Cervical passive accessory motion was assessed C2 to C7 and found to be mildly hypomobile with no change in paresthesia or dysesthesia symptoms. Thoracic passive accessory motions

Table 2. Patient outcomes.

Outcome measure	Visit 1	Visit 6
Active range of motion – shoulder		
Flexion	140°	155°
Abduction	104°	155°
Internal rotation	45°	43°
External rotation	80°	75°
Manual muscle testing (left shoulder)		
Flexion	3/5	4/5
Abduction	3/5	3/5
Internal rotation	3+/5	5/5
External rotation	3+/5	4/5
Quickdash outcome tool	45%	22%
Laterality assessment (time/21 slides)	98 s (9 incorrect)	120 s (8 incorrect)
Global rating of change	–	5

were moderately hypomobile with a subjective report of increased intensity of "metal brace" sensation with T8–11 unilateral posterior to anterior assessment. Rib mobility assessment revealed normal passive accessory motion but left sided T8–11 rib assessment also increased the "metal brace" sensation.

Laterality testing

Patient was tested with 21 slides of left and right hand discrimination. Patient results were 4.6 seconds per slide with 57.15% accuracy. Normative data for this is 2 seconds per picture with 80% accuracy [36].

Clinical impression

Examination findings indicated two separate but interrelated problems. First, there were residual sensory changes from the thalamic lucunar stroke that occurred 8 months prior, and secondly shoulder and trunk hypomobility were found, the latter of which partially reproduced the patient's unpleasant sensory symptoms. It was hypothesized that use of joint manual therapy at the shoulder and thoracic spine might improve glenohumeral mobility and decrease the patient's dysesthesia.

Interventions

Manual therapy treatment included left glenohumeral joint anterior to posterior mobilization, left thoracic spine and rib unilateral posterior to anterior mobilizations for 6 treatment sessions over 2 months. Treatment was directed at the joints where assessment had reproduced the subjective metal brace-like sensation. The patient's Quick DASH, Global Rating of Change Scale (GROC), symptom diagram, NPRS to objectively measure symptoms, and shoulder active range of motion were taken three times over six treatment sessions.

Manual therapy

Thoracic and rib mobilizations were performed in prone and glenohumeral joint mobilizations in supine. Treatment consisted of both large and small amplitude (grade III and IV) mid to end range oscillatory joint mobilizations [37]. The patient reported diminishing dysesthesias and brace-like sensation during and after each manual therapy treatment was applied. The patient's drawings were completed directly after the manual therapy treatments of visits three and six. Over six physical therapy visits, oscillatory techniques were repeated until tissue/joint mobility normalized and subjective report of the "metal brace" sensation had diminished (Table 2).

Graded motor imagery/laterality training/patient education

Laterality training with right/left discrimination was initiated [38]. Patient was instructed to view magazines at home and circle the left upper extremity/hand as quickly as possible [38]. She was instructed to perform this task 5–7x/week, however, substantial noncompliance was reported. She admitted to performing it at most once/week. Education included sitting and standing postural correction, the importance of laterality training and basic principles of neuroplasticity education [38].

Therapeutic exercise/home exercise program

The patient was taught seated thoracic extension over a towel roll 1X10 repetitions every 2–3 hours while awake to promote thoracic spine mobility. In successive sessions, she was given supine cane flexion, sidelying left shoulder abduction, left upper extremity behind the back towel stretches, left wall walks in flexion and scaption [39]. These exercises were performed 1x/day for 20–30 repetitions 3–4x/week.

Outcomes

The patient was seen for six visits over two months (Table 2). Glenohumeral mobility and left shoulder active range of motion improved and subjective reports of upper extremity tingling decreased. Dysesthesias were reduced in distribution and intensity from 8/10 to 5/10 and were abolished in some body locations (Figure 1(A–C)). The NPRS has a meaningful detectable change of 3 [35]. In addition, her left shoulder strength and function improved. The GROC score was rated +5. The minimal clinically important difference (MCID) for GROC is +4 [40], which was met. The Quick DASH score decreased from 45% disability to 22%, meeting the MCID [21]. The patient's left shoulder active range of motion improved [34] and her strength improved bilaterally (Table 2) [25]. The patient performed the same 21 slides at 62% accuracy, however, at a slower rate of 5.7 seconds per slide.

Discussion

While pain is common following thalamic stroke, this patient denied pain and presented with chronic dysesthesia in a hemisensory distribution. Dysesthesia is typical following thalamic stroke [41] and has been reported in up to 85% of patients [11]. Various pathophysiological mechanisms may explain poststroke dysesthesia including spinothalamocortical tract insult, loss of cortical inhibition and/or central sensitization [11,13]. These mechanisms are not mutually exclusive, but rather, likely to occur in tandem. The symptoms described by the patient had some characteristics which were similar to phantom limb as described by Melzack [42]. Phantom limb is often described as tingling and has been attributed to alterations in body schema, a consequence of cortical neuroplasticity. Neglect has also been suggested as one of the characteristics of altered body schema [43]. It was subjectively described by this patient, and reported to be diminished following the episode of care.

Interventions have been proposed to normalize body schema and thereby decrease pain and improve function. These interventions include graded motor imagery, which initially involves hand recognition, termed laterality training [44]. Laterality deficits were demonstrated in this case and a home program issued, although the patient admitted almost complete noncompliance. Accordingly, her laterality deficits were unchanged, even though symptoms had remitted. In the amputee population where phantom limb sensations

are common, the phantom limb is reported to become shorter and shorter; retracting into the stump. This shrinkage of aberrant sensations is called telescoping [45], and is purported to occur due to cortical remapping. It is possible this may be the mechanism underlying the treatment outcomes in this case, though graded motor imagery measures, as measured by laterality testing, did not capture this change.

However, while some research has implicated cortical reorganization as an underlying mechanism behind chronic pain conditions, several studies have suggested that neural plasticity following thalamic stroke, and with subsequent rehabilitation, is distributed across various neural pathways [46,47] and specifically with passive movement training [48]. Thus, it would be difficult to suggest that the reduced dysesthesias reported in this case were due solely to cortical reorganization, particularly considering that laterality testing, which has been suggested to be correlated with cortical plasticity, was unchanged after the patient's episode of care.

Much of the evidence supports early rehabilitative intervention following stroke, with evidence of critical brain plasticity occurring in the early months post insult [49]. However, starting rehabilitation too early (e.g. constraint-induced movement therapy within 7 days post insult) may be detrimental in certain instances [49]. Much of the research discussing early intervention pertains to regaining motor function. The novel finding of this case report was that rehabilitation, in this case manual therapy intervention, was initiated well beyond what would be recommended as optimal, and for the purpose of managing sensory dysesthesia. What is not clear in the research literature on this topic is whether functional/motor recovery post-stroke has a different trajectory than recovery of somatosensation. Carey et al. demonstrated improved sensation in a sample of individuals >6 months post-stroke with lesions involving primary (S1) and/or secondary (S2) somatosensory cortex or with lesions primarily involving somatosensory thalamus and/or capsular/white matter regions [47]. Further research on optimal timeframe of somatosensory recovery is warranted.

An interesting finding of this case was that thoracic spine passive joint examination (i.e. stretch of joint articular structures), but not cutaneous stimulation, provoked the patient's dysesthetic sensory symptoms. Poststroke dysesthesia or allodynia has been reported to be exacerbated by movement [50]. In this case, a novel approach to management of thalamic stroke symptoms was chosen, oscillatory joint mobilization. Joint mobilization is a common intervention for painful musculoskeletal conditions. Studies on the underlying mechanisms of joint mobilization have demonstrated a decrease in neuroexcitability as measured by the nociceptive reflex [17,18], indicating a potential central neurophysiological effect of this intervention. A subsequent study suggested this effect may occur via facilitation of descending inhibitory mechanisms [19]. Passive oscillatory joint mobilization may have had an inhibitory effect on cortical excitability. Previous studies have demonstrated that passive physiological movement at the wrist [51] and passive accessory movement at the ankle [52] resulted in cortical inhibition as measured by transcranial magnetic stimulation. It is also important to note that as her shoulder improved, the patient increased the use of the upper extremity which may have contributed to the dampening of sensory dysesthesias.

This case report describes the successful use of thoracic, rib and shoulder manual therapy to decrease dysesthesia in an individual 8 months following a thalamic stroke. The patient's Symptom Specific Scale, Quick DASH score, and GROC improved and dysesthesias decreased. Future studies to determine the effectiveness of manual therapy on nociceptive/neurophysiological mechanisms post-thalamic stroke would be beneficial.

Disclosure statement

The authors report no conflicts of interest.

References

- [1] Meyer S, Karttunen AH, Thijs V, et al. How do somatosensory deficits in the arm and hand relate to upper limb impairment, activity, and participation problems after stroke? A systematic review. *Phys Ther*. 2014;94:1220–1231.
- [2] Bannister LC, Crewther SG, Gavrilescu M, et al. Improvement in touch sensation after stroke is associated with resting functional connectivity changes. *Front Neurol*. 2015;6:165.
- [3] Lastilla M. Lacunar infarct. *Clin Exp Hypertens*. 2006;28:205–215.
- [4] Hornby TG, Holleran CL, Leddy AL, et al. Feasibility of focused stepping practice during inpatient rehabilitation poststroke and potential contributions to mobility outcomes. *Neurorehabil Neural Repair*. 2015;29:923–932.
- [5] Chen JC, Shaw FZ. Progress in sensorimotor rehabilitative physical therapy programs for stroke patients. *World J Clin Cases*. 2014;2:316–326.
- [6] Chu VW, Hornby TG, Schmit BD. Perception of lower extremity loads in stroke survivors. *Clin Neurophysiol*. 2015;126:372–381.
- [7] Tyson SF, Brown P. How to measure pain in neurological conditions? A systematic review of psychometric properties and clinical utility of measurement tools. *Clin Rehabil*. 2014;28:669–686.
- [8] Sullivan JE, Hedman LD. Sensory dysfunction following stroke: Incidence, significance, examination, and intervention. *Top Stroke Rehabil*. 2008;15:200–217.
- [9] Carey LM, Lamp G, Turville M. The state-of-the-science on somatosensory function and its impact on daily life in adults and older adults, and following stroke: a scoping review. *OTJR (Thorofare N J)*. 2016;36(2 Suppl):275–415.
- [10] Pampa LU, Cahill LS, Carey LM. Somatosensory assessment and treatment after stroke: an evidence-practice gap. *Aust Occup Ther J*. 2015;62:93–104.
- [11] Boivie J, Leijon G, Johansson I. Central post-stroke pain—a study of the mechanisms through analyses of the sensory abnormalities. *Pain*. 1989;37:173–185.
- [12] Klit H, Finnerup NB, Andersen G, et al. Central poststroke pain: a population-based study. *Pain*. 2011;152:818–824.
- [13] Klit H, Hansen AP, Marcussen NS, et al. Early evoked pain or dysesthesia is a predictor of central poststroke pain. *Pain*. 2014;155:2699–2706.
- [14] Lewis GN, Byblow WD. A method to monitor corticomotor excitability during passive rhythmic movement of the upper limb. *Brain Res Brain Res Protoc*. 2001;8:82–87.
- [15] Maertens de Noordhout A, Rothwell JC, Day BL, et al. Effect of digital nerve stimuli on responses to electrical or magnetic stimulation of the human brain. *J Physiol (Lond)*. 1992;447:535–548.
- [16] Tokimura H, Di Lazzaro V, Tokimura Y, et al. Short latency inhibition of human hand motor cortex by somatosensory input from the hand. *J Physiol*. 2000;523:503–513.
- [17] Sterling M, Pedler A, Chan C, et al. Cervical lateral glide increases nociceptive flexion reflex threshold but not pressure or thermal pain thresholds in chronic whiplash associated disorders: a pilot randomised controlled trial. *Man Ther*. 2010;15:149–153.
- [18] Courtney CA, Witte PO, Chmell SJ, et al. Heightened flexor withdrawal response in individuals with knee osteoarthritis is modulated by joint compression and joint mobilization. *J Pain*. 2010;11:179–185.
- [19] Courtney CA, Steffen AD, Fernandez-de-Las-Penas C, et al. Joint mobilization enhances mechanisms of conditioned pain modulation in individuals with osteoarthritis of the knee. *J Orthop Sports Phys Ther*. 2016;46:168–176.
- [20] Maihofner C, Seifert F, Markovic K. Complex regional pain syndromes: new pathophysiological concepts and therapies. *Eur J Neurol*. 2010;17:649–660.
- [21] Gummesson C, Ward MM, Atroshi I. The shortened disabilities of the arm, shoulder and hand questionnaire (QuickDASH): validity and reliability based on responses within the full-length DASH. *BMC Musculoskelet Disord*. 2006;7:44.
- [22] Keibaetse M, McClure P, Pratt NA. Thoracic position effect on shoulder range of motion, strength, and three-dimensional scapular kinematics. *Arch Phys Med Rehabil*. 1999;80:945–950.
- [23] Rolke R, Magerl W, Campbell KA, et al. Quantitative sensory testing: a comprehensive protocol for clinical trials. *Eur J Pain*. 2006;10:77–88.
- [24] Joshi KC, Eapen C, Kumar SP. Normal sensory and range of motion (ROM) responses during thoracic slump test (ST) in asymptomatic subjects. *J Man Manip Ther*. 2013;21:24–32.
- [25] Kendall F, McCreary E, Provance P, et al. *Muscles testing and function with posture and pain*. 5th ed. Baltimore (MD): Lippincott Williams and Wilkins; 2005.
- [26] Chen CW, Pan ZE, Zhang C, et al. Clinical research on the efficiency of physical examinations used for diagnosis of subacromial impingement syndrome. *Zhongguo Gu Shang*. 2016;29:434–438.
- [27] Manske R, Ellenbecker T. Current concepts in shoulder examination of the overhead athlete. *Int J Sports Phys Ther*. 2013;8:554–578.
- [28] Lazaro LE, Cordasco FA. Physical exam of the adolescent shoulder: tips for evaluating and diagnosing common shoulder disorders in the adolescent athlete. *Curr Opin Pediatr*. 2017;29:70–79.
- [29] Jain NB, Luz J, Higgins LD, et al. The diagnostic accuracy of special tests for rotator cuff tear: The ROW cohort study. *Am J Phys Med Rehabil*. 2017;96:176–183.
- [30] Owens S, Itamura JM. Differential diagnosis of shoulder injuries in sports. *Orthop Clin North Am*. 2001;32:393–398.
- [31] Kim SH, Ha KI, Ahn JH, et al. Biceps load test II: a clinical test for SLAP lesions of the shoulder. *Arthroscopy*. 2001;17:160–164.
- [32] Reinold MM, Gill TJ. Current concepts in the evaluation and treatment of the shoulder in overhead-throwing athletes, part 1: physical characteristics and clinical examination. *Sports Health*. 2010;2:39–50.
- [33] Cook C, Roman M, Stewart KM, et al. Reliability and diagnostic accuracy of clinical special tests for myelopathy in patients seen for cervical dysfunction. *J Orthop Sports Phys Ther*. 2009;39:172–178.
- [34] Norkin C, White J. *Measurement of joint motion; a guide to goniometry*. 3rd ed. Philadelphia (PA): F.A. Davis Company; 2003.
- [35] Mintken PE, Cleland JA, Carpenter KJ, et al. Some factors predict successful short-term outcomes in individuals with shoulder pain receiving cervicothoracic manipulation: a single-arm trial. *Phys Ther*. 2010;90:26–42.

- [36] Wallwork SB, Butler DS, Fulton I, et al. Left/right neck rotation judgments are affected by age, gender, handedness and image rotation. *Man Ther.* 2013;18:225–230.
- [37] Hengeveld E, Banks K, editors. *Maitland's peripheral manipulation*. 4th ed. Saint Louis: Elsevier; 2011.
- [38] Daffada PJ, Walsh N, McCabe CS, et al. The impact of cortical remapping interventions on pain and disability in chronic low back pain: a systematic review. *Physiotherapy.* 2015;101:25–33.
- [39] Castelein B, Cagnie B, Parlevliet T, et al. Superficial and deep scapulothoracic muscle electromyographic activity during elevation exercises in the scapular plane. *J Orthop Sports Phys Ther.* 2016;46:184–193.
- [40] Jaeschke R, Singer J, Guyatt GH. Measurement of health status ascertaining the minimal clinically important difference. *Control Clin Trials.* 1989;10:407–415.
- [41] Klit H, Finnerup NB, Jensen TS. Central post-stroke pain: clinical characteristics, pathophysiology, and management. *Lancet Neurol.* 2009;8:857–868.
- [42] Melzack R. Phantom limbs and the concept of a neuromatrix. *Trends Neurosci.* 1990;13:88–92.
- [43] Llorens R, Borrego A, Palomo P, et al. Body schema plasticity after stroke: subjective and neurophysiological correlates of the rubber hand illusion. *Neuropsychologia.* 2017;96:61–69.
- [44] Bowering KJ, O'Connell NE, Tabor A, et al. The effects of graded motor imagery and its components on chronic pain: a systematic review and meta-analysis. *J Pain.* 2013;14:3–13.
- [45] Oouchida Y, Sudo T, Inamura T, et al. Maladaptive change of body representation in the brain after damage to central or peripheral nervous system. *Neurosci Res.* 2016;104:38–43.
- [46] Borstad A, Schmalbrock P, Choi S, et al. Neural correlates supporting sensory discrimination after left hemisphere stroke. *Brain Res.* 2012;1460:78–87.
- [47] Carey LM, Abbott DF, Lamp G, et al. Same intervention-different reorganization: the impact of lesion location on training-facilitated somatosensory recovery after stroke. *Neurorehabil Neural Repair.* 2016;30:988–1000.
- [48] Dechaumont-Palacin S, Marque P, De Boissezon X, et al. Neural correlates of proprioceptive integration in the contralesional hemisphere of very impaired patients shortly after a subcortical stroke: An fMRI study. *Neurorehabil Neural Repair.* 2008;22:154–165.
- [49] Allred RP, Kim SY, Jones TA. Use it and/or lose it-experience effects on brain remodeling across time after stroke. *Front Hum Neurosci.* 2014;8:379.
- [50] Beric A. Central pain and dysesthesia syndrome. *Neurol Clin.* 1998;16:899–918.
- [51] Lewis GN, Byblow WD, Carson RG. Phasic modulation of corticomotor excitability during passive movement of the upper limb: Effects of movement frequency and muscle specificity. *Brain Res.* 2001;900:282–294.
- [52] Fisher BE, Piraino A, Lee YY, et al. The effect of velocity of joint mobilization on corticospinal excitability in individuals with a history of ankle sprain. *J Orthop Sports Phys Ther.* 2016;46:562–570.