

Unilateral lesion of the paramedian pontine reticular formation

Loss of rapid eye movements with preservation of vestibulo-ocular reflex and pursuit*

G. KOMMERELL¹, V. HENN², M. BACH¹ and C. H. LÜCKING³

¹Department of Ophthalmology, University of Freiburg, FRG; ²Department of Neurology, University of Zürich, Switzerland; ³Department of Neurology, University of Freiburg, FRG

ABSTRACT. A 55-year-old man had a spontaneous hemorrhage into the pontine tegmentum causing a saccadic gaze palsy with slowing and truncation of all rapid eye movements to the left, and a paralysis of the left lateral rectus muscle. There was no gaze-paretic nystagmus to the left. The vestibulo-ocular reflex and pursuit movements were preserved. In analogy to ocular motor deficits found after experimental lesions in the monkey the authors postulate involvement of the left paramedian pontine reticular formation (PPRF) and the left abducens fasciculus. The location of pathology in the CT scan is consistent with such a hypothesis. The following conclusions can be drawn: (1) The PPRF is not necessary for holding ipsilateral gaze, and (2) smooth pursuit movements and the vestibulo-ocular reflex are not mediated by the PPRF.

Key word: eye movements; gaze palsy; nystagmus (gaze paretic); PPRF; pursuit; saccades; vestibulo-ocular reflex

INTRODUCTION

The paramedian pontine reticular formation (PPRF) has been defined as the structure that generates all types of rapid eye movements, *i.e.*, saccades and rapid phases of nystagmus (Goebel

et al., 1971). The PPRF is not required for the slow movement component of the vestibulo-ocular reflex. This can be inferred from clinical pathological correlations in man (Pierrot-Deseilligny *et al.*, 1981, 1982) and from experiments in the monkey. The vestibulo-ocular reflex remained intact after neurons in the PPRF were selectively destroyed by local injection of kainic acid (Henn *et al.*, 1984).

Whether the PPRF is required for smooth pursuit movements has remained unclear. The fact that patients with a lesion of the PPRF usually lack pursuit movements in the ipsilateral hemifield, even in cases where the vestibulo-ocular reflex is spared (Leigh & Zee, 1983), led to the assumption that the PPRF might be the

Addresses:

G. Kommerell, M.D., Professor of Ophthalmology, and M. Bach, Ph.D., Universitäts-Augenklinik, D 7800 Freiburg, BRD.

V. Henn, M.D., Professor of Neurology, Neurologische Universitätsklinik, CH 8091 Zürich, Switzerland.

C. H. Lücking, M.D., Professor of Neurology, Abteilung Klinische Neurologie und Neurophysiologie, D 7800 Freiburg, BRD.

* Reported in part at the sixth INOS meeting in Hakone, Japan 1986.

last prenuclear relay for smooth pursuit (Pierrot-Deseilligny *et al.*, 1981). This view was challenged by recent experiments in monkeys where a bilateral lesion of the PPRF with kainic acid allowed the animal to pursue at normal velocities (Henn *et al.*, 1984). Preservation of pursuit in a unilateral PPRF lesion has as yet not been described, neither in the monkey nor in man. In this paper, we present a patient with such a syndrome. Recently, we have observed a second patient with very similar signs, but we will restrict this report to one case only.

CASE REPORT

A 55-year-old athletic man suddenly experienced double vision, tinnitus in the left ear, vertigo, nausea, and vomiting. On the following day the patient was admitted to hospital. His clinical findings were compatible with a lesion of the left ponto-medullary tegmentum. He showed a 'one-and-a-half' syndrome, *i.e.*, gaze palsy to the left and an internuclear palsy of the left medial rectus muscle. The *right* eye could be fully abducted with

a saccade of nearly normal velocity, but it could not be held in a right position because of a gaze paretic nystagmus. Leftward saccades could not be elicited. Instead, the eye drifted to a paramedian position in the right hemifield. With near convergence or with the vestibulo-ocular reflex the eye could be brought up to the midline, but not across into the left hemifield. The *left* eye was slightly adducted. Neither with gaze effort nor with the vestibulo-ocular reflex could the left eye be moved in the horizontal plane, but with near convergence the eye could be adducted by about 15°. Vertical saccades of both eyes were slightly slowed, but not limited in amplitude. Horizontal optokinetic nystagmus could not be elicited. Vertical OKN could be evoked, but was much slowed.

The neurological examination further revealed a peripheral facial palsy and a palsy of the IX and X cranial nerves on the left with some difficulty in swallowing. Sensibility in the area of V₁ and V₂ on the *right* was reduced. The gait was ataxic. Acoustically evoked brainstem potentials showed an increased latency of the 2 and 3 components, and a lack of the 4 and 5 complex. A CT scan, two days after the insult, showed a hemorrhage in the tegmentum of the pons, slightly lateralized to the left (Fig. 1). This hemorrhage had been partially

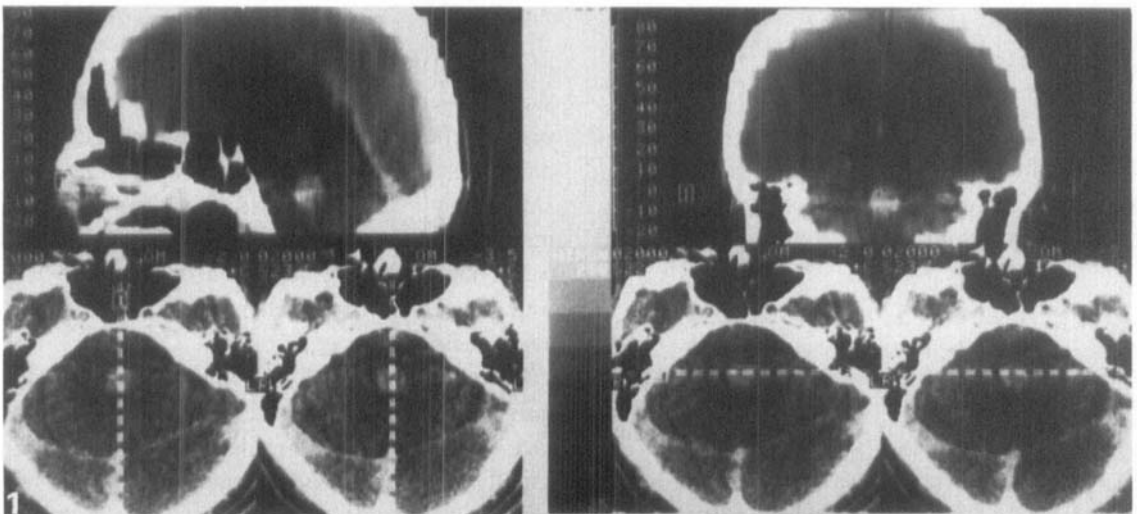


Fig. 1. Computed tomography, with contrast (Telebrix), two days after the insult, shows a lesion in the ponto-medullary tegmentum that was interpreted as a hemorrhage.

absorbed at a repeat scan three weeks after the insult. In the follow-up, the palsies of the VII, IX, and X cranial nerves and the ataxia gradually resolved. The tinnitus slowly disappeared over weeks, and an audiogram performed one year after the insult revealed only a moderate depression in the high frequency range, slightly more pronounced in the left than in the right ear. Acoustically evoked brainstem potentials had become normal on both sides. The ocular motility improved in that the left internuclear ophthalmoplegia disappeared, but a palsy for rapid eye movements to the left (in the right eye) and a complete abduction paralysis of the left eye compatible with a lesion of the left PPRF and of the left abducens fasciculus remained as permanent deficits (Fig. 2).

A detailed analysis of the ocular motor disturbance was performed 15 months after the insult. In Figs. 3 to 8 the movements of the right eye are shown. They can be considered representative of the remaining supranuclear signals as there was no additional muscle paresis. The movements of the left eye were very small and distorted because of the abducens paralysis, and were therefore not included in the figures. The left eye was esotropic with an angle of 23° when the right eye looked 20° to the right, 32° when the right eye looked straight ahead, and 50° when the right eye looked 20° to the left. The patient did not report double vision. Obviously, vision from the left eye was suppressed.

Regarding the movements of the right eye, most of the leftward saccades were very slow, even if executed in the right hemifield (Fig. 3). To get from 20° on the right to the midposition often took longer than one second. Refixation movements into the left hemifield were even slower and were limited to about 10°, but with the vestibulo-ocular reflex and with pursuit of a moving target the right eye reached the nasal end position. The

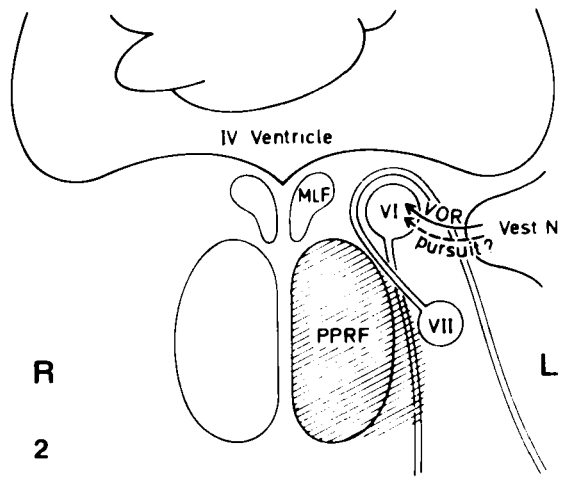


Fig. 2. Schematic drawing of a horizontal cut through the brainstem at the level of the caudal pons. Deficits that had remained 15 months after the insult were compatible with a lesion of the left paramedian pontine reticular formation (PPRF) and the left abducens fasciculus (hatched area). The fibers conveying pursuit to the abducens nucleus are indicated by a dashed line because their origin and course are not yet known.

gain of the vestibulo-ocular reflex was near unity (Fig. 4), and pursuit reached normal velocities (Fig. 5). Once the eye had been brought to the extreme left position by tracking a target, it could be held there, even in complete darkness (Fig. 6, left). However, in the right hemifield a gaze evoked nystagmus was recorded, and the eye drifted back to the midposition as soon as the target light was switched off (Fig. 6, right). When the patient looked at a fixation target that was rotated together with the chair on which he was sitting (hand-driven, approximately sinusoidal oscillation at 2 Hz over an amplitude of 40°), he was able to completely suppress his vestibulo-ocular reflex.




Fig. 3. Refixation saccades in the right hemifield. Nearly normal velocities to the left are only achieved when a blink is added. Otherwise, the saccades are very slow. Infrared reflection technique.

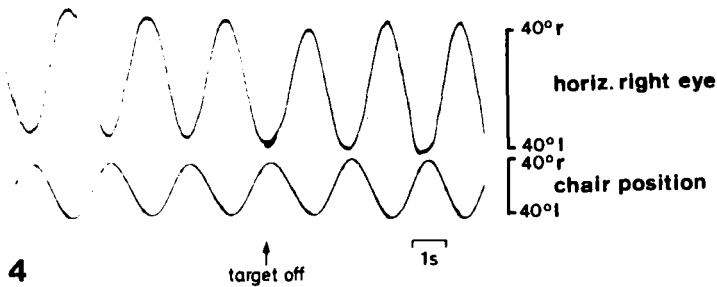


Fig. 4. Vestibulo-ocular reflex, left to the arrow with a small fixation target, right to the arrow in complete darkness. DC-electro-oculogram.




Fig. 5. Pursuit movements reaching 54°/sec to the left and 21°/sec to the right. Absence of saccades during leftward tracking. DC-electro-oculogram.

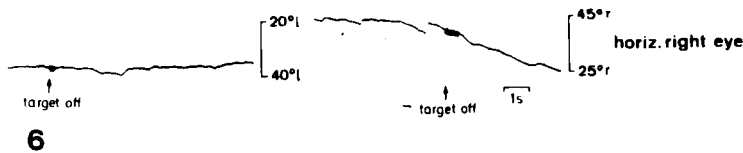


Fig. 6. Gaze holding to the left and right. DC-electro-oculogram. Note the differently truncated ordinates.

Caloric nystagmus, recorded with AC-electro-oculography, was very weak. Irrigation with warm water (44 °C over 30 sec) into the right ear elicited only three rightward jerks; after irrigation with cold water (30 °C over 30 sec) into the left ear no response was observed. Warm water into the left ear and cold water into the right ear were not tried because leftward jerks could not be expected. Optokinetic nystagmus could be elicited when stripes were moved to the left; the gain was slightly reduced. There was no OKN when stripes were moved to the right. Vertical OKN with the stripes moving up or down was weak.

It was interesting to observe how the patient coped with his impediment. He made excessive use of head movements and blinked whenever he wanted to make a leftward eye movement. Together with a blink, leftward movements occa-

sionally reached normal saccade velocities (Fig. 3). When he was reading, head movements and blinking enabled him to find the beginning of a new line fairly quickly (Fig. 7). When his head was restrained, a series of blinks each of them associated with an eye shift to the left, was required to reach the beginning of a new line (Fig. 8). The patient was unaware of his conspicuous head movements and frequent blinking. He had been able to resume athletic sports which he had been practising before the insult.

DISCUSSION

We have described a patient with a spontaneous hemorrhage into the ponto-medullary tegmen-

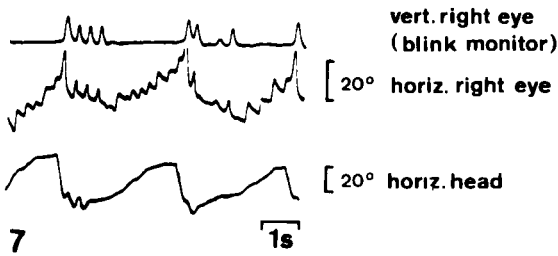


Fig. 7. Reading with the head unrestrained. When searching for the beginning of the new line, the patient first used a big head thrust and then one or two smaller head jerks. The head movements were synchronous with blinks. DC-electro-oculogram. Head position was recorded with a potentiometer mounted on a light helmet. Direct observation proved that the small deflections of the curve after the large one were not inertia artifacts.

ocular motor deficits remained that indicated a lesion of the left PPRF and of the left abducens fasciculus (Fig. 2).

The evidence that the PPRF was damaged comes from the similarities of the patient's ocular motor deficits with those found in monkeys after experimental lesion of the PPRF (Henn *et al.*, 1984). In the patient, as in monkeys, there was a severe disturbance of ipsilaterally directed rapid eye movements, even in the contralateral hemifield. That the paralysis of the left lateral rectus muscle was due to a lesion of the abducens fibers rather than the nucleus can be inferred from the fact that the right eye could be fully adducted by vestibular stimuli. With a lesion of the abducens nucleus, this would have been impossible because of damage to internuclear neurons that provide the main

supranuclear input to right medial rectus motoneurons for conjugate gaze.

It was interesting to observe how the patient could cope with his difficulty to perform goal directed saccades to the left. Firstly, he substituted with head movements. Secondly, he used blinks that greatly helped him to bring his eyes to the left. Monkeys with a PPRF lesion sometimes use the same blinking strategy. A possible explanation for the beneficial effect of blinking lies in the function of the pause cells that are located near the midline of the pontine tegmentum. During fixation or slow movements these cells fire at a high continuous rate, but stop during saccades in all directions. Pause cells also stop firing during the whole duration of a blink (Cohen & Henn, 1972). Their function has been interpreted as a gate which opens only during rapid movements to allow the saccadic pulse to reach motoneurons. During a blink the 'gate' might be open long enough to allow the few PPRF cells that have survived to produce a longer or more effective pulse which would result in a faster movement.

The most interesting observation in our patient is the fact that the gaze palsy was 'dissociated': While rapid eye movements were severely impaired, slow eye movements appeared normal. Translated into structural terms, this means that a lesion confined to the PPRF does not interfere with slow eye movement generation. That the vestibulo-ocular reflex is not mediated by the PPRF had been known from

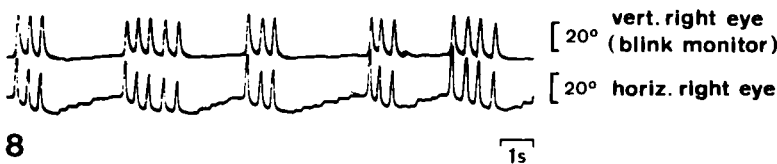

Fig. 8. Reading with the head restrained. The patient needed three or four 'saccades', each of them combined with a blink, to bring the eye to the beginning of a new line. DC-electro-oculogram.

clinical (Pierrot-Deseilligny *et al.*, 1981) and experimental (Henn *et al.*, 1984) studies. Preservation of pursuit with a unilateral PPRF syndrome has, to our knowledge, not been documented before, neither in a patient nor in the monkey. However, preserved pursuit has been described for bilateral lesions in the monkey (Henn *et al.*, 1984) and recently in man. Hanson *et al.* (1986) documented in two patients with an ischemic lesion preserved pursuit and VOR, but slowing of saccades and fast phases of nystagmus in all directions. In one patient post-mortem examination proved that the lesion was located in the median and paramedian pontine reticular formation. There is no neurophysiological explanation why in monkeys such a dissociation syndrome has so far not been observed with a unilateral lesion.

The fact that preservation of pursuit is so rare in clinical lesions of the PPRF suggests that fibers which convey pursuit are located in the immediate vicinity. It may well be that hemorrhages are more likely to destroy cells and spare axons, whereas other pathology would not lead

to such selective lesions. We would propose such a mechanism for the case presented here and for a similar one we have seen since, although, in both cases, fibers of the abducens fasciculus were permanently damaged.

Although the patient's rapid eye movements to the left were severely truncated, he was able to hold his gaze in the left field once it had been brought there by a pursuit movement. Even after the target had been switched off, the position at 40° on the left was maintained for many seconds. Only in the contralateral field, to which saccades were normal, was slight gaze evoked nystagmus observed together with a centripetal drift after the target was switched off. This observation proves that a saccadic gaze palsy can exist without a gaze paretic nystagmus. Furthermore, it can be concluded that the PPRF is not necessary for holding ipsilateral gaze. In more theoretical terms, the velocity-to-position integrator which provides motoneurons with a continuous tonic input, is not located in the PPRF.

REFERENCES

- COHEN, B. & HENN, V.: Unit activity in the pontine reticular formation associated with eye movements. *Brain Res.* 46: 403-410, 1972
- GOEBEL, H. H., KOMATSUZAKI, A., BENDER, M. B. & COHEN, B.: Lesions of the pontine tegmentum and conjugate gaze paralysis. *Arch. Neurol. (Chicago)* 24: 431-440, 1971
- HANSON, M. R., HAMID, M. A., TOMSAK, R. L., CHOU, S. S. & LEIGH, R. J.: Selective saccadic palsy caused by pontine lesions: clinical, physiological, and pathological correlation. *Ann. Neurol.* 20: 209-217, 1986
- HENN, V., LANG, W., HEPP, K. & REISINE, H.: Experimental gaze palsies in monkeys and their relation to human pathology. *Brain* 107: 619-636, 1984
- LEIGH, R. J. & ZEE, D. S.: *The Neurology of Eye Movements*, p. 221. F. A. Davis Company, Philadelphia 1983
- PIERROT-DESEILLIGNY, C., CHAIN, F., SERDARU, M., GRAY, F. & LHERMITTE, F.: The 'one-and-a-half' syndrome. Electro-oculographic analysis of five cases with deductions about the physiological mechanisms of lateral gaze. *Brain* 104: 665-699, 1981
- PIERROT-DESEILLIGNY, C., CHAIN, F. & LHERMITTE, F.: Syndrome de la formation réticulaire pontique. Précisions physiopathologiques sur les anomalies des mouvements oculaires volontaires. *Rev. Neurol. (Paris)* 138: 517-532, 1982