

Phenylpropanolamine: An Over-the-Counter Drug Causing Central Nervous System Vasculitis and Intracerebral Hemorrhage

Case Report and Review

Roberta Glick, M.D., John Hoying, M.D., Leonard Cerullo, M.D., and Susan Perlman, M.D.

Department of Neurosurgery, Cook County Hospital—University of Illinois Hospital (RG), and Departments of Neurosurgery (LC) and Rheumatology (JH, SP), Northwestern University Medical School, Chicago, Illinois

Phenylpropanolamine (PPA) is the major ingredient in more than 70 over-the-counter preparations including diet pills, nasal decongestants, and the legal "look-alike" stimulants. Structurally and functionally similar to amphetamine and ephedrine, PPA has recently been associated with several neurological manifestations including psychosis, stroke, severe headache, seizures, and intracerebral hematoma. We report a case of intracerebral hematoma and subarachnoid hemorrhage in a young woman with angiographic and biopsy-proven vasculitis of the central nervous system (CNS) induced by PPA in her diet pills. From review of the literature, we distinguish drug-induced vasculitis as a separate entity from primary CNS vasculitis, both clinically and pathologically. This report should alert physicians, in general, to this potentially fatal side effect of PPA, a commonly used over-the-counter drug. Also, neurosurgeons in particular should consider the possibility of drug-induced vasculitis when faced with cases of intracerebral or subarachnoid hemorrhage without apparent cause. (*Neurosurgery* 20:969-974, 1987)

Key words: Central nervous system vasculitis, Drug-induced vasculitis, Intracerebral hematoma, Phenylpropanolamine, Subarachnoid hemorrhage

INTRODUCTION

Phenylpropanolamine (PPA) is the major ingredient in more than 70 over-the-counter preparations including diet pills, nasal decongestants, and the legal "look-alike" stimulants (1, 2, 12, 44, 45, 53). Structurally and functionally similar to amphetamine and ephedrine (12, 44, 64), PPA recently has been associated with several neurological manifestations including psychosis (32, 48, 60, 66), stroke (1, 30, 34, 38), severe headache (51), seizures (1, 44), and intracerebral hematoma (1, 34, 46). We report a case of intracerebral hematoma and subarachnoid hemorrhage in a young woman with angiographic and biopsy-proven vasculitis of the central nervous system (CNS) induced by PPA in her diet pills. The proximity of the ingestion of PPA to the acute onset of symptoms, the clinical presentation and course, the histopathological findings, and the structural and functional similarity of PPA to ephedrine and amphetamine (both of which can cause CNS vasculitis or hematoma), lead to this conclusion.

CASE PRESENTATION

The patient is a 35-year-old, right-handed mother of five children who was 3 weeks postpartum when she developed the sudden onset of headache in the posterior-occipital area, associated with nausea, vomiting, photophobia, and extreme fatigue. She was seen at a local hospital emergency room and discharged with pain medication. Her symptoms persisted, and 4 days later she was admitted to another hospital. A computed tomographic (CT) scan then demonstrated a right frontal intracerebral hematoma and subarachnoid blood. She was transferred to Northwestern University Medical School Hospital the next day.

On admission, major complaints were severe headache and mild photophobia. She said that she had not used amphetamine,

heroin, or other drugs except librium, 5 mg orally, 3 times a day, prescribed for postpartum depression, which she had discontinued 2 days before the ictus. Later, she reported using an over-the-counter diet pill, Dexatrim, Extra Strength (Thompson Medical Co., New York, New York) which contains PPA. She took Dexatrim for 2 years, but stopped taking the diet pills when she discovered she was pregnant. She then took her first Dexatrim tablet in many months 1½ hours before the onset of her symptoms.

She was employed as a business executive. Her medical history was negative except for a cesarean section in 1980 and the use of birth control pills 10 years before admission. Her family history was remarkable for stroke (maternal grandfather) and myocardial infarction (mother, age 52).

Physical examination showed that the vital signs and general physical condition were normal. Neurological examination demonstrated minimal nuchal rigidity, mild diffuse hyperreflexia, and no focal abnormalities. The admitting complete blood count, SMA 20, coagulation profile, chest x-ray film, urinalysis, and electrocardiogram (EKG) were normal. The Westergren sedimentation rate was 14 mm/hour.

The patient was admitted to the neurosurgical intensive care unit, where she was placed at total bedrest and received diocetyl sodium sulfosuccinate, phenytoin, pain medication (acetaminophen), maintenance fluids, dexamethasone (4 mg orally every 6 hours), and cimetidine (300 mg orally every 6 hours).

The following morning, a CT scan again showed a right frontal hematoma with surrounding edema. Transfemoral bilateral carotid and left vertebral angiography demonstrated diffuse segmental narrowing and dilation of intracranial arterial branches involving both the anterior and the posterior circulation, including small, medium, and large vessels (Fig. 1), consistent with vasculitis. In addition, there was a shift of the right anterior cerebral artery to the left, secondary to mass

effect. No aneurysm or arteriovenous malformation was seen. Collagen vascular, infectious, and metastatic disease work-ups by medical consultants all were negative. The working diagnosis entertained was primary CNS vasculitis. Dexamethasone was stopped, and intravenous methylprednisolone (300 mg every 6 hours) was begun.

On the 7th hospital day, repeated neurological examination showed the development of a slightly blurred right disc margin and an equivocal upgoing toe on the left; her severe headache persisted. Consequently, craniotomy was performed for evacuation of the intracerebral hematoma, leptomeningeal biopsy, brain biopsy, and biopsy of the hematoma cavity. Histopathological examination demonstrated necrotizing vasculitis of small arteries and veins, with infiltration of polymorphonuclear leukocytes, particularly prominent in the intima, and subsequent thickening and reduction of the lumen, areas of vessel occlusion, and fragmentation of the elastic lamina (Fig.

2). Areas of subarachnoid hemorrhage organizing with fibroblastic proliferation and recent small infarcts involving the gray matter were also noted. No evidence of tumor or infection was found.

Neurologically, the patient did well postoperatively. Postoperative digital subtraction angiography showed irregularity of the proximal right carotid artery, but the distal vasculitic changes were not visualized. Cytosoxan (125 mg orally, 3 times a day), was begun, and she was discharged 10 days postoperatively. Two months after admission, she continued to note intermittent headaches. A CT scan with contrast infusion and magnetic resonance (MR) scan were obtained. The CT scan did not demonstrate any active disease process. The MR scan showed increased signal in the deep right frontal lobe interpreted as residual intracerebral hematoma, gliosis, or ischemia. Four months postictus, her headaches had resolved, and cerebral angiography showed almost complete resolution of

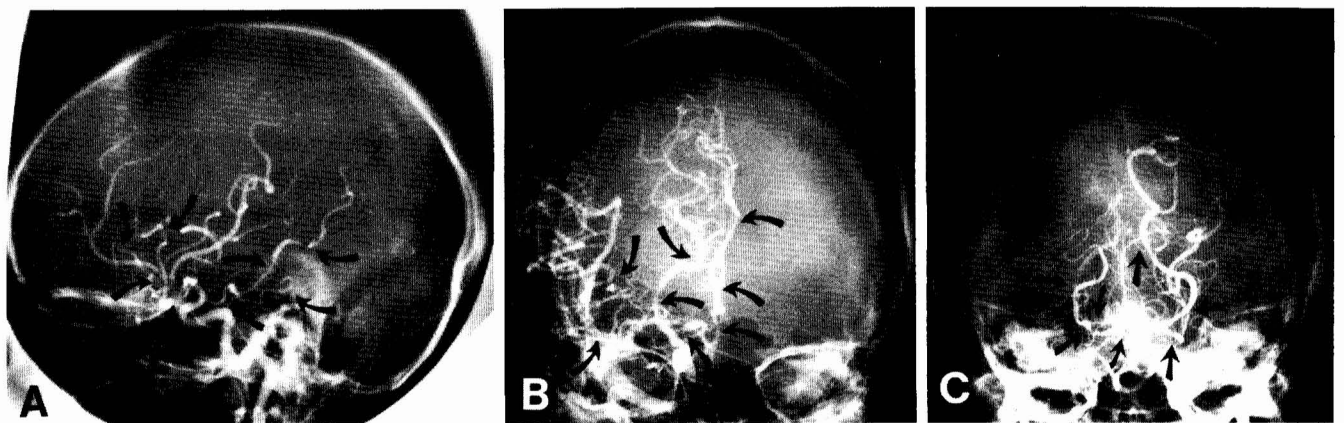


FIG. 1. Cerebral angiogram showing diffuse segmental narrowing (arrows). A, lateral carotid; B, anteroposterior (AP) carotid; C, AP vertebral.

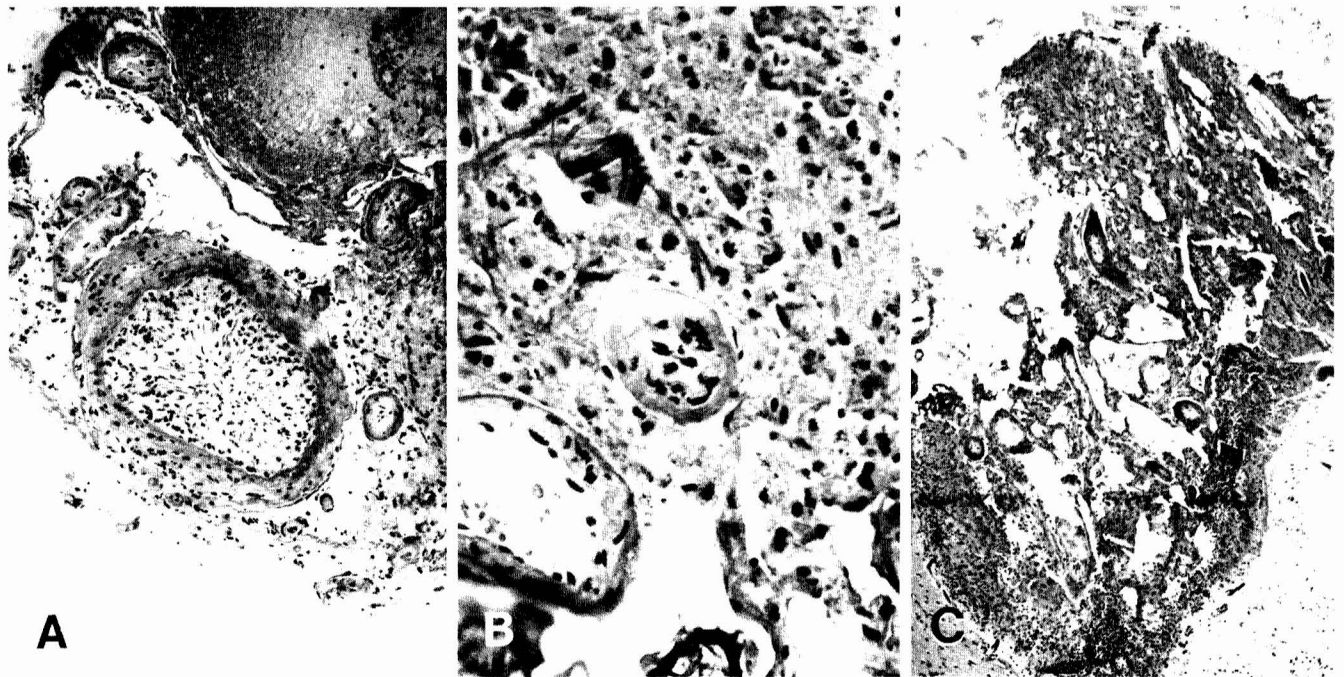


FIG. 2. Photomicrograph of the biopsy specimen. A, section showing a larger artery with intimal proliferation and infiltration of polymorphonuclear leukocytes. B, section showing a large and surrounding small arteries with more infiltration of polymorphonuclear leukocytes and disruption of the vessel. C, section showing complete destruction of the architecture with necrosis and fragmentation.

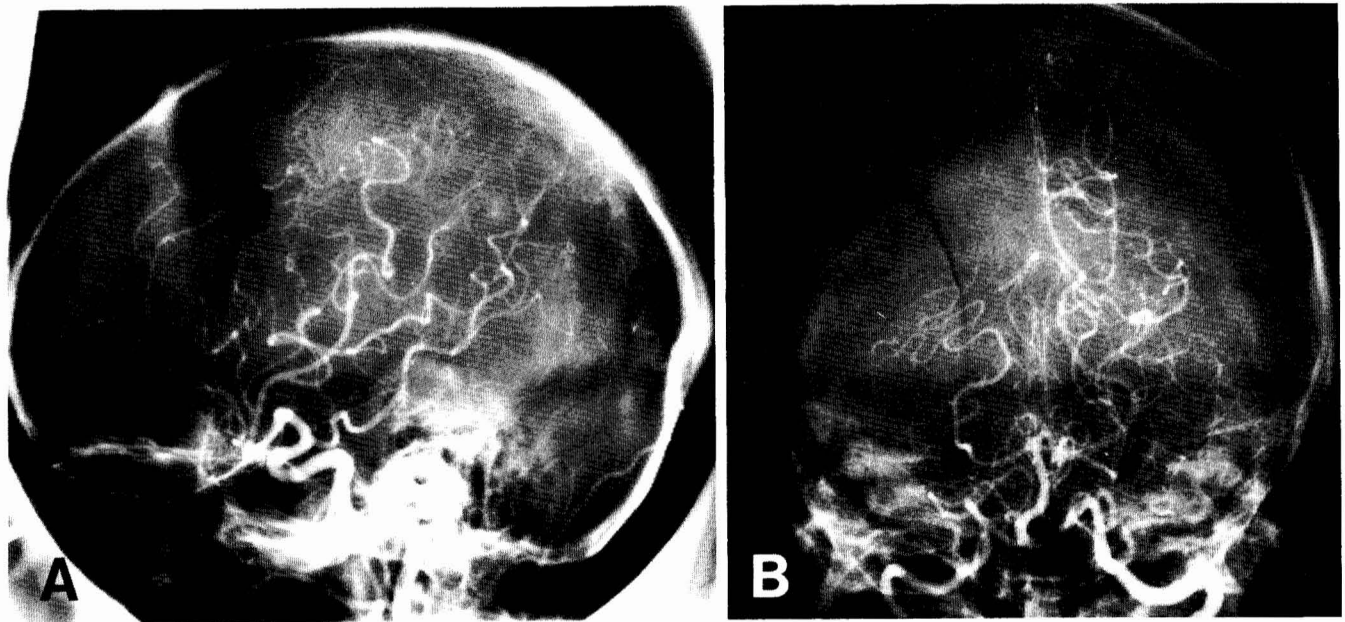


FIG. 3. Cerebral angiogram showing resolution of previously noted lesions. A. lateral carotid; B, AP vertebral.

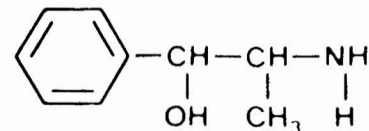
all previously noted lesions (Fig. 3). Over the ensuing 7 months, medications were tapered and stopped.

DISCUSSION

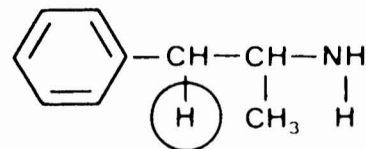
Phenylpropanolamine, the major ingredient in more than 70 over-the-counter preparations of diet pills, decongestants, and stimulants (1, 2, 12, 44, 45, 53), has recently been associated with intracerebral hemorrhage (1, 34, 46). Our patient is the first angiographic and biopsy-proven case of CNS vasculitis and intracerebral hemorrhage associated with the use of PPA. There are several reasons to believe that this is a case of drug-induced rather than primary CNS vasculitis: (a) The proximity in time of the ingestion of PPA to the acute onset of symptoms is similar to other cases of drug-induced vasculitis (7, 8, 11, 13, 23, 33, 39, 40, 50, 65, 68, 69). (b) The clinical presentation and remitting course are similar to those seen with drug-induced vasculitides in contrast to primary CNS vasculitis, which is usually a progressive and fatal disease (3-6, 9, 10, 14-16, 20, 22, 24, 25, 28, 29, 31, 35, 41-43, 47, 49, 52, 55-57, 62, 63, 70). (c) The occurrence of intracerebral hemorrhage is frequently associated with drug-induced vasculitis, but is rare with primary CNS vasculitis (4, 5, 9, 24, 49). (d) PPA is structurally and functionally similar to amphetamine and ephedrine (12, 44, 64) (Fig. 4), both of which have been shown to cause CNS vasculitis with intracerebral hemorrhage (7, 11, 23, 33, 39, 40, 50, 67-69). (e) The histopathological findings in our patient are similar to those in patients with other drug-induced vasculitides (8, 21, 33, 65) and differ from those of primary CNS vasculitis (3-6, 9, 10, 14, 20, 24, 25, 28-29, 35, 43, 47, 49, 52, 63, 70).

Primary CNS vasculitis, a rare disease that is by definition confined to CNS, had been considered invariably fatal until recently (10, 43). Approximately 30 cases of primary CNS vasculitis have been reported in the world literature (3-6, 9, 10, 14-16, 20, 22, 24-25, 28-29, 31, 35, 41-43, 47, 49, 52, 55-57, 62-63, 70), but the diagnosis has been made by premortem biopsy in only 3 cases (6, 10, 20). The initial symptoms in the reported cases are shown in Table 1. Seizures occurred as the presenting event in 8 patients, and systemic

PHENYLPROPANOLAMINE



AMPHETAMINE



EPHEDRINE

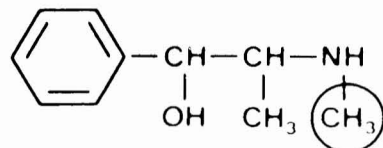


FIG. 4. Structural similarities among phenylpropanolamine, amphetamine, and ephedrine.

symptoms notably were absent. In 90% of the patients, there is progressive neurological deterioration; death occurred in all but the 4 most recently reported cases (10). The difficulty encountered in establishing the diagnosis of primary CNS vasculitis is that no single laboratory test can firmly establish or exclude it. Changes in spinal fluid show the pattern of increased pressure, increased protein, normal glucose, and lymphocytic pleocytosis. However, angiography was positive in only 8 of the 12 cases in which it was performed (Table 2), and 4 patients with negative angiograms were found to have vasculitis at autopsy (Table 2) (5, 24, 28, 29). The characteristic angiographic findings of vasculitis include segmental areas of stenosis and dilation described as "beading" or "sau-

TABLE 1
Primary CNS Vasculitis: Clinical Presentation in 30 Cases

Symptoms	No. Patients	Description
CNS	22	Headache, mental status changes, nausea and vomiting, confusion, decreased intellectual function
Cranial nerve	16	Diplopia, blurred vision, nystagmus, dysarthria, pupillary abnormalities
Focal	17	Hemiparesis and/or aphasia
Seizures	8	Focal or generalized

TABLE 2
Selected Variables in Primary vs. Drug-induced Vasculitis

	Primary	Drug-Induced
No. patients	30	25
No. hemorrhages (total)	5	11
Xanthochromic CSF (LP) ^a	4	
Intraventricular hemorrhage	1	
Subarachnoid hemorrhage		4
Intracerebral hematoma		7
No. positive angiograms/total no. performed	8/12	24/25
No. positive histological specimens/total no. performed	25/30	8/8
Biopsy	3/7	3
Autopsy	23	5

^a CSF, cerebrospinal fluid; LP, lumbar puncture.

sage" patterns and nonspecific small vessel occlusion (10). Also, aneurysms may be present (10, 20). Thus, the mainstay of diagnosis remains tissue biopsy. In all but 3 cases in the literature, the diagnosis of primary CNS vasculitis was made postmortem (6, 10, 20). Histological examination shows the characteristic granulomatous inflammation, with vessel necrosis and almost uniform involvement of the leptomeninges (10, 14). This last finding has led to the recommendation that "leptomeningeal biopsy be the test of choice in establishing the diagnosis of primary CNS vasculitis" (10). In the 7 antemortum biopsy cases reported in the literature (4, 6, 10, 20, 24, 25, 28), leptomeningeal biopsy was diagnostic in all 3 patients in which it was performed (6, 10, 20).

An association of primary CNS vasculitis with intracerebral hemorrhage is suggested but not substantiated in the literature. Xanthochromic cerebrospinal fluid was found in 4 of the 22 patients studied (4, 9, 24, 49), and intraventricular hemorrhage occurred as the terminal event in another patient who suffered a protracted course (Table 2) (5). Several of the autopsy reports mention subarachnoid hemorrhage, petechiae, and infarcts, but none mentions intracerebral hematoma specifically.

In contrast, drug-induced vasculitis is commonly associated with both intracerebral hematoma and subarachnoid hemorrhage (Table 2) (7, 11, 23, 33, 39, 40, 50, 58, 65, 67-69). Cerebral hemorrhage has been well described in patients using amphetamines (7, 11, 13, 17, 19, 23, 37, 50, 54, 61, 65, 69), as has the pathological syndrome of necrotizing angitis (8, 21). Experimentally, angiographically, and histologically confirmed vasculitis has been induced in animals immediately after the intravenous injection of amphetamines (59). A review of the world literature reveals 24 well-documented cases of drug-induced vasculitis of the CNS secondary to amphet-

amine (7, 8, 11, 23, 33, 39, 40, 50, 65, 68, 69) and 1 due to ephedrine use (67). Eleven patients had intracerebral hemorrhages: 7 hematomas (23, 33, 39, 65, 68, 69) and 4 subarachnoid hemorrhages (7, 11, 40, 50). Almost all patients with intracerebral hemorrhage experienced the abrupt onset of severe headache minutes after the oral or intravenous administration of the drug. The admission blood pressure was most often normal. Twenty-four of the 25 patients had angiographic evidence of vasculitis. Histological examination was positive in all patients in whom it was performed, including 3 premortem biopsies (11, 33, 65) and 5 autopsies (8, 50). In the 1 patient with ephedrine-induced vasculitis, skin biopsy was positive for immune complex deposition of immunoglobulin M and C3 component of complement (67); angiography was initially negative, but 7 days later showed the typical features of vasculitis. Clearly, the presentation and clinical course of our patient most strongly resemble those seen in cases of drug-induced vasculitis and not those of primary CNS vasculitis.

It may be possible to differentiate drug-induced vasculitis from primary CNS vasculitis (Table 3). The findings in drug-induced vasculitis are indistinguishable from those of immune complex-mediated vasculitic disease, i.e., polyarteritis nodosa (PAN). Involvement of small and medium vessels (usually arteries) is predominant; there is a predisposition for bifurcation points; the lesions are segmental and at different stages of development; early lesions show intimal proliferation, infiltration of polymorphonuclear leukocytes, and luminal narrowing; later lesions often show marked fibrinoid necrosis and fragmentation of elastic lamina (10, 14). Characteristically, no giant cells or granulomas are present, the cells are mainly polymorphonuclear leukocytes, and the reaction is most pronounced within the intima of the vessel. In contrast, the lesions of primary CNS vasculitis are more restricted to small vessels; there is no preference for bifurcation points; infiltrating cells are usually lymphocytes and monocytes; the inflammatory reaction is more pronounced in the media and adventitia; and necrosis is less marked than in PAN or drug-induced disease (10, 14). In primary CNS vasculitis, both giant cells and granuloma formation are noted, suggestive of a cell-mediated immune vasculitis (10, 14).

The pathological findings in our patient are most consistent with the diagnosis of drug-induced immune complex-mediated vasculitis and not primary CNS vasculitis. Infiltration was predominantly with polymorphonuclear leukocytes and was most marked in the intima. Necrotizing vasculitis of small vessels was present, and no giant cell or granuloma was observed.

Differences demonstrated by histopathological examination suggest that different immune mechanisms underlie the production of drug-induced vasculitis and primary CNS vasculitis. The mechanism of immune complex vasculitis best explains the pathological changes seen in drug-induced vasculitis and also would account for the rapid onset of symptoms and the production of pathological changes after exposure to amphetamine-like substances. Because of the presence of giant cells and granuloma formation, the pathological picture of primary CNS vasculitis seems more consistent with a cell-mediated immune vasculitic process.

The pharmacological properties of PPA also may have contributed to the clinical course of this patient. Structurally and functionally similar to amphetamine and ephedrine (Fig. 4), both of which are known to cause vasculitis and intracerebral hemorrhage (12, 44, 64, 67), PPA has recently been implicated as a cause of intracerebral hematoma in three patients (1, 34), although no studies were performed in those patients to establish the diagnosis of vasculitis. PPA in com-

TABLE 3
Histopathology of Primary and Drug-induced Vasculitis

Feature	Drug-induced	Primary
Vessels	Small, medium arteries	Arteries and veins
Lesions	Multiple stages	Multiple stages
Cellular infiltrate	Predominantly polymorphonuclear leukocytes	Predominantly lymphocytes, monocytes
Giant cells	None	Characteristic
Granulomas	None	Characteristic
Microaneurysm	Occasional	Occasional
Necrosis	Marked	Moderate
Vessel wall involvement	Intimal	Adventitial

combination with caffeine will produce intracerebral hemorrhage in hypertensive or stroke-prone rats (46) and, in a clinical experiment, a single dose of PPA-containing diet pills caused diastolic hypertension (27). PPA-induced hypertension (18, 26, 27, 36), then, may play a role in the production of intracerebral hemorrhage in these patients, especially if vessels are concurrently injured by vasculitis.

Diagnosis and classification of the vasculitis are based on a combination of clinical, angiographic, and pathological features. Based on the clinical and experimental data, we propose the following outline as an appropriate sequential diagnostic approach to a patient suspected of having CNS vasculitis: (a) detailed history-taking and physical examination, noting all prescribed and over-the-counter medications and drug use, allergies, pregnancy history (eclampsia), hypertension, stroke, and use of caffeine and cigarettes; (b) noninvasive neurological testing: CT scan, lumbar puncture, radionuclide brain scan; (c) collagen vascular, infection, and metastatic work-up; (d) invasive testing—angiography; (e) leptomeningeal and cortical biopsy.

Surgical biopsy should be performed when the diagnosis remains in question or when the clinical condition—such as an intracerebral hematoma—necessitates operation. Because there seem to be discernible histological differences between drug-induced and primary CNS vasculitis, leptomeningeal biopsy may be the definitive means of differentiating these two entities.

The preferred treatment of primary CNS vasculitis is still being established. In the treatment of drug-induced vasculitis, removal and discontinuance of the offending agent is essential. The combination of cyclophosphamide and prednisone has been recommended because of its efficacy in the treatment of other life-threatening vasculitides, e.g., PAN and Wegener's granulomatosis (10, 14, 43). Initial success has been obtained in halting the progression of primary CNS vasculitis, a disease previously thought to be progressive and invariably fatal. The good response in our patient with drug-induced CNS vasculitis suggests that chemotherapy and antiinflammatory agents also may be appropriate for the critically ill patient with severe and diffuse vascular changes due to vasculitis, although previous studies have not addressed this issue.

In summary, this report should alert physicians to this potentially fatal side effect of PPA, i.e., CNS vasculitis with intracerebral hemorrhage, and its diagnostic and therapeutic implications. Also, neurosurgeons should consider the possibility of drug-induced vasculitis when faced with cases of intracerebral or subarachnoid hemorrhage without apparent cause.

Received for publication, November 10, 1986; accepted, December 21, 1986.

Reprint requests: Dr. Roberta Glick, Department of Neurosurgery, Cook County Hospital, 1835 West Harrison, Chicago, Illinois 60612.

REFERENCES

- Bernstein E, Diskant B: Phenylpropanolamine, a potentially hazardous drug. *Ann Emerg Med* 11:311-315, 1982.
- Blum A: Phenylpropanolamine: An over-the-counter amphetamine. *JAMA* 245:1346-1347, 1981.
- Budzilovich GN, Feigin I, Siegel H: Granulomatous angiitis of the nervous system. *Arch Pathol* 76:250-256, 1963.
- Case Records of the Massachusetts General Hospital (Case 41152). *N Engl J Med* 252:634-641, 1955.
- Case Records of the Massachusetts General Hospital (Case 14-1976). *N Engl J Med* 176:741-750, 1967.
- Case Records of the Massachusetts General Hospital (Case 43-1976). *N Engl J Med* 295:944-950, 1976.
- Chynn KY: Acute subarachnoid hemorrhage. *JAMA* 233:55-56, 1975.
- Citron BP, Halpern M, McCarron M, Lundberg G, McCormick R, Pincus I, Tatter D, Haverback B: Necrotizing angiitis associated with drug abuse. *N Engl J Med* 283:1003-1011, 1970.
- Cravioto H, Feigin L: Noninfectious granulomatous angiitis with a predilection for the nervous system. *Neurology (NY)* 9:599-609, 1959.
- Cupps TR, Moore PM, Fauci AS: Isolated angiitis of the CNS. *Am J Med* 74:97-105, 1983.
- Delaney P, Estes M: Intracranial hemorrhage with amphetamine abuse. *Neurology (NY)* 30:1125-1128, 1980.
- Dietz AJ: Amphetamine-like reactions to phenylpropanolamine. *JAMA* 245:601-602, 1981.
- D'Souza T, Shraberg D: Intracranial hemorrhage associated with amphetamine use. *Neurosurgery* 31:922-923, 1981.
- Fauci AS, Haynes BF, Katz P: The spectrum of vasculitis: Clinical, pathologic, immunologic and therapeutic consideration. Part I. *Ann Intern Med* 89:660-676, 1978.
- Feasby TE, Ferguson GG, Kaufmann JCE: Isolated spinal cord vasculitis. *Can J Neurol Sci* 2:143-146, 1975.
- Fulton AB, Lee RV, Jampol LM, Kelther JL, Abert DM: Active giant cell arteritis with cerebral involvement. *Arch Ophthalmol* 94:2068-2071, 1976.
- Gericke OL: Suicide by ingestion of amphetamine sulfate. *JAMA* 128:1098-1099, 1945.
- Gibson GJ, Warrell DA: Hypertensive crisis and phenylpropanolamine. *Lancet* 2:492, 1972.
- Goodman SJ, Becker DP: Intracranial hemorrhage associated with amphetamine abuse. *JAMA* 212:480, 1970.
- Griffin J, Price DL, David L, McKann G: Granulomatous angiitis of the central nervous system with aneurysms of multiple cerebral arteries. *Trans Am Neurol Assoc* 98:146-148, 1973.
- Halpern M, Citron P: Necrotizing angiitis associated with drug abuse. *AJR* 111:663-671, 1971.
- Harbitz F: Unknown forms of arteritis, with special reference to their relation to syphilitic arteritis and pararteritis nodosa. *Am J Med Sci* 163:250-272, 1922.
- Harrington H, Heller A, Dawson D, Caplan L, Rumbaugh C:

- Intracerebral hemorrhage and oral amphetamine. *Arch Neurol* 40:503-507, 1983.
24. Harrison PE: Granulomatous angiitis of the central nervous system: Case report and review. *J Neurol Sci* 29:335-341, 1976.
 25. Hinck VC, Carter CC, Rippey JG: Giant cell (cranial) arteritis: A case with angiographic abnormality. *AJR* 92:769-775, 1964.
 26. Horowitz JD, Howes LG, Christophidis N, Lang WJ, Tennessy MR, Rand MJ: Hypertension responses induced by phenylpropranolamine in anorectic and decongestant preparations. *Lancet* 1(8259):60-61, 1980.
 27. Horowitz JD, McNeil JJ, Sweet B, Mendelsohn FAO, Louis WJ: Hypertension and postural hypotension induced by phenylpropranolamine (trimolets). *Med J Aust* 1(5):176-177, 1979.
 28. Hughes JT, Brownell B: Granulomatous giant-celled angiitis of the central nervous system. *Neurosurgery* 16:293-298, 1966.
 29. Jellinger K: Giant cell granulomatous angiitis of the central nervous system. *J Neurol* 215:175-190, 1977.
 30. Johnson DA, Etter HS, Reeves PM: Stroke and phenylpropranolamine use. *Lancet* 2:970, 1983.
 31. Judice DJ, LeBlanc JH, McGarry PA: Spinal cord vasculitis presenting as a spinal cord tumor in a heroin addict. *J Neurosurg* 48:131-134, 1978.
 32. Kane FJ, Green BQ: Psychotic episodes associated with the use of common proprietary decongestants. *Am J Psychiatry* 123:484-487, 1966.
 33. Kessler JT, Jortner BS, Adapon BD: Cerebral vasculitis in a drug abuser. *J Clin Psychiatry* 39:559-564, 1978.
 34. King J: Hypertension and cerebral hemorrhage after timolets ingestion. *Med J Aust* 2(5):258, 1979.
 35. Kolodny EH, Rebeiz JJ, Caviness VS, Richardson EP: Granulomatous angiitis of the central nervous system. *Arch Neurol* 10:510-524, 1968.
 36. Livingston PH: Transient hypertension and phenylpropranolamine. *JAMA* 196:1159, 1966.
 37. Lloyd JTA, Walker DRH: Death after combined dexamphetamine and phenelzine. *Br Med J* 2:168-169, 1965.
 38. Lovejoy FH Jr: Stroke and phenylpropranolamine. *Pediatr Alert* 12:45, 1981.
 39. Margolis MT, Newton TH: Metamphetamine ("speed") arteritis. *Neuroradiology* 2:179-182, 1971.
 40. Matick H, Anderson D, Brumlik J: Cerebral vasculitis associated with oral amphetamine overdose. *Arch Neurol* 40:253-254, 1983.
 41. McCormick HM, Neuburger KT: Giant-cell arteritis involving small meningeal and intracerebral vessels. *J Neuropathol Exp Neurol* 17:471-478, 1958.
 42. Miller DH, Haas LF, Teague C, Neale TJ: Small vessel vasculitis presenting as neurologic disorder. *J Neurol Neurosurg Psychiatry* 47:791-794, 1984.
 43. Moore PM, Cupps TR: Neurologic complications of vasculitis. *Ann Neurol* 14:155-167, 1983.
 44. Mueller SM: Phenylpropranolamine, a non-prescription drug with potentially fatal side effects. *N Engl J Med* 308:653, 1983.
 45. Mueller SM: Neurologic complications of phenylpropranolamine use. *Neurology (NY)* 33:650-652, 1983.
 46. Mueller SM, Muller J, Asdell SM: Cerebral hemorrhage associated with phenylpropranolamine in combination with caffeine. *Stroke* 15:119-123, 1984.
 47. Newman W, Wolf A: Noninfectious granulomatous angiitis involving the central nervous system. *Trans Am Neurol Assoc* 77:114-117, 1952.
 48. Norvenious G, Widerlov E, Lonnerholm G: Phenylpropranolamine and mental disturbances. *Lancet* 2:1367-1368, 1979.
 49. Nurick S, Blackwood W, Mair WGP: Giant cell granulomatous angiitis of the central nervous system. *Brain* 95:133-142, 1972.
 50. Olsen ER: Intracranial hemorrhage and amphetamine usage. *Ophthalmology* 28:464-471, 1977.
 51. Ostern S, Dodson WH: Hypertension following ornade ingestion. *JAMA* 194:472, 1965.
 52. Peison B, Padleckas R: Granulomatous angiitis of the central nervous system. *Illinois Med J* 126:330-334, 1964.
 53. *Phenylpropranolamine Weight Control Products*. Bulletin, FDA National Clearing House for Poison Control Centers, 25:16-20, 1981.
 54. Poteliakhoff A, Roughton BC: Two cases of amphetamine poisoning. *Br Med J* 1:26-27, 1956.
 55. Rewcastle NB, Tom MI: Non-infectious granulomatous angiitis of the nervous system associated with Hodgkin's disease. *J Neurol Neurosurg Psychiatry* 25:51-58, 1962.
 56. Reyes MG, Fresco R, Chokroyerty S: Viruslike particles in granulomatous angiitis of the central nervous system. *Neurology (NY)* 26:797-799, 1976.
 57. Rosenblum WI, Hadfield RR: Granulomatous angiitis of the nervous system in cases of herpes zoster and lymphosarcoma. *Neurology (NY)* 22:348-354, 1972.
 58. Rumbaugh CL, Bergeron RT, Fang HCH, McCormick R: Cerebral angiographic changes in the drug abuse patient. *Radiology* 101:335-344, 1971.
 59. Rumbaugh CL, Bergeron RT, Scanlan RL: Cerebral vascular changes secondary to amphetamine abuse in the experimental animal. *Radiology* 101:345-351, 1971.
 60. Schaffer CB, Pauli MW: Psychotic reaction caused by proprietary oral diet agents. *Am J Psychiatry* 137:1256-1257, 1980.
 61. Shukla D: Intracranial hemorrhage associated with amphetamine use. *Neurology (NY)* 32:917-918, 1982.
 62. Synder BD, McClelland RR: Isolated benign cerebral vasculitis. *Arch Neurol* 35:612-614, 1978.
 63. Vincent FM: Granulomatous angiitis. *N Engl J Med* 296:452, 1977.
 64. Weiner N: Norepinephrine, epinephrine, and the sympathomimetic amines, in Gilman AG, Goodman L, Gilman A (eds): *The Pharmacological Basis of Therapeutics*. New York, MacMillan, 1980, ed 6, ch 8, pp 138-175.
 65. Weiss SR, Raskind R, Morganstern NL, Pytlyk P, Baiz T: Intracerebral and subarachnoid hemorrhage following the use of methamphetamine ("speed"). *Int Surg* 53:123-127, 1970.
 66. Wharton BK: Nasal decongestants and paranoid psychosis. *Br J Psychiatry* 117:429-440, 1970.
 67. Wooten MR, Khangure MS, Murphy MJ: Intracerebral hemorrhage and vasculitis related to ephedrine abuse. *Ann Neurol* 13:337-340, 1983.
 68. Yatsu F, Wesson O, Smith D: Amphetamine abuse, in Richter R (ed): *Medical Aspects of Drug Abuse*. New York, Harper and Row, 1975, pp 50-56.
 69. Yu YJ, Cooper DR, Wellenstein DE, Block B: Cerebral angiitis and intracerebral hemorrhage associated with amphetamine abuse. *J Neurosurg* 58:109-111, 1983.
 70. Zollinger HU: Grosszellig-granulomatose lymphagitis cerebri (Morbus Boeck) unter dem Bilde einer multiplen Sklerose verlaufend. *Virchow Arch [Pathol Anat]* 307:597-615, 1941.