

CASE REPORT

Cortical laminar necrosis in a case of migrainous cerebral infarction

Vikram Khardenavis,¹ Davala Krishna Karthik,² Sharvari Kulkarni,³ Anirudda Deshpande⁴¹Miraj Medical College, Miraj, Maharashtra, India²Department of Radiology, Surya Diagnostics, Warangal, Telangana, India³Maharashtra Institute of Medical Education and Research, Pune, Maharashtra, India⁴Department of Neurology, Vinayaka Neuro Multispecialty Clinic, Warangal, Telangana, India**Correspondence to**Dr Anirudda Deshpande,
dr.anirudda.deshpande@gmail.com

Accepted 16 March 2018

SUMMARY

We report a 27-year-old woman, a known case of classical migraine headache, on oral contraceptive pills. She had a severe episode of migraine with visual aura attack, which continued late into the night. The next early morning, her headache persisted and she developed abrupt onset of dysarthria, right hemiparaesthesias. She attributed symptoms to her long-standing headache problem, and hence did not seek medical help for the next two weeks. The symptoms persisted despite her headache subsiding over the next 24 hours. She worsened 2 weeks later during another such episode of headache. This time, she developed right hemiparesis. The patient was admitted with provisional diagnosis of stroke. MRI of the brain showed left temporoparietal lesion and was radiologically compatible with cortical laminar necrosis. Extensive work-up was done to rule out other causes of young stroke. The patient improved with antiplatelets, antimigraine prophylaxis and stroke rehabilitation therapy.

BACKGROUND

Cortical laminar necrosis (CLN) is a less common form of infarction where there is a selective pan-necrosis of cerebral cortex comprising glia, neuron and blood vessels with relative or absolute sparing of underlying white matter. It is frequently associated with hypoglycaemic or hypoxic encephalopathy, in some cases of status epilepticus. It is rarely associated with migrainous infarction.

CASE PRESENTATION

We report a 27-year-old female patient, with history of hemicranial headaches since her adolescence.

Often, the episode of headache used to be preceded by visual perceptions of bright star-shaped objects ‘floating’ in front of her eyes. These symptoms usually lasted for a few minutes. Other associated features during the episodes of headache were photophobia, phonophobia and severe nausea. The episode of headache usually lasted more than 4–6 hours on an average, sometimes 1–2 days. She was never on any medication for migraine prophylaxis or triptans for acute episodes of migraine. She recalled her mother having episodes of such severe headaches on and off for many years. There was no history of alcohol, nicotine and narcotic substance abuse. On the evening before the fateful day, she had a prolonged episode of migraine (preceded by visual aura) which continued into early next morning for 24–36 hours. With ongoing headache, she developed dysarthria along with paraesthesias of right half of the body, a day after the onset of her headache. She did not seek medical help for 2 weeks. On experiencing weakness in right upper and lower limb after 2 weeks from the primary event, she decided to visit the hospital. On examination, vitals were normal and her National Institutes of Health Stroke Scale was 4, suggestive of minor stroke.

Her Rankin scale was +2 as she had slight disability such that she was unable to carry out all previous activities, but able to look after her own affairs without assistance. The patient also had left upper motor neuron facial paralysis, left pronator sign. There was no evidence of neck stiffness. Clinical diagnosis of cerebrovascular accident was made. MRI of the brain showed gyral enhancement in the left temporoparietal region (figures 1–3). The patient was extensively evaluated for various causes leading to stroke in young; however, these tests were negative. The patient responded favourably to antiplatelet medication and antimigraine medication.

INVESTIGATIONS

Chest roentgenography, 12-lead electrocardiography, two-dimensional echocardiography, bilateral carotid Doppler, routine haematological screening, routine biochemical profile, urinalysis, serology for syphilis, HIV, ELISA, immunological blood tests (extractable nuclear antigen, antinuclear antibodies, lupus anticoagulant, IgG and IgM anticardiolipin antibodies, rheumatoid factor) and procoagulant panel (protein C&S, antithrombin 3, factor V Leiden mutation and homocysteine).

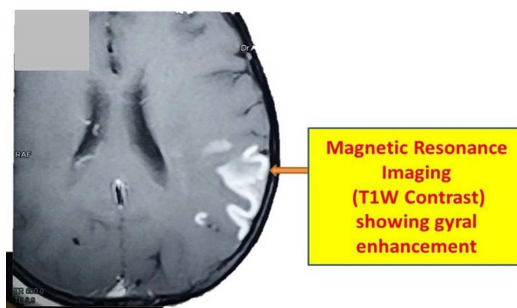


Figure 1 MRI of the brain with contrast (axial view) showing gyral enhancement in the left temporoparietal area, suggestive of cortical laminar necrosis.

Check for updates

To cite: Khardenavis V, Karthik DK, Kulkarni S, et al. *BMJ Case Rep* Published Online First: [please include Day Month Year]. doi:10.1136/bcr-2017-221483

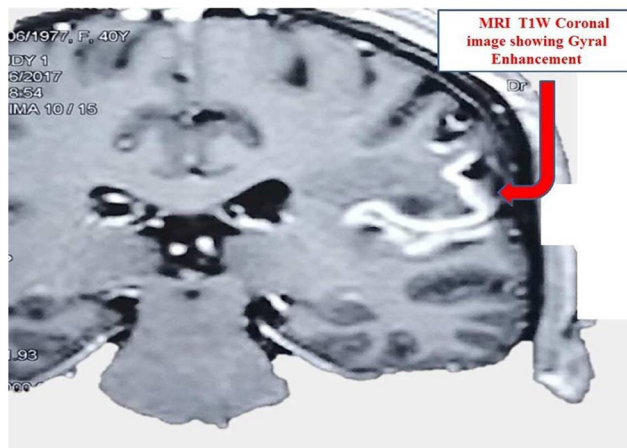


Figure 2 MRI of the brain with contrast (coronal view) showing gyral enhancement in the left temporoparietal area, suggestive of cortical laminar necrosis.

DIFFERENTIAL DIAGNOSIS

Demyelinating lesion, space-occupying lesion and venous infarct secondary to cerebral venous thrombosis.

TREATMENT

Antiplatelet medication (aspirin) 150 mg once daily in the afternoon (after lunch), antimigraine medication (topiramate 25 mg twice daily, flunarizine 10 mg once daily, naproxen 500 mg if needed).

OUTCOME AND FOLLOW-UP

The patient responded favourably to antiplatelet medication, antimigraine medications and physiotherapy.

DISCUSSION

Migraine headache is a known yet less common cause of stroke in young. Little is known about the exact demographics, and statistical association between CLN and migrainous stroke is not known; however, such previous study, with data extrapolated over 19 years, shows that only 10 of the 3808 consecutive

patients with stroke fulfilled the necessary criteria for migrainous stroke and amounts to roughly 0.26% of total cases.¹

Ischaemic strokes are more common than intracranial bleeds. Around 40% of the cases had an active migraine attack while they had the stroke.² Classical migraine (with aura) is more predisposed to vascular insufficiency than those who have simple migraine headache.³ The exact pathophysiology of migrainous infarction is not known. However, some of the possible mechanisms include vascular changes related to cortical spreading depression vasospasm and hypercoagulability.^{4 5} Oxidative stress-induced endothelial dysfunction may be a cause and effect of migraine, leading to stroke.⁶ Migrainous stroke presenting radiologically as CLN has been infrequently reported.^{7 8} CLN has been noted in cases with metabolic disturbances, cerebral hypoxia, drugs and infections. Potential mimickers for such clinical presentation are mitochondrial encephalopathy, lactic acidosis and stroke-like episodes, Fabry's disease and 'arterial dissection'. The radiological findings in CLN show cortical hyperintensity on T1-weighted images, usually from 2 weeks to approximately 2 years after ischaemia. Fluid-attenuated inversion recovery hyperintensities appear later in the course of illness. The curvilinear 'gyriform' enhancement on gadolinium contrast is attributed to breakdown of the blood–brain barrier necrosis of the blood vessels.⁹ Migrainous infarcts causing CLN could be explained theoretically that the endothelial dysfunction can in turn lead to breakdown of the blood–brain barrier.¹⁰

Learning points

- ▶ Migrainous infarction is a less common, but important cause of 'stroke in young'.
- ▶ Migrainous infarcts present as cortical laminar necrosis, an infrequent radiological finding.
- ▶ Vascular changes related to cortical spreading depression vasospasm and hypercoagulability are some of the possible mechanisms postulated to cause migrainous infarct.

Contributors VK and DKK made substantial contributions to the conception and design of the work, acquisition, analysis and interpretation of the data. AD and SK was involved in drafting the work and revising it critically for important intellectual content. All authors approved the final version to be published.

Funding The authors have not declared a specific grant for this research from any funding agency in the public, commercial or not-for-profit sectors.

Competing interests None declared.

Patient consent Obtained.

Provenance and peer review Not commissioned; externally peer reviewed.

© BMJ Publishing Group Ltd (unless otherwise stated in the text of the article) 2018. All rights reserved. No commercial use is permitted unless otherwise expressly granted.

REFERENCES

- 1 Liang Y, Scott TF. Migrainous infarction with appearance of laminar necrosis on MRI. *Clin Neurol Neurosurg* 2007;109:592–6.
- 2 Chang CL, Donaghy M, Poulter N. Migraine and stroke in young women: case-control study. *BMJ* 1999;318:13–18.
- 3 Tzourio C, Tehindrazanarivelo A, Iglésias S, *et al*. Case-control study of migraine and risk of ischaemic stroke in young women. *BMJ* 1995;310:830–3.
- 4 Kurth T. Migraine and ischaemic vascular events. *Cephalalgia* 2007;27:965–75.
- 5 Tietjen EG. Migraine and ischaemic heart disease and stroke: potential mechanisms and treatment implications. *Cephalalgia* 2007;27:981–7.
- 6 Bousser MG, Welch KM. Relation between migraine and stroke. *Lancet Neurol* 2005;4:533–42.
- 7 Kinoshita T, Ogawa T, Yoshida Y, *et al*. Curvilinear T1 hyperintense lesions representing cortical necrosis after cerebral infarction. *Neuroradiology* 2005;47:647–51.
- 8 Arboix A, Massons J, García-Eroles L, *et al*. Migrainous cerebral infarction in the Sagrat Cor Hospital of Barcelona stroke registry. *Cephalalgia* 2003;23:389–94.

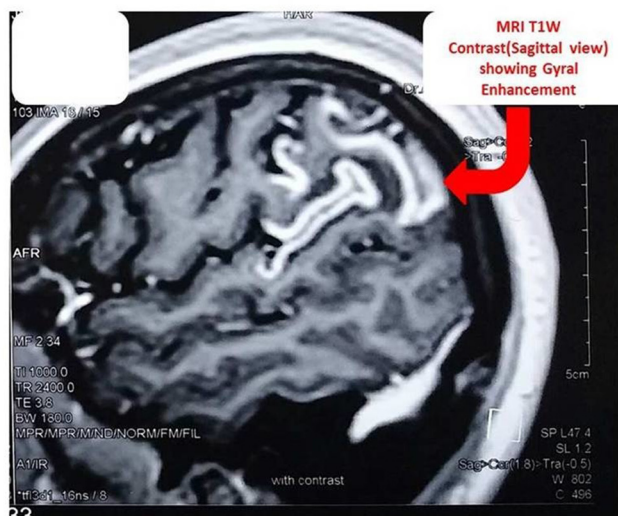


Figure 3 MRI of the brain with contrast (sagittal view) showing gyral enhancement in the left temporoparietal area, suggestive of cortical laminar necrosis.

9 Arboix A, González-Peris S, Grivé E, *et al.* Cortical laminar necrosis related to migrainous cerebral infarction. *World J Clin Cases* 2013;1:256–9.

10 Abbott NJ, Rönnbäck L, Hansson E. "Astrocyte–endothelial interactions at the blood–brain barrier". *Nature Reviews Neuroscience* 2006;7.1:41–53.

Copyright 2018 BMJ Publishing Group. All rights reserved. For permission to reuse any of this content visit <http://group.bmj.com/group/rights-licensing/permissions>.
BMJ Case Report Fellows may re-use this article for personal use and teaching without any further permission.

Become a Fellow of BMJ Case Reports today and you can:

- ▶ Submit as many cases as you like
- ▶ Enjoy fast sympathetic peer review and rapid publication of accepted articles
- ▶ Access all the published articles
- ▶ Re-use any of the published material for personal use and teaching without further permission

For information on Institutional Fellowships contact consortiasales@bmjgroup.com

Visit casereports.bmj.com for more articles like this and to become a Fellow