


Accepted Manuscript

Endovascular recanalization of occluded dural sinus in a patient with dural arteriovenous fistulas: case report and literature review

Kun Zhang, Bu-Lang Gao, Liang-Fu Zhu, Jiang-Yu Xue, Bo-Wen Yang, Tian-Xiao Li



PII: S1878-8750(18)30622-3

DOI: [10.1016/j.wneu.2018.03.140](https://doi.org/10.1016/j.wneu.2018.03.140)

Reference: WNEU 7752

To appear in: *World Neurosurgery*

Received Date: 8 January 2018

Revised Date: 19 March 2018

Accepted Date: 20 March 2018

Please cite this article as: Zhang K, Gao B-L, Zhu L-F, Xue J-Y, Yang B-W, Li T-X, Endovascular recanalization of occluded dural sinus in a patient with dural arteriovenous fistulas: case report and literature review, *World Neurosurgery* (2018), doi: 10.1016/j.wneu.2018.03.140.

This is a PDF file of an unedited manuscript that has been accepted for publication. As a service to our customers we are providing this early version of the manuscript. The manuscript will undergo copyediting, typesetting, and review of the resulting proof before it is published in its final form. Please note that during the production process errors may be discovered which could affect the content, and all legal disclaimers that apply to the journal pertain.

Endovascular recanalization of occluded dural sinus in a patient with dural arteriovenous fistulas: case report and literature review

Authors: Kun Zhang*, Bu-Lang Gao*, Liang-Fu Zhu, Jiang-Yu Xue, Bo-Wen Yang,
Tian-Xiao Li

*These two authors contributed equally to this work.

Affiliations:

Henan Provincial People's Hospital

Henan University

7 Weiwu Road

Zhengzhou

Henan Province, China 450003

Corresponding author:

Tian-Xiao Li

litianxiaod@163.com

Department of Interventional Therapy

Henan Provincial People's Hospital

Zhengzhou University

7 Weiwu Road

Zhengzhou, Henan Province, China 450003

ABSTRACT

Symptomatic sinus occlusion complicated with dural arteriovenous fistulas (dAVFs) can be treated endovascularly with occlusion of the fistula. No studies have reported the use of endovascular transvenous approaches alone to recanalize the occluded sinuses for the treatment of the involved dAVFs without stent deployment. In this study, we presented a 75-year-old man with occlusion of the transverse and sigmoid sinuses complicated with a dAVF. Balloon angioplasty was used to recanalize the occluded sinuses resulting in good effects. The symptoms disappeared after endovascular recanalization of the occluded left transverse sinus and sigmoid sinuses, and follow-up magnetic resonance imaging venography revealed opened sinuses with complete disappearance of the dAVF.

Key words: Dural arteriovenous fistula, Sinus occlusion, Angiography, Balloon angioplasty, Recanalization

Introduction

Approximately 5% of cranial arteriovenous shunts are originated in the dural coverings. The major etiologies may include smoking history, thrombosis of venous sinuses, oral contraception, radical neck dissection or radiation for head and neck cancers. Most (62%) of the dural arteriovenous fistulas (dAVFs) are located in the transverse and sigmoid sinuses (1-6). Venous hypertension plays a key role in the physiologic mechanism in the development of clinical symptoms. Tinnitus, focal neurologic deficits, headaches or global cognitive impairment may be present in these patients. Intracranial bleeding may be at a risk of 10%-65% when cortical venous reflux is present (7). dAVFs complicated with intracranial venous sinus occlusion are rare and have to be managed timely to prevent further severe complications from happening. Various endovascular approaches have been employed including endovascular venous sinus coil occlusion of the fistula. However, no studies in the literature performed recanalization of the venous sinuses to treat the dAVFs associated with venous sinus occlusion through transvenous approach only without use of stent deployment. In this study, we presented a case of dAVF associated with occlusion of the transverse and sigmoid sinuses. Instead of embolizing the fistula feeders to reduce flow into the fistula and occlusion of the sinus in its fistulous part, we aimed to re-open the occluded normal venous pathways by balloon angioplasty only for the treatment of the fistula.

Case report

A 75-year-old male patient suffered intermittent headache, nausea and vomiting in July 2015. He suddenly developed seizures and hemiplegic paralysis on September 3, 2015, which lasted for about 2 minutes and was relieved spontaneously with the left limb remaining hypermyotonia for 30 minutes. There was no history of trauma or surgery. He was diagnosed as brain tumor initially by a local hospital and received conservative treatment of medication including dehydration, antiexndation and proton pump inhibitor. The therapeutic effects were poor, and progressive neurological

deterioration occurred. Neurological examination revealed mildly decreased motor function in grade-IV in the left limb. No other anomalies were revealed. Physical examination revealed deep tendon reflexes of the knees and ankle jerks. The intracranial pressure by lumbar puncture was 300 mm H₂O. Magnetic resonance imaging (MRI) venography disclosed sinus occlusion and dAVFs accounting for encephaledema (Figure 1A). Cerebral angiography revealed occlusion of the left transverse and sigmoid sinuses and cortical reflux with the sinus junction unobstructed (Figure 2A). The feeding arteries of the left transverse sinus dAVFs were muscular branches of the left vertebral artery and the external carotid artery (Figure 2A and B), and the draining vein was from the superior sagittal sinus to the contralateral transverse sinus.

The patient was treated with endovascular recanalization of the occluded transverse and sigmoid sinuses by mechanical cracking (pulling a microcatheter back and forth) in combination with balloon dilatation. Partial obliteration of the dAVFs near the occluded sinus was evident by cerebral angiography after dilation with a Rial 6mm×40mm Balloon (Rival, Bard Inc, Covington, GA, USA) in the left transverse sinus (Figure 2C), and an Avitor 5mm×30mm Balloon (Aviator, Cordis Inc, Europa, NV, USA) was used to repeatedly dilate the left sigmoid sinus. Then, cerebral angiography demonstrated recanalization of the left venous sinus and disappearance of the dAVF, and no complications occurred. Contrast injection of the left internal carotid artery revealed complete recanalization of the occluded sinuses and decreased flow through the fistula. Headache and hypermyotonia improved post-operation, and transient motor weakness with the motor function being in grade III remained in the left limbs within 48 hours but recovered completely one week later. Two months later, neurological examination revealed no deficits, MRI venography showed complete recanalization of the sinuses and obliteration of messy draining venous plexuses (Figure 1D), and the patient was asymptomatic.

Discussion

It has been proposed that a dAVF may develop as a result of sinus occlusion due to opening up of small physiological arteriovenous pathways in the wall of the sinus

or abnormal connections formed during recanalization (2, 3). Intracranial venous sinus occlusion is considered an independent pathological factor for dAVFs (1). To re-establish antegrade flow and eliminate venous hypertension in the sinus and cortical veins, it is important to recanalize the ipsilateral transverse sinus and sigmoid sinus. Intracranial venous sinus occlusion complicated with dAVFs is mostly acute or subacute with the primary clinical manifestations of increased intracranial pressure, epilepsy, focal nerve function deficit, consciousness and mental disorders, and obvious murmur can be heard in patients with the lesion close to the petrous bone. Here, we described a type III dAVF (4), which had retrograde cortical venous drainage, without antegrade flow through the normal venous pathways. In cases of such high grade fistula, the annual mortality rate is 10.4% with the annual risk for haemorrhagic morbidity of 8.1% (6). Occlusion of the left transverse and sigmoid sinuses might be the cause of the dAVF, and cerebral angiography displayed dAVFs distributing near the left transverse sinus. Increased intracranial pressure and blood steal caused by arteriovenous fistulas might be the causes for brain edema. The structure of intracranial venous sinuses is usually asymmetric (8, 9), and when a main dural sinus is occluded, venous drainage in the contralateral transverse sinus may develop decompensation. In the cases of multiple causes, intracranial venous sinus pressure elevation and local pressure imbalance are more likely to occur. This may be another possible reason for development of the dAVF, and abnormal dilation of dAVFs and vasoganglion may be the result of long-term venous sinus high pressure transmission (10).

The venous drainage of dAVFs may determine the clinical symptoms and risk of bleeding, and high venous pressure can bring about a series of neurological dysfunctions including cognitive dysfunction. In treatment of sinus occlusion involving dAVFs, the sinus drainage of cerebrum should be stressed besides feeding arteries of dAVFs. Proper treatment can induce immediate changes in arterial supply and abnormal venous flow of the dAVF together with changes in clinical symptoms. Reduction of shunt flow from the external carotid artery and the muscular branches of the left vertebral artery was observed at angiography during treatment in our case, and

this change in flow dynamics might be important in the process of spontaneous obliteration of dAVFs. After stent deployment in the venous system, the patient should be medicated with long-term anticoagulation for prophylaxis, or else progressive neurological deterioration or severe disability after initial intracranial bleeding may occur. In our study, only balloon dilatation was adopted for recanalization, however, postoperative venous sinus occlusion may occur after balloon dilation. Mori et al (5) report a case with occluded sinus complicated with dAVF which was managed conservatively with glyceol and anticonvulsants for four weeks and eventually recovered, which was confirmed by cerebral angiography 10 months after onset with complete recanalization of the previously occluded sinus and disappearance of the dAVFs. They believed that sinus occlusion was caused by high arterial flow to the fistula, and disappearance of high arterial flow made recanalization of the occluded sinus possible. In the study by Choi et al (1), a stent graft with or without transarterial embolization to preserve venous sinus flow was used as an effective treatment. In the study by Levrier et al (10) who presented 10 consecutive patients with transverse and/or sigmoid sinus dAVFs with or without sinus thrombosis, complete recovery or significant clinical improvement was achieved in all patients with no severe or permanent complications after stenting or balloon angioplasty. In the four patients with dAVFs of the transverse and sigmoid sinus treated with transvenous angioplasty and stent deployment as a definitive therapy reported by Liebig et al (11), three patients had complete occlusion of the fistula, and the last one patient had a negligible and nonsymptomatic remnant of the fistula fed by the tentorial artery which was left untreated. They concluded that transvenous stent deployment is an alternative to traditional concepts. Weber et al (12) reported clinical improvement in a patient with occluded transverse sinus complicated with multiple dAVFs which was treated with mechanical recanalization by angioplasty. The treatment of dAVFs is complex and challenging, and the use of combined approaches seems to achieve better clinical outcomes. A clinical 'cure' may be achieved by endovascular approaches through the venous route for the dAVFs with the physiological structures of the venous sinus preserved (13, 14). In our case, the dAVF is probably caused by occlusion of the dural

sinuses, and consequently, the therapeutic goal is to improve venous drainage of the normal brain tissue. We used the transvenous endovascular approach focusing on recanalization of venous sinuses without additional transarterial embolization, which significantly ameliorated the clinical symptoms and proved the importance of maintaining normal venous outflow. Changes of flow in the sinus affect not only spontaneous closure of the dAVFs but also relief of encephaledema. Sinus occlusion can promote development of intradural vascular networks, resulting in arteriosinus communication and dAVFs (15), whereas pressure decrease in the sinuses may prevent occurrence of new dAVFs (12).

In our study, we used only mechanical crushing of thrombosis within the sinuses. For dAVFs complicated with thrombosed sinuses, another option is to use stenting with stents placed within the sinuses after the sinuses have been recanalized so as to obliterate the dAVFs (7, 12, 13). Murphy et al (7) reported successful use of balloon angioplasty and placement of six overlapping stents extending from the transverse sinus to the proximal internal jugular vein for the treatment of a case with type IV dAVF of the left transverse sinus with widespread white matter changes secondary to venous hypertension. Ohara et al (13) presented a case report of successful stenting treatment of dAVF involving the superior sagittal sinus combined with occluded sinuses. Weber et al (12) used angioplasty and stent deployment for the treatment of a case with bilaterally thrombosed transverse sinuses and a dAVF causing cortical venous reflux. Anticoagulant therapy is often needed to prevent formation of thrombus after stent implantation in the venous system, but antiplatelet therapy is also effective. So, anticoagulation or antiplatelet therapy is important after stenting as an option for recanalization of the thrombosed sinuses.

In conclusion, endovascular recanalization may be a better alternative therapy for selected patients with dural arteriovenous fistulas complicated by sinus occlusion, however, further studies are needed to confirm the effects and safety.

References

1. Choi BJ, Lee TH, Kim CW, Choi CH. Reconstructive treatment using a stent graft for a dural arteriovenous fistula of the transverse sinus in the case of hypoplasia of the contralateral venous sinuses: Technical case report. *Neurosurgery* 2009;65:E994-996; discussion E996
2. Cognard C, Gobin YP, Pierot L, Bailly AL, Houdart E, Casasco A et al. Cerebral dural arteriovenous fistulas: Clinical and angiographic correlation with a revised classification of venous drainage. *Radiology* 1995;194:671-680
3. Huo X, Li Y, Jiang C, Wu Z. Balloon-assisted endovascular treatment of intracranial dural arteriovenous fistulas. *Turkish neurosurgery* 2014;24:658-663
4. Malek AM, Halbach VV, Higashida RT, Phatouros CC, Meyers PM, Dowd CF. Treatment of dural arteriovenous malformations and fistulas. *Neurosurgery clinics of North America* 2000;11:147-166, ix
5. Mori F, Gotoh H, Sasanuma J, Gotoh T, Ogayama H, Koizumi J et al. [recanalization of dural sinus occlusion following the disappearance of dural arteriovenous fistula: Report of a case]. *No shinkei geka. Neurological surgery* 1996;24:631-636
6. van Dijk JM, terBrugge KG, Willinsky RA, Wallace MC. Clinical course of cranial dural arteriovenous fistulas with long-term persistent cortical venous reflux. *Stroke* 2002;33:1233-1236
7. Murphy KJ, Gailloud P, Venbrux A, Deramond H, Hanley D, Rigamonti D. Endovascular treatment of a grade iv transverse sinus dural arteriovenous fistula by sinus recanalization, angioplasty, and stent placement: Technical case report. *Neurosurgery* 2000;46:497-500; discussion 500-491
8. Gutierrez A, Do HM, Marks MP. Alteration in the venous drainage of a dural arteriovenous fistula following angioplasty. *AJNR. American journal of neuroradiology* 2004;25:1086-1088
9. Hamada Y, Goto K, Inoue T, Iwaki T, Matsuno H, Suzuki S et al. Histopathological aspects of dural arteriovenous fistulas in the transverse-sigmoid sinus region in nine patients. *Neurosurgery* 1997;40:452-456; discussion 456-458
10. Levrier O, Metellus P, Fuentes S, Manera L, Dufour H, Donnet A et al. Use of a self-expanding stent with balloon angioplasty in the treatment of dural arteriovenous fistulas involving the transverse and/or sigmoid sinus: Functional and neuroimaging-based outcome in 10 patients. *Journal of neurosurgery* 2006;104:254-263
11. Liebig T, Henkes H, Brew S, Miloslavski E, Kirsch M, Kuhne D. Reconstructive treatment of dural arteriovenous fistulas of the transverse and sigmoid sinus: Transvenous angioplasty and stent deployment. *Neuroradiology* 2005;47:543-551
12. Weber W, Kis B, Esser J, Berlit P, Kuhne D. Endovascular treatment of a dural arteriovenous fistula of the transverse sinus by recanalisation, angioplasty and stent deployment. A case report and follow-up. *Interventional neuroradiology* :

- journal of peritherapeutic neuroradiology, surgical procedures and related neurosciences 2003;9:65-69
13. Ohara N, Toyota S, Kobayashi M, Wakayama A. Superior sagittal sinus dural arteriovenous fistulas treated by stent placement for an occluded sinus and transarterial embolization. A case report. *Interventional neuroradiology : journal of peritherapeutic neuroradiology, surgical procedures and related neurosciences* 2012;18:333-340
 14. Troffkin NA, Graham CB, 3rd, Berkmen T, Wakhloo AK. Combined transvenous and transarterial embolization of a tentorial-incisural dural arteriovenous malformation followed by primary stent placement in the associated stenotic straight sinus. Case report. *Journal of neurosurgery* 2003;99:579-583
 15. Phatouros CC, Halbach VV, Dowd CF, Lempert TE, Malek AM, Meyers PM et al. Acquired pial arteriovenous fistula following cerebral vein thrombosis. *Stroke* 1999;30:2487-2490

Figures and legends

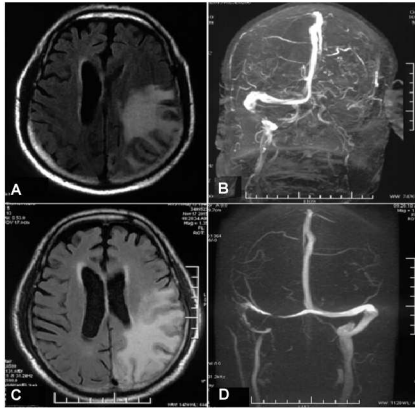


Fig 1: A&B. Magnetic resonance image (MRI) of the patient on admission. Brain edema and compression of the left ventricula were shown (A), and MRI venography showed occlusion of the transverse and sigmoid sinuses (B). C. Postoperative MRI demonstrated diminished brain edema and the left ventricula which was not compressed (C). D. MRI venography two months later showed that the sinuses were completely recanalized and that messy draining venous plexuses were completely obliterated.

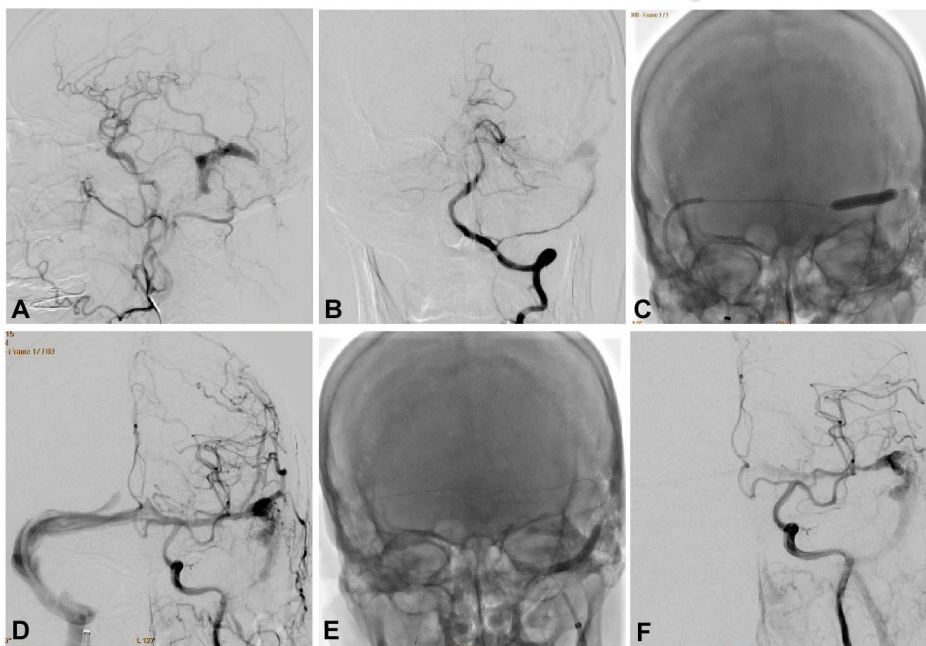


Fig.2. A&B. The dural arteriovenous fistula (dAVF) was supplied by branches of the external carotid (A) and left vertebral arteries (B). C&D. A Rial 6mm×40mm balloon was used for dilatation in the left transverse sinus (C). Left common carotid angiography after the predilatation in the left transverse sinus showed recanalization of the left transverse sinus with partial disappearance of the dAVF shunting. E. An Avitor 5mm×30mm balloon was used for dilatation in the sigmoid sinus (E). F. Final angiography of the left common carotid artery injection at the end of the procedure showed restoration of normal antegrade flow in the initially occluded sinuses and improved flow in the transverse/sigmoid sinuses with decreased shunting.

Highlights

1. Venous sinus occlusion complicated with dural arteriovenous fistulas can be successfully recanalized endovascularly.
2. Recanalization of the occluded sinuses may be a better alternative to occluding the fistula arterial feeders for the treatment of venous sinus occlusion complicated with dural arteriovenous fistulas.

Abbreviations

DAVFs: dural arteriovenous fistulas

MRI : Magnetic resonance imaging

ACCEPTED MANUSCRIPT

Disclosure of conflict of interest

The authors declared that they have no conflict of interest in publication of this article.

ACCEPTED MANUSCRIPT