

# Cavernous Sinus Aneurysm Associated With Cerebellar Hemangioblastoma in an Adult With von Hippel-Lindau Disease

Hui Zhou, MD, Shuo Sun, MD, Hui Shi, MD, and Kui Ma, MD

**Abstract:** A case of cerebellar hemangioblastoma with von Hippel-Lindau disease and an aneurysm of the cavernous sinus segment of the internal carotid artery is presented here. A 60-year-old woman presented with a cerebellar solid tumor manifesting as headache of 4 months, progressive vomiting, and ataxia of half a month. Four-vessel angiography revealed a high stain mass tumor located in the posterior fossa; an aneurysm on the cavernous sinus segment of the internal carotid artery was demonstrated at the same time. The ipsilateral anterior inferior cerebellar artery (AICA) and posterior inferior cerebellar artery (PICA) branches were the main feeding vessels of the hemangioblastoma. The patient underwent left-lateral suboccipital craniectomy to remove the highly vascular hemangioblastoma. Successful total excision of the tumor was demonstrated on postoperative magnetic resonance (MR) images. The unruptured cavernous sinus aneurysm in this case was not on the feeding artery, which was asymptomatic and has not been treated further. The patient was in good condition in 1-year follow-up.

**Key Words:** Cavernous sinus, cerebellum, hemangioblastoma, internal carotid artery, intracranial aneurysm

A cerebral aneurysm associated with a brain tumor is rare. Cerebral aneurysms have been reported in patients with cerebral lesions such as meningiomas, pituitary adenomas, other brain tumors, and vascular malformations.<sup>1</sup> To the best of our knowledge, however, only 6 cases of coexisting intracranial aneurysm and cerebellar hemangioblastoma other than the 1 presented here have been reported in the literature (Table 1).<sup>2</sup>

In the present article, we report on a patient with an aneurysm of the cavernous sinus segment of the internal carotid artery associated with a cerebellar hemangioblastoma with von Hippel-Lindau disease.

## CLINICAL REPORT

### History

A 60-year-old woman consulted after 4 months of headache, progressive development and vomiting, and gait ataxia for half a month. After examination and MR imaging studies, a posterior

From the Department of Neurosurgery, Lianyungang Hospital, Affiliated to Xuzhou Medical University, Lianyungang, China.

Received January 22, 2018.

Accepted for publication February 13, 2018.

Address correspondence and reprint requests to Kui Ma, MD, Department of Neurosurgery, Lianyungang Hospital, Affiliated to Xuzhou Medical University, Hai Zhou District, Lianyungang, China;

E-mail: 17714156318@163.com

HZ and SS contributed equally to this article.

The authors report no conflicts of interest.

Copyright © 2018 by Mutaz B. Habal, MD

ISSN: 1049-2275

DOI: 10.1097/SCS.0000000000004545

fossa tumor with slightly secondary obstructive hydrocephalus was diagnosed. One elder brother of the patient was diagnosed as brainstem hemangioblastoma and operated 10 years before. Furthermore, 1 elder sister of the patient was diagnosed as giant hepatic cavernous hemangioma and operated 8 years before. They were all confirmed through histological diagnosis. Family history for VHL disease was demonstrated.

### Physical Examination

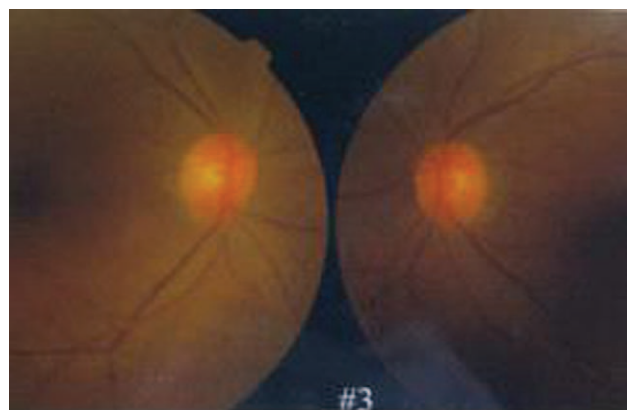
On neurological examination, the ocular funduscopy showed no presence of angiomatous change (Fig. 1), the 24-h urine test was within normal ranges. Abdominal ultrasonography revealed hepatic cysts, the biggest one located on the right hepatic lobe, its size being  $2.1 \times 1.2 \text{ cm}^2$ . The other abdominal organs were unremarkable. So its Melmon and Rosen clinical criteria for VHL diagnosis were found.<sup>3</sup> No genetic analysis of the VHL gene was performed because of technical limitations in our center at that time.

### Imaging Examination

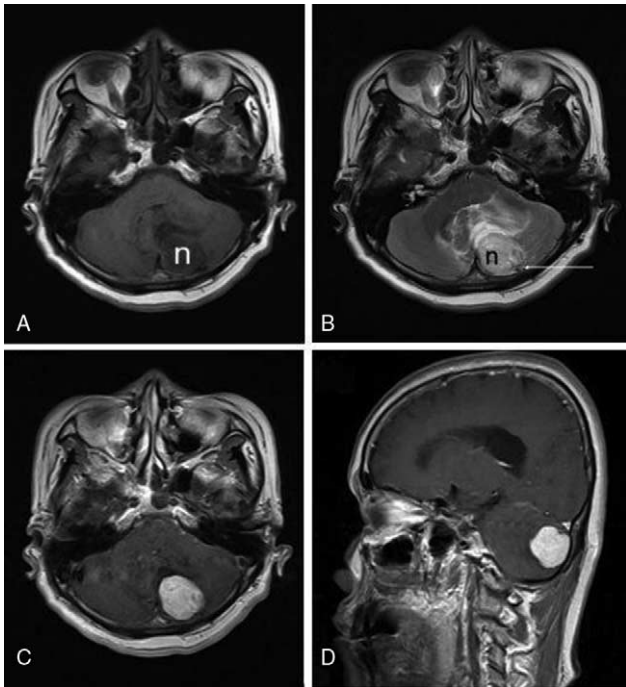
MRI revealed a solid lesion in the posterior fossa, exerting compression on the cerebellum and the 4th ventricle (Fig. 2). On T1WI, the mass lesion displayed isointense to the brain (Fig. 2A). On T2WI, the mass appeared hyperintense to the cerebellum (Fig. 2B). T1WI after gadolinium administration showed highly intense mass enhancement (Fig. 2C and D). MRI demonstrated compression and displacement of the 4th ventricle by the mass effect (Fig. 2A-C). Both T2WI and T1WI after gadolinium-enhanced images showed flow voids within and peritumoral of the mass lesion from prominent vessels (Fig. 2B-D). Complete CNS gadolinium MRI study ruled out other HB. Four-vessel cerebral angiography confirmed the presence of a 3-cm-wide area of tumor neovascularly in the left cerebellar hemisphere that was diagnosed as a hemangioblastoma and was predominantly supplied by the left anterior inferior cerebellar artery (AICA) and the left posterior inferior cerebellar artery (PICA) (Fig. 3A and B). Left carotid angiography confirmed the presence of a  $1.1 \times 1.2 \text{ cm}^2$  large aneurysm of the cavernous sinus segment of the internal carotid artery, which was not supplying the lesion (Fig. 3C-E).

### Evolution

The patient was planned for surgery. Based on the cavernous sinus aneurysm is unruptured and asymptomatic, the microsurgical treatment or endovascular embolization of the cavernous sinus aneurysms is difficult and challenging. Also, the aneurysm remains asymptomatic and the female patient refused further treatment, the aneurysm has not



**FIGURE 1.** The ocular funduscopy showed no presence of retinal disease and angiomatous change, the retinal vascular was normal.



**FIGURE 2.** Preoperative MRI. (A) Axial T1-weighted image showing the tumoral mass (*n*) isointense to the cerebellum and the relationship to its neighboring structures. See the mass compressing the 4th ventricle and displaying slightly more hyperintense than cerebrospinal fluid. (B) Axial T2-weighted image demonstrating the mass effect exerted by the solid tumor (*n*) on the cerebellum and the 4th ventricle, the peritumoral sheet edema and the lesion display more hyperintense than cerebellum, flow voids within and peritumoral (*white arrow*) of the mass lesion from prominent vessels. (C) Axial T1-weighted image with gadolinium enhancement showing the homogeneously enhanced lesion in the left cerebellum, flow voids within the mass lesion. (D) Sagittal T1-weighted image with gadolinium enhancement showing the homogeneously enhanced lesion in the left cerebellum, and its related to the cerebellar dura and transverse sinus.

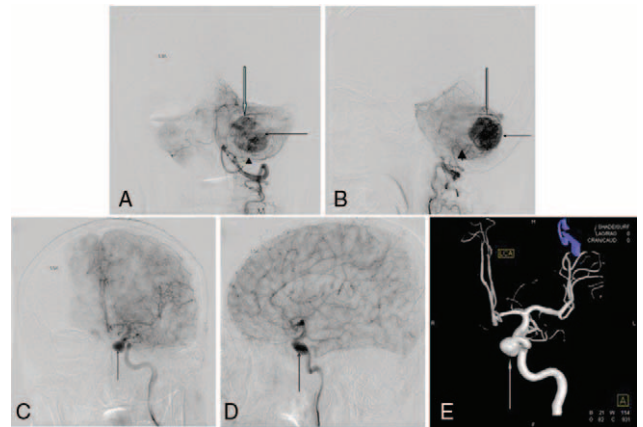
been interfered. Preoperative embolization was refused because of multiple small feeding arteries to the tumor a hazardous feature for the endovascular procedure.<sup>4</sup> Radiosurgery was also rejected due to the tumor size and its already symptomatic onset, and slightly secondary obstructive hydrocephalus caused by the mass lesion.

**Operation**

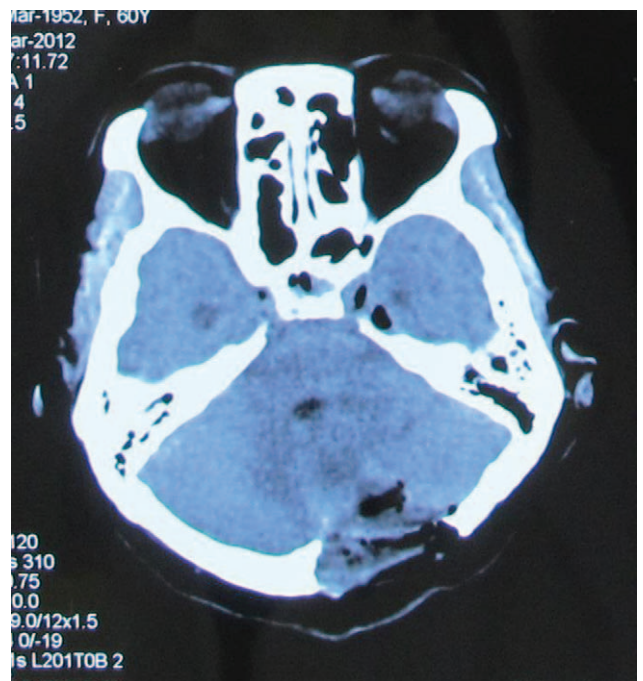
The patient was positioned in the park-bench position. Left suboccipital craniectomy was performed. The foramen magnum was removed. Gross total tumor removal under microsurgical technique was accomplished uneventfully. Great care was taken not to enter inside the solid tumor. Tumor appearance was dark reddish on naked-eye inspection, and the tumor nodule size was 3.0 × 3.0 × 2.7 cm<sup>3</sup>. The cerebellum was dilated after tumor removal; the bone flap was removed unroofly.

**Postoperative Course**

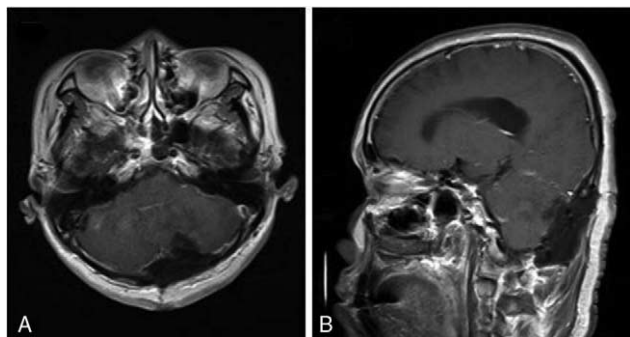
The postoperative course was uneventful. The patient woke up from anesthesia 6 hours after surgery later with complete recovery of consciousness and no limb weakness and normal respiration and gag reflex. Postoperative CT scan confirmed the complete removal of the lesion 24 hours after operation (Fig. 4). The patient was discharged with no neurological deficit on the 8th day after surgery, she was followed up on 3 to 6 months intervals, and was in good condition in 1-year follow-up. Postoperative MRI scan was conducted (Fig. 5A and B), which demonstrates that the untreated



**FIGURE 3.** Preoperative arteriography. (A) Left vertebral artery angiogram (anteroposterior-oblique view) showing the beginning of the capillary phase. A large tumor blush (*black arrow*) is demonstrated. Left AICA (*double white arrow*) and left PICA (*arrow head*), which originates from the ipsilateral vertebral artery, displays as the main feeding artery of the tumor. (B) Left vertebral artery angiogram (*lateral view*) showing the tumor blush (*black arrow*). The AICA (*white arrow*) and the PICA are shown as the feeding tumoral arteries. Venous phase is advanced on time, which is shown by the main draining trunk (*arrow head*) from the tumor to the ipsilateral jugular vein during the capillary phase. (C) Left internal carotid artery angiogram (anteroposterior view) showing the beginning of the capillary phase. A large cavernous internal carotid artery aneurysm (*black arrow*) is demonstrated, which size is 11 × 12 mm<sup>2</sup>, broad of its base is 4.7 mm, left anterior cerebral artery is double dries. (D) Left internal carotid artery angiogram (oblique view) showing the large cavernous internal carotid artery aneurysm (*black arrow*), a large unruptured cavernous internal carotid artery aneurysm is diagnosed. (E) Left internal carotid artery 3-dimensional reconstructed image (*lateral view*) showing the cavernous internal carotid artery aneurysm (*white arrow*), left internal carotid artery and its branches.



**FIGURE 4.** Postoperative CT scan showing the total resection of the tumor, slightly cerebellar edema compressing the 4th ventricle, CSF in the 4th ventricle can be seen, furthermore, defected bone flap can be seen.



**FIGURE 5.** Postoperative MRI scan. (A) Axial T1-weighted image with gadolinium enhancement. (B) Sagittal T1-weighted image with gadolinium enhancement, they all showing complete tumor removal, no residual tumor enhancement and re-expansion of the cerebellar hemisphere are well visualized.

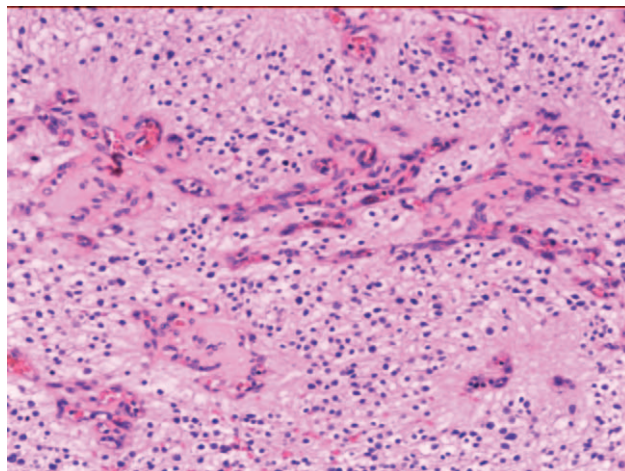
cavernous sinus aneurysm of the left internal carotid artery had intervals of stable size (as demonstrated on serial CTA imaging studies), and showed no clinical change.

### Pathology

The pathology report demonstrated hemangioblastoma (WHO grade I) with prominent capillary blood vessels intermingled with a rich population of foaming stromal cells. These stromal cells displayed epithelioid appearance with clear cytoplasm. No necrosis, pleomorphism, or abnormal mitoses were observed. Stromal cells displayed positive enhancement for neuro-specific enolase (Fig. 6). Immunohistochemistry-stain results the capillary network enhanced positively for CD-34 marker, for EMA marker cells can be seen occasionally. While negative enhancement for CK, GFAP, CD-68. This histological pattern was consistent with the diagnosis of transitional type hemangioblastoma, described by Vates.<sup>5</sup>

### DISCUSSION

Association of a cerebral aneurysm with an intracranial tumor is rare.<sup>1</sup> The first case was reported by Yoshii on a cerebellar hemangioblastoma with a coexistent cerebral aneurysm in 1976.<sup>6</sup> Since then, only 6 cases involving a hemangioblastoma coexisting aneurysm have been reported (Table 1). The patients were aged 50 to 72 years (mean 55 years). Only 1 patient had initial clinical symptoms due to hemangioblastoma and subsequent clinical symptoms caused by SAH from cerebral aneurysm, in all cases the initial clinical symptoms caused by the hemangioblastoma.<sup>2,7</sup> Angiography revealed 3 cases of aneurysms were located on the main feeding artery of the hemangioblastomas, other 4 cases of aneurysms did not arise from the artery feeding the hemangioblastomas.



**FIGURE 6.** Histological sample with hematoxylin-eosin (H&E) stain. Histological picture of the HB (H&E, × 400), composed by numerous stromal cells with clear and vacuolated cytoplasm, focal nuclear atypias, and intermingled capillary vessels, steady staining and positive staining for stromal cells.

Hemangioblastomas are tumors of the central nervous system (CNS) that constitute approximately 1% to 2% of all intracranial tumors and 7% to 12% of all posterior fossa tumors.<sup>8</sup> They can develop in any portion of the CNS, but the most common site is the cerebellum. Approximately, 75% of hemangioblastomas are found as sporadic lesions, whereas 25% are a manifestation of the hereditary von Hippel–Lindau disease.<sup>8</sup> Extensive progress has been made in determining the genetic cause of sporadic and VHL-associated CNS hemangioblastomas. The gene mutated in autosomal dominant VHL syndrome has been identified and is located on chromosome 3p25–26. This gene is a tumor suppressor and is thought that the VHL protein mechanism of action involves inhibition of transcriptional elongation through interaction with the elongation B and C proteins.<sup>8</sup> According to VHL syndrome, in addition to CNS hemangioblastomas, other manifestations of VHL syndrome include retinal hemangioblastomas, renal and pancreatic cysts, renal carcinoma, hepatic cysts, pheochromocytoma, pancreatic islet cell tumors, endolymphatic sac tumors, and papillary cystadenoma of the epididymis.<sup>9,10</sup>

### Presentation

Coexistence of intracranial aneurysm and hemangioblastoma was observed in 7 patients. Sporadic hemangioblastomas were observed in 5 patients (71%), 2 (29%) of 7 patients with VHL

**TABLE 1.** Reported Cases of Coexisting Hemangioblastoma and Cerebral Aneurysm

Author (Year)	Age/Sex	Site of Aneurysm	Site of Hemangioblastoma	Feeder of Hemangioblastoma	Cause of Symptoms
Yoshii et al. (1976)	50/F	BA bifurcation, It ICA terminal	It cerebellar hemisphere	It PICA	tumor, SAH from aneurysm
Ueno et al. (1977)	50/F	It ICA	It cerebellar hemisphere	It PICA	tumor
Guzman and Grady (1999)	53/M	It distal AICA	It cerebellar hemisphere	It AICA and PICA	tumor
Menovsky et al. (2002)	52/F	It VA-AICA	It cerebellar hemisphere	It AICA	tumor
Zager et al. (2002)	53/M	It distal AICA	It cerebellar hemisphere	It AICA	tumor
Yasuo et al. (2006)	72/M	It ICA-PPTA	It cerebellar vermis	It SCA	tumor
Present case	60/F	It ICA	It cerebellar hemisphere	It AICA and PICA	tumor

AICA, anterior inferior cerebellar artery; BA, basilar artery; ICA, internal carotid artery; PICA, posterior inferior cerebellar artery; PPTA, persistent primitive trigeminal artery; SAH, subarachnoid hemorrhage; SCA, superior cerebellar artery; VA, vertebral artery.

syndrome who provided information had a positive family history of VHL syndrome. No difference was observed between the prevalence of sex with coexistence of intracranial aneurysm and hemangioblastoma. Its sex distribution with a M-to-F ratio of 3:4 (3 males, 4 females). Patients with VHL syndrome tended to experience neurological symptoms at an earlier age (mean, 36 years) than patients with sporadic CNS hemangioblastomas (mean, 45 years);<sup>9</sup> patients of hemangioblastomas coexisting aneurysms were aged from 50 to 72 years (mean 55 years).<sup>2</sup> In the present case, the patient was hemangioblastoma with VHL syndrome, female, 60 years old.

## Pathology

Macroscopically, HBs can be classified into 4 types. Type 1 present as cystic tumor without a macroscopic nodule (5%); type 2 is the most common (60%) and is composed of a cyst and a mural nodule; type 3 is a solid tumor (26%); and type 4 is a solid tumor with small internal cysts (9%).<sup>11</sup> In the present case, the macroscopic type was solid (type 3).

Histologically, HBs are classified into 3 types.<sup>12</sup> Juvenile type is predominantly composed of packed dilated vessels. Clear-cell type shows a higher proportion of stromal cells. Transitional type is considered as an intermediate group between juvenile and clear-cell types, with both dilated vessels and intermingled stromal cells. In the present case, the histological type was transitional type. Only 1 presented here confirms the histological type of coexistence of intracranial aneurysm and hemangioblastoma. Neither report described the histological type. Wakai et al reported the bleeding hemangioblastoma histological type of 6 cases,<sup>13</sup> 5 were transitional type, and 1 was juvenile type. This distribution could be expected since both juvenile and transitional types have a denser vascular network than the clear-cell variety, which might make them more prone to hemorrhage. Guzman reported the hemangioblastomas consist of 3 cell types: vascular endothelial cells that form the capillary network, pericytes adjacent to the endothelial cells, and epithelioid or stromal cells that are often laden with lipids.<sup>10,14</sup>

## Hemangioblastomas and Arteriovenous Malformations

The coexistence of an intracranial aneurysm and a hemangioblastoma is a rare occurrence. To find a comparative pathophysiological associated situation, we looked at the association of cerebral aneurysm and arteriovenous malformation (AVM), which has been reported to occur in 8% to 10% of AVM cases.<sup>11</sup> There are 2 theories to explain the pathogenesis of coexistence of AVMs and aneurysms.

- (1) A high flow in the feeding vessel of the AVM
- (2) a common congenital defect of the vessel walls. Similar to that observed with AVMs, the feeding arteries of hemangioblastomas show high flow velocity because of missing capillary bed resistance.

This phenomenon can be seen by the early appearance of tumor blush on angiography. Both AVM nidus and HB nodule present a dense vascular network. This feature makes both lesions quite alike from a functional point of view.<sup>14</sup> The vascular network creates a low resistance bed, which favors a high blood flow towards the lesion. This augmented flow can cause hemodynamic stress on the walls of the feeding arteries, draining veins, and intralésional vessels. Eventually, some structural changes can occur into the vessel walls. Feeding artery aneurysms, in both AVMs and HBs, is a good example of the structural change caused by that hemodynamic stress.<sup>11</sup> These appearances of high flow velocity in the feeding artery of the hemangioblastoma could be due to aneurysm formation, as proposed in the first theory regarding to AVMs. That can demonstrate the most plausible explanation when the aneurysm is located on the feeding artery of the hemangioblastoma.

## Hemangioblastomas and Vascular Endothelial Growth Factor

Vascular endothelial growth factor (VEGF), also known as vascular permeability factor, is a potent polypeptide regulator of blood vessel function that acts on 2 kinds of endothelial cell-specific tyrosine kinase receptors.<sup>14,15</sup> It promotes an array of responses in endothelium, including hyperpermeability, endothelial cell growth, and angiogenesis. Several studies have confirmed the expression of VEGF messenger RNA in CNS hemangioblastomas. It has been proposed that VEGF may represent the major endothelial mitogen in CNS hemangioblastomas. Concerning the mechanism of aneurysm formation in association with pathological hemodynamic situations, immunohistochemical studies have shown that increased hemodynamic stresses on the vessel wall can lead to regulation of VEGF.<sup>16</sup> Skirgaudas et al.<sup>17</sup> found expression of VEGF in ten of 10 analyzed cerebral aneurysm vessel walls, whereas no expression of VEGF was found in non-aneurysmal vessels of 10 cases. VEGF is thought to initiate changes favoring leakage at intercellular junctions and the secondary activation of pathways causing enzymatic breakdown of matrix proteins.<sup>14</sup> Hence, a multifactorial genesis is likely responsible for the association of hemangioblastoma and aneurysm. Furthermore, a complex pathophysiological process derived from the HB would make the aneurysm develop. The aneurysm would not only be caused by an increased blood flow and its consequent hemodynamic disturbance but also by some other chemically modulated mechanisms. Expression and upregulation of VEGF and its receptors has been demonstrated on HBs.<sup>18,19</sup> Furthermore, some other studies have also demonstrated that increased hemodynamic stress on the vessel wall can lead to VEGF upregulation.<sup>11</sup> VEGF effects on blood vessels consist of hyperpermeability, endothelial cell growth, and angiogenesis.<sup>19</sup> So, VEGF is thought to start certain structural changes within vessel walls, as disruption of intercellular junctions and activation of enzymatic rupture of matrix proteins.<sup>11</sup> Those changes will eventually make the vessel wall weaker and more prone to distortion under hemodynamic stimuli. Thus, VEGF expressed by the HB could act in conjunction with the hemodynamic disturbances also created by the HB. VEGF would make the vessel wall more fragile, while the hemodynamic stress, caused by a high blood flow, would deform the wall and create an aneurysm eventually.<sup>10,14</sup> In present case, the aneurysm probably caused by the latter theory.

## Neurosurgical Management

Dealing with the coexisting aneurysm and cerebellar hemangioblastoma, if the aneurysm located on the main feeding artery, the optimal strategies are successful total excision of the hemangioblastoma and clipping of the aneurysm achieved in a one-stage operation. Ruptured aneurysms as the bleeding sources, such as SAH or hemorrhage, which have produced symptoms, should be treated primarily. Surgical removal of the hemorrhage and clip the aneurysm should be considered as the best option for the ruptured aneurysm,<sup>14</sup> the hemangioblastoma of coexistence mainly feeding artery should be removed at the same aneurysm surgery stage. The hemangioblastoma should be removed at the second stage while the aneurysm did not arise from the tumoral feeding artery.<sup>2</sup> The radical curable criteria is clip the aneurysm and surgical removal the hemangioblastoma in a one-stage or a second-stage operation.

## Cavernous Sinus Aneurysm

Association of the cavernous sinus aneurysm with a brain tumor is rare. Cavernous sinus aneurysms have been reported in patients with meningiomas, pituitary adenomas, hemangiomas and other brain tumors.<sup>21</sup> But, there is no literature about cavernous sinus aneurysm associated with hemangioblastoma. Surgical treatment for cavernous

sinus aneurysm is difficult, reflected by the confusing array of reports and recommendations, including carotid artery ligation with or without bypass surgery, parent vessel occlusion and intravascular coil placement with stenting. The indication for treatment of asymptomatic cavernous sinus aneurysm, brings to our attention once again the modern management dilemma of knowing whether to provide treatment for a condition of which we do not know the natural history.<sup>21</sup> We have all seen, in the past few years, many more such aneurysms, incidentally discovered at the time of noninvasive imaging performed for unrelated symptoms. Very few natural history

Studies have been performed, and most included small numbers of patients. The indication for active intervention is well-accepted for those patients with cavernous sinus aneurysms who present with progressive neurologic symptoms, pain syndromes that are not clinically tolerated, or aneurysms associated with rupture into the adjacent cavernous sinus, sphenoid sinus, or subarachnoid space.<sup>22</sup> The indication for active treatment of asymptomatic cavernous sinus aneurysms is questionable, and any decision to treat should be carefully considered in view of our very limited knowledge of their natural history and the small but definite immediate potential risk associated with their treatment. As new treatment options become available, the risk-management strategy will need to include a consideration of which type of treatment (parent vessel occlusion, coiling, stent placement, flow-diverting stent, and so forth) would be most efficient for alleviating symptoms at the lowest possible associated risk.<sup>20</sup> There is little scientific evidence to support treatment of an asymptomatic cavernous sinus aneurysm, irrespective of size or age. There is certainly no indication for treatment if the aneurysm is small and the patient is in the elderly age group.<sup>5,22</sup> The indication for treatment of unruptured cavernous sinus aneurysms, asymptomatic cavernous sinus aneurysms and in an elder age group, growth-changes were observed symptom and size of aneurysms on follow-up CTA or DSA imaging studies, the follow-up intervals used to define half an year to 1 year. The present case of cavernous sinus aneurysms that did not require surgery during the observation interval. Whether eventual decision for intervention is needed by observation.

## CONCLUSIONS

In summary, a cavernous sinus aneurysm associated with a cerebellar hemangioblastoma is a rare and scarcely documented event. The present case revealed symptoms of cerebellum obviously. Preoperative DSA showed the large cavernous sinus aneurysm though is unruptured, asymptomatic, diagnosed certainly. The unruptured cavernous sinus aneurysm was asymptomatic in our presented elderly patient, and she rejected further intervention. Whether requiring management has relied on more time follow up.

## REFERENCES

1. Abe T, Fujita S, Ozawa H, et al. Haemorrhagic nonsecreting pituitary adenoma associated with persistent primitive trigeminal artery. *Acta Neurochir (Wien)* 2000;142:1423–1424
2. Murai Y, Kobayashi S, Tateyama K, et al. Persistent primitive trigeminal artery aneurysm associated with cerebellar hemangioblastoma. Case report. *Neurol Med Chir (Tokyo)* 2006;46:143–146
3. Melmon KL, Rosen SW. Lindau's disease: review of the literature and study of a large kindred. *Am J Med* 1965;36:595–617
4. Cornelius JF, Saint-Maurice JP, Bresson D, et al. Hemorrhage after particle embolization of hemangioblastomas: comparison of outcomes in spinal and cerebellar lesions. *J Neurosurg* 2007;106:994–998
5. Sun-Yoon Chung, Sin-Soo Jeun, Jae-Hyun Park. Disseminated hemangioblastoma of the central nervous system without Von Hippel-Lindau disease. *Brain Tumor Res Treat* 2014;2:96–101
6. Yoshii Y, Maki Y, Tomono Y, et al. Cerebellar hemangioblastoma with multiple aneurysms. *No To Shinkei* 1976;28:703–708
7. Mrinal Bhuyan, Deep Dutta, Basanta Kumar Baishya, et al. Cerebellospinal hemangioblastoma with bilateral pheochromocytoma and hepatic cyst: a rare entity. *Asian J Neurosurg* 2016;11:311
8. Conway JE, Chou D, Clatterbuck RE, et al. Hemangioblastomas of the central nervous system in von Hippel-Lindau syndrome and sporadic disease. *Neurosurgery* 2001;48:55–62
9. Ammerman JM, Lonser RR, Dambrosia J, et al. Long-term natural history of hemangioblastomas in patients with von Hippel-Lindau disease: implications for treatment. *J Neurosurg* 2006;105:248–255
10. Yu Fang, Das Nirav, Singh Achint K. Cerebellar hemangioblastoma and pancreatic cysts in a case of von Hippel-Lindau disease. *The Journal of Pediatrics* 2016;168:251–e1
11. Javier RSP, Fernando AR, Belen FN, et al. Massive hemorrhage in hemangioblastoma (Literature review). *Neurosurg Rev* 2010;33:11–26
12. Silver ML, Hennigar G. Cerebellar hemangioma (heman-gioblastoma); a clinicopathological review of 40 cases. *J Neurosurg* 1952;9:484–494
13. Wakai S, Inoh S, Ueda Y, et al. Hemangioblastoma presenting with intraparenchymatous hemorrhage. *J Neurosurg* 1984;61:956–960
14. Guzman R, Grady MS. An intracranial aneurysm on the feeding artery of a cerebellar hemangioblastoma. Case report. *J Neurosurg* 1999;91:136–138
15. Hallsworth D, Thompson J, Wilkinson D, et al. Intracranial pressure monitoring and caesarean section in a patient with von Hippel-Lindau disease and symptomatic cerebellar haemangioblastomas. *Int J Obstet Anesth* 2016;24:73–77
16. De Vries C, Escobedo JA, Ueno H, et al. The fms-like tyrosine kinase, a receptor for vascular endothelial growth factor. *Science* 1992;255:989–991
17. Skirgaudas M, Awad IA, Kim J, et al. Expression of angiogenesis factors and selected vascular wall matrix proteins in intracranial saccular aneurysms. *Neurosurgery* 1996;39:537–547
18. Huntoon K, Lonser RR. Findings from the natural history of central nervous system hemangioblastomas in von Hippel-Lindau disease. *Neurosurgery* 2016;61(Suppl 1):N159–N162
19. Hatva E, Böhling T, Jääskeläinen J, et al. Vascular growth factors and receptors in capillary hemangioblastomas and hemangiopericytomas. *Am J Pathol* 1996;148:763–775
20. Gupta S, Goel A. Cavernous haemangioma of cavernous sinus associated with an internal carotid artery aneurysm. *Br J Neurosurg* 2000;14:56–59
21. Linskey ME, Sekhar LN, Hirsch WL, et al. Aneurysms of the intracavernous carotid artery: natural history and indications for treatment. *Neurosurgery* 1990;26:933–937
22. Ter Brugge KG. Cavernous sinus segment internal carotid artery aneurysms: whether and how to treat. *AJNR Am J Neuroradiol* 2012;33:327–328