

# Acute amnesia associated with damaged fiber tracts following anterior fornix infarction

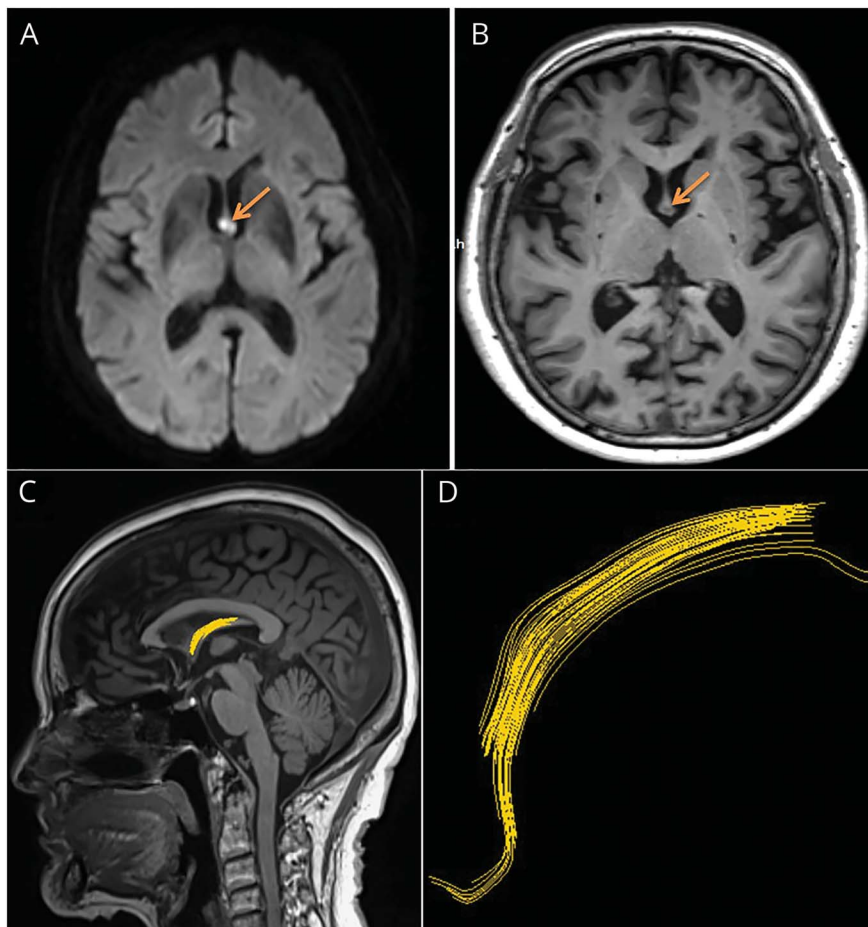
Qing Yong Zhu, MD, PhD, Hong Can Zhu, MD, PhD, and Cheng Ru Song, MD

*Neurology*® 2018;90:706-707. doi:10.1212/WNL.0000000000005306

**Correspondence**

Dr. H.C. Zhu  
hcan\_zhu@126.com

**Figure** Brain MRI and diffusion tensor tracking of anterior fornix infarction



(A) Axial diffusion-weighted imaging reveals an acute infarction of the anterior fornix (arrow). (B) Repeat T1-weighted brain MRI at 17 days after onset shows hypointense lesions in the same region (arrow). (C, D) Diffusion tensor tracking demonstrates that few fibers were followed.

A 78-year-old woman developed sudden-onset confusion and memory impairment. Examination demonstrated both retrograde and anterograde amnesia. Mini-Mental State Examination score of 17 exhibited poor performance in delayed recall and orientation function. Brain diffusion-weighted imaging revealed an acute infarction of the anterior fornix. Repeat T1-weighted images at 17 days after onset showed hypointense lesions in the same region. Meanwhile, diffusion tensor tracking was performed and demonstrated that few fibers were followed (figure), using Siemens (Munich, Germany) Syngo software with the measures of fractional anisotropy threshold 0.15 and angle 30. The fornix constitutes a core element of the Papez circuit<sup>1,2</sup> and acute amnesia was the result of damaged fiber tracts following anterior fornix infarction in this patient.

From the Departments of Neurology (Q.Y.Z., H.C.Z.) and Magnetic Resonance Imaging (C.R.S), The First Affiliated Hospital of Zhengzhou University, China. Go to [Neurology.org/N](http://Neurology.org/N) for full disclosures. Funding information and disclosures deemed relevant by the authors, if any, are provided at the end of the article.

### Author contributions

Dr. Qing Yong Zhu: study concept and design, drafting the manuscript. Dr. Hong Can Zhu: revising the manuscript, interpretation of data. Dr. Cheng Ru Song: analysis and acquisition of radiologic data.

### Study funding

No targeted funding reported.

### Disclosure

The authors report no disclosures relevant to the manuscript. Go to [Neurology.org/N](http://Neurology.org/N) for full disclosures.

### References

1. Thomas AG, Koumellis P, Dineen RA. The fornix in health and disease: an imaging review. *Radiographics* 2011;31:1107–1121.
2. Hattingen E, Rathert J, Raabe A, Anjorin A, Lanfermann H, Weidauer S. Diffusion tensor tracking of fornix infarction. *J Neurol Neurosurg Psychiatry* 2007;78:655–656.

---

## AAN Wants to Help You with MIPS!

MACRA and the Quality Payment Program and the 2018 Merit-based Incentive Payment System (MIPS) performance year began January 1. The AAN is committed to your success and has tools and resources to help you successfully meet your performance goals with minimal amount of effort. Take action today and visit [AAN.com/view/QPP](http://AAN.com/view/QPP) or email your questions to [macra@aan.com](mailto:macra@aan.com).

---

---

## Share Your Artistic Expressions in *Neurology* ‘Visions’

AAN members are urged to submit medically or scientifically related artistic images, such as photographs, photomicrographs, and paintings, to the “Visions” section of *Neurology*<sup>®</sup>. These images are creative in nature, rather than the medically instructive images published in the NeuroImages section. The image or series of up to six images may be black and white or color and must fit into one published journal page. Accompanying description should be 100 words or less; the title should be a maximum of 96 characters including spaces and punctuation.

Please access the Author Center at [Npub.org/authors](http://Npub.org/authors) for full submission information.

---

---

## Seeking Concussion Abstracts by May 7

Submit your concussion research for presentation in general poster sessions during the 2018 Sports Concussion Conference July 20 through 22 at the JW Marriott in Indianapolis, IN.

Visit [AAN.com/view/ConcussionConference](http://AAN.com/view/ConcussionConference).

---

---