

Accepted Manuscript

Contrast-induced encephalopathy presenting as acute subarachnoid hemorrhage

Julie A. Pokersnik, Louisa Lou, Erin L. Simon


PII: S0735-6757(18)30182-7
DOI: doi:[10.1016/j.ajem.2018.03.005](https://doi.org/10.1016/j.ajem.2018.03.005)
Reference: YAJEM 57356

To appear in:

Received date: 17 February 2018
Accepted date: 2 March 2018

Please cite this article as: Julie A. Pokersnik, Louisa Lou, Erin L. Simon , Contrast-induced encephalopathy presenting as acute subarachnoid hemorrhage. The address for the corresponding author was captured as affiliation for all authors. Please check if appropriate. Yajem(2018), doi:[10.1016/j.ajem.2018.03.005](https://doi.org/10.1016/j.ajem.2018.03.005)

This is a PDF file of an unedited manuscript that has been accepted for publication. As a service to our customers we are providing this early version of the manuscript. The manuscript will undergo copyediting, typesetting, and review of the resulting proof before it is published in its final form. Please note that during the production process errors may be discovered which could affect the content, and all legal disclaimers that apply to the journal pertain.



Contrast-induced Encephalopathy Presenting as Acute Subarachnoid Hemorrhage

Julie A. Pokersnik MD, Cleveland Clinic Akron General, Department of Emergency Medicine, Akron, OH

Louisa Lou BS, Cleveland Clinic Akron General Department of Emergency Medicine, Akron, Ohio.

Erin L. Simon DO, Cleveland Clinic Akron General, Department of Emergency Medicine, Akron, OH. Northeastern Ohio Medical University, Rootstown, OH.

Corresponding Author:

Erin L. Simon DO, Department of Emergency Medicine, Cleveland Clinic Akron General
1 Akron General Ave, Akron, Ohio 44307

PH: 330-962-9208

Fax: 330-761-3416

Esimon78@yahoo.com

Prior Presentations: None

Funding Sources/Disclosures: None

Conflicts of Interest: None

Abstract: Contrast media induced encephalopathy is a rare complication of contrast administration characterized by non-specific neurological signs and symptoms that may present both clinically and radiographically as subarachnoid hemorrhage. While there are few reported presentations in the neurology literature after inpatient contrast

administration, similar emergency department presentations have not been documented. We describe a patient who presented with encephalopathy and expressive aphasia after outpatient evaluation of an intrathecal analgesia pump who had radiographic imaging consistent with acute subarachnoid hemorrhage. The hyperdensities seen on computed tomography scanning were subsequently identified as residual gadolinium contrast media resulting in allergic encephalopathy in this patient.

Key Words: SAH, encephalopathy, contrast, contrast-induced, encephalitis, allergy

Case Report:

Contrast-induced encephalopathy is a rare complication characterized by development of neurological symptoms and caused by administration of intravascular contrast media [1]. Its clinical presentation varies from seizure, transient cortical blindness, to focal neurological deficits [2]. A possible underlying mechanism is neurotoxicity of intravascular contrast media, which can cause osmotic disruption of the blood-brain barrier (BBB) [1]. One form of contrast-induced encephalopathy results from gadolinium-based contrast agents (GBCAs), which are often used as an alternative for patients in whom iodine-containing contrast is contraindicated due to allergy [3]. Most cases of gadolinium-induced encephalopathy are due to gadolinium accumulating in the tissues of exposed patients during magnetic resonance imaging [4]. Currently, there have been no reported cases of encephalopathy following a fluoroscopy procedure used to evaluate the mechanical complication of an implanted fentanyl pump. Furthermore, it has previously been established that in patients with normal renal function, GBCAs are rapidly and completely excreted from the body in their intact state. Up until recent years, however, a few cases have emerged reporting the build up of gadolinium in the tissues of patients who do not have renal impairment [5]. In this report, we present the case of a patient displaying neurological deficit due to gadolinium contrast administration via fluoroscopy, despite having normal renal function.

A 56-year old male with a history of chronic pain, dysautonomia, gastrointestinal disease, and gastroesophageal reflux presented to a freestanding emergency department (ED) with a chief complaint of confusion and slurred speech. His wife stated he was asking questions he would typically know the answer to and having difficulty remembering the year. The patient had a history of a complex regional pain syndrome following a remote mechanical injury and had been using an intrathecal pain pump for management. He stated concern that his confusion was secondary to his fentanyl because he began feeling more confused since his pump was evaluated and dosage increased three hours prior. He denied any headache, vision change, chest pain, or shortness of breath.

Patient had a blood pressure of 148/92mmHg, respiratory rate of 10 breaths/min, pulse of 79 bpm, oxygen saturation 100% on room air, and temporal temperature 36.2°C. He was oriented to person and place, pupils were equal, round, and reactive to light, and he had intact cranial nerves with no focal motor or sensory deficits. Additionally, the patient was asking repetitive questions with some expressive aphasia and confusion. The remainder of his physical examination was unremarkable with heart regular rate and rhythm no murmurs, clear lung sounds with unlabored respirations, abdomen soft, non-tender, and normal, intact skin with no external evidence of trauma.

A non-contrast CT of the brain demonstrated diffuse hyperattenuation involving the basal cisterns. The patient was transferred emergently to the main campus tertiary care ED with a suspected subarachnoid hemorrhage. Prior to arrival at the main campus ED, the patient was started on a nicardipine drip to reduce his rising blood pressure. Due to a documented history of iodine base contrast allergy, he was unable to have a CT angiogram performed immediately. After pre-treatment with Solu-Cortef, the patient underwent a CT angiogram, which demonstrated no evidence of aneurysm or other architectural abnormality. In light of the preceding use of intrathecal gadolinium contrast and the patient's clinical picture, the findings on the CT scan were highly suggestive of residual gadolinium-based contrast rather than subarachnoid blood leading to gadolinium-induced encephalopathy. The patient was admitted to

the neurological intensive care unit, where he remained hemodynamically stable and returned to baseline neurologic function. He was discharged home on day 6.

Gadolinium-induced encephalopathy results from the deposition of gadolinium in brain tissue. A dysfunctional BBB allows the influx of normally excluded hydrophilic molecules, like gadolinium-based contrast agents, into the brain tissue [6]. Once past the BBB, gadolinium becomes neurotoxic, inhibiting mitochondrial function and inducing oxidative stress [7-8]. Any break in the BBB grants gadolinium access to the brain, regardless of patients' level of renal function at the time of their contrast procedure [9].

Gadolinium-induced encephalopathy is initially difficult to distinguish from other complications, such as subarachnoid hemorrhage and cerebral ischemia [10]. The disruption of the BBB may cause leakage of the contrast media, which may mimic acute subarachnoid hemorrhage [11]. Neurotoxicity due to leakage of contrast media has been reported as transient and rapidly reversible [12]. Consequently, in the case of contrast media extravasation, the hyperdensity suggestive of subarachnoid hemorrhaging should quickly improve upon subsequent CT images [13]. In our report, we present a case of neurotoxicity of gadolinium contrast that was initially confused with subarachnoid hemorrhage. Based on CT imaging, coupled with analysis of the patient's history of present illness and overall clinical picture, his condition was deemed a case of neurotoxicity due to contrast media leakage. This case demonstrates the importance of differentiating between subarachnoid hemorrhage and contrast-induced neurotoxicity diagnoses in order to avoid the risks associated with erroneous treatment, such as surgery for an incorrectly diagnosed subarachnoid hemorrhage. Early recognition of the contrast induced encephalopathy could guide appropriate, disease-specific treatment and potentially reduce hospital length of stay and patient morbidity.

References:

- [1] Liao, M-T., Lin, T-T., Lin, L-Y., Hwang, J-J., Tseng, C-D. Contrast-induced encephalopathy after percutaneous coronary intervention. *Acta Cardiologica Sinica*. 2013;29(3):277-280.
- [2] Leong, S., Fanning, NF. Persistent neurological deficit from iodinated contrast encephalopathy following intracranial aneurysm coiling: a case report and review of the literature. *Interv Neuroradiol*. 2012;18(1):33-41.
- [3] Saleh, L., Juneman, E., Movahed, M.R. The use of gadolinium in patients with contrast allergy or renal failure requiring coronary angiography, coronary intervention, or vascular procedure. *Catheter Cardiovasc Interv*. 2011;78(5):747-54.
- [4] Rogosnitzky, M., Branch, S. Gadolinium-based contrast agent toxicity: a review of known and proposed mechanisms. *Biometals*. 2016;29:365-376.
- [5] Kanal, E., Tweedle, M.F. Residual or retained gadolinium: practical implications for radiologists and our patients. 2015;275(3):630-634.
- [6] Ray, D.E., Cavanagh, J.B., Nolan, C.C., Williams, S.C. Neurotoxic effects of gadopentetate dimeglumine: behavioral disturbance and morphology after intracerebroventricular injection in rats. *Am J Neuroradiol*. 1996;17(2):365-373.
- [7] Feng, X., Xia, Q., Yuan, L., Yang, X., & Wang, K. Impaired mitochondrial function and oxidative stress in rat cortical neurons: implications for gadolinium-induced neurotoxicity. *Neurotoxicology*. 2010;31(4), 391-8.
- [8] Xia, Q., Feng, X., Huang, H., Du, L., Yang, X., & Wang, K. Gadolinium-induced oxidative stress triggers endoplasmic reticulum stress in rat cortical neurons. *J Neurochem*. 2011;117(1):38-47.
- [9] Montagne, A., Toga, A.W., Zlokovic, B.V. Blood-brain barrier permeability and gadolinium: benefits and potential pitfalls in research. *JAMA Neurol*. 2016;73(1):13-14.
- [10] Spina, R., Simon, N., Markus, R., Muller, D.W.M., Kathir, K. Contrast-induced encephalopathy following cardiac catheterization. 2017;90(2):257-268.
- [11] Oh, M.S., Kwon, J.E., Kim, K.J., Jo, J.H., Min, Y.J., Byun, J.S., et al. Subarachnoid hemorrhage mimicking leakage of contrast media after coronary angiography. *Korean Circ J*. 2012;42(3):197-200.
- [12] Sharp, S., Stone, J., Beach, R. Contrast agent neurotoxicity presenting as subarachnoid hemorrhage. *Neurology*. 1999;52:1503-1505.
- [13] Khan, S.M., Ho, D.W., Lazar, J.M., Marmur, J. Cerebral contrast retention after difficult cardiac catheterization: Case report. *SAGE Open Med Case Rep*. 2014;2:2050313X14530283.

Figure 1. Red arrows denote extensive increased attenuation involving the subarachnoid space suggestive of subarachnoid hemorrhage

ACCEPTED MANUSCRIPT

[AH]

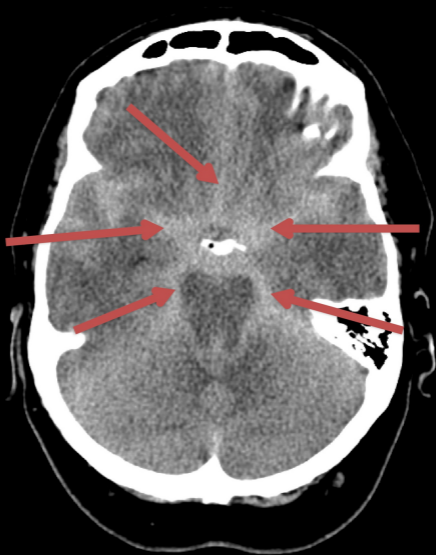


Figure 1