

## CASE REPORT

## Blind spot: blindness as initial presentation of subarachnoid haemorrhage

André Leonardo Gordinho, Steeve Rosado, Teresa Mesquita, Nuno Ribeiro Ferreira

Department of Medicine,  
Hospital Beatriz Angelo, Loures,  
Portugal

**Correspondence to**

Dr André Leonardo Gordinho,  
aj.leonardogordinho@gmail.com

Accepted 27 March 2018

**SUMMARY**

A 47-year-old Caucasian man with arterial hypertension was admitted after a seizure. At the emergency department, he presented with high blood pressure, bilateral vision loss (evidenced by unresponsiveness to threatening stimuli), right hemiplegia and severe agitation. The brain CT angiography showed a diffuse basal cisterns subarachnoid haemorrhage with a ruptured basilar aneurysm. He was admitted for neurovascular procedure and embolisation. The patient's neurological examination improved but blindness persisted. A fundoscopic examination revealed a left eye vitreous haemorrhage and diffuse retinal haemorrhages in the posterior pole. Assuming the haemorrhages were the cause of blindness, Terson syndrome was diagnosed. The patient underwent vitrectomy surgery being discharged 5 days later maintaining left eye blindness and able to count fingers from 1 m distance with the right eye. Two months after discharge, he was re-evaluated at our clinic with left eye blurred vision and almost normal right eye visual acuity.

**BACKGROUND**

Terson syndrome was first described by Albert Terson in 1900 as a vitreous haemorrhage occurring secondary to subarachnoid haemorrhage.<sup>1</sup> Today, Terson syndrome has a broader use and also includes other forms of vitreous and retinal haemorrhages associated with subarachnoid haemorrhage.<sup>2</sup> The presence of this syndrome is associated with increased mortality and a reported incidence of 3%–28% of subarachnoid haemorrhages.<sup>3 4</sup> There are many theories regarding the pathophysiology of this syndrome; a more recent one suggests retinal vessel rupture secondary to venous hypertension caused by sudden intracranial hypertension.<sup>5</sup>

This case illustrates a rare presentation of subarachnoid haemorrhage. Although Terson syndrome presence is considered a predisposing factor of poor prognostic outcome, our patient survived without neurological motor deficits and partially recovered his visual acuity.

**CASE PRESENTATION**

A 47-year-old Caucasian man with medical history of arterial hypertension was admitted to our emergency department after a seizure. At arrival to the emergency department, physical examination showed blood pressure was high (165/110 mm Hg), with a slow pulse rate (45 bpm) and fluent aphasia, isocoric and isoreactive pupils, bilateral loss of

vision (evidenced by unresponsiveness to threatening stimuli) and right hemiplegia. He had severe agitation requiring sedation and orotracheal intubation.

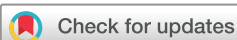A brain CT angiography was performed which showed a diffuse basal cisterns subarachnoid haemorrhage complicated with third and fourth intraventricular haemorrhage (Fisher 4) (figure 1) with a ruptured saccular aneurysm measuring 5x4 mm at the top of the basilar artery (figure 2) and signs of intracranial hypertension. He was classified as Hunt and Hess grade IV which includes patients with severe clinical deficits and reduced survival rate (20%): stupor and moderate to severe hemiparesis.

After the brain CT angiography, he was transferred to the neurosurgery department for neurovascular procedure with stenting and embolisation. The patient was extubated, and significant improvement was reported: absence of aphasia, a right hemiparesis grade 3, but the blindness persisted. Repeat CT scan demonstrated the stent on the top of the basilar artery, reabsorption of the subarachnoid haemorrhage and a right posterior cerebellar hypodensity. The patient persisted with complaints of visual loss. A fundoscopic examination revealed a left eye vitreous preretinal haemorrhage and bilateral diffuse retinal haemorrhages in the posterior pole (figure 3).

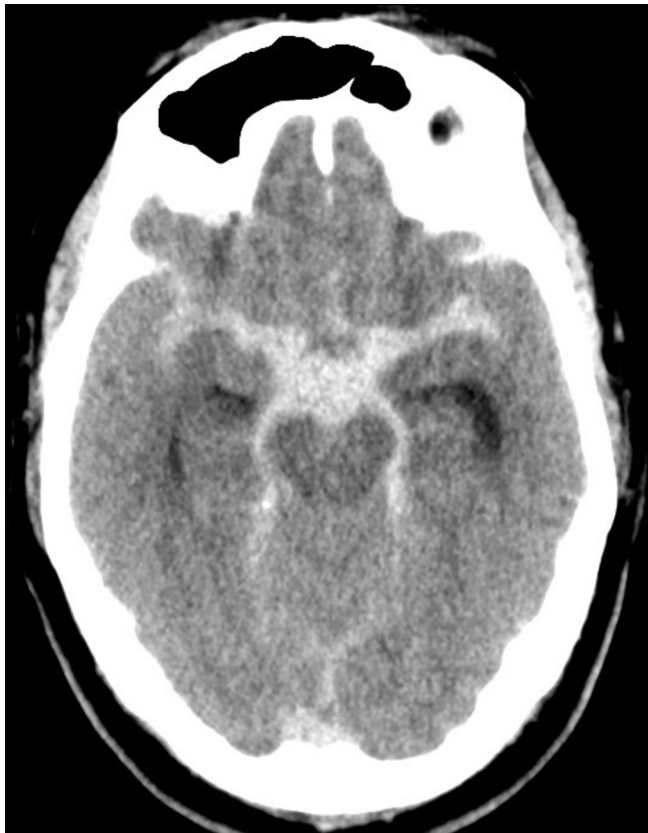After consulting an ophthalmologist, assuming the haemorrhages were blocking his vision, he was submitted to vitrectomy with panretinal photocoagulation. Unfortunately, his left eye vision failed to improve immediately after the vitrectomy, although it succeeded with the right eye as he was able to count fingers from 1 m distance. He was discharged 5 days later.

**DIFFERENTIAL DIAGNOSIS**

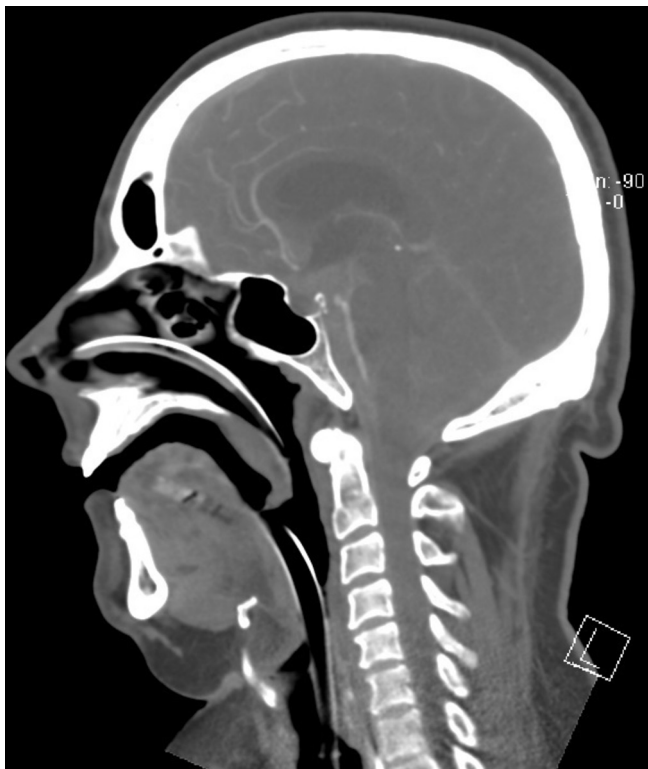
Other potential causes of visual loss were considered in this case. The first presumption on admission was that the patient had cortical blindness, but the repeat CT scan did not reveal any lesion in the cerebral area that could support this hypothesis. This was a case of subarachnoid haemorrhage. It could raise the possibility of an anterior communicating artery aneurysm, but the CT angiography and the neurovascular procedure only confirmed a basilar artery aneurysm. At last, there could be retinal ischaemia secondary to vasospasm; however, the acute presentation with consistency in improvement, and without any fluctuating or worsening symptoms within the temporal window of 3–7 days make it less probable. After performing a fundoscopic

**To cite:**

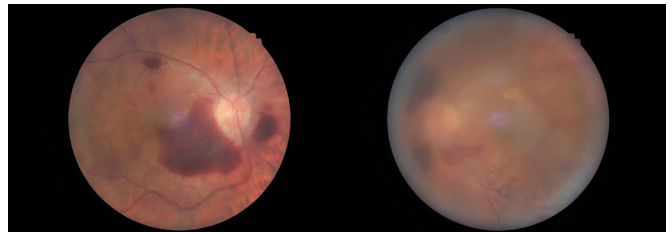
Leonardo Gordinho A,  
Rosado S, Mesquita T, et al.  
*BMJ Case Rep* Published  
Online First: [please  
include Day Month Year].  
doi:10.1136/bcr-2017-  
222745



**Figure 1** Head CT showing diffuse basal cisterns subarachnoid haemorrhage with third and fourth ventricular haemorrhage (Fisher grade 4).



**Figure 2** CT angiography showing ruptured saccular aneurysm measuring 5x4 mm at the top of the basilar artery.



**Figure 3** Retinography of the right and left eyes, patient's perspective.

examination, the definite diagnosis of Terson syndrome was made.

#### OUTCOME AND FOLLOW-UP

Two months after discharge, he was re-evaluated showing great improvement: left eye with slightly blurred vision and an almost normal right eye visual acuity, being able to distinguish fingers from 2 m distance and read with moderate difficulty. At final follow-up, his visual acuity was 20/30 (right eye) and 20/50 (left eye).

#### DISCUSSION

Terson's description of this syndrome was published more than 100 years ago, and its pathophysiology has remained doubtful. There were many possible explanations, from sudden increase in intracranial pressure that lead to stasis in the venous drainage of the eye and orbit resulting in haemorrhage to aneurysmal blood dispersed within cerebrospinal fluid which migrated into the optic nerve sheath and deposited.<sup>6,7</sup> A more recent description suggests that a sudden rise in intracranial pressure is transmitted along the optic sheath leading to venous hypertension and rupture of retinal vessels.<sup>5</sup>

A sudden rise in intracranial pressure due to aneurysmal rupture is compatible with our case which presented clinically with seizure and agitation. Most of published cases are due to anterior circulation aneurysmal rupture.<sup>5</sup> Terson syndrome from posterior circulation aneurysmal rupture, as in our case, is rare. As in this case, many of the diagnosis may be missed initially at presentation or misinterpreted as cortical blindness.

Mortality has been reported higher in patients with subarachnoid haemorrhage presenting with Terson's syndrome.<sup>3</sup> Our patient presented with a grade IV Hunt and Hess classification. In a meta-analysis published by McCarron *et al* in 2004, patients with subarachnoid haemorrhage and Terson syndrome who presented with higher Hunt and Hess grades were much more likely to die (43% mortality with an average grade of 3.5 vs 9% of whom scored 2.6).<sup>8</sup> Although our patient presented with a high Hunt and Hess grade, he had a better outcome. The funduscopy (gold standard) gave us the diagnosis, and the vitrectomy was performed as soon as possible emphasising the importance of early diagnosis and treatment as it is a reversible cause of blindness. Unfortunately, his left eye vision failed to improve immediately after the vitrectomy, as it succeeded with the right eye, and until now we do not have any explanation for that. The early endovascular procedure contributed to the good outcome presented, also showing the importance of early intervention.

This case illustrates a rare presentation of subarachnoid haemorrhage, although its presence is considered a predisposing factor of poor prognostic outcome, our patient survived without neurological motor deficits and recovered part of his visual acuity. We highlight the importance of a fundoscopic examination as many of the diagnosis may be missed or misinterpreted as cortical blindness.

## Learning points

- ▶ Terson syndrome is underdiagnosed, it may be present in up to one-third of subarachnoid haemorrhage, and its presence is associated with increased mortality.
- ▶ Fundoscopic examination is essential in patients with new onset neurological symptoms, especially in subarachnoid haemorrhage.
- ▶ Evaluation by an ophthalmologist is fundamental as surgical intervention may recover part or total visual acuity.

**Acknowledgements** The authors of the article, Blind spot: blindness as initial presentation of subarachnoid haemorrhage, would like to acknowledge the support and contribution of Dr. Francisco Araújo and Dr. José Lomelino Araújo.

**Contributors** ALG was involved in data collection regarding the clinical case, planning, drafting, editing, design and final approval of submitted version. SR was involved in data collection regarding the clinical case, editing, revising and final approval of the submitted version. TM and NRF were involved in editing, revising and final approval of the submitted version.

**Funding** This research received no specific grant from any funding agency in the public, commercial or not-for-profit sectors.

**Competing interests** None declared.

**Patient consent** Obtained.

**Provenance and peer review** Not commissioned; externally peer reviewed.

© BMJ Publishing Group Ltd (unless otherwise stated in the text of the article) 2018. All rights reserved. No commercial use is permitted unless otherwise expressly granted.

## REFERENCES

- 1 Terson A. De l'hémorragie dans le corps vitre au cours de l'hémorragie cérébrale. *Clin Ophthalmol* 1900;6:309–12.
- 2 Frizzell RT, Kuhn F, Morris R, *et al*. Screening for ocular hemorrhages in patients with ruptured cerebral aneurysms: a prospective study of 99 patients. *Neurosurgery* 1997;41:529–33. discussion 533–4.
- 3 Stienen MN, Lücke S, Gautschi OP, *et al*. Terson haemorrhage in patients suffering aneurysmal subarachnoid haemorrhage: a prospective analysis of 60 consecutive patients. *Clin Neurol Neurosurg* 2012;114:535–8.
- 4 Fountas KN, Kapsalaki EZ, Lee GP, *et al*. Terson hemorrhage in patients suffering aneurysmal subarachnoid hemorrhage: predisposing factors and prognostic significance. *J Neurosurg* 2008;109:439–44.
- 5 Garfinkle AM, Danys IR, Nicolle DA, *et al*. Terson's syndrome: a reversible cause of blindness following subarachnoid hemorrhage. *J Neurosurg* 1992;76:766–71.
- 6 Ballantyne AJ. The ocular manifestations of spontaneous subarachnoid haemorrhage. *Br J Ophthalmol* 1943;27:383–414.
- 7 Muller PJ, Deck JH. Intraocular and optic nerve sheath hemorrhage in cases of sudden intracranial hypertension. *J Neurosurg* 1974;41:160–6.
- 8 McCarron MO, Alberts MJ, McCarron P. A systematic review of Terson's syndrome: frequency and prognosis after subarachnoid haemorrhage. *J Neurol Neurosurg Psychiatry* 2004;75:491–3.

Copyright 2018 BMJ Publishing Group. All rights reserved. For permission to reuse any of this content visit <http://group.bmj.com/group/rights-licensing/permissions>.  
BMJ Case Report Fellows may re-use this article for personal use and teaching without any further permission.

Become a Fellow of BMJ Case Reports today and you can:

- ▶ Submit as many cases as you like
- ▶ Enjoy fast sympathetic peer review and rapid publication of accepted articles
- ▶ Access all the published articles
- ▶ Re-use any of the published material for personal use and teaching without further permission

For information on Institutional Fellowships contact [consortiasales@bmjgroup.com](mailto:consortiasales@bmjgroup.com)

Visit [casereports.bmj.com](http://casereports.bmj.com) for more articles like this and to become a Fellow