

Fulminant course in a patient with anti-*N*-methyl-*D*-aspartate receptor encephalitis with bilateral ovarian teratomas

A case report and literature review

Kuo-Wei Lee, MD^a, Li-Min Liou, MD, MS^{a,b}, Meng-Ni Wu, MD, MS^{a,b,*}

Abstract

Rationale: Anti-*N*-methyl-*D*-aspartate (NMDA) receptor encephalitis is an autoimmune disorder that can be controlled and reversed by immunotherapy. The presentation of NMDA receptor encephalitis varies, but NMDA receptor encephalitis is seldom reported in patients with both bilateral teratomas and preexisting brain injury.

Patient concerns: A 28-year-old female with a history of traumatic intracranial hemorrhage presented acute psychosis, seizure, involuntary movement, and conscious disturbance with a fulminant course. Anti-NMDA receptor antibody was identified in both serum and cerebrospinal fluid, confirming the diagnosis of anti-NMDA receptor encephalitis. Bilateral teratomas were also identified during tumor survey.

Diagnoses: anti-*N*-methyl-*D*-aspartate receptor encephalitis.

Interventions: Tumor resection and immunotherapy were performed early during the course.

Outcomes: The patient responded well to tumor resection and immunotherapy. Compared with other reports in the literature, her symptoms rapidly improved without further relapse.

Lessons: This case report demonstrates that bilateral teratomas may be related to high antibody titers and that the preexisting head injury may be responsible for lowering the threshold of neurological deficits. Early diagnosis and therapy are crucial for a good prognosis in such patients.

Abbreviations: CSF = cerebrospinal fluid, CT = computed tomography, ICH = intracranial hemorrhage, MRI = magnetic resonance imaging, NMDA = *N*-methyl-*D*-aspartate.

Keywords: anti-NMDA receptor encephalitis, course, head injury, teratoma, trauma

1. Introduction

Anti-*N*-methyl-*D*-aspartate (NMDA) receptor encephalitis is an inflammatory disease caused by cerebrospinal fluid (CSF) antibodies against the GluN1 subunit of the NMDA receptor.^[1] A quarter of patients with anti-NMDA receptor encephalitis present with persistent and severe neurological deficits or die, and early identification and treatment may improve the outcomes of these patients.^[1,2] Most patients with anti-NMDA receptor encephalitis present with a subacute onset of psychiatric symptoms, seizure, and involuntary movement followed by autonomic instability and disturbed consciousness within 3

weeks of symptom presentation; however, the clinical course may vary among individuals. Although ovarian teratoma has been identified in approximately half of the patients with anti-NMDA receptor encephalitis, little of the literature has reported such encephalitis in combination with bilateral teratomas, and to the best of our knowledge, no clinical course and laboratory data pertaining to anti-NMDA receptor encephalitis in patients with preexisting brain injury have been reported to date. Herein, we present an atypical and fulminant course in a patient with anti-NMDA receptor encephalitis presenting with bilateral teratomas and with a history of traumatic intracranial hemorrhage (ICH). Although this patient exhibited no remarkable findings on brain magnetic resonance imaging (MRI) and CSF study, her symptoms rapidly improved after tumor removal and immunotherapy.

2. Case report

A 28-year-old female who suffered from traumatic ICH received a craniectomy 8 years previously and showed no obvious sequela or seizure thereafter. She presented with an abrupt onset of abdominal pain, vomiting, diarrhea, and common cold-like symptoms followed by auditory hallucinations and delusions 2 days thereafter. Five days after the initial symptoms onset, she was admitted because of 2 episodes of general tonic-clonic seizures. On admission, a decrease in speech, fluctuation of cognition, echolalia, and oral-facial and orolingual dyskinesia were recorded. On day 9 of symptom onset, she developed akinetic mutism. Neurological examinations were unremarkable

Editor: N/A.

The authors have no funding and conflicts of interest to disclose.

^a Department of Neurology, Kaohsiung Medical University Hospital, ^b Department of Master's Program in Neurology, Kaohsiung Medical University, Kaohsiung, Taiwan.

* Correspondence: Meng-Ni Wu, No. 100, Tzyou 1st Road, Kaohsiung 80754, Taiwan (e-mail: berkeley0701@gmail.com).

Copyright © 2018 the Author(s). Published by Wolters Kluwer Health, Inc. This is an open access article distributed under the Creative Commons Attribution-NoDerivatives License 4.0, which allows for redistribution, commercial and non-commercial, as long as it is passed along unchanged and in whole, with credit to the author.

Medicine (2018) 97:15(e0339)

Received: 10 January 2018 / Received in final form: 14 March 2018 / Accepted: 15 March 2018

<http://dx.doi.org/10.1097/MD.0000000000010339>

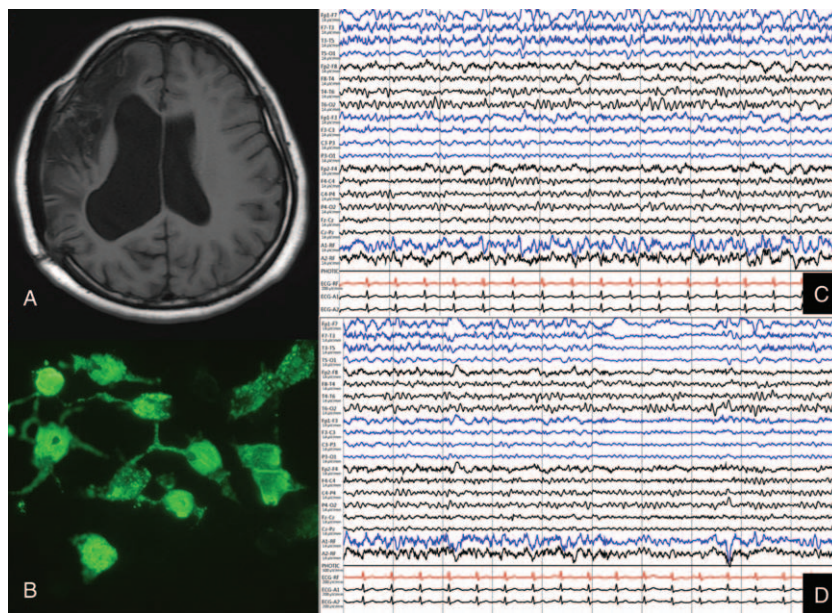


Figure 1. (A) Brain magnetic resonance imaging (T2WI) showed encephalomalacia on the right fronto–parieto–temporal lobe related to previous head trauma. (B) Immunofluorescent staining using NMDA receptor-1 antibody. (C–D) Results of electroencephalography showing disorganized postdominant rhythm with a run of the bilateral asynchronous polymorphic slow wave at 3 to 5 Hz.

except for decreasing responses to verbal or pain stimulation, whereas the eyes spontaneously opened. A further physical examination revealed autonomic dysfunction as transient tachycardia and hypertension.

Brain MRI (Fig. 1A) revealed only encephalomalacia on the right fronto–parieto–temporal lobe related to previous head trauma. Electroencephalography (Fig. 1C and D) revealed a disorganized postdominant rhythm with a run of bilateral asynchronous polymorphic slow waves at 3 to 5 Hz. Electroencephalography did not reveal any evidence of nonconvulsive status epilepticus, and the clinical seizure subsided after the administration of antiepileptic drugs (valproic acid at 1800 mg/d and levetiracetam 1 g/d). Routine laboratory tests were unremarkable. Tumor markers, including CEA, CA125, CA153, and α -fetoprotein, and autoimmune profiles, including antinuclear antibodies, rheumatoid factor, anti-double-stranded DNA antibody, thyroid peroxidase antibody, and thyroglobulin antibody, were within normal limits. No pleocytosis, increased protein levels, or hypoglycorrhachia identified via CSF study were noted, and the IgG index was unremarkable. Under the consideration of autoimmune encephalitis, methylprednisolone (1000 mg/d for 5 days as a cycle) was initiated on day 9 after symptoms onset, and abdominal computed tomography (CT) on day 12 revealed bilateral teratomas. Bilateral partial oophorectomy was conducted on day 13 followed by plasma exchange on day 14. The pathological examination of bilateral ovaries revealed matured cystic teratoma. Anti-NMDA receptor antibody was identified in both serum and CSF using immunofluorescence staining (Fig. 1B) on day 24, and the diagnosis of anti-NMDA receptor encephalitis was confirmed. Her neurological symptoms gradually improved, and she became alert and could recognize her family. On day 36 after symptoms onset, she presented with mild short memory impairment after tumor removal, 10 courses of plasma exchange, and 15 days of methylprednisolone therapy at 1000 mg/d divided into 3 cycles. On day 41 after symptoms onset, she could perform daily activities well except some paranoid persistent and bilateral lower limb weakness caused by being previously bedridden. Finally, she was discharged

with oral steroids (prednisolone at 10 mg/d) and antiepileptic drugs (valproic acid at 1800 mg/d and levetiracetam at 1 g/d). The total duration of hospitalization was 41 days (Fig. 2). During a 2-year follow-up, her symptoms completely improved without relapse or other similar symptoms.

The informed consent was obtained from the patient for publishing the article.

3. Discussion

Although early treatment is associated with better outcomes, the clinical presentation and course of anti-NMDA receptor

Past Medical History and Interventions			
28 years-old female suffered from traumatic ICH and received craniectomy 8 years ago without sequelae.			
Day from initial symptoms	Clinical presentation	Diagnostic Testing (including dates)	Intervention
D1 (20151217)	Cough, common-cold like symptoms		
D3	Auditory hallucination, delusion		
D5-D8	Seizure(day5), decreased speech, orofacial dyskinesia	*CSF study and brain MRI: unremarkable *EEG: disorganized post dominant rhythm with run of bilateral asynchronous polymorphic slow wave at 3-5 Hz	*Admission(day5) *Start antiepileptic use: Valproic acid 1800mg per day and Levetiracetam 1g per day
D9	akinetic mutism	*Check serum and CSF NMDAR antibody	*1 st course pulse therapy: methylprednisolone 1000mg/day, total 5 days
D12		*Abdominal CT: bilateral teratomas	
D13			*Bilateral partial oophorectomy *Pathological finding: matured cystic teratoma
D14			*1 st course of plasma exchange: on day14,16,18,20,22
D19			*2 nd course pulse therapy: methylprednisolone 1000mg/day, total 5 days, day 19-23
D24		Formal report of NMDAR : POSITIVE (antibody in serum and CSF)	*2 nd course of plasma exchange on day24,26,28,30,32
D29			*3 rd course pulse therapy: methylprednisolone 1000mg/day, total 5 days, day 29-33
D34			*Shift to oral prednisolone: 80mg/day(day 34-36) 60mg/day(day37-38) 40mg/day(day39-41) 20mg/day(day42-44)
D36	Consciousness improved with mild short memory impairment		
D41	Can perform daily activity well except some paranoid persisted		
D45		Discharge	*Oral prednisolone 10mg/day *Oral antiepileptic: Valproic acid 1800mg per day and Levetiracetam 1g per day

Figure 2. Scheme of the clinical timeline.

encephalitis vary among individuals, making accurate and timely diagnosis difficult. The clinical presentation of anti-NMDA receptor encephalitis can be divided into 4 specific phases as follows: prodrome phase; psychotic phase; neurological complications (unresponsive phase, hyperkinetic phase, seizure, etc.); and recovery phase.^[3,4] In the prodrome phase, patients may present similar symptoms as those in viral infection including lethargy, upper respiratory symptoms, nausea, or diarrhea that lasts for no >2 weeks. During the psychotic phase, schizophrenia-like symptoms, such as delusional thought content, perceptual disturbances, and disorganized thoughts and behaviors, are prominent without obvious neurological symptoms. The psychotic phase usually lasts 1 to 3 weeks, and gradual neurological complications, such as being mute, being akinetic, being unresponsive to verbal commands or painful stimulation, and the eyes remaining open (resembling catatonia), develop. During this period, orofacial dyskinesia, dystonic posturing, and other involuntary limb movements may also present with autonomic dysfunction. In addition, hypoventilation has been reported in some cases that required ventilator support, and seizures have been reported to be usually present in patients with anti-NMDA receptor encephalitis.^[3–5] In the recovery phase, the symptoms may improve with the reversal of the abovementioned phases, requiring 3 to 4 months of hospitalization.^[3]

Here, we presented an atypical case of anti-NMDA receptor encephalitis with a fulminant course and rapid improvement compared with other cases. In our patient, the prodromal phase lasted only 3 days, followed by the psychotic phase of 6 days that progressed onto an unresponsive phase with abnormal movements. Our patient experienced a seizure on day 5. The possible cause of the fulminant course in our patient may be related to the downregulation of NMDA receptors caused by her previous traumatic brain injury. Traumatic brain injury may activate metabolic cascades, including cellular and molecular changes such as excitotoxicity, inflammation, oxidative damage, and synaptic injury.^[6] Reportedly, NMDA receptor density is reduced in the neurons after a traumatic brain injury to cope with the increase in extracellular excitatory neurotransmitters.^[7] The other possible cause of the fulminant course is the bilateral ovary teratomas, which may indicate higher antibody titers in our patient although CSF antibody titers were not available. Furthermore, patients with tumors show higher antibody titers than those without tumors, and patients with milder symptoms show lower antibody titers.^[5,8] However, the precise serum or CSF antibody titers were not available in this study, and further research is warranted to investigate changes in antibody titers after therapy.

Currently, anti-NMDA receptor encephalitis treatments include tumor resection (in cases presenting with tumors), symptomatic treatment, and immunotherapy. The first-line immunotherapy includes the administration of corticosteroids, intravenous immunoglobulins, plasma exchange, and plasmapheresis, whereas the second-line immunotherapy includes the administration of rituximab, cyclophosphamide, mycophenolate mofetil, azathioprine, and methotrexate.^[9] Although receiving these therapies, approximately 25% of the patients with anti-NMDA receptor encephalitis still develop persistent and severe

neurological deficits or die. Reportedly, patients who do not require intensive care, receive early treatment, show a lower antibody titer after treatment, present with a less severe disease within 4 weeks of onset, and receive a diagnosis and undergo tumor removal within 4 months of symptom onset achieve good outcomes.^[2,5] Moreover, the mean interval between the presentation of symptoms and the initial signs of improvement is 8 weeks in patients receiving early tumor removal and 11 weeks in patients receiving late tumor removal.^[5] Compared with cases reported in previous studies, our patient, despite her fulminant course, responded well to treatments after the first-line immunotherapy (corticosteroids and plasma exchange) combined with tumor removal and manifested the initial symptoms of improvement on day 36. We hypothesize that the rapid intervention of immunotherapy followed by tumor resection may be related to the more positive response to therapy in our patient.

4. Conclusions

The presentation and clinical course of anti-NMDA receptor encephalitis are variable. We assumed that bilateral teratomas may be related to the high antibody titer in our patient and that preexisting head injury was responsible for lowering the threshold of neurological deficits. Early diagnosis and therapy are crucial for a good prognosis in such patients.

Author contributions

Writing – original draft: Kuo-Wei Lee, Meng-Ni Wu, Li-Min Liou.

Writing – review & editing: Kuo-Wei Lee, Meng-Ni Wu, Li-Min Liou.

References

- [1] Graus F, Titulaer MJ, Balu R, et al. A clinical approach to diagnosis of autoimmune encephalitis. *Lancet Neurol* 2016;15:391–404.
- [2] Titulaer MJ, McCracken L, Gabilondo I, et al. Treatment and prognostic factors for long-term outcome in patients with anti-N-Methyl-D-Aspartate (NMDA) receptor encephalitis: a cohort study. *Lancet Neurol* 2013;12:157–65.
- [3] Kayser MS, Dalmau J. Anti-NMDA receptor encephalitis in psychiatry. *Curr Psychiatry Rev* 2011;7:189–93.
- [4] Iizuka T, Sakai F, Ide T, et al. Anti-NMDA receptor encephalitis in Japan: long-term outcome without tumor removal. *Neurology* 2008;70:504–11.
- [5] Dalmau J, Gleichman AJ, Hughes EG, et al. Anti-NMDA-receptor encephalitis: case series and analysis of the effects of antibodies. *Lancet Neurol* 2008;7:1091–8.
- [6] Carvajal FJ, Mattison HA, Cerpa W. Role of NMDA receptor-mediated glutamatergic signaling in chronic and acute neuropathologies. *Neural Plast* 2016;2701526.
- [7] Park Y, Luo T, Zhang F, et al. Downregulation of Src-kinase and glutamate-receptor phosphorylation after traumatic brain injury. *J Cereb Blood Flow Metab* 2013;33:1642–9.
- [8] Gresa-Arribas N, Titulaer MJ, Torrents A, et al. Antibody titres at diagnosis and during follow-up of anti-NMDA receptor encephalitis: a retrospective study. *Lancet Neurol* 2014;13:167–77.
- [9] Zhang L, Wua M-Q, Hao Z-L, et al. Clinical characteristics, treatments, and outcomes of patients with anti-N-methyl-D-aspartate receptor encephalitis: a systematic review of reported cases. *Epilepsy Behav* 2017;68:57–65.