

PNE487089 - Pediatr Neurosurg - ISSN 1016-2291 (for internal use only)							
Code 3	PE	CE	Copy edited	Figures	Tables	Suppl. mat.	Typesetting
PNE	bd			3	0	x	mü
Language	E	Second Language		Third Language	Template_Art		ZU

Internal info: **Info für CE: bitte den Hinweis für 'suppl. material' im Text einfügen, danke**

**Pediatric
Neurosurgery**

KARGER
www.karger.com

Queries to the author	<ol style="list-style-type: none"> 1. Please confirm that authors' names and initials have been identified correctly. 2. Online supplementary material: the supplementary video is not cited in the text -- please cite where appropriate.
-----------------------	--

Article title	A Rare Cause of Juvenile Stroke: Extracranial Carotid Artery Aneurysm with Venous Complete Reconstruction of the Carotid Bifurcation
Article title second language	
Article title third language	
Subtitle	
Short title	Carotid Bifurcation Reconstruction of ECAA Using the Greater Saphenous Vein
Section title	Technical Note

Relation(s)	Example:	Initials S.-J.	Given name Seo-Jin	Surname/Collaboration Park	Affiliation(s) a,b
2313755		M.	Maurizio	Domanin	a,b
2313756		S.	Silvia	Lanfranconi	c
2313757		S.	Silvia	Romagnoli	b
2313758		L.	Letterio	Runza	d
2313759		F.	Francesca	Cortini	e
2313760		G.P.	Giacomo Piero	Comi	c,f
2313761		L.	Livio	Gabrielli	a,b

Affiliation(s)	City	State	Country
a Department of Clinical Science and Community Health, University of Milan	Milan		Italy
b Operative Unit of Vascular Surgery I.R.C.C.S. Fondazione Cà Granda Ospedale Maggiore Policlinico	Milan		Italy
c Operative Unit of Neurology, I.R.C.C.S. Fondazione Cà Granda Ospedale Maggiore Policlinico	Milan		Italy
d Division of Pathology, I.R.C.C.S. Fondazione Cà Granda Ospedale Maggiore Policlinico	Milan		Italy
e Genetics Laboratory, I.R.C.C.S. Fondazione Cà Granda Ospedale Maggiore Policlinico	Milan		Italy
f Department of Pathophysiology and Transplantation, University of Milan	Milan		Italy

- Formattato: Italiano (Italia)
- Formattato: Italiano (Italia)
- Formattato: Italiano (Italia)
- Formattato: Italiano (Italia)
- Formattato: Italiano (Italia)
- Formattato: Italiano (Italia)
- Formattato: Italiano (Italia)

Additional information

Corresponding author	Maurizio Domanin
Full address	Unità Operativa di Chirurgia Vascolare, Fondazione I.R.C.C.S. Ca' Granda Ospedale Maggiore Policlinico Via Francesco Sforza 35 IT--20122 Milano (Italy)
E-Mail	E-Mail maurizio.domanin@unimi.it

Formattato: Italiano (Italia)

Formattato: Italiano (Italia)

Formattato: Italiano (Italia)

Citation line	Journal
	Pediatr Neurosurg
10.1159/000487089	Article-Nr 487089
ISSN	1016-2291
ISBN	

Received	Received: October 6, 2017
Accepted	Accepted after revision: January 21, 2018
Revised	
Published online	Published online: ■■■
Copyright statement	© 2018 S. Karger AG, Basel
Copyright description	

Keywords	Keywords
	Extracranial carotid artery aneurysm Stroke Carotid bifurcation reconstruction

Keywords Second Language	
--------------------------	--

Keywords Third Language	
-------------------------	--

Abbreviations	
---------------	--

Abstract	Abstract
----------	----------

Extracranial carotid artery aneurysms (ECAA) are a rare cause of embolic stroke. The underlying etiology is variable, with atherosclerosis being the most common entity in older subjects. Several treatments have been developed over the last 20 years, but the preferred method remains unknown. Notwithstanding the widespread use of endovascular techniques, surgical reconstruction by means of a bifurcated venous bypass graft should be applied in younger patients. In this way, it is possible to avoid major concerns about the development of long-term intrastent restenosis, and also to spare the external carotid artery which represents the main branch for the ipsilateral cerebral and facial perfusion. We propose ECAA resection and interposition of the inverted great saphenous vein to both the internal and external carotid

artery by means of a tributary, i.e., the Giacomini vein.

Abstract Second Language

Abstract Third Language

Key Messages

When feasible, after the avulsion of the extracranial carotid aneurysm, the revascularization of both the internal and external carotid arteries should be mandatory in younger patients

Body

Introduction

The incidence of extracranial carotid artery aneurysms (ECAA) is ranges between 0.09 and 2.0% of all carotid surgical procedures [1, 2], being even rarer in the younger population. ECAA are associated with a stroke prevalence of 50% and a mortality of 70% under conservative treatment. Literature data suggest that medical treatment may be considered in cases of small, asymptomatic aneurysms [3–6]. In contrast, an active surgical approach, by means of open or endovascular treatment, is generally preferred for symptomatic ECAA [4, 7]. Either way, the best method to treat ECAA has not yet been established [8].

In the case in this study, in view of the unfavorable clinical evolution despite anticoagulant therapy, i.e., the development of a voluminous floating thrombus inside the ECAA,

surgical treatment was performed 10 days after the onset of stroke. Further investigation suggested an underlying collagenopathy whose molecular defect has not been identified so far.

Case Report

A 17-year-old boy presented to the emergency department of a local hospital for the sudden onset of focal secondary generalized seizures treated with intravenous (i.v.) lorazepam (4 mg). His past medical history was positive for recurrent pharyngitis with tonsillitis, mitral valve prolapse, kyphosis, and recurrent headache. There was no history of previous head trauma.

Examination

General examination revealed a Marfanoid habitus. The blood tests and toxicology results were negative. Due to persistent drowsiness, aphasia, and right hemiparesis, the patient underwent cerebral magnetic resonance imaging which showed a deep left middle cerebral artery stroke (Fig. 1a). Computed tomography angiography disclosed an ECAA of 1.5 cm in diameter located at the origin of the left internal carotid artery (Fig. 1b, c). He was then transferred to the Neurology Department of our hospital and started on low-molecular-weight heparin. A full dose was not administered because of an initial hemorrhagic transformation of the stroke. He then underwent serial Doppler ultrasound monitoring.

On day 9, Doppler ultrasound revealed the presence of a floating thrombus inside the ECAA (Fig. 1d). Consequently, we urgently performed the surgical correction of the ECAA under general anesthesia and electroencephalographic monitoring. Before ECAA exposure, a short segment (8.0 cm in length) of the left great saphenous vein (GSV) was harvested at the inguinal groin. During the exposure, lymphoid tissue hypertrophy was observed in the laterocervical space. Enlarged lymph nodes (>2.0 cm in diameter) were collected and sent to the laboratory for examination. After carefully exposing the carotid bifurcation and ECAA (Fig. 2a), i.v. administration of 2,500 IU of heparin, carotid cross-clamping and aneurysm resection

were then performed. The restoration of the antegrade flow was obtained by means of interposition of the inverted GSV. In order to complete the reconstruction of the whole bifurcation, the Giacomini vein, a proximal tributary of the GSV, was used to revascularize the external carotid artery (Fig. 2b). Total cross-clamping time was 32 min and no shunting was needed. Running sutures were all performed with a 6-0 monofilament (Prolene, Ethicon, Somerville, USA) under $\times 3.5$ optical magnification.

Postoperative histological examination of the specimen (Fig. 3a) disclosed focal thinning of the tunica media associated with an increased intimal thickness, elastic fiber, fragmentation and myxoid alcyanophilic material deposition (Fig. 3b--d). All 3 layers of the artery wall were involved and no inflammatory infiltrates through the different layers were observed. Histological analysis of the arterial specimen demonstrated the presence of a true aneurysm of the carotid artery. Notwithstanding previous episodes of oropharyngeal inflammation, the lymph node analysis result was negative.

None of the findings were consistent with infectious etiology and this suggested the presence of an underlying connective-tissue disease. The patient underwent genetic testing by next-generation sequencing gene panel sequencing which is available at our institution. The analysis of a panel of 19 genes implicated in collagen pathology (*TGFBR3*, *TGFBR2*, *FLNB*, *COL12A1*, *DSE*, *COL1A2*, *TGFBR1*, *NOTCH1*, *ACTA2*, *NTM*, *COL4A1*, *COL4A2*, *FBN1*, *SMAD3*, *ABCC6*, *COL1A1*, *COL6A1*, *ATP7A*, and *FLNA*) did not reveal any pathogenic mutations.

The patient was then transferred to rehabilitation, and showed consistent improvements in aphasia and right hemiparesis on antiplatelet therapy (clopidogrel, 75 mg daily). At the 3-month follow-up, a significant improvement in the aphasia was observed but he still presented with weakness of the right arm. Today, 3 years later, the carotid vein graft is still patent on Doppler ultrasound monitoring and the patient has not complained of further symptoms.

Discussion

ECAA in children, adolescents, and young adults is a rare event, and its etiology is currently unclear. Atherosclerosis is the most common entity in elderly people [9], but in younger patients, otorhinolaryngoiatric pathologies have been invoked as initiating events [10--14]. About 10% of subjects with posttraumatic extracranial dissection present with dissecting aneurysms on follow-up [15, 16]. Stab wounds [17], congenital pathologies [18], fibromuscular dysplasia [19], Takayasu arteritis [20], Marfan syndrome [21], neurofibromatosis [22], and early atherosclerosis [23] have also been considered in ECAA pathogenesis.

Currently, little is known about the natural course and pathophysiological mechanisms of ECAA. In a series of 13 patients, treated by open ECAA repair, histology disclosed degeneration with a general loss of elastin fibers in the media in the majority of cases, and dissection with abrupt interruption of the media in the minority [6].

Most patients are usually asymptomatic, and ECAA is often discovered by accident as a beating laterocervical mass with bruits. Pain, dizziness, tinnitus, compression of the cranial nerves, dysphagia, and dyspnea have been also described [1, 11, 17, 23].

The natural history of ECAA is poorly defined and evolution towards stroke is less frequent in young patients [12]. A recently published systematic review confirmed a benign course in dissecting aneurysms [16]. ECAA can also rupture, with massive life-threatening epistaxis or hematemesis [24, 25].

Several treatments have been developed over the last 20 years, but the preferred method to treat ECAA remains unknown. The potential risks involved require surgical correction. Several technical solutions have been proposed, such as ligation, clipping, plication, patch angioplasty, and aneurysm resection with extracranial-intracranial bypass [1, 26] but GSV graft has been advocated as the first choice for treatment because of its long-term patency and reduced risk of infection [27--30]. Endovascular treatment of ECAA with coil embolization and

covered stent are popular nowadays and increasingly used due to their minimally invasive approach [31, 32].

In our case, GSV graft interposition was preferred, considering the presence of the floating thrombus, the young age of the patient and the related life-time risk of the development of intrastent restenosis [33, 34]. Moreover, harvesting the proximal segment of the GSV allows the use of the Giacomini vein for the simultaneous reconstruction of the external carotid artery in order to revascularize the major supply branch of the ipsilateral cerebral perfusion and of the hemiface [35, 36]. ECA collateral circulation reduces, or even cancels, the symptoms of cerebral ischemia [37]. We believe that, when feasible, this fundamental pathway of the cerebral collateral perfusion should always be protected. This issue could be even more important when treating younger patients with a long life ahead of them.

Conclusion

ECAA is a rare cause of ischemic stroke in children and teenagers and the underlying etiology is poorly understood, given the limited availability of pathological studies. A number of conditions, such as local infection, early atherosclerosis, and congenital pathology, have been associated with ECAA in younger patients, with the actual pathogenesis often remaining undefined. We believe that, when feasible, the revascularization of both the internal and external carotid arteries should be mandatory in younger patients.

Disclosure Statement

The authors have no personal, financial, or institutional interest in any of the drugs, materials, or devices described in this article.

References

- 1 El-Sabroun R, Cooley DA: Extracranial carotid artery aneurysms: Texas Heart Institute experience. *J Vasc Surg* 2000;31:702--712.
- 2 Radak D, Davidovic L, Vukobratov V, Ilijevski N, Kostic D, Maksimovic Z, et al: Carotid artery aneurysms: Serbian multicentric study. *Ann Vasc Surg* 2007;21:23--29.
- 3 McCollum CH, Wheeler WG, Noon GP, DeBakey ME: Aneurysms of the extracranial carotid artery. Twenty-one years' experience. *Am J Surg* 1979;137:196--200.
- 4 Zwolak RM, Whitehouse WM Jr, Knake JE, Bernfeld BD, Zelenock GB, Cronenwett JL: Atherosclerotic extracranial carotid artery aneurysms. *J Vasc Surg* 1984;1:415--422.
- 5 Longo GM, Kibbe MR: Aneurysms of the carotid artery. *Semin Vasc Surg* 2005;18:178--183.
- 6 Welleweerd JC, Nelissen BG, Koole D, de Vries JP, Moll FL, Pasterkamp G, Vink A, et al: Histological analysis of extracranial carotid artery aneurysms. *PLoS One* 2015;10:e0117915.
- 7 Sundt, TM Jr, Pearson BW, Piepgras DG, Houser OW, Mokri B: Surgical management of aneurysms of the distal extracranial internal carotid artery. *J Neurosurg* 1986;64:169--182.
- 8 Welleweerd JC, Moll FL, de Borst GJ: Technical options for the treatment of extracranial carotid aneurysms. *Expert Rev Cardiovasc Ther* 2012;10:925--931.
- 9 Rosset E, Albertini JN, Magnan PE, Ede B, Thomassin JM, Branchereau A: Surgical treatment of extracranial internal carotid artery aneurysms. *J Vasc Surg* 2000;31:713--723.
- 10 Sandmann W, Aulich A, Edelmann M: Aneurysm of the internal carotid artery at the base of the skull. *Arch Otorhinolaryngol* 1982;234:285--291.
- 11 Brochu B, Dubois J, Garel L, Quintal MC, Roy D: Complications of ENT infections: pseudoaneurysm of the internal carotid artery. *Pediatr Radiol* 2004;34:417--420.

- 12 Pourhassana S, Grotemeyera D, Fokoua M, Heinenb W, Balzera K, Rampc U, Sandmanna W: Extracranial carotid arteries aneurysms in children. Single-center experiences in 4 patients and review of the literature. *J Ped Surg* 2007;42:1961--1968.
- 13 Windfuhr JP, Sesterhenn AM, Schloendorff G, Kremer B: Post-tonsillectomy pseudoaneurysm: an underestimated entity? *J Laryngol Otol* 2010;124:59--66.
- 14 Foreman PM, Griessenauer CJ, Falola M, Harrigan MR: Extracranial traumatic aneurysms due to blunt cerebrovascular injury. Clinical article. *J Neurosurg* 2014;120:1437--1445.
- 15 Evans CE: Internal carotid artery aneurysm: a singular anomaly. *Head Neck Surg* 1984;6:1043--1050.
- 16 Larsson SC, King A, Madigan J, Levi C, Norris JW, Markus HS: Prognosis of carotid dissecting aneurysms: results from CADISS and a systematic review. *Neurology* 2017;88:646--652.
- 17 Chambers N, Hampson-Evans D, Patwardhan K, Murdoch L: Traumatic aneurysm of the internal carotid artery in an infant: a surprise diagnosis. *Paediatr Anaesth* 2002;12:356--361.
- 18 Hazarika P, Sahota JS, Nayak DR, George N: Congenital internal carotid artery aneurysm. *Int J Pediatr Otorhinolaryngol* 1993;28:63--68.
- 19 Mettinger KL, Ericson K: Fibromuscular dysplasia and the brain: observations on angiographic, clinical and genetic characteristics. *Stroke* 1982;13:46--52.
- 20 Kumar S, Subramanyan R, Mandalam KR, Rao VR, Gupta AK, Joseph S, et al: Aneurysmal form of aortoarteritis (Takayasu's disease): analysis of thirty cases. *Clin Radiol* 1990;42:342--347.
- 21 Sztajzel R, Hefft S, Girardet C: Marfan's syndrome and multiple extracranial aneurysms. *Cerebrovasc Dis* 2001;11:346--349.

- 22 Lin AE, Birch PH, Korf BR, Tenconi R, Niimura M, Poyhonen M, et al: Cardiovascular malformations and other cardiovascular abnormalities in neurofibromatosis 1. *Am J Med Genet* 2000;95:108--117.
- 23 James AL, O'Malley S, Milford CA: Extracranial internal carotid artery aneurysm in a child: a diagnostic and surgical challenge. *J Laryngol Otol* 1999;113:373--375.
- 24 Misra BK, Shaw JF: Haematemesis from distal extracranial carotid aneurysms. Case report and literature review. *Childs Nerv Syst* 1986;2:329--332.
- 25 Unal OF, Hepgül KT, Turantan MI, Bozboga M, Yazicioglu E: Extracranial carotid artery aneurysm in a child misdiagnosed as a parapharyngeal abscess: a case report. *J Otolaryngol* 1992;21:108--111.
- 26 Schievink WI, Piegras DG, McCaffrey TV, Mokri B: Surgical treatment of extracranial internal carotid artery dissecting aneurysms. *Neurosurgery* 1994;35:809--815.
- 27 Busuttill RW, Davidson RK, Foley KT, Liversay JT, Barker WF: Selective management of extracranial carotid arterial aneurysms. *Am J Surg* 1980;140:85--91.
- 28 Welling RE, Talisa A, Tarun G: Extracranial carotid artery aneurysms. *Surgery* 1983;93:319--323.
- 29 Attigah N, Kulkens S, Zausig N, Hansmann J, Ringleb P, Hakimi M, et al: Surgical therapy of extracranial carotid artery aneurysms: long-term results over a 24-year period. *Eur J Vasc Endovasc Surg* 2009;37:127--133.
- 30 Pulli R, Dorigo W, Alessi Innocenti A, Pratesi G, Fargion A, Pratesi C: A 20-year experience with surgical management of true and false internal carotid artery aneurysms. *Eur J Vasc Endovasc Surg* 2013;45:1--6.
- 31 Wolfe SQ, Mueller-Kronast N, Aziz-Sultan MA, Zauner A, Bhatia S: Extracranial carotid artery pseudoaneurysm presenting with embolic stroke in a pediatric patient. *J Neurosurg Pediatr* 2008;1:240--243.

- 32 Li Z, Chang G, Yao C, Guo L, Liu Y, Wang M, et al: Endovascular stenting of extracranial carotid artery aneurysm: a systematic review. *Eur J Vasc Endovasc Surg* 2011;42:419–426.
- 33 Christiaans MH, Ernst JMPG, Suttorp MJ, van den Berg JC, Overtoom TTC, Kelder JC, et al: Restenosis after carotid angioplasty and stenting: a follow-up study with duplex ultrasonography. *Eur J Vasc Endovasc Surg* 2003;26:141--144.
- 34 Arquizan C, Trinquart L, Touboul PJ, Long A, Feasson S, Terriat B et al; EVA-3S Investigators: Restenosis is more frequent after carotid stenting than after endarterectomy: the EVA-3S study. *Stroke* 2011;42:1015--1020.
- 35 Fearn SJ, Picton AJ, Mortimer AJ, Parry AD, McCollum CN: The contribution of the external carotid artery to cerebral perfusion in carotid disease. *J Vasc Surg* 2000;31:989--993.
- 36 Domanin M, Isalberti M, Romagnoli S, Rolli A, Sommaruga S: Acute hemifacial ischemia as a late complication of carotid stenting. *J Vasc Surg Cases Inn Tech* 2017;3:83--86.
- 37 van Laar PJ, van der Grond J, Bremmer JP, Klijn CJM, Hendrikse J: Assessment of the contribution of the external carotid artery to brain perfusion in patients with internal carotid artery occlusion. *Stroke* 2008;39:3003--3008.

Appendix after References (Editorial Comments)

Legend(s)

Fig. 1. **a** Magnetic resonance imaging. Deep left middle cerebral artery stroke. **b, c** Computed tomography angiography. External carotid arterial aneurysm of 1.5 cm in diameter located at the origin of the left internal carotid artery. **d** Doppler ultrasound. Evidence of a floating thrombus in the aneurysm sac.

Fig. 2. Intraoperative imaging. **a** Exposure of the carotid bifurcation and of the ECAA. **b** Reconstruction of the carotid bifurcation with interposition of the inverted greater

saphenous vein to the internal carotid artery and of the Giacomini vein to the external carotid artery.

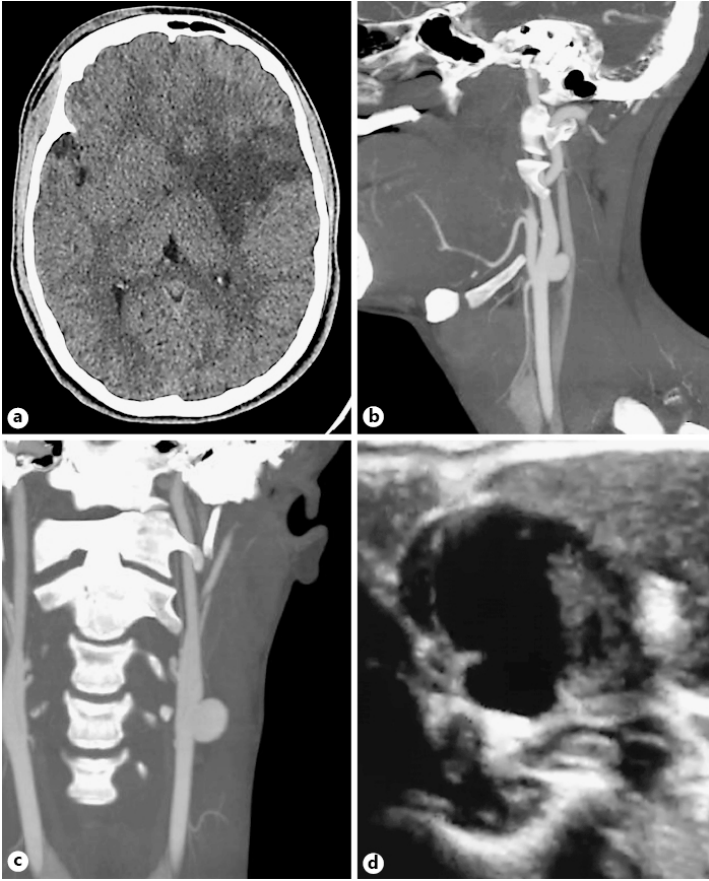
Fig. 3. Anatomopathological examination. **a** ECAA specimen. **b** Histology: focal thinning of the tunica media associated with increased intimal thickness. HE. $\times 20$. **c** Histology: elastic fiber fragmentation. Orcein. $\times 40$. **d** Histology: myxoid alcyanophilic material deposition. Alcian blue (pH 2.5). $\times 20$.

Table(s)

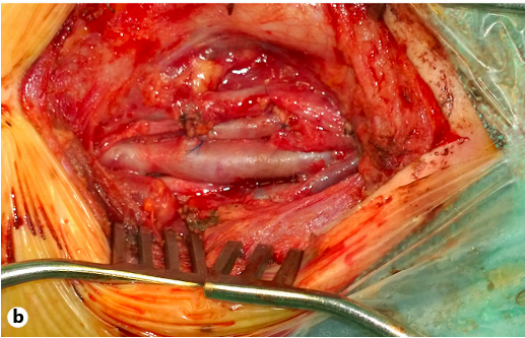
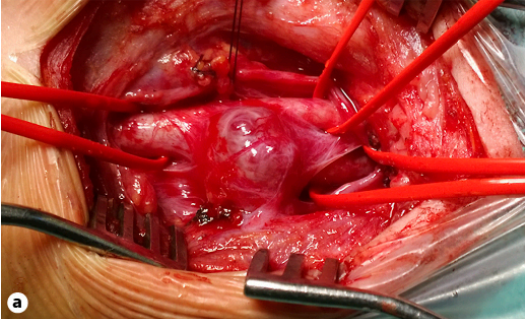
Footnote(s)

[Supplementary Video on Line:
Doppler Ultrasound of the extracranial carotid artery aneurysms: presence of a floating thrombus inside the carotid aneurysm lumen.](#)

pne487089_f01.jpg



pne487089_f02.jpg



pne487089_f03.jpg

