

Accepted Manuscript

Case Report: A Comparative Report on Intracranial Tumor-to-Tumor Metastasis and Collision Tumors

Sohail Syed, David I. Karambizi, Amanda Baker, Darren M. Groh, Steven A. Toms



PII: S1878-8750(18)30829-5

DOI: [10.1016/j.wneu.2018.04.109](https://doi.org/10.1016/j.wneu.2018.04.109)

Reference: WNEU 7945

To appear in: *World Neurosurgery*

Received Date: 10 January 2018

Revised Date: 16 April 2018

Accepted Date: 17 April 2018

Please cite this article as: Syed S, Karambizi DI, Baker A, Groh DM, Toms SA, Case Report: A Comparative Report on Intracranial Tumor-to-Tumor Metastasis and Collision Tumors, *World Neurosurgery* (2018), doi: 10.1016/j.wneu.2018.04.109.

This is a PDF file of an unedited manuscript that has been accepted for publication. As a service to our customers we are providing this early version of the manuscript. The manuscript will undergo copyediting, typesetting, and review of the resulting proof before it is published in its final form. Please note that during the production process errors may be discovered which could affect the content, and all legal disclaimers that apply to the journal pertain.

**Case Report: A Comparative Report on Intracranial Tumor-to-Tumor Metastasis
and Collision Tumors**

Sohail Syed¹, David I. Karambizi⁵, Amanda Baker⁴, Darren M. Groh³,

Steven A. Toms^{1,2}

Department of Neurosurgery¹; Normal Prince Neurosciences Institute²; Department of
Neuropathology³; Department of Radiology⁴; Warren Alpert Medical School of Brown
University⁵; Brown University: 222 Richmond Avenue Providence, RI 02903, USA

Corresponding Author:

Steven A. Toms, MD

Rhode Island Hospital

593 Eddy St

Providence, RI 02903, USA

Tel: (410) 793-9175

Fax: (401) 606-4012

Email: Steven.Toms@lifespan.org

Key words: Collision tumors, Tumor-to-tumor metastasis, Glioblastoma, Meningioma, Perfusion magnetic resonance (MR) imaging, Magnetic resonance (MR) spectroscopy.

Abbreviations used: CT, MRI, FLAIR, GBM, GFAP, TTF, Cho, Cr, NAA , FDG PET, NSCLC, MUC16, CA125, wnt

Abstract:

Background: The incidence of two distinct tumor types occupying the same anatomical location is rarely observed and may be accounted for by two separate mechanisms: Tumor to tumor metastasis and “collision” tumors where two adjacent tumors invade one another. These rare phenomena arise from distinct mechanisms, which may impact their preoperative recognition, surgical approach, and postoperative care. We will review two cases, highlighting their identification and perioperative management.

Case descriptions: In case 1, a 71-year-old patient with history of sphenoid wing meningioma presented with headache, nausea, vomiting and was found to have a mass with meningioma and glioblastoma (GBM) characteristics. In case 2, a 61-year-old male with worsening dysmetria in the setting of unintentional weight loss, presented with multiple masses in the pelvis, abdomen, lung, and brain. The brain masses were classified as meningioma with intra-tumoral metastatic adenocarcinoma foci.

Conclusion: Preoperative recognition of collision tumor and tumor-to-tumor metastasis is imperative for surgical planning including selecting regions for tissue biopsy and goals of care. Meticulous evaluation of history and imaging, and thorough pathological analysis allows for effective diagnosis and optimal patient outcomes.

Introduction

The anatomical co-localization of distinct tumors is a rare occurrence. Two such phenomena are presented in this report: a tumor-to-tumor metastasis and a collision tumor. These tumor types are often mistakenly used interchangeably in current literature. Collision tumors are generally characterized by the co-localization of two distinct malignancies arising within the same organ and growing into one another [1]. In contrast, a tumor-to-tumor metastasis is a tumor composed of a primary recipient mass into which a hematogenous metastatic donor arrives and establishes a secondary cancer [2]. The low prevalence of these intracranial tumor types is evidenced by the limited volume of reports in clinical publications, with approximately 30 cases reported on collision tumors and fewer than 100 reports on tumor-to-tumor metastasis over the past century [1- 4].

Given their hyper-vascularization and relatively high incidence intracranially, meningioma are the most commonly implicated intracranial neoplasms in both metastasis and collision tumors [4,5,6]. For a tumor to be classified as a tumor-to-tumor metastasis, the following criteria must be met: 1) the donor metastasis must be partially enclosed by a recipient benign primary neoplasm of the brain 2) the metastatic neoplasm must be shown to originate from a known primary carcinoma [1]. In a tumor-to-tumor metastasis mass, the recipient tumor, commonly a meningioma, most frequently receives metastatic foci from donor breast and lung cancer [5,7,8]. There have also been reports on metastatic foci originating from renal cell, prostate and thyroid carcinomas [1,5]. In comparison, a collision tumor is most typically the result of a tumor such as a meningioma forming adjacent to another intracranial tumor such as a schwannoma or pituitary adenoma and a craniopharyngioma [9,10]. The most commonly encountered collision tumor constitutes a meningioma and an astrocytoma [11,12,13].

Though both phenomena have been independently described in previous literature, they have seldom been juxtaposed in a single comprehensive, comparative study. The main objectives of this case report are to compare patient presentations, imaging findings, and medical/surgical management of these lesions as well as to discuss the underlying mechanism behind these rare intracranial tumors.

Case Summaries

Case 1: Collision Tumor Case

The first patient is a 71-year-old female with known history of right sphenoid wing meningioma, who presented initially to the emergency department with approximately 1 week of persistent headache, nausea, and dizziness. Physical examination revealed no focal neurological deficits. Patient was initially seen at an outside hospital where non-contrast computed tomography (CT) brain revealed a new right parieto-occipital mass. The patient underwent a magnetic resonance imaging (MRI) of the brain, showing a heterogeneously enhancing mass with cystic

components, as well as possible intraventricular involvement. As per radiology, differential included primary malignancy, lymphoma, and atypical meningioma. Patient was initially taken for stereotactic biopsy from which pathology revealed likely meningioma. Given patient's severe edema and mass effect, the patient underwent a craniotomy and resection of mass. Intraoperatively, a firm lesion was encountered in the atrium of the lateral ventricle. Surrounding the lateral ventricle was a soft, hypervascular lesion with necrosis. Pathology confirmed both an intraventricular meningioma component as well as a GBM. The patient had a benign post-operative course other than a visual field loss (a left inferior quadrantanopia) and underwent radiation therapy and concomitant temozolomide therapy for the GBM. She did well for the first 9 months postoperatively, before moving out of the region and being lost to follow-up.

Case 2 Tumor-to-tumor Metastasis Case

The second patient is a 61-year-old male, non-smoker, who presented to the emergency department with worsening dysmetria over two weeks as well as a 15lbs unintentional weight loss and poor exercise tolerance. Patient initially presented at an outside hospital where a non-contrast CT brain revealed a right-sided parasagittal mass with edema. CT of the chest, abdomen, and pelvis revealed a spiculated lung mass as well as liver lesions. MRI brain was obtained to further characterize the lesion and revealed a heterogeneously enhancing parasagittal mass with encasement of the sagittal sinus without any occlusion as well as a second remote site of osseous involvement of the left middle skull base was noted. Given history of lung mass, the primary diagnosis was likely metastatic disease. Patient underwent biopsy of his liver lesions, which revealed adenocarcinoma. Given this finding we elected to offer patient surgical resection of his parietal mass. Patient underwent bilaterally craniotomies overlying the affected region for resection. Patient operative course was without complication. Intraoperative pathological specimens revealed meningioma with intra-tumoral metastasis of patient's adenocarcinoma. The patient underwent chemotherapy for his lung primary lesion and brain radiotherapy. One year postoperatively, he is free of disease.

Proposed Mechanisms for Collision Tumors and Tumor-to-Tumor Metastasis

The exact mechanisms underlying the rare co-localization of these intracranial tumors have not yet been characterized. However, few potential mechanisms have been proposed to elucidate how collision tumors occur and how malignancies may metastasize to an intracranial mass.

The most recently suggested mechanism driving tumor-to-tumor metastasis involves the co-expression of molecular markers MUC16 and mesothelin in meningioma with intratumoral adenocarcinoma [15]. Adenocarcinomas are the most likely metastatic masses to ascend to intracranial meningioma [1,14]. Mesothelin, which is normally found on peritoneal, pericardial, and pleural mesothelium, has increased expression in meningioma. MUC16 or CA125 is a transmembrane, glycoprotein, mucin protein that is markedly found on metastatic adenocarcinoma [15, 16,19]. MUC16 has high affinity for mesothelin. The latter interaction between MUC16

and mesothelin is believed to play an integral role in facilitating the migration of metastatic adenocarcinoma to the brain [17,18,19]. It is however important to also note the potential, concurrent role of other metastatic processes such as alterations in expressions of metalloproteinases, e-cadherin levels and increased relative blood flow to meningioma. [20,24,26]. Furthermore, various criteria render meningioma an ideal recipient for tumor metastasis: 1) meningioma are very slow growing tumors, providing ample time for metastasis to develop and spread 2) there is increased potential for hematogenous spread due to hypervascularity 3) meningioma lack immune response to metastasis and hence permits their growth [32]. Therefore, meningiomas are a favorable milieu for metastasis. If one were to refer to Paget's proposed "soil and seed" hypothesis, meningioma represent a perfect soil or environment for metastases implantation. Briefly put, the seed and soil hypothesis maintains that a metastatic tumor cell may circulate to regions that are physiologically and biologically favorable for its implantation and development. Despite its robust barrier and a less well-characterized lymphatic drainage, the brain is considered an attractive destination (soil) for metastasis (seeds). Further understanding of the role of the perivascular niche and epigenetic mechanisms involved in metastasis will aid in the elucidation of preventative and therapeutic options for patients with brain metastases[40, 41, 31].

Though the pathogenesis of collision tumors remains unclear there is a host of proposed postulates enumerating the circumstances that make this tumor type possible. Some studies suggest that collision tumors are incidental and purely a result of statistical chance [21]. Others maintain that a histologically distinct intratumoral neoplasm may arise within a primary tumor secondary to prior surgery, trauma, or radiation therapy [22]. Lastly, an adjacent primary tumor, commonly a meningioma, may induce nearby cells to transform into distinct tumor types [6,23]. Transformations may be facilitated by certain driving genes/genetic changes that predispose brain tissues to tumorigenesis as well as via intracellular cross talk through mechanisms of communication such as exosomes [42]. Though there are a multitude of genetic mutations and effector protein alterations that may drive oncogenesis, some of the well-established tumorigenic pathways mutations are found in the wnt signaling and P53 pathways [33]. Genetic mutations in the wingless-related integration site (wnt) proto-oncogene pathway ranging from alterations in signaling/effector molecules such as APC and B-catenin to downregulation of e-cadherin are shown to play a significant role in tumorigenesis [34,35]. Down regulation of the key tumor suppressor p53 is known to facilitate oncogenesis. Cross talks between p53 and wnt signaling pathways have most recently been proposed [36]. Therefore, it is possible that intracranial tumors may induce tumorigenic mutations or epigenetic alterations in signal transduction pathways in adjacent brain parenchyma, thus facilitating the formation of tumor adjacent to the primary tumor. Continued growth of the adjacent neoplasms eventually coalesces into the collision tumors.

Radiologic Considerations

There are few reports discussing the radiologic features of co-localizing tumors, which allow for the preoperative identification of these entities to aid in

planning surgery and therapy. Meningiomas, which are the most implicated tumor types in both tumor-to-tumor metastasis and tumor collisions, generally appear as well-demarcated, intense homogenous contrast enhancing lesions on MRI and CT [32,38]. It has been reported that the presence of heterogeneous enhancement, mushroom pattern and irregular margins may be indicative of harbored metastasis [38]. Furthermore, foci of intense enhancement on a background of moderate enhancement on CT/MRI have been shown to pre-operatively identify tumor-to-tumor metastasis in some patients [39]. However, the reliability of these findings is questionable given that benign meningiomas are known to occasionally contain necrotic tissue and cyst. Therefore, there is no definite correlation between MRI/CT imaging pattern and histological diagnostics [32,38,39]. Ultimately, conventional anatomical imaging modalities such as CT and MRI, cannot always differentiate amongst intracranial masses, thus requiring more precise and valid pre-operative means of tumor type diagnosis. Physiology based neuro-imaging such as dynamic susceptibility weighted enhanced contrast perfusion MR and MR spectroscopy represents noninvasive means of specifically characterizing and differentiating tumor types [26].

Perfusion MR imaging relies on regional hemodynamic differentiation based on tumor types microvasculature whereas MR spectroscopy depends on metabolic composition of the tumors. This allows for noninvasive imaging-based differentiation between extra-axial tumors such as meningioma/ metastases and intra-axial tumor masses [26,27]. Due to the hyper-vascularity relative to mucin-filled metastasis, meningioma show a greater T2 intensity drop and therefore greater relative blood volume compared to metastases [27]. In some cases, peak height and percentage of signal recovery intensity derived from perfusion MR can play a crucial in the differentiation of similarly appearing malignant tumors, such as GBM and metastasis [30].

Furthermore, with MR spectroscopy disparate tumor types have different metabolites composition. Generally, most tumors, including metastasis, have increased choline (Cho) with decreased creatine (Cr) and N-acetyl-aspartate (NAA). Gliomas possess significantly increased Cho and lipid that correlates with tumor grading [28,29]. Metastases, like high-grade gliomas, tend to have high Cho, however the latter have more lipid formation in comparison. Meningioma and other extra-axial tumors can be differentiated from other tumor types due to very low levels of NAA [29]. Ultimately, even with such excellent imaging modalities, histopathologic diagnosis in conjunction with patient history remains the golden standard for tumor type evaluation.

Discussion

In the two cases described in this report, preoperative suspicion of collision tumor and tumor-to-tumor metastasis were entertained, facilitating surgical planning. Case one, the meningioma / GBM collision tumor, shows distinct features on MRI suggesting the presence of distinct tumor types. Non-contrasted CT upon emergency room presentation showed a hyperdense lesion with calcified flecks and extensive vasogenic edema suggestive of meningioma or metastasis (Fig. 1A). T2 weighted MRI

demonstrated a hypointense solid intracentricular lesion capped by a mixed intensity lesion with extensive edema (Fig. 1B). Contrast enhancement illustrated the solidly enhancing central, intraventricular core with a multicystic, enhancing parenchymal lesion (Fig. 1C). Although the patient had undergone biopsy showing meningioma, it was not felt that the brain parenchymal lesion was compatible with meningioma and possibly represented a malignant tumor such as lymphoma, metastasis, or, more likely, GBM and the patient underwent definitive craniotomy and gross total resection of both the intraventricular meningioma and the surrounding GBM (Fig. 1D.).

Pathology showed two distinct lesions. The meningioma was WHO Grade 1 transitional type with multiple whorls of tumor cells and no mitoses or other atypical features (Fig. 2A). The parenchymal lesion surrounding the atrium of the lateral ventricle demonstrated hypercellularity, pleomorphism and geographic necrosis consistent with GBM (Fig 2B). When the two tissues were stained for glial fibrillary acidic protein, the meningioma (top of slide) was largely negative while the GBM component at the bottom was strongly positive for GFAP (Fig. 2C).

In the second case, the patient had both clinical and radiographic clues that the lesion was not a simple parasagittal meningioma. First, the patient had unexplained 15-pound weight loss over the past several months. MRI showed bony calvarial erosion and extensive edema consistent with meningioma on FLAIR sequences. However, there were mixed intensity areas within the lesion not consistent with cyst formation typically seen in a meningioma (Fig 3A). Sagittal contrast enhanced MRI shows differential enhancement within the lesion and poorly defined borders (Fig. 3B). Given the clinical suspicion for atypical meningioma or metastasis, a chest, abdomen, and pelvis CT was performed. The axial lung windows demonstrated a mass in the right upper lobe consistent with lung primary (Fig 3C). Given the edema, mass effect, and lack of diagnosis, a decision was made to debulk the lesion to establish diagnosis and improve the existing mass effect on the brain. One year after surgery and radiotherapy, the patient remains disease free. (Fig. 3D).

The tumor-to-tumor metastasis pathological examination showed many bland meningotheelial cells surrounded by a large cell pleomorphic tumor with many mitotic figures (Fig. 4A). The large cells stained positive for antibody to TTF-1 (Fig. 4B), confirming the suspicions of a lung cancer primary in this patient with abrupt weight loss and a lung lesion.

Diagnosis of collision tumor can have significant management implications perioperatively. The nature of diagnostic management may appropriately expand when a previously thought to be CNS primary reveals to involve a metastatic focus. An expanded imaging regimen may require additional CT imaging, FDG PET and scintigraphy may be warranted given associated clinical concerns in the setting of solid malignancy like NSCLC [43]. In cases of hematopoietic malignancies, bone marrow biopsy may be required as well to assess for systemic involvement [44]. Post diagnosis, care must be coordinated with the appropriate hematology and/or oncology teams to

arrange for appropriate work up, management and continued surveillance of the systemic disease/metastatic disease.

Comprehensive and systemic review of 175 cases reported to date on these rare intracranial tumor lesions demonstrates that approximately 1/3 of all such reported cases are collision tumors and about 2/3 are tumor-to-tumor metastasis [2, 3, 4, 5, 8, 10, 13, 49-131]. The most prevalently reported intracranial collision type is the meningioma/astrocytoma combination, constituting a little less than 1/3 of all reported intracranial collision cases [13, 49-62]. Other comparatively less common but fairly reported collision cases are meningioma/schwannoma and pituitary adenoma/craniopharyngioma combinations [63-78]. The most common intracranial tumor-to-tumor metastases are the breast cancer or lung cancer to meningioma combinations [2, 5, 7, 8, 79-119]. The most prevalent donors, which contribute in more than half of all tumor-to-tumor metastasis cases, are lung and breast carcinoma; while the most common recipients are meningioma, comprising more than 3/4 of all recipients [2, 5, 7, 8, 79-131]. Surgical planning may be complicated by pathology as well. Highly vascular tumors may benefit from pre-operative angiographic embolization or intraoperative glue/cement based embolization prior to surgical resection [45]. In the cases of radiosensitive tumors, collisions may increase resistance to treatment modality and require more aggressive surgical management than in isolation as has been described in literature outside the CNS [46]. Post-operative chemo-radiation paradigms must similarly be tailored appropriately to address the components of collision lesions [47,48].

REFERENCES

1. Kochanski RB, Byrne N, Arvanitis L, Bhabad S, Byrne RW. A rare intracranial tumor consisting of malignant anaplastic and papillary meningioma subtypes. *Surg Neurol Int.* 2016;7:21.
2. Petraki C, Vaslamatzis M, Argyrakos T, et al. Tumor to tumor metastasis: report of two cases and review of the literature. *International Journal of Surgical Pathology.* 2003;11(2):127–135.
3. Fried BM. Metastatic Inoculation of a Meningioma by Cancer Cells from a Bronchiogenic Carcinoma. *Am J Pathol.* 1930;6:47–52.
4. Benedetto N, Perrini P, Scollato A, Buccoliero AM, Di Lorenzo N. Intracranial meningioma containing metastatic colon carcinoma. *Acta Neurochir (Wien).* 2007;149:799–803.
5. Lanotte M, Benech F, Panciani PP, Cassoni P, Ducati A. Systemic cancer metastasis in a meningioma: report of two cases and review of the literature. *Clin Neurol Neurosurg.* 2009;111:87–93.
6. Maiuri F, Cappabianca P, Iaconetta G, Esposito F, Messina A. Simultaneous presentation of meningiomas with other intracranial tumours. *Br J Neurosurg.* 2005;19:368–75.
7. Baratelli GM, Ciccaglioni B, Dainese E, Arnaboldi L. Metastasis of breast carcinoma to intracranial meningioma. *J Neurosurg Sci.* 2004;48:71–3.
8. Ravnik J, Ravnik M, Bunc G, Glumbic I, Tobi-Veres E, Velnar T. Metastasis of an occult pulmonary carcinoma into meningioma: A case report. *World J Surg Oncol.* 2015;13:292.
9. Furtado SV, Venkatesh PK, Ghosal N, Hegde AS. Coexisting intracranial tumors with pituitary adenomas: genetic association or coincidence? *J Cancer Res Ther.* 2010;6:221–3.
10. Zhang D, Yu J, Guo Y, Zhao S, Shao G, Huang H. An intraventricular meningioma and recurrent astrocytoma collision tumor: A case report and literature review. *World J Surg Oncol.* 2015;13:37.
11. Goyal A, Singh AK, Sinha S, Tatke M, Singh D, Gupta V. Simultaneous occurrence of meningioma and glioma in brain: report of two cases. *J Clin Neurosci.* 2003;10 (2):252–254
12. Lee EJ, Chang CH, Wang LC, Hung YC, Chen HH. Two primary brain tumors, meningioma and glioblastoma multiforme, in opposite hemispheres of the same patient. *J Clin Neurosci.* 2002; 9(5):589-91.
13. Hasimu A, Fu Q, Zhou Q, Li S, Zhu X, Liu C, et al. Astrocytoma simultaneously present with Meningioma-a report of two cases and review of the literature. *Chinese Neurosurgical Journal .* 2016;2:9.
14. Singh EO, Benson RC, Jr., Wold LE. Cancer-to-cancer metastasis. *Journal of Urology.* 1984;132 (2):340–342.
15. Mahlon DJ et. al. Do mesothelin/MUC16 interactions facilitate adenocarcinoma metastasis to intracranial meningiomas? *Surg Neurol Int.* 2016;7(41): S1049–S1052.
16. Gubbels JA, Belisle J, Onda M, Rancourt C, Migneault CM, Ho M, et al. Mesothelin-MUC16 binding is a high affinity, N-glycan dependent interaction that facilitates peritoneal metastasis of ovarian tumors. *Mol Cancer.* 2006;5:50–65.
17. Hassan R, Bera T, Pastan I. Mesothelin: A new target for immunotherapy. *Clin Cancer Res.* 2004;10:3937–42.

18. Rump A, Morikawa Y, Tanaka M, Minami S, Umesaki N, Takeuchi M, et al. Binding of ovarian cancer cell antigen CA125/MUC16 to mesothelin mediates cell adhesion. *J Biol Chem*. 2004;279:9190–8.
19. Hollingsworth MA, Swanson BJ. Mucins in cancer: Protection and control of the cell surface. *Nat Rev Cancer*. 2004;4:45–60.
20. Bohle AS, Kalthoff H. Molecular mechanism of tumor metastasis and angiogenesis. *Langenbeck's Arch Surg*. 1999;384:133–140.
21. Strong AJ, Symon L, MacGregor BJ, O'Neill BP. Coincidental meningioma and glioma. Report of two cases. *J Neurosurg*. 1976;45(4):455–8.
22. Pereira EA, Dabbous B, Qureshi HU, Ansorge O, Bojanic S. Rapid development of glioblastoma at the site of atypical meningioma resection. *Br J Neurosurg*. 2010;24:471–3.
23. Vaquero J, Coca S, Martínez R, Jiménez C. Convexity meningioma and glioblastoma in collision. *Surg Neurol*. 1990 Feb;33(2):139–41.
24. Siddique K, Yanamandra N, Gujrati M, Dinh D, Rao JS, Olivero W. Expression of matrix metalloproteinases, their inhibitors, and urokinase plasminogen activator in human meningiomas. *Int J Oncol*. 2003;22:289–294.
25. Shimada S, Ishizawa K, Hirose T. Expression of E-cadherin and catenins in meningioma: Ubiquitous expression and its irrelevance to malignancy. *Pathol Int*. 2005;55:1–7.
26. Moody P, Murtagh K, Piduru S, et al. Tumor-to-tumor metastasis: pathology and neuroimaging considerations. *Int J Clin Exp Pathol*. 2012;5(4):367–73.
27. Jun P, Garcia J, Tihan T, McDermott MW, Cha S. Perfusion MR imaging of an intracranial collision tumor confirmed by image-guided biopsy. *AJNR Am J Neuroradiol*. 2006;27:94–97.
28. Moller-Hartmann W, Herminghaus S, Krings T, Marquardt G, Lanfermann H, Pilatus U, Zanella FE. Clinical application of proton magnetic resonance spectroscopy in the diagnosis of intracranial mass lesions. *Neuroradiology*. 2002;44:371–381.
29. Server A, Josefsen R, Kulle B, Maehlen J, Schellhorn T, Gadmar Ø, Kumar T, Haakonsen M, Langberg CW, Nakstad PH. Proton magnetic resonance spectroscopy in the distinction of high-grade cerebral gliomas from single metastatic brain tumors. *Acta Radiol*. 2010;51:316–325.
30. Cha S, Lupo JM, Chen MH, Lamborn KR, McDermott MW, Berger MS, et al. Differentiation of glioblastoma multiforme and single brain metastasis by peak height and percentage of signal intensity recovery derived from dynamic susceptibility-weighted contrast-enhanced perfusion MR imaging. *AJNR Am J Neuroradiol*. 2007;28:1078–1084.
31. Ramakrishna R, Rostomily R. Seed, soil, and beyond: The basic biology of brain metastasis. *Surg Neurol Int*. 2013;4:S256–64.
32. Abrahao-Machado L, Abrahao-Machado E, Abrahao-Machado E, Guimaraes F, et al. Tumor-to-tumor metastasis: Intracranial meningioma harboring metastatic breast carcinoma. *Ann Clin Pathol*. 2015;3(2):1049.
33. Pećina-Šlaus N, Kafka A, Lechpammer M. Molecular genetics of intracranial meningiomas with emphasis on canonical Wnt signalling. *Cancers*. 2016;8:67.
34. Pećina-Šlaus N, Nikuševa Martić T, Tomas D, Beroš V, Zeljko M, Cupić H. Meningiomas exhibit loss of heterozygosity of the APC gene. *J Neurooncol*. 2008;87:63–70.

35. Utsuki S, Oka H, Sato Y, Kawano N, Tsuchiya B, Kobayashi I, Fujii K. Invasive meningioma is associated with a low expression of E-cadherin and beta-catenin. *Clin. Neuropathol.* 2005;24:8–12.
36. Pećina-Šlaus N, Kafka A, Vladušić T, Tomas D, Logara M, Skoko J, Hrašćan, R. Loss of p53 expression is accompanied with upregulation of beta-catenin in meningiomas: A concomitant reciprocal expression. *Int. J. Exp. Pathol.* 2016;97:159–169.
37. Lee A, Wallace C, Rewcastle B, Sutherland G. Metastases to meningioma. *AJNR Am J Neuroradiol.* 1998;19:1120-1122.
38. Watanabe T, Fujisawa H, Hasegawa M, Arakawa Y, Yamashita J, Ueda F. Metastasis of breast cancer to intracranial meningioma: case report. *Am J Clin Oncol.* 2002;25: 414-417.
39. Benedetto N, Perrini P, Scollato A, Buccoliero AM, Di Lorenzo N. Intracranial meningioma containing metastatic colon carcinoma. *Acta Neurochir (Wien).* 2007;149:799-803.
40. Murgai M, Ju W, Eason M, Kline J, Beury DW, Kaczanowska S, Miettinen MM, Kruhlak M, Lei H, Shern JF, Cherepanova OA, Owens GK, Kaplan RN. KLF4-dependent perivascular cell plasticity mediates pre-metastatic niche formation and metastasis. *Nat Med.* 2017;23(10):1176-1190.
41. Svokos KA, Salhia B, Toms SA. Molecular biology of brain metastasis. *Int J Mol Sci.* 2014;15:9519–30.
42. Qian Z, Shen Q, Yang X, Qiu Y, Zhang W. The Role of Extracellular Vesicles: An Epigenetic View of the Cancer Microenvironment. *Biomed Res Int.* 2015;2015:649161.
43. Purandare C, Rangarajan V. Imaging of lung cancer: Implications on staging and management. *Indian J Radiol Imaging.* 2015;25(2):109-120.
44. Ban S, Chaudhary R, Allinson K, Santarius T, Kirillos W. Concomitant Primary CNS Lymphoma and FSH-Pituitary Adenoma Arising Within the Sella. Entirely Coincidental? *Neurosurgery.* 2017;80(1):E170-E175.
45. Johnson J, Morcos J, Elhammady M, Pao L, Aziz-Sultan A. Renal cell carcinoma metastasis to the cerebellopontine cistern: intraoperative Onyx embolization via direct needle puncture. *BMJ Case Rep.* 2013.
46. Untch R, Shia J, Downey J, Carrasquillo A, Panicek M, Strong E. Imaging and management of a small cell lung cancer metastasis/adrenal adenoma collision tumor: a case report and review of the literature. *World J Surg Oncol.* 2014;12:45.
47. Chang H, Horton J, Schoenfeld D, Salazer O, Perez-Tamayo. Comparison of postoperative radiotherapy and combined postoperative radiotherapy and chemotherapy in the multidisciplinary management of malignant gliomas. A joint Radiation Therapy Oncology Group and Eastern Cooperative Oncology Group study. *Cancer.* 1983;52(6):997-1007.
48. Lo S, Chang L, Sahgal A. Radiosurgery for resected brain metastases-a new standard of care? *Lancet Oncol.* 2017;18(8):985-987.
49. Rotondo M, Parlato C, Zotta DC, Moraci A. Simultaneous multiple brain tumors of different histological nature. Report of two cases. *J Neurosurg Sci.* 1990;34:57–60.
50. Ruiz J, Capilla E, Díaz JF, et al. Secretory meningioma with KLF4 K409Q mutation in collision with glioma. *Clin Neuropathol.* 2015;34(6):322-9.

51. Zhao Y, Zhang H, Lian W, et al. Collision tumors composed of meningioma and growth hormone-secreting pituitary adenoma in the sellar region: Case reports and a literature review. Li. S, ed. *Medicine*. 2017;96(50):e9139.
52. Tanaka J, Garcia JH, Netsky MG, Williams JP. Late appearance of meningioma at the site of partially removed oligodendroglioma. Case report. *J Neurosurg*. 1975;43(1):80-5.
53. Khalatbari M, Borghei-razavi H, Shayanfar N, Behzadi AH, Sepehrnia A. Collision tumor of meningioma and malignant astrocytoma. *Pediatr Neurosurg*. 2010;46(5):357-61.
54. Mitsos AP, Konstantinou EA, Fotis TG, Lafazanos SA, Kontogeorgos G, Georgakoulis NV. Sphenoid wing meningioma and glioblastoma multiforme in collision - case report and review of the literature. *Neurol Neurochir Pol*. 2009;43(5):479-83.
55. Fortuniak J, Jaskólski DJ, Zawirski M, Tybor K. Glioblastoma multiforme and meningioma in the same patient - a case report. *Neurol Neurochir Pol*. 2007;41(3):272-5.
56. Chen G, Gao X, Liao Y, Xu B. A glioblastoma adjacent to a meningioma. *Br J Neurosurg*. 2010;24(6):718-9.
57. Hakan T. A case of sphenoid wing meningioma and glioblastoma multiforme in collision. *Neurol Neurochir Pol*. 2010;44(1):102.
58. Yaghmour W, Kurdi ME, Baeesa SS. De novo glioblastoma in the territory of a recent middle cerebral artery infarction and a residual meningioma: pathogenesis revisited. *World Journal of Surgical Oncology*. 2016;14:112.
59. Vaquero J, Coca S, Martínez R, Jiménez C. Convexity meningioma and glioblastoma in collision. *Surg Neurol*. 1990;33(2):139-41.
60. Malhotra V, Beohar PC, Paul DN, Kumar S. Meningioma in association with astrocytoma--a case report. *Indian J Cancer*. 1983;20(1A):86-8.
61. Krajewski R, Wisławski J. [Simultaneous occurrence of meningioma and astrocytoma]. *Neurol Neurochir Pol*. 1979;13(4):455-8.
62. Prayson RA, Chowdhary S, Woodhouse S, Hanson M, Nair S. Collision of a syncytial meningioma and malignant astrocytoma. *Ann Diagn Pathol*. 2002;6(1):44-8.
63. Jin G, Hao S, Xie J, Mi R, Liu F. Collision tumors of the sella: coexistence of pituitary adenoma and craniopharyngioma in the sellar region. *World Journal of Surgical Oncology*. 2013;11:178.
64. Finzi G, Cerati M, Marando A, et al. Mixed pituitary adenoma/craniopharyngioma: clinical, morphological, immunohistochemical and ultrastructural study of a case, review of the literature, and pathogenetic and nosological considerations. *Pituitary*. 2014;17(1):53-9.

65. Asada H, Otani M, Furuhata S, Inoue H, Toya S, Ogawa Y. Mixed pituitary adenoma and gangliocytoma associated with acromegaly--case report. *Neurol Med Chir.* 1990;30(8):628-32.
66. Tajika Y, Kubo O, Takeshita M, Tajika T, Shimizu T, Kitamura K. [An intracranial collision tumor composed of intrasellar gangliocytoma and pituitary adenoma]. *No Shinkei Geka.* 1989;17(12):1181-6.
67. Karavitaki N, Scheithauer BW, Watt J, et al. Collision lesions of the sella: co-existence of craniopharyngioma with gonadotroph adenoma and of Rathke's cleft cyst with corticotroph adenoma. *Pituitary.* 2008;11(3):317-23.
68. Yoshida A, Sen C, Asa SL, Rosenblum MK. Composite pituitary adenoma and craniopharyngioma?: an unusual sellar neoplasm with divergent differentiation. *Am J Surg Pathol.* 2008;32(11):1736-41.
69. Asari J, Yamanobe K, Sasaki T, Yamao N, Kodama N. [A case of prolactinoma associated with craniopharyngioma]. *No Shinkei Geka.* 1987;15(12):1313-8.
70. Matyja E, Maksymowicz M, Grajkowska W, et al. Ganglion cell tumours in the sella turcica in close morphological connection with pituitary adenomas. *Folia Neuropathol.* 2015;53(3):203-18.
71. Kim DG, Paek SH, Chi JG, Chun YK, Han DH. Mixed tumour of schwannoma and meningioma components in a patient with NF-2. *Acta Neurochir (Wien).* 1997;139(11):1061-4.
72. Muzumdar DP, Goel A. Acoustic schwannoma and petroclival meningioma occurring as collision tumours: a case report. *J Clin Neurosci.* 2004;11(2):207-10.
73. Gelal F, Rezanko T, Uyaroglu MA, Tunakan M, Bezircioglu H. Islets of meningioma in an acoustic schwannoma in a patient with neurofibromatosis-2: pathology and magnetic resonance imaging findings. *Acta Radiol.* 2005;46(5):519-22.
74. Elizabeth J, Menon G, Nair S, Radhakrishnan VV. Mixed tumour of schwannoma and meningioma in a patient with neurofibromatosis-2: A case report. *Neu India.* 2001;49:398-400.
75. Izi Y, Secer HI, Gönül E, Ongürü O. Simultaneously occurring vestibular schwannoma and meningioma in the cerebellopontine angle: case report and literature review. *Clin Neuropathol.* 2007;26(5):219-23.
76. Sakai Y, Hirose T, Tomono A, et al. Angiosarcoma arising in schwannoma of cerebellopontine angle and later associating with meningioma in a patient with neurofibromatosis type 2. *Brain Tumor Pathol.* 2014;31(4):293-8.

77. Graffeo CS, Perry A, Copeland WR, et al. Synchronous Tumors of the Cerebellopontine Angle. *World Neurosurg.* 2017;98:632-643.
78. Verma SK, Kumar S, Deb P, Yadav KK. Rare case of radiologically distinct but pathologically admixed vestibular schwannoma and meningioma in the cerebellopontine angle: A case report. *J Cancer Res Ther.* 2015;11(4):1029.
79. Miyagi N, Hara S, Terasaki M, et al. [A rare case of intracranial meningioma with intratumoral metastatic breast cancers]. *No Shinkei Geka.* 2007;35(9):901-5.
80. Okada E, Nakamura M, Koshida Y, Mukai K, Toyama Y, Matsumoto M. Breast carcinoma metastasis to meningioma in the thoracic spine: A case report and review of the literature. *The Journal of Spinal Cord Medicine.* 2015;38(2):231-235.
81. Pamphlett R. Carcinoma metastasis to meningioma. *Journal of Neurology, Neurosurgery, and Psychiatry.* 1984;47(5):561-563.
82. Hockley AD. Metastatic carcinoma in a spinal meningioma. *Journal of Neurology, Neurosurgery, and Psychiatry.* 1975;38(7):695-697.
83. Caroli E, Salvati M, Giangaspero F, Ferrante L, Santoro A. Intrameningioma metastasis as first clinical manifestation of occult primary breast carcinoma. *Neurosurg Rev.* 2006;29:49-54.
84. Dadlani R, Ghosal N, Hegde AS. An unusual metastasis from a breast carcinoma to a psammomatous tuberculum sella meningioma. *Journal of Neurosciences in Rural Practice.* 2013;4(2):233-234.
85. Lin JW, Su FW, Wang HC, Lee TC, Ho JT, Lin CH, et al. Breast carcinoma metastasis to intracranial meningioma. *J Clin Neurosci.* 2009;16:1636-9.
86. Sayegh ET, Burch EA, Henderson GA, Oh T, Bloch O, Parsa AT. Tumor-to-tumor metastasis: breast carcinoma to meningioma. *J Clin Neurosci.* 2015;22(2):268-74.
87. Elmaci L, Ekinici G, Kurtkaya O, Sav A, Pamir MN. Tumor in tumor metastasis of breast of breast carcinoma to intracranial meningioma. *Tumori.* 2001;87(6):423-7.
88. Seckin H, Yigitkanli K, Ilhan O, Han U, Bavbek M. Breast carcinoma metastasis and meningioma. A case report. *Surgical neurology.* 2003;66(3), 324-327.
89. Völker U, Thierauf P. [Tumor in tumore: breast cancer metastasis in a meningioma]. *Pathologe.* 1993;14(4):231-3.
90. Fornelli A, Bacci A, Collina G, Eusebi V. [Breast carcinoma metastatic to meningioma: review of the literature and description of 2 new cases]. *Pathologica.* 1995;87(5):506-12.

91. Cervoni L, Salvati M, Gagliardi D, Delfini R. Metastasis of breast carcinoma to intracranial meningioma. Case report. *Neurosurg Rev.* 1994;17(3):233-6.
92. Doron Y, Gruszkiewicz J. Metastasis of invasive carcinoma of the breast to an extradural meningioma of the cranial vault. *Cancer.* 1987;60(5):1081-4.
93. Bucciero A, del Basso de Caro M, Vizioli L, Carraturo S, Cerillo A, Tedeschi G. Metastasis of breast carcinoma to intracranial meningioma. Case report and review of the literature. *J Neurosurg Sci.* 1992;36(3):169-72.
94. Lee A, Wallace C, Rewcastle B, Sutherland G. Metastases to meningioma. *AJNR Am J Neuroradiol.* 1998;19(6):1120-2.
95. Watanabe T, Fujisawa H, Hasegawa M, Arakawa Y, Yamashita J, Ueda F, Suzuki M. Metastasis of breast cancer to intracranial meningioma: case report. *Am J Clin Oncol.* 2002;25(4):414-7.
96. Aghi M, Kiehl TR, Brisman JL. Breast adenocarcinoma metastatic to epidural cervical spine meningioma: case report and review of the literature. *J Neurooncol.* 2005;75(2):149-55.
97. McCormack M, Rosa CS, Murphy M, Fox SB. HER2-positive breast cancer metastatic to intracranial meningioma: a case report. *J Clin Pathol.* 2013;66(7):633-4.
98. Di Bonito L, Bianchi C. [Metastasis from a breast cancer in a meningioma]. *Sem Hop.* 1979;55(3-4):171-2.
99. Nunnery E Jr, Kahn LB, Rudnick SA. Breast carcinoma metastatic to meningioma. *Arch Pathol Lab Med.* 1980;104(7):392-3.
100. Joglekar VM, Davis CH, Blakeney CG. Metastasis of carcinoma to meningioma and glioma. *Acta Neurochir (Wien).* 1981;58(1-2):67-74.
101. Pablo LJ, Patricia C, Julián I, Ariel Z, Roberto S, Jorge C, Juan L, Carlos V, Bernardo L. Metastasis of breast carcinoma to spinal meningioma. *Breast J.* 2009;15(5):539-107. Chou LW, Ho KH, Fong CM. Intracranial meningioma with metastatic breast carcinoma. *Ann Oncol.* 1992;3(5):409-10.
102. Lodrini S, Savoiaro M. Metastases of carcinoma to intracranial meningioma: report of two cases and review of the literature. *Cancer.* 1981;48(12):2668-73.
103. Fabaron F, Bainier L, Vendé B, Babin P, Morin M [Metastasis of breast cancer in frontal meningioma]. *Ann Radiol (Paris).* 1990;33(1):48-50.
104. Hamperl M, Goehre F, Schwan S, et al. Tumor-to-tumor metastasis--bronchial carcinoma in meningioma. *Clin Neuropathol.* 2015;34(5):302-6.

105. Conzen M, Sollmann H, Schnabel R. Metastasis of lung carcinoma to intracranial meningioma. Case report and review of literature. *Neurochirurgia (Stuttg)*. 1986;29(5):206-9.
106. Talukdar A, Khanra D, Mukhopadhyay S, Bose D. Tumor to tumor metastasis: adenocarcinoma of lung metastatic to meningioma. *J Postgrad Med*. 2014;60(4):403-5.
107. Reynolds MR, Crilly SM, Sweeny KJ, Farrell M, Rawluk D. Metastatic pancreatic neuroendocrine tumor to the central nervous system in a patient with Von Hippel-Lindau disease. A case report and literature review. *Br. J Neurosurg*. 2015;29(2)291-3.
108. Bhargava P, Mcgrail KM, Manz HJ, Baidas S. Lung carcinoma presenting as metastasis to intracranial meningioma: case report and review of the literature. *Am J Clin Oncol*. 1999;22(2):199-202.
109. Duprez R, Thimon S, Kerdraon R, Bonneau C, Metois D, Michenet P. [Tumor-to-tumor metastasis: report of three cases]. *Ann Pathol*. 2009;29(6):507-11.
110. Takei H, Powell SZ. Tumor-to-tumor metastasis to the central nervous system. *Neuropathology*. 2009;29(3):303-8.
111. Bori R, Kiss CA, Huszka E, Szûcs M, Tusa M, Cserni G. [A rare case of tumor-to-tumor metastasis: secondary deposits of pulmonary adenocarcinoma in a secretory meningioma]. *Magy Onkol*. 2002;46(3):261-4.
112. Cheng YJ, Wu JT, Chen HY, Wang KH, Tsai JW, Liliang PC, Chang PC. Coexistence of intracranial meningioma, pulmonary meningiomas, and lungcancer. *Ann Thorac Surg*. 2011;91(4):1283-5.
113. Weems TD, Garcia JH. Intracranial meningioma containing metastatic foci. *South Med J*. 1977;70(4):503-5.
114. Wolintz AH, Mastri A. Metastasis of carcinoma of lung to sphenoid ridge meningioma. *N Y State J Med*. 1970;70(20):2592-8.
115. Gardiman M, Altavilla G, Marchioro L, Alessio L, Parenti A, Piazza M. Metastasis to intracranial meningioma as first clinical manifestation of occult primary lung carcinoma. *Tumori*. 1996;82(3):256-8.
116. Arnold AC, Hepler RS, Badr MA, Lufkin RB, Anzai Y, Konrad PN, Vinters HV. Metastasis of adenocarcinoma of the lung to optic nerve sheath meningioma. *Arch Ophthalmol*. 1995;113(3):346-51.
117. Jomin M, Dupont A, Wemeau J, Krivosic I, Montagne B, Lesoin F, Adenis L. [Metastasis of visceral tumors in intracranial tumors. Apropos of a metastasis of a lung cancer in an intracranial meningioma]. *Neurochirurgie*. 1982;28(5):343-7.

118. Smith TW, Wang SY, Schoene WC. Malignant carcinoid tumor metastatic to a meningioma. *Cancer*. 1981;47(7):1872-7.
119. Martin SE, Al-khatib SM, Turner MS, Douglas-akinwande AC, Hattab EM. A 41-year-old woman with von Hippel-Lindau and a cerebellar lesion. *Brain Pathol*. 2010;20(2):511-4.
120. Altinoz MA, Santaguida C, Guiot MC, Del maestro RF. Spinal hemangioblastoma containing metastatic renal cell carcinoma in von Hippel-Lindau disease. Case report and review of the literature. *J Neurosurg Spine*. 2005;3(6):495-500.
121. Hamazaki S, Nakashima H, Matsumoto K, Taguchi K, Okada S. Metastasis of renal cell carcinoma to central nervous system hemangioblastoma in two patients with von Hippel-Lindau disease. *Pathol Int*. 2001;51(12):948-53.
122. Dessauvagie BF, Wong G, Robbins PD. Renal cell carcinoma to haemangioblastoma metastasis: a rare manifestation of Von Hippel-Lindau syndrome. *J Clin Neurosci*. 2015;22(1):215-8.
123. Abou-hamden A, Koszyca B, Carney PG, Sandhu N, Blumbergs PC. Metastasis of renal cell carcinoma to haemangioblastoma of the spinal cord in von Hippel-Lindau disease: case report and review of the literature. *Pathology*. 2003;35(3):224-7.
124. Xiong J, Chu SG, Wang Y, Zhu JJ, Li C, Mao Y. Metastasis of renal cell carcinoma to a haemangioblastoma of the medulla oblongata in von Hippel-Lindau syndrome. *J Clin Neurosci*. 2010;17(9):1213-5.
125. Bret P, Streichenberger N, Guyotat J. Metastasis of renal carcinoma to a cerebellar hemangioblastoma in a patient with von Hippel Lindau disease: a case report. *Br J Neurosurg*. 1999;13(4):413-6.
126. Martin SE, Al-Khatib SM, Turner MS, Douglas-Akinwande AC, Hattab EM. A 41-year-old woman with von Hippel-Lindau and a cerebellar lesion. *Brain Pathol*. 2010;20(2):511-4.
127. Mottolese C, Stan H, Giordano F, Frappaz D, Alexei D, Streichenberger N. Metastasis of clear-cell renal carcinoma to cerebellar hemangioblastoma in von Hippel Lindau disease: rare or not investigated? *Acta Neurochir (Wien)*. 2001;143(10):1059-63.
128. Polydorides AD, Rosenblum MK, Edgar MA. Metastatic renal cell carcinoma to hemangioblastoma in von Hippel-Lindau disease. *Arch Pathol Lab Med*. 2007;131(4):641-5.
129. Jamjoom A, Kane N, Nicoll J. Metastasis of a renal carcinoma to a cerebellar haemangioblastoma in a case of von Hippel-Lindau disease. *Neurosurg Rev*. 1992;15(3):231-4.

130. Altinoz MA, Santaguida C, Guiot MC, Del Maestro RF. Spinal hemangioblastoma containing metastatic renal cell carcinoma in von Hippel-Lindau disease. Case report and review of the literature. *J Neurosurg Spine*. 2005;3(6):495-500.
131. Heng LJ, Jia D, Gong L, Zhang W, Ma J, Qu Y. Endoscopic Endonasal Resection of a Mixed Lesion of Gangliocytoma and Nonfunctioning Pituitary Adenoma. *World Neurosurg*. 2017;106:1050.e1-1050.e6.
132. Tanriover N, Aydin O, Kucukyuruk B, et al. Endoscopic approach to a collision tumor of growth hormone-secreting adenoma and gangliocytoma in the pituitary gland. *J Craniofac Surg*. 2014;25(4):1277-9.
133. Rivera J, Alves S, Bianchi CC, Al-mutawa N, Guiot MC, Zeitouni A. An unusual collision tumor comprising a prolactinoma and a plasmocytoma originating from the sellar region. *Pituitary*. 2010;13(2):189-93.
134. Sahli R, Christ E, Kuhlen D, Giger O, Vajtai I. Sellar collision tumor involving pituitary gonadotroph adenoma and chondroma: a potential clinical diagnosis. *Pituitary*. 2011;14(4):405-8.
135. Ban VS, Chaudhary BR, Allinson K, Santarius T, Kirollos RW. Concomitant Primary CNS Lymphoma and FSH-Pituitary Adenoma Arising Within the Sella. Entirely Coincidental?. *Neurosurgery*. 2017;80(1):E170-E175.
136. Jukes A, Allan R, Rawson R, Buckland ME. Growth hormone secreting pituitary adenoma with admixed gangliocytoma and ganglioglioma. *J Clin Neurosci*. 2016;31:202-4.
137. Georgiu C, Mihuț E, Raus I, Mirescu ȘC, Szabo L, Șovrea AS. Pediatric glioblastoma with giant cells and "supratentorial" primitive neuroectodermal component - case report and review of the literature. *Rom J Morphol Embryol*. 2015;56(3):1165-71.
138. Matyja E, Maksymowicz M, Grajkowska W, et al. Ganglion cell tumours in the sella turcica in close morphological connection with pituitary adenomas. *Folia Neuropathol*. 2015;53(3):203-18.
139. Takahashi-fujigasaki J, Matumoto M, Kan I, Oka H, Yasue M. Atypical teratoid/rhabdoid tumor with 26-year overall survival: case report. *J Neurosurg Pediatr*. 2012;9(4):400-5.
140. Hattab EM, Martin SE, Shapiro SA, Cheng L. Pleomorphic xanthoastrocytoma and oligodendroglioma: collision of 2 morphologically and genetically distinct anaplastic components. *J Neurosurg*. 2011;114(6):1648-53.
141. Perry A, Scheithauer BW, Szczesniak DM, Atkinson JL, Wald JT, Hammak JE. Combined oligodendroglioma/pleomorphic xanthoastrocytoma: a probable collision tumor: case report. *Neurosurgery*. 2001;48(6):1358-61.

142. López JI, Scheithauer BW, Giannini C, Torp SH. Concurrent solitary fibrous tumor and low-grade fibrillary astrocytoma of the cerebellum. *Clin Neuropathol*. 2010;29(5):301-6.
143. Muzumdar DP, Goel A, Desai KI. Pontine glioma and cerebellopontine angle epidermoid tumour occurring as collision tumours. *Br J Neurosurg*. 2001;15(1):68-71.
144. Spinner RJ, Scheithauer BW, Perry A, Amrami KK, Emmett R, Gutmann DH. Colocalized cellular schwannoma and plexiform neurofibroma in the absence of neurofibromatosis. Case report. *J Neurosurg*. 2007;107(2):435-9.
145. George B, Kumar R, Johns P, Bartlett RJ, O'Brien D. Contiguous synchronous occurrence of primary cerebral lymphoma and meningioma. *Br J Neurosurg*. 2007;21(1):35-8.
146. Binello E, Bederson JB, Kleinman GM. Hemangiopericytoma: collision with meningioma and recurrence. *Neurol Sci*. 2010;31(5):625-30.
147. Hayashi Y, Kimura M, Kinoshita A, Hasegawa M, Yamashita J. Meningioma associated with intraosseous lipoma. *Clin Neurol Neurosurg*. 2003;105(3):221-4.
148. Omeis I, Hillard VH, Braun A, Benzil DL, Murali R, Harter DH. Meningioangiomas associated with neurofibromatosis: report of 2 cases in a single family and review of the literature. *Surg Neurol*. 2006;65(6):595-603.
149. Zenke K, Sakaki S, Nakagawa K. Association of meningioma and ependymoma-case report. *Neurol Med Chir*. 1992;32(4):220-4
150. Shah, A., Goel, A., & Goel, N. (2010). A case of cerebellopontine angle epidermoid tumor and brainstem squamous cell carcinoma presenting as collision tumor. *Acta Neurochirurgica*, 152, 1087-1088.
151. Wanifuchi H, Kadowaki H, Kubo O, Kitamura K. [Intracranial collision tumor composed of ganglioglioma and meningioma. Case report]. *Neurol Med Chir*. 1988;28(2):195-9.
152. Cheng HX, Chu SG, Xu QW, Wang Y. spinal tumor showing mixed features of ependymoma and hemangioblastoma: a case report and literature review. *Brain Tumor Pathol*. 2015;32(2):112-8.
153. Ghosal N, Kumaran SP, Furtado SV, Hegde AS. Mixed schwannoma with meningioma - report on 2 cases of unusual tumor with review of literature. *Clin Neuropathol*. 2012;31(5):374-8.
154. Tajika Y, Reifenberger G, Kiwit JC, Wechsler W. Metastatic adenocarcinoma in cerebral astrocytoma: clinicopathological and immunohistochemical study with review of the literature. *Acta Neurochir (Wien)*. 1990;105(1-2):50-5.

155. Mörk SJ, Rubinstein LJ. Metastatic carcinoma to glioma: a report of three cases with a critical review of the literature. *Journal of Neurology, Neurosurgery, and Psychiatry*. 1988;51(2):256-259.
156. Zhang C, Yang AI, Vasconcelos L, Moon S, Yang C, Nesvick CL, Saidkhodjaeva L, Abdullaev Z *et. al.* Von hippel-lindau disease associated pulmonary carcinoid with cranial metastasis. *J Clin Endocrinol Metab*. 2014;99(8):2633-6
157. Bhojwani N, Huang J, Gupta A, Badve C, Cohen ML, Wolansky LJ. Rectal carcinoid tumor metastasis to a skull base meningioma. *The Neuroradiology Journal*. 2016;29(1):49-51.
158. Chatani M, Nakagawa I, Yamada S, Sugimoto T, Hironaka Y, Nakamura M, Nakase H. Intracranial meningioma as initial clinical manifestation of occult lung carcinoma: case report. *Neurol Med Chir* . 2014;54(8):670-2.
159. Sonet A, Hustin J, De Coene B, Gilliard C, Gustin T, Doyen C, Vandenbossche L *et. al.* Unusual growth within a meningioma (leukemic infiltrate). *Am J Surg Pathol*. 2001;25(1):127-30.
160. Han HS, Kim EY, Han JY, Kim YB, Hwang TS, Chu YC. Metastatic renal cell carcinoma in a meningioma: a case report. *Journal of Korean Medical Science*. 2000;15(5):593-597.
161. Tsunoo M, Meoded A, Bonetti M, Gasparotti R. MR imaging of metastatic renal cell carcinoma to a meningioma. *J Neuroradiol*. 2010;37(4):248-50.
162. Breadmore R, House R, Gonzales M. Metastasis of renal cell carcinoma to a meningioma. *Australas Radiol*. 1994;34(2):144-3.
163. Carr K, He L, Weaver K, Highfield Nickols H. Renal cell carcinoma metastatic to meningioma: tumor-to-tumor metastasis. *Clin Neuropathol*. 2014;33(2):152-6.
164. Vetrano A, Addeo R, Russo I, Meo G, De Rosa G, D'Anna F, Caraglia M. A case of clear renal cell cancer associated to meningioma and verrucous carcinoma of frontal region in an old patient. *J Exp Clin Cancer Res*. 2007;26(1):157-9.
165. Mitchell RA, Dimou J, Tsui A, *et al.* Metastatic prostate adenocarcinoma invading an atypical meningioma. *J Clin Neurosci* 2011;18:1723–5.
166. Bernstein RA, Grumet KA, Wetzel N. Metastasis of prostatic carcinoma to intracranial meningioma. Case report. *J Neurosurg*. 1983;58:774–777.
167. Döring L. Metastasis of carcinoma of prostate to meningioma. *Virchows Arch A Pathol Anat Histol*. 1975;366:87–91.

168. Cluroe AD. Metastasis to meningioma: Clues and investigation. *Pathology*. 2006; 38:76-78.
169. Pugsley D, Bailly G, Gupta R, Wilke D, Wood L. A case of metastatic adenocarcinoma of the prostate arising in a meningioma. *Can Urol Assoc J*. 2009;3:E4–E6.
170. Chambers PW, Davis RL, Blanding JD, Buck FS. Metastases to primary intracranial meningiomas and neurilemmomas. *Arch Pathol Lab Med*. 1980;104:350–354.
171. Guraya SS, Prayson RA. Metastatic prostatic adenocarcinoma with neuroendocrine differentiation to meningioma. *J Clin Neurosci*. 2016;34:30-32.
172. Shinde SV, Shenoy AS, Savant HV, Balasubramaniam SB. Coexistent intracerebral metastatic melanoma and meningioma. *Neurol India*. 2017;65(1):110-112
173. Chance A, Liu JJ, Raskin JS, Zhrebetskiy V, Gultekin SH, Raslan AM. Thoracic primary central nervous system melanoma and lumbar schwannoma of complex neurocristopathy: case report. *J Neurosurg Spine*. 2015;23(6):780-3.
174. Ling M, Wong T, Bui CD, Atlas S, Li JJ, Yang T, Harvey S, Flack JR. Tumor within another tumor: an unusual case of metastatic poorly differentiated thyroid carcinoma within an intracranial meningioma. *J Clin Endocrinol Metab*. 2014;99(10):3513-4.
175. Wu WQ, Hiszczynskij R. Metastasis of carcinoma of cervix uteri to convexity meningioma. *Surg Neurol*. 1977;8(5):327-9.
176. Das S, Chaudhary N, Ang LC, Megyesi JS. Papillary thyroid carcinoma metastasizing to anaplastic meningioma: an unusual case of tumor-to-tumor metastasis. *Brain Tumor Pathol*. 2017;34(3):130-134.
177. Campos paiva AL, Vitorino araujo JL, Ferraz VR, Esteves veiga JC. Simultaneous meningioma and brain metastasis from renal cell carcinoma - a rare presentation. Case report. *Sao Paulo Med J*. 2017;135(3):296-301.
178. Richter B, Harinath L, Pu C, Stabingas K. Metastatic spread of systemic neoplasms to central nervous system tumors: review of the literature and case presentation of esophageal carcinoma metastatic to meningioma. *Clin Neuropathol*. 2017;36(2017):60-65.
179. Noh MG, Moon KS, Kim IY, Lee JH, Lee KH. Tumor-to-tumor metastasis of breast carcinoma to cervical spinal schwannoma: Case report. *Br J Neurosurg*. 2015;29(3):435-7.
180. Reynolds MR, Crilly SM, Sweeney KJ, Farrell M, Rawluk D. Metastatic pancreatic neuroendocrine tumor to the central nervous system in a patient with von Hippel-Lindau disease: A case report and literature review. *Br J Neurosurg*. 2015;29(2):291-3.

181. Lua BK, Lieu AS, Hwang SL. Breast carcinoma metastasized to vestibular schwannoma: a rare case of tumor-to-tumor metastasis and literature review. *Kaohsiung J Med Sci.* 2012;28(7):397-9.
182. Gazic B, Pizem J. Lobular breast carcinoma metastasis to a superficial plexiform schwannoma as the first evidence of an occult breast cancer. *Am J Dermatopathol.* 2011;33(8):845-9.
183. Fukushima Y, Ota T, Mukasa A, Uozaki H, Kawai K, Saito N. Tumor-to-tumor metastasis: lung adenocarcinoma metastasizing to vestibular schwannoma suspected on preoperative [18F]-fluorodeoxyglucose positron emission tomography imaging. *World Neurosurg.* 2012;78(5):553.e9-553.e13.
184. Pal D, Bhargava D, Bucur SD, Shivane A, Chakrabarty A, Van hille P. Metastatic malignant melanoma within meningioma with intratumoral infarct: report of an unusual case and literature review. *Clin Neuropathol.* 2010;29(2):105-8.
185. Williams MD, Asa SL, Fuller GN. Medullary thyroid carcinoma metastatic to the pituitary gland: an unusual site of metastasis. *Ann Diagn Pathol.* 2008;12(3):199-203.
186. Brown HM, Mccutcheon IE, Leeds NE, Schomer DS, Luna MA, Fuller GN. Melanoma metastatic to central neurocytoma: a novel case of tumor-to-tumor metastasis. *J Neurooncol.* 2003;61(3):209-14.
187. Wong A, Koszyca B, Blumbergs PC, Sandhu N, Halcrow S. Malignant melanoma metastatic to a meningioma. *Pathology.* 1999;31(2):162-5.
188. Han HS, Kim EY, Han JY, Kim YB, Hwang TS, Chu YC. Metastatic renal cell carcinoma in a meningioma: a case report. *J Korean Med Sci.* 2000;15(5):593-7.
189. Tally PW, Laws ER Jr, Scheithauer BW. Metastases of central nervous system neoplasms. Case report. *J Neurosurg.* 1988;68(5):811-6.
190. Mizutani H, Suzuki H, Wakabayashi S, Mitake A, Mizutani M, Banno T *et al.* [A case of metastasis from a colon carcinoma to an intracranial oligodendroglioma]. *Gan No Rinsho.* 1987;33(13):1733-9.
191. Lu J, Frater JL, Kreisel FH, Marcus JN, Hassan A. Secondary Lymphoma Involving Metastatic Follicular Thyroid Carcinoma to the Skull: A Unique Example of Tumor-to-Tumor Metastasis. *Head and Neck Pathology.* 2008;2(3):209-212.

FIGURE LEGENDS

Figure 1: 71-year-old female with known history of meningioma who presented with headache and dizziness. Glioblastoma multiforme and meningioma were surgically proven. A-B, Axial unenhanced CT (A), axial T2 weighted (B) images show a large predominantly solid mass containing specks of calcium as well as multiple cystic areas and extensive vasogenic edema. Abnormal signal extends into the splenium of the corpus callosum. Axial contrast-enhanced T1-weighted images (C) show homogenous enhancement of the solid component corresponding to known meningioma as well as ring-enhancement of the cystic components and subependymal enhancement suggestive of a centrally necrotic, invasive glioblastoma multiforme. Postoperative axial contrast-enhanced T1-weighted MR images show a gross total resection of both lesions (D).

Figure 2: Pathology of Case 1 showed two distinct lesions. The meningioma component was WHO Grade 1 transitional type with multiple whorls of tumor (A). The parenchymal lesion surrounding the atrium of the lateral ventricle demonstrated hypocellularity, pleomorphism and geographic necrosis consistent with GBM (B). The meningioma (top of slide) was largely negative while the GBM component at the bottom was strongly positive for GFAP (C).

Figure 3: 61-year-old male with dysmetria and weight loss. Metastatic adenocarcinoma involving meningioma proven at biopsy. A and B, Axial FLAIR (A) and sagittal contrast-enhanced T1-weighted (B) images show a midline heterogeneously enhancing mass centered on the parieto-occipital sulcus with extensive edema and osseous destruction of the inner table of the calvarium. The mass encases the superior sagittal sinus. An axial unenhanced CT image of the chest (C) demonstrates a spiculated right lower lobe mass consistent with primary lung adenocarcinoma. One year postoperatively, sagittal contrast-enhanced T1-weighted MRI shows that the patient remains free of intracranial disease (D).

Figure 4: Case 2 pathological examination showed many meningothelial cells surrounded by a large cell pleomorphic tumor with many mitotic figures (A). The large cells stained positive for antibody to TTF-1 (B), confirming the suspicions of a lung cancer primary.

Table 1.

Intracranial Collision Tumors		Intracranial Tumor-to-Tumor Metastases	
Total Cases		Total Cases	
(67)		(108)	
Case Prevalence		Case Prevalence	
Meningioma/Astrocytoma (19)	[13] [49-62]	Breast Carcinoma to Meningioma (31)	[5][7][79-104]
Pituitary Adenoma/Craniopharyngioma (10)	[63-70]	Lung Carcinoma to Meningioma (19)	[2][8] [105-118]
Schwannoma/Meningioma (10)	[71-78]	Renal Cell Carcinoma to Hemangioblastoma (13)	[119-130]
Others (28)	[supplemental]	Others (45)	[supplemental]
Contributing Tumor Subtype		Contributing Tumor Subtype	
<u>Common Contributors</u>		Donors	Recipients
Meningioma (39)		Breast Carcinoma (34)	Meningioma (81)
Pituitary Adenoma (21)		Lung Carcinoma (24)	Hemangioblastoma (15)
Schwannoma (12)		Renal Cell Carcinoma (21)	Others (12)
Craniopharyngioma (11)		Prostate Adenocarcinoma (10)	
Others [supplemental]		Others (21)	

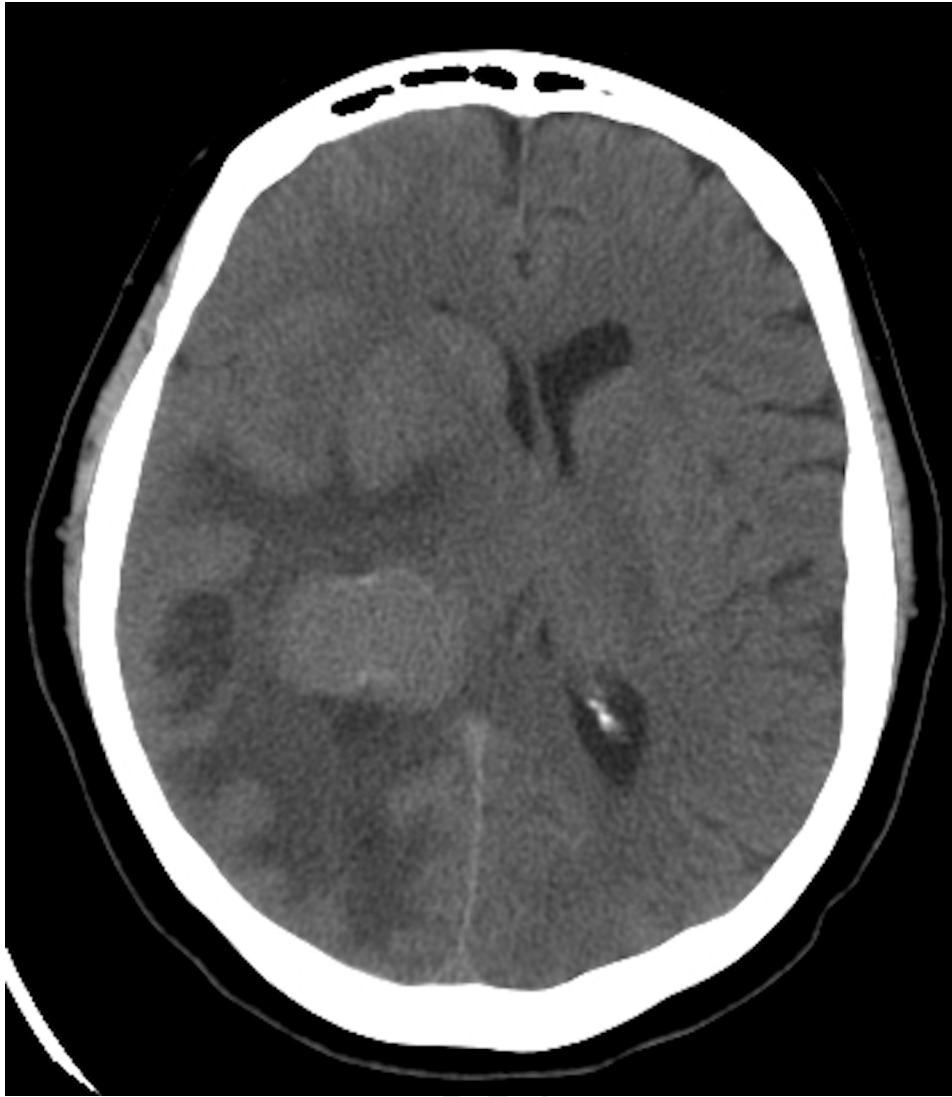Table 1. The top half of the table denotes highest percent prevalence of reported intracranial collision tumors and tumor-to-tumor metastasis cases by tumor type combination. The bottom half shows degree of tumor subtypes involvement in reported intracranial collision tumor cases and donor/recipient percent prevalence in reported tumor-to-tumor metastasis. Note: numbers in parenthesis represents number of cases.

Table 2. Supplemental Content

Intracranial Collision Tumors	Intracranial Tumor-to-Tumor Metastases	
Total Cases	Total Cases	
(67)	(108)	
Case Prevalence	Case Prevalence	
<u>Common Cases</u> Meningioma/Astrocytoma (19) Pituitary Adenoma/Craniopharyngioma (10) Schwannoma/Meningioma (10) <u>Others (28)</u> [3] [10] [131-153] Meningioangiomas/Meningioma (2) Pleomorphic Xanthoastrocytoma/Oligodendroglioma (2) Pituitary/Gangliocytoma (2) Meningioma/Pituitary Adenoma (3) Pituitary Adenoma/ Astrocytoma (1) Pituitary Adenoma/Ganglioglioma (2) Pituitary Adenoma/Plasmocytoma (1) Pituitary Adenoma/Chondroma (1) Pituitary Adenoma/Lymphoma (1) Meningioma/Ependymoma (1) Meningioma/Gangliocytoma (1) Meningioma/Introsseous Lipoma (1) Anaplastic Meningioma/Papillary Meningioma (1) Meningioma/CNS lymphoma (1) Meningioma/Hemangiopericytoma (1) Ependymoma/Hemangioblastoma (1) Solitary Fibrous Tumor/astrocytoma (1) Supratentorial Primitive Neuroectodermal Tumor/astrocytoma (1) schwannoma/Atypical Teratoid and Rhabdoid (1) Schwannoma/Neurofibroma (1) Pontine glioma/Cerebellar Pontine Angle Epidermoid tumor (1) Brainstem Squamous Cell Carcinoma/Epidermoid Tumor (1)	<u>Common Cases</u> Breast Carcinoma to Meningioma (31) Lung Carcinoma to Meningioma (19) Renal Cell Carcinoma to Hemangioblastoma (13) <u>Others (46)</u> [4] [5][26] [154-192] Renal Cell Carcinoma to Meningioma (7) Breast Carcinoma to Schwannoma (2) Lung Carcinoma to Schwannoma (2) Lung Carcinoma to Astrocytoma (3) Lung Carcinoma to Ependymoma (1) Papillary Thyroid Carcinoma to Anaplastic Meningioma (1) Thyroid carcinoma to Meningioma (1) Cervical Carcinoma to Meningioma (1) Esophageal Carcinoma to Meningioma (1) Prostatic Adenocarcinoma to Meningioma (9) Pituitary Carcinoma to Meningioma (1) Rectal Adenocarcinoma to Meningioma (1) Colorectal Carcinoma to Meningioma (3) Schwannoma to Meningioma (1) Melanoma to Meningioma (3) Melanoma to Schwannoma (1) Leukemia to Meningioma (1) Thyroid Carcinoma Pituitary Adenoma (1) Thyroid Carcinoma and B-Cell Lymphoma to Brain (1) Pancreatic Neuroendocrine Tumor to Hemangioblastoma (1) Breast Carcinoma to Oligodendroglioma (1) Colon Cancer to Oligodendroglioma (1) Melanoma to Central Neurocytoma(1)	
Contributing Tumor Subtype	Contributing Tumor Subtype	
<u>Common Contributors:</u> Meningioma (39) Pituitary Adenoma (21) Schwannoma (12) Craniopharyngioma (11)	Donors	Recipients
	<u>Common Donors</u> Breast Carcinoma (34) Lung Carcinoma (24) Renal Cell Carcinoma (21) Prostate Adenocarcinoma (9) <u>Others (21)</u> Melanoma (5) Colorectal Carcinoma (5) Thyroid Carcinoma (4) Cervical carcinoma (1) Esophageal Carcinoma (1) Pancreatic Neuroendocrine Tumor(1) Schwannoma (1) Pituitary Carcinoma (1) B-cell Lymphoma (1) Leukemia (1)	<u>Common Recipients</u> Meningioma (81) Hemangioblastoma (15) <u>Others (12)</u> Schwannoma (4) Astrocytoma (3) Oligodendroglioma (2) Ependymoma (1) Pituitary Adenoma (1) Central Neurocytoma (1)

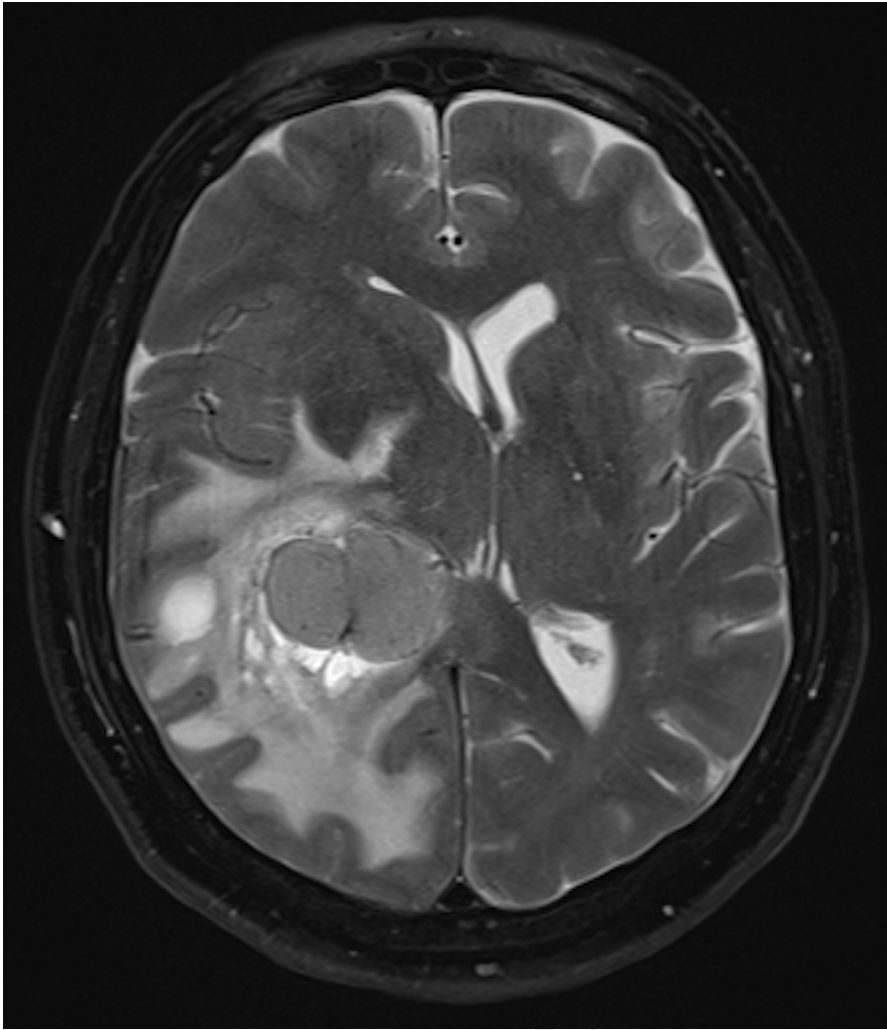
Table 2. Supplemental Content

ACCEPTED MANUSCRIPT



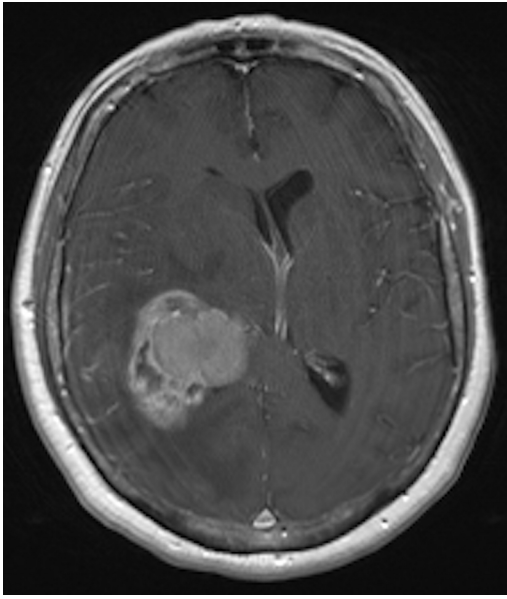
ACCEPTED MANUSCRIPT

ACCEPTED MANUSCRIPT

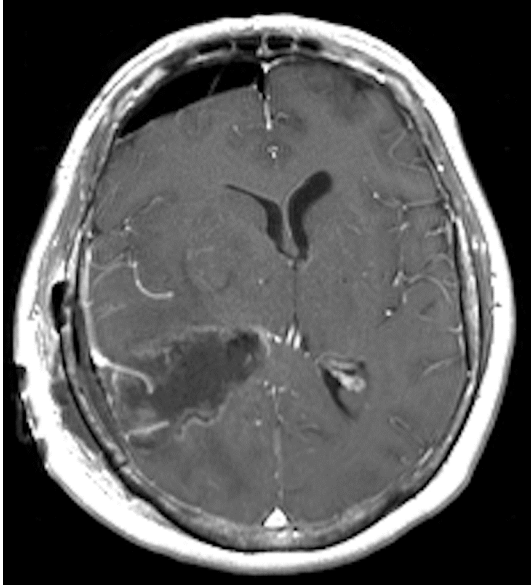


ACCEPTED

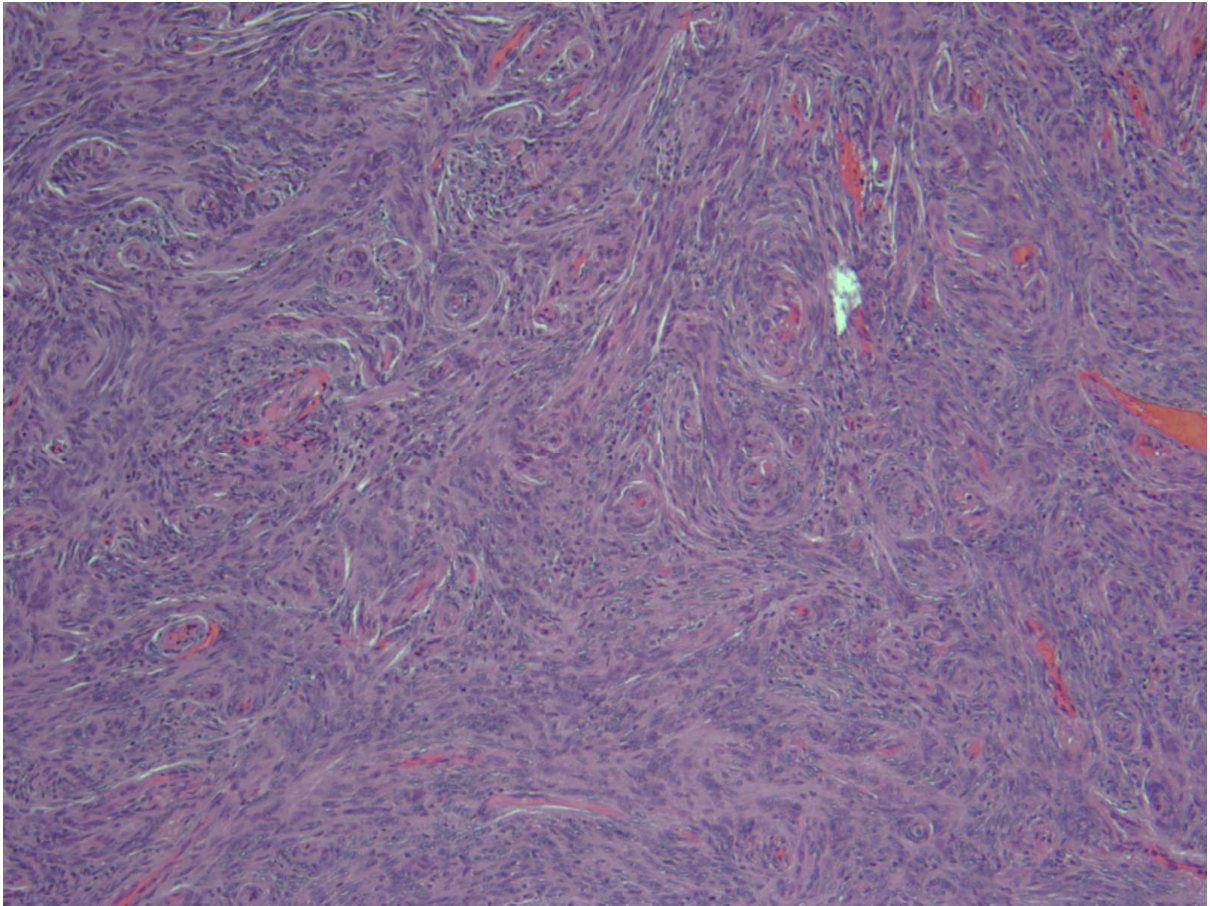
SCRIPT



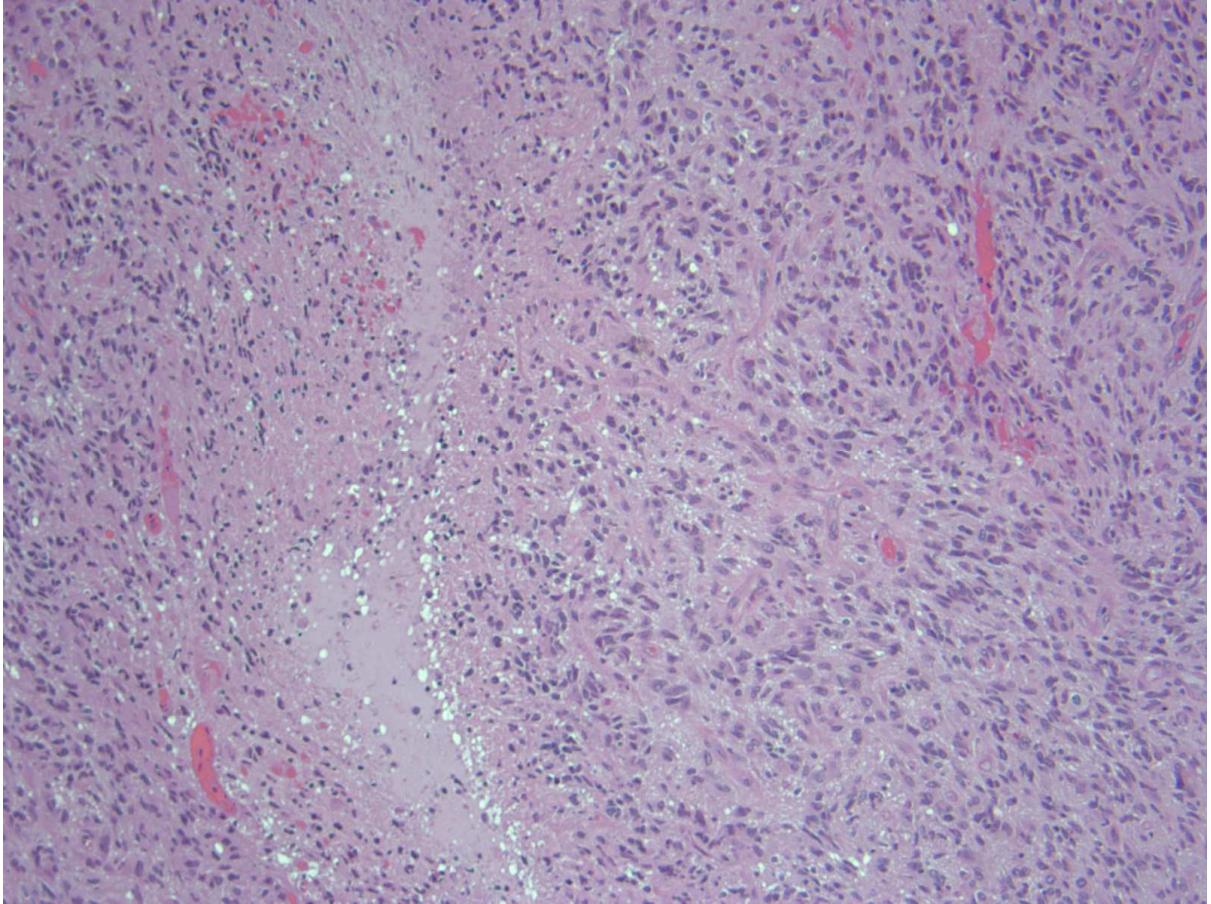
ACCEPTED MANUSCRIPT



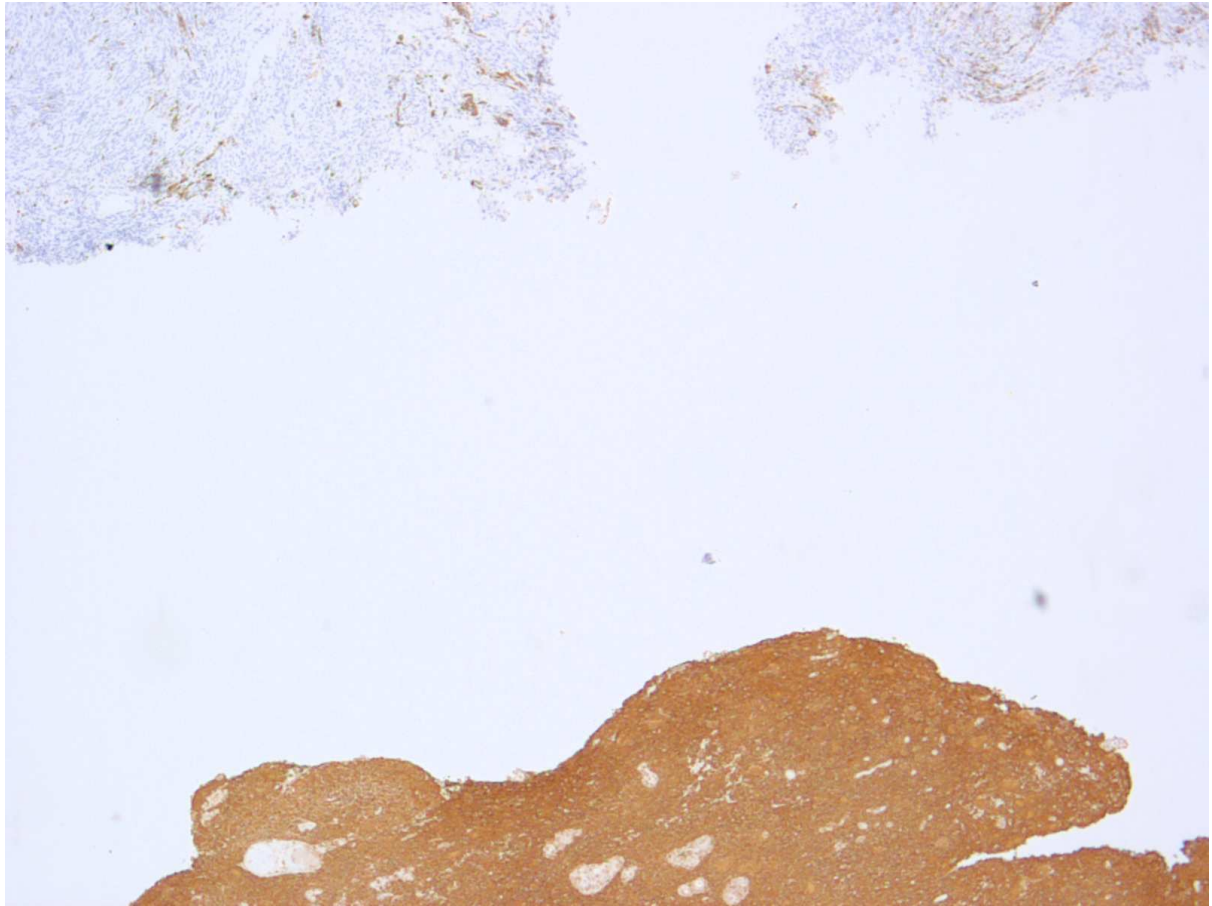
ACCEPTED MANUSCRIPT



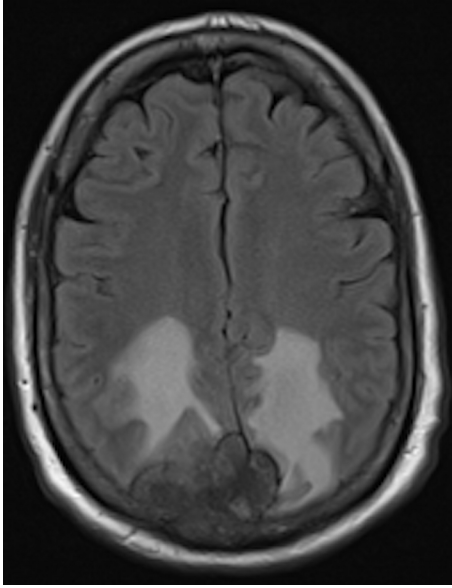
ACCEPTED MANUSCRIPT



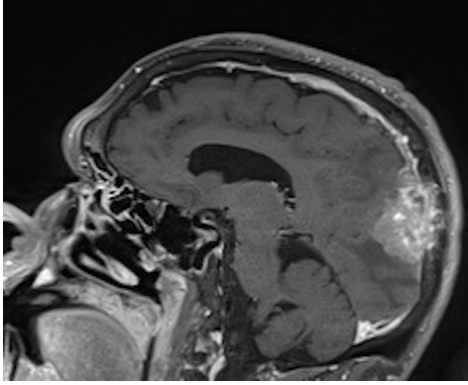
ACCEPTED MANUSCRIPT



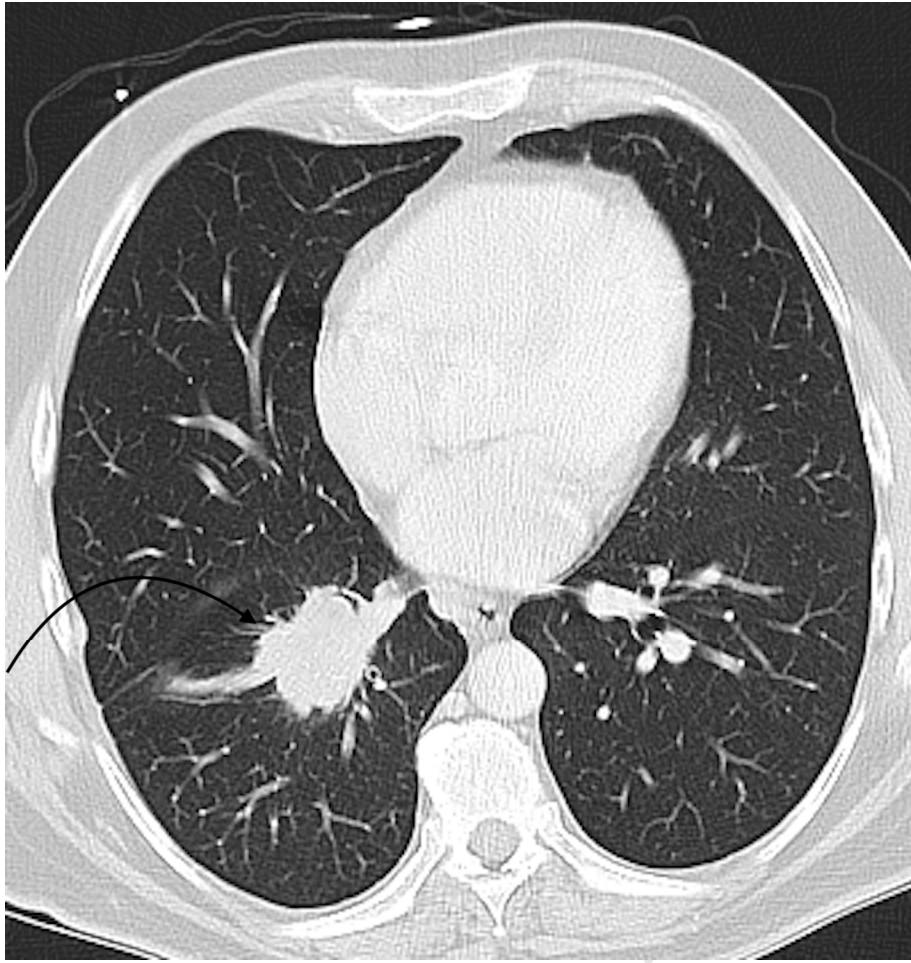
ACCEPTED MANUSCRIPT



ACCEPTED MANUSCRIPT

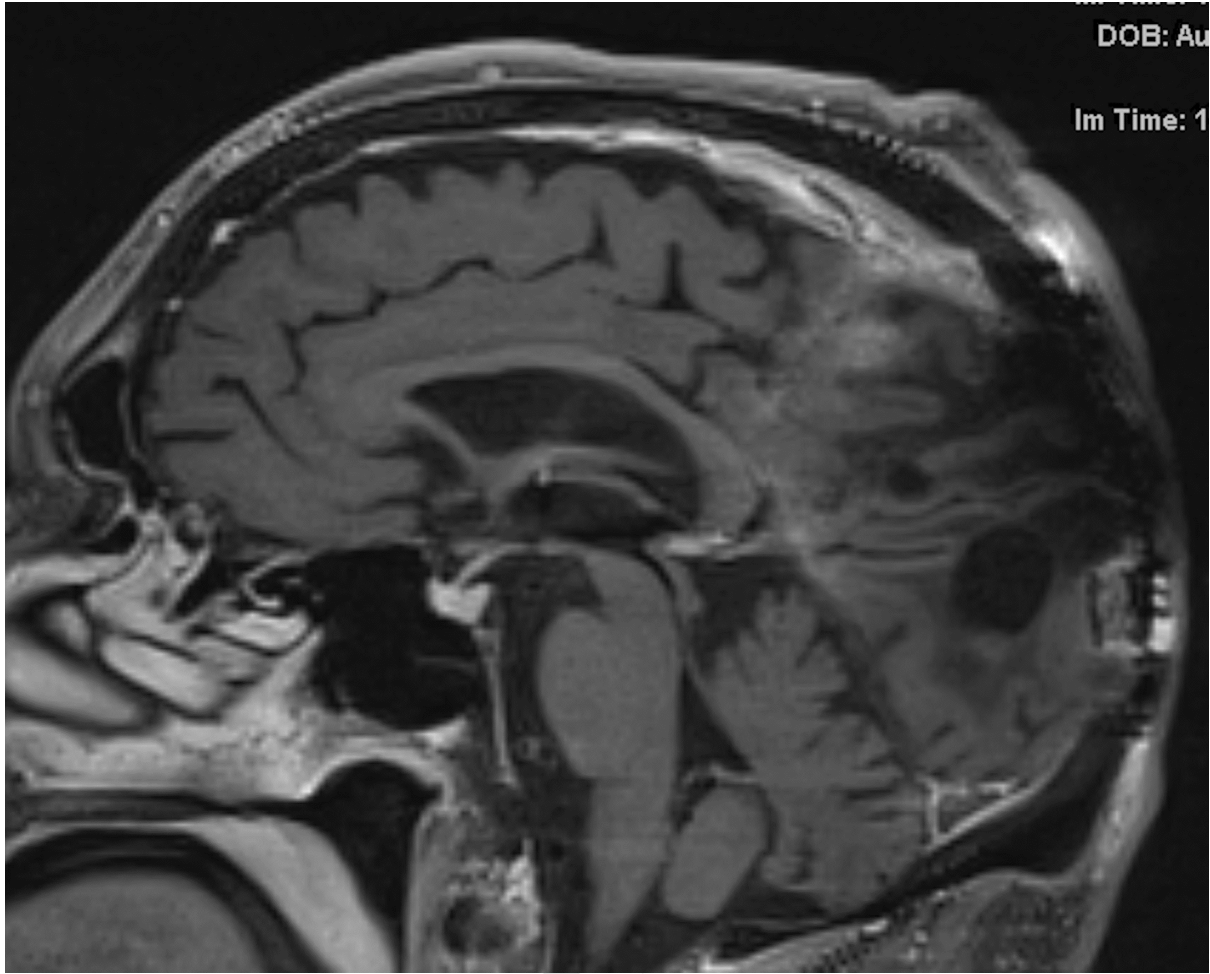


ACCEPTED MANUSCRIPT

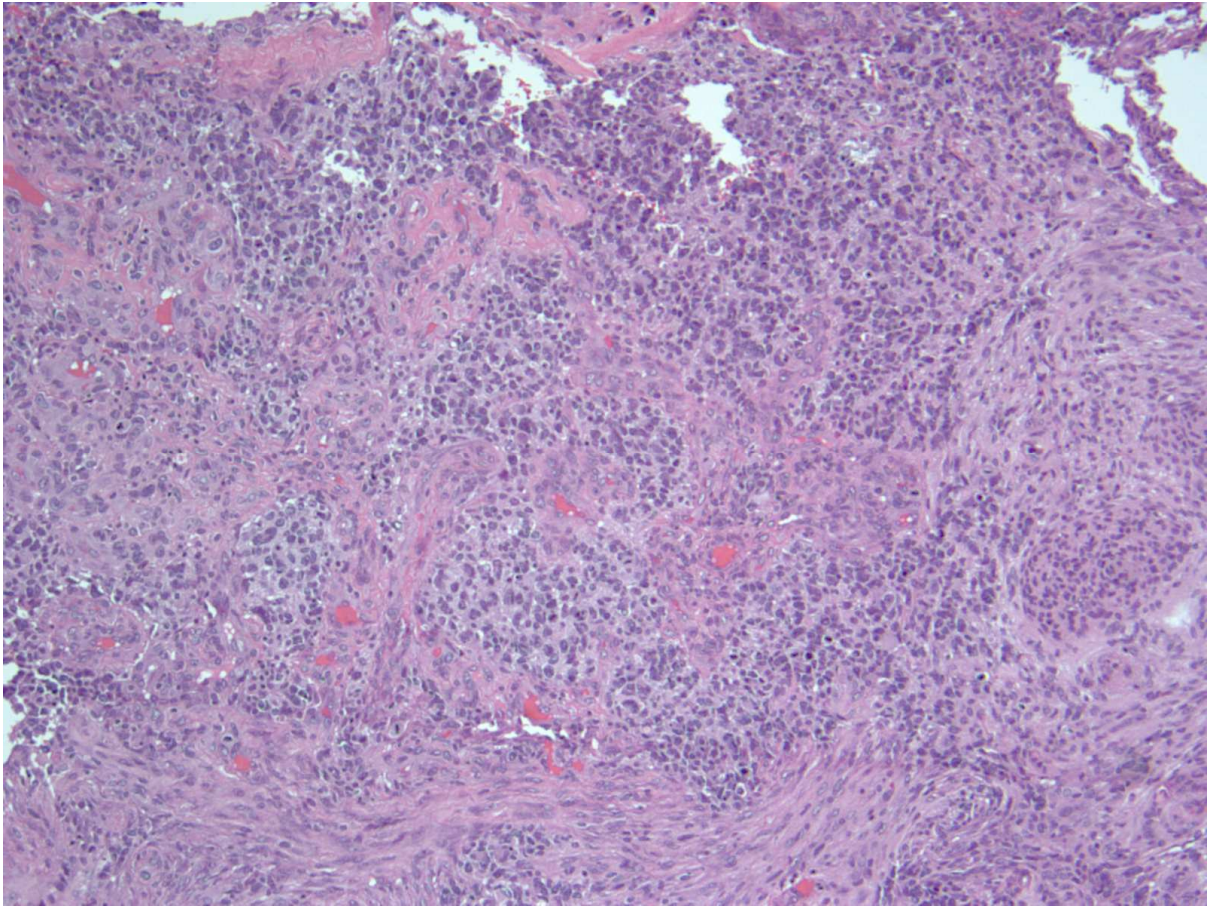


ACCEPTED

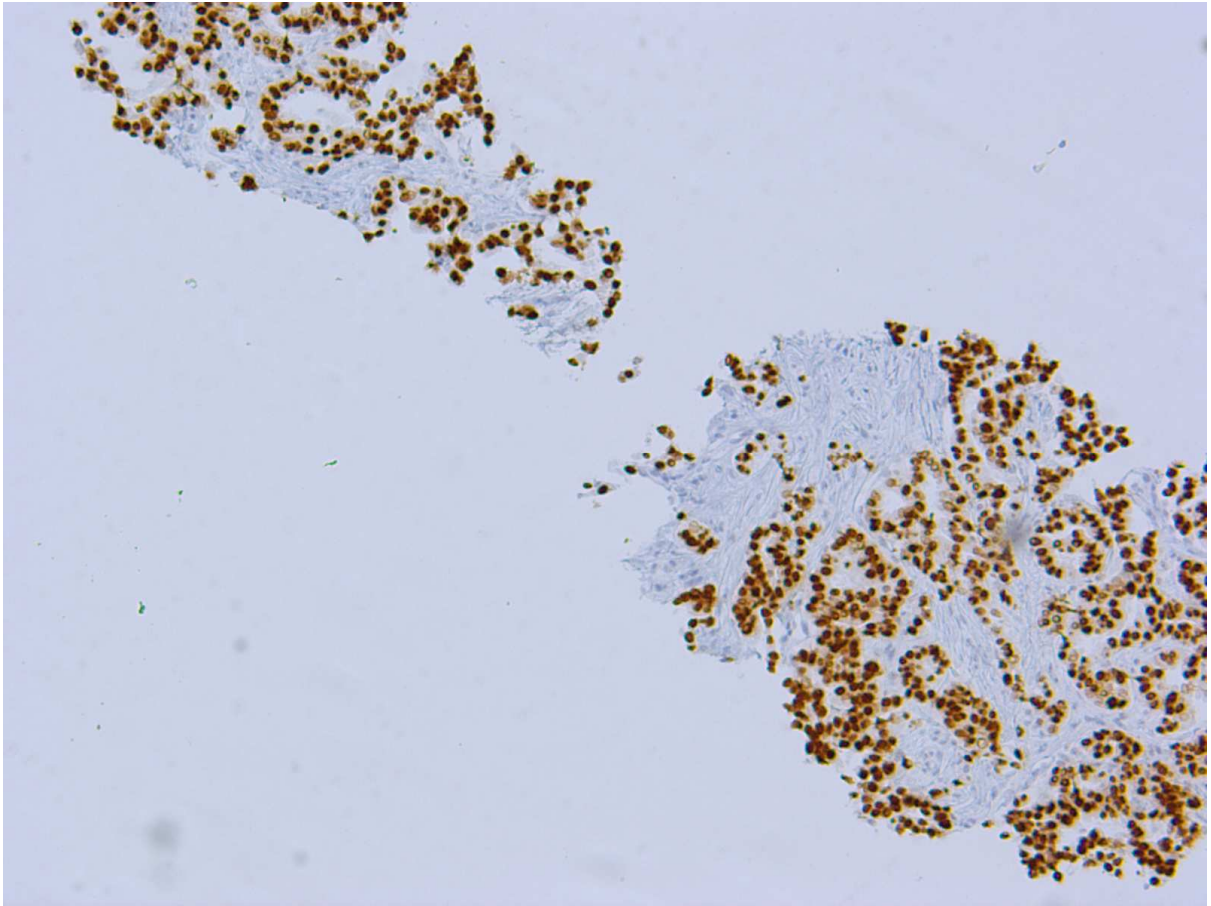
SCRIPT



ACCEPTED



ACCEPTED MANUSCRIPT



ACCEPTED M

Highlights:

- Collision tumors represent two distinct, geographically co-localized tumors growing into one another
- Tumor-to-tumor metastasis involves the hematogenous spread of a malignant tumor to the parenchyma of an anatomically distant tumor
- Preoperative identification of these entities aids in surgical planning and successful treatment of these rare tumors