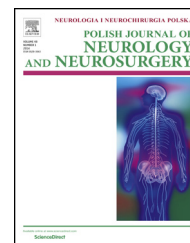


Available online at www.sciencedirect.com

ScienceDirect

journal homepage: <http://www.elsevier.com/locate/pjnns>

Case report

Tako-tsubo cardiomyopathy with transient global amnesia and cerebellar embolic stroke triggered by existential fear

Claudia Stöllberger^{*}, Nicolas DeCillia, Josef Finsterer

Rudolfstiftung, Juchgasse 25, A-1030 Wien, Austria

ARTICLE INFO

Article history:

Received 16 August 2017

Accepted 23 December 2017

Available online xxx

Keywords:

Acute coronary syndrome

Cardiomyopathy

Stroke

Takotsubo

Transient global amnesia

ABSTRACT

Background: Embolic stroke is a complication of Tako-Tsubo-cardiomyopathy (TTC), transient left ventricular dysfunction mimicking myocardial infarction without coronary culprit lesion explaining the whole left ventricular dysfunction. Transient global amnesia (TGA) is characterized by sudden onset of anterograde amnesia without compromise of other neurologic functions.

Case report: A 57 years old female was admitted because of sudden confusion and loss of her memory after emotional stress. TGA was diagnosed. Because of chest pain and laboratory tests indicating myocardial ischemia, she underwent coronary angiography which was normal. Within the following 24 h her memory improved. She complained about severe vertigo and cerebral magnetic resonance imaging showed a recent ischemia in the left cerebellum.

Conclusions: TGA is not a disease for the neurologists exclusively but also cardiac comorbidities have to be considered and cardiologists should be involved in the acute care of these patients in order not to overlook life-threatening diseases.

© 2018 Polish Neurological Society. Published by Elsevier Sp. z o.o. All rights reserved.

Tako-Tsubo cardiomyopathy (TTC) is characterized by transient left ventricular dysfunction, electrocardiographic changes, and release of myocardial enzymes that mimic acute myocardial infarction in patients without coronary culprit lesion explaining the whole left ventricular dysfunction. An emotional or physiologic stressor frequently precedes the presentation. Although the pathogenesis of TTC is unknown, the cardiac sympathetic nervous system seems to play a role [1]. Embolic stroke from the transient hypokinetic cardiac cavity has been described as a complication of TTC in

1–7% of patients [2,3]. Transient global amnesia (TGA) is characterized by the sudden onset of anterograde amnesia (the inability to encode new memories), accompanied by repetitive questioning, sometimes with a retrograde component, without compromise of other neurologic functions [4]. TGA associated with TTC has been described in 6 cases (Table 1) [5–10]. Furthermore, in a TTC-registry 4 patients with TGA, are reported [11]. We recently observed a further patient with TGA-associated TTC followed by a cerebellar stroke.

^{*} Corresponding author at: Steingasse 31/18 A-1030 Wien, Österreich, Austria.

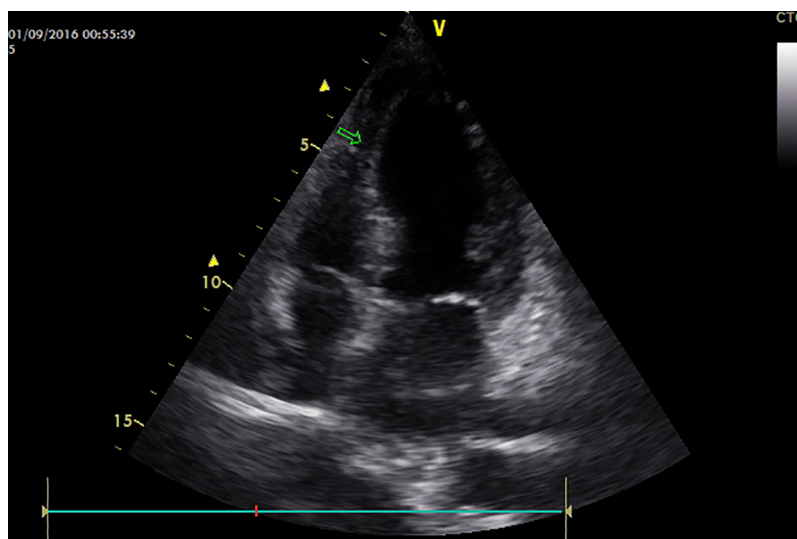
E-mail addresses: claudia.stoellberger@chello.at (C. Stöllberger), n.de-cillia@gmx.at (N. DeCillia), fifigs1@yahoo.de (J. Finsterer).

<https://doi.org/10.1016/j.pjnns.2017.12.013>

0028-3843/© 2018 Polish Neurological Society. Published by Elsevier Sp. z o.o. All rights reserved.

Table 1 – Case reports of patients with transient global amnesia (TGA) and takotsubo cardiomyopathy (TTC).

Author	Age/Sex	Trigger	Comorbidities	Sequence	Complications
[7]	62/f	Visit to a swimming pool	Hypothyroidism, TGA 2 years before	TGA-TTC	None
[6]	69/f	Health problems of the daughter	None	TGA-TTC	Bradycardia necessitating pacemaker implantation
[9]	73/f	NR	Hypertension, diabetes mellitus	TGA-TTC	None
[10]	57/f	Death of son in car accident	None	TGA-TTC	None
[8]	66/f	Death of sister because of gastrointestinal hemorrhage	Hyperlipidemia, Hypertension, gastric ulcers	TGA-TTC	None
[5]	77/f	Assault	Hypertension, TGA 4 years before	TGA-TTC	None
Present case	57/f	Existential fear, neuronitis vestibularis	Hypertension, fibromuscular dysplasia, stenting of the left subclavian artery 7 years before	TGA-TTC	Cerebellar stroke

**Fig. 1 – Echocardiographic apical four-chamber view showing hypokinesia of the apical and midventricular parts (arrow) of the interventricular septum.**

A 57 years old Caucasian female, a migrant from Latvia, was admitted to our emergency department because of sudden confusion and loss of her memory after a telephone discussion with her chief. She had a history of arterial hypertension since 7 years. Because of fibromuscular dysplasia a stent had been implanted into the left subclavian artery 7 years ago. One week before the actual admission she had been hospitalized because of a neuronitis vestibularis, which was treated by intravenous glucocorticoids and physiotherapy. Clinical neurologic examination and cerebral magnetic resonance imaging were normal. Under medical therapy, the symptoms regressed and she had been discharged in the morning of the day when she was readmitted in the evening. She was on a chronic medication with acetylsalicylic acid 100 mg/d, folic acid 5 mg/d and ramipril 5 mg/d. In the emergency department, she was investigated neurologically and a TGA was diagnosed. She complained chest pain during waiting in the emergency department. The electrocardiogram showed ST-depressions in the leads II, V₅-V₆. Troponin was elevated (272 ng/l, normal

<14 ng/l) and she was admitted at the cardiological department. Echocardiography showed hypokinesia of the apical anterior wall, apex and apical septum (Fig. 1). Within the following hours she repeatedly complained chest pain why coronary angiography was carried out which showed normal coronary arteries. Coronary angiography showed neither signs for fibromuscular dysplasia nor for spontaneous dissection in the coronary or subclavian arteries.

Within the next days, the wall motion abnormalities regressed and the patient's memory improved after 24 h. However, she complained about severe vertigo. Clinical neurologic examination revealed sore neck muscles exclusively. Cerebral magnetic resonance imaging showed a recent ischemia in the left cerebellum. After 10 days she was discharged with only slight vertigo and a medication of clopidogrel 75 mg/d, sertraline 25 mg/d and rilmenidine 1 mg/d.

She reported that in the days before admission she had suffered from existential fear due to problems in her job and

impeding deportation. She recently had also lost her house, and had been divorced 3y ago. She was also swamped by the requirements of daily life. At clinical follow-up investigation 3 months after discharge, she is in a stable condition with well controlled blood-pressure and started psychotherapy.

We propose the following hypotheses for this presentation: first, TTC occurred in response to a primary neurological event manifesting as TGA; second, TGA was an atypical symptom of a primary stress cardiomyopathy; or third, an unspecified common mechanism concurrently caused TGA and TTC. The first hypothesis is not probable since our patient had been neurologically investigated in the days before the onset of TGA and normal results were reported. TGA as an atypical symptom of a primary stress cardiomyopathy is also rather unlikely since, like in the other reported cases (table), onset of TGA preceded TTC. Thus, that the third hypothesis is most probable.

The etiology of the cerebellar stroke was most probably embolism from the hypokinetic left ventricular regions, although no thrombus was visible echocardiographically. Since the wall motion abnormalities resolved quickly no anticoagulant therapy was prescribed. A further possibility for the stroke etiology could be affection of the cerebral arteries by fibromuscular dysplasia, however, the magnetic resonance imaging did not show any abnormalities in the cerebral arteries.

The prognosis of TGA is generally assumed to be benign [4]. However, cardiovascular emergencies like aortic dissection or TTC may be associated with TGA [12]. The clinical history in patients with TGA is difficult to obtain because of the amnesia. Thus, recording of electrocardiogram, echocardiogram and assessing of cardiac enzymes should be carried out in these patients in order not to overlook a life-threatening disease. Cardiac troponin T elevation has been described in a patient with TGA and otherwise normal cardiac findings [13]. In that case, it may be possible that troponin elevation was also due to an "aborted TTC".

In conclusion, TGA does not seem to be a disease for the neurologists exclusively but also cardiac comorbidities have to be considered and cardiologists should be involved in the acute care of these patients in order not to overlook life-threatening diseases.

Funding

None declared.

Conflict of interest

None declared.

Contributions of each author

Claudia Stöllberger: collection of data, literature research, drafting of the manuscript.

Nicolas DeCillia: collection of data, literature research.

Josef Finsterer: collection of data, literature research, drafting of the manuscript.

REFERENCES

- [1] Y-Hassan S, De Palma R. Contemporary review on the pathogenesis of takotsubo syndrome: the heart shedding tears: norepinephrine churn and foam at the cardiac sympathetic nerve terminals. *Int J Cardiol* 2016;228:528–36.
- [2] Schneider B, Athanasiadis A, Schwab J, Pistner W, Gottwald U, Schoeller R, et al. Complications in the clinical course of tako-tsubo cardiomyopathy. *Int J Cardiol* 2014;176:199–205.
- [3] Dias A, Franco E, Janzer S, Koshkelashvili N, Bhalla V, Rubio M, et al. Incidence and predictors of stroke during the index event in an ethnically diverse Takotsubo cardiomyopathy population. *Func Neurol* 2016;31:157–62.
- [4] Arena JE, Rabinstein AA. Transient global amnesia. *Mayo Clin Proc* 2015;90:264–72.
- [5] Stöllberger C, Sporn R, Skala K, Schneider B, Finsterer J. Assault-induced Takotsubo cardiomyopathy associated with persisting anterograde amnesia and myopathy. *Int J Legal Med* 2010;124:467–70.
- [6] Grautoff S, Sitzer M, Weitkamp P, Kähler J. Transient global amnesia and Tako-Tsubo cardiomyopathy – coincidence or corollary? *Dtsch Med Wochenschr* 2012;137:2256–9.
- [7] Bobinger T, Köhrmann M, Raaz-Schrauder D, Schwab S, Kallmünzer B. Lost memories can break your heart: a case report of transient global amnesia followed by takotsubo cardiomyopathy. *Clin Res Cardiol* 2013;102:693–6.
- [8] Toussi A, Bryk J, Alam A. Forgetting heart break: a fascinating case of transient left ventricular apical ballooning syndrome associated with dissociative amnesia. *Gen Hosp Psychiatry* 2014;36:225–7.
- [9] Jain P, Michel J, McCrohon J. Of hearts and minds: a case of simultaneous transient global amnesia and regional left ventricular dysfunction. *Int J Cardiol* 2015;198:49–50.
- [10] Quick S, Speiser U, Richter N, Youssef A, Waessnig N, Strasser RH, et al. Transient global amnesia and broken heart syndrome: two faces of one pathology. *Clin Auton Res* 2015;25:189–91.
- [11] Weihs V, Szücs D, Fellner B, Eber B, Weihs W, Lambert T, et al. Stress-induced cardiomyopathy (Tako-Tsubo syndrome) in Austria. *Eur Heart J Acute Cardiovasc Care* 2013;2:137–46.
- [12] April MD, Fossum K, Hounshell C, Stolper K, Spear L, Semelrath K. A sinister cause of anterograde amnesia: painless aortic dissection. *Am J Emerg Med* 2015;33:989. e5–7.
- [13] Jalanko M, Forsström F, Lassus J. Cardiac troponin T elevation associated with transient global amnesia: another differential diagnosis of troponosis'. *Eur Heart J Acute Cardiovasc Care* 2015;4:561–4.