



The first case of bacillus Calmette-Guérin-induced small-vessel central nervous system vasculitis

Marc-Etienne Parent¹ · Maxime Richer² · Patrick Liang¹

Received: 17 April 2018 / Revised: 28 April 2018 / Accepted: 1 May 2018
© International League of Associations for Rheumatology (ILAR) 2018

Abstract

To present an unrecognized vascular complication of bacillus Calmette-Guérin (BCG) therapy administered for superficial bladder carcinoma. We also review the potential mimickers for primary angiitis of the central nervous system (PACNS) as well as complications of intravesical BCG therapy. An 89-year-old Caucasian man with a history of relapsing high-grade bladder carcinoma treated with intravesical BCG presented with recurring episodes of right upper limb paresthesia with clumsiness and dysarthria. Magnetic resonance imaging of the head revealed multiple predominantly left-sided frontotemporal micronodular peri-vascular lesions. Left frontal lobe biopsy showed non-necrotizing granulomatous vasculitis. Ziehl staining was negative. Initially, he was treated for PACNS but his symptoms relapsed during every attempt to taper the corticosteroids. Six months later, he developed bilateral mycobacterial endophthalmitis, caused by *Mycobacterium bovis*. Brain biopsy was reviewed and confirmed the presence of perivascular mycobacteria. A retrospective diagnosis of BCG-induced central nervous system vasculitis was made and he was treated with high-dose corticosteroids, moxifloxacin, isoniazid, ethambutol, and rifampicin. BCG is a live attenuated form of *Mycobacterium bovis* widely used as tuberculosis vaccination and intravesical therapy for superficial forms of bladder cancer. Systemic complications affect roughly 5% of patients and can manifest months or years after the last instillation. Cases of endophthalmitis, meningitis, aortitis, or mycotic aneurysms have been described, but no reports of CNS vasculitis have been found. In disseminated forms of BCG infections, referred to as BCGitis, histopathology usually reveals granulomatous inflammation. Mycobacterial cultures are often negative, making this a diagnostic challenge. This is the first documented case of BCG-induced small-vessel CNS vasculitis. *Mycobacterium bovis* infection is rare and findings are often nonspecific, making the diagnosis very difficult. Other infectious and non-infectious causes must be ruled out appropriately before considering this entity.

Keywords Autoimmune diseases · Bacillus Calmette-Guérin · Immunology · Rheumatology · Vasculitis · Vasculitis mimickers

Case presentation

An 89-year-old Caucasian man presented in the emergency department for three episodes of right upper limb paresthesia associated with limb clumsiness and once with dysarthria, lasting 10–15 min each.

Past medical history revealed bladder carcinoma treated—5 years ago—with transurethral bladder tumor resection, hypertension, benign prostate hyperplasia, irritable bowel syndrome, gastroesophageal reflux, and biopsy-negative gynecostasia. Two years ago, he suffered from a relapse of his bladder carcinoma, which was treated with transurethral resection of the prostate and bladder tumor, as well as intravesical bacillus Calmette-Guérin (BCG). Interestingly, 2 days after his fifth and last BCG treatment, the patient developed septic shock of unknown etiology and responded well to a short course of intravenous antibiotics. His latest follow-up and

✉ Marc-Etienne Parent
Marc-Etienne.Parent@USherbrooke.ca

Maxime Richer
Maxime.Richer@USherbrooke.ca

Patrick Liang
Patrick.Liang@USherbrooke.ca

¹ Department of Rheumatology, Centre Intégré Universitaire de Santé et de Services Sociaux de l'Estrie, Centre Hospitalier Universitaire de Sherbrooke, 3001 12e Avenue Nord, Sherbrooke, QC J1H 5N4, Canada

² Department of Pathology, Centre Intégré Universitaire de Santé et de Services Sociaux de l'Estrie, Centre Hospitalier Universitaire de Sherbrooke, 3001 12e Avenue Nord, Sherbrooke, QC J1H 5N4, Canada

cystoscopy were normal. He had no allergies, smoking, alcohol, or illicit drug use. His only medications were verapamil SR 120 mg daily, celecoxib 200 mg twice daily as needed, and pantoprazole 40 mg daily.

At the moment of presentation, the patient was asymptomatic and complete neurological examination—including cranial nerves and cerebellar tests—was completely normal. Head computed tomography (CT) revealed discrete leukoaraiosis. Transthoracic echocardiography, Holter monitoring, and Doppler ultrasound of the carotid arteries were all normal. The patient was diagnosed with transient ischemic attacks and was discharged with acetylsalicylic acid 80 mg daily.

Two weeks later, he was readmitted for recurrence of his episodic symptoms despite adequately taking his medication. Episodes were accompanied by right-sided upper limb weakness. Complete history and physical examination were unremarkable. He was treated with clopidogrel 75 mg daily and was admitted for further investigations.

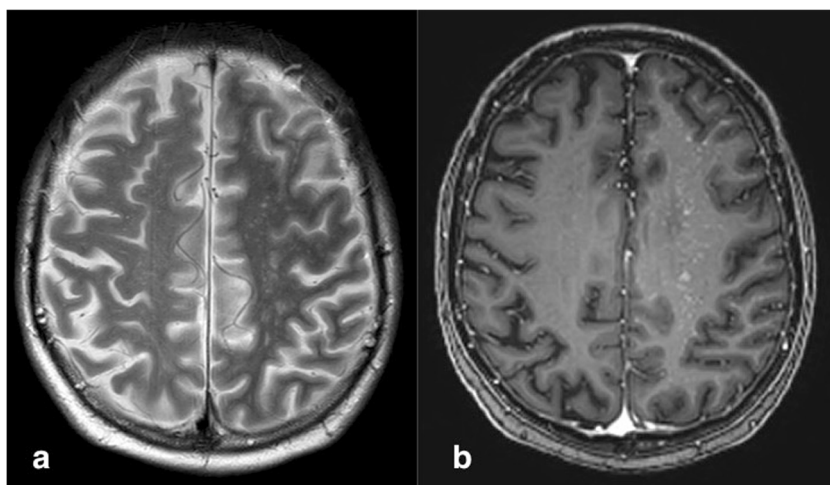
On admission, blood work revealed a normal white blood cell count, $4.9 \times 10^9/L$ (N , 3.8 – $10.6 \times 10^9/L$); slightly low absolute lymphocyte count, $0.9 \times 10^9/L$ (N , 1.2 – $3.5 \times 10^9/L$); normal hemoglobin level, 138 g/L (N , 130–180 g/L); normal platelets, $149 \times 10^9/L$ (N , 130 – $400 \times 10^9/L$); normal creatinine, 82 $\mu\text{mol/L}$ (N , 58–110 $\mu\text{mol/L}$); normal C-reactive protein, 4.1 mg/L (N , 0–8.0 mg/L); normal sedimentation rate, 8 mm/h (N , 0–15 mm/h); elevated lactate dehydrogenase, 328 UI/L (N , 0–250 UI/L); slightly elevated serum angiotensin-converting enzyme level, 74.4 U (N , 8–52 U); and increased beta-2-microglobulin, 416.7 nmol/L (N , 68–186 nmol/L); as well as normal serum sodium, potassium, calcium, and coagulation parameters. Head CT was unchanged. A CT angiography of the carotid arteries and circle of Willis, an electroencephalography (EEG), and a transcranial Doppler ultrasound were normal. Magnetic resonance imaging (MRI) findings are shown in Fig. 1.

Meanwhile, the patient's symptoms kept recurring on a daily basis and he was started on levetiracetam 250 mg twice daily with a progressive increase to 500 mg twice daily. A lumbar puncture revealed clear fluid containing a trace of erythrocytes, $7 \times 10^6/L$; a trace of leucocytes, $3 \times 10^6/L$; normal glucose level, 2.8 mmol/L (N , 2.5–4.5 mmol/L); and normal protein level, 0.59 g/L (N , 0.12–0.60 g/L). Flow cytometry and cytology performed on the cerebrospinal fluid were negative. Tuberculin skin testing, interferon-gamma release assay, anti-neutrophil cytoplasmic antibodies (ANCA), and antinuclear antibodies (ANA) were all negative. Blood, CSF, and urine cultures were negative. A search for syphilis with rapid plasma reagin and cryptococcus with latex agglutination were negative. Positron emission tomography (PET) was normal. A repeat MRI was performed and demonstrated a slight increase in the number and intensity of the left-sided lesions. Cerebral arteriography was normal.

Faced with diagnostic uncertainty, unwavering symptoms, and worsening MRI findings, acetylsalicylic acid, clopidogrel, and levetiracetam were stopped and a left frontal lobe biopsy was performed. This demonstrated chronic vascular inflammation, mostly lymphocytic (Fig. 2), with the formation of non-necrotizing granulomas (Fig. 3) and occasional perivascular hemorrhages. Special staining (Gram, PAS, Grocott, Whartin-Starry, and Ziehl) was negative. The patient did not present any features of a systemic inflammatory disorder and was diagnosed with primary angiitis of the central nervous system (PACNS). He was treated with prednisone 50 mg daily, as well as appropriate osteoporosis and pneumocystis jiroveci prophylaxis. After remaining symptom-free for 72 h, the patient was discharged with a slow prednisone taper.

One month later, while on prednisone 45 mg daily, the patient presented with a 3-min episode of right-sided brachiofacial paralysis associated with right arm paresthesia and dysarthria. MRI of the head showed a net regression of previously identified lesions, but five new small punctiform

Fig. 1 Magnetic resonance imaging demonstrating multiple predominantly left-sided micronodular hyperintense white matter lesions in T2-weighted (a) and T1-weighted 3D Turbo Field Echo (b) sequences



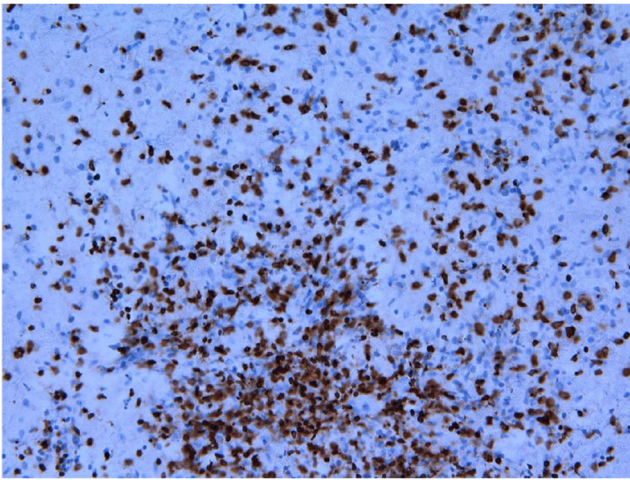


Fig. 2 CD3 staining demonstrating the presence of numerous T lymphocytes

lesions in the left frontal lobe. The patient was treated with intravenous solumedrol 1 g daily for 3 consecutive days and a return to prednisone 50 mg daily thereafter. Mofetil mycophenolate was introduced and progressively increased to 1 g twice daily.

Three weeks later, while on prednisone to 40 mg daily, the patient suffered multiple episodes of bilateral facial paralysis and bilateral upper limb paresthesias. He also complained of fatigue with impaired cognition and attention. Physical examination revealed a slow but steady gait as well as slowing of rapid skilled movements of the left upper limb. MRI showed a clear increase in the number of subcortical punctiform lesions involving all lobes bilaterally but predominantly affecting the left frontal lobe. EEG demonstrated diffuse mild electrocerebral dysfunction with intermittent left frontotemporal dysfunction but no clear epileptiform pattern. Intravenous pulses of solumedrol 1 g daily were given for 3 days. At discharge, mofetil mycophenolate was replaced with intravenous cyclophosphamide 1 g every 3 weeks and prednisone was increased to 50 mg daily.

In the following weeks, there was an increase in fatigue, attention deficit, memory impairment, and a new onset of expression aphasia and right-sided upper and lower limb weakness. The Montreal Cognitive Assessment (MoCA) test result was 10/30 (N , $>25/30$). The patient was again

hospitalized for further investigation. Blood work showed an increased white blood cell count, $13.8 \times 10^9/L$ (N , 3.8 – $10.6 \times 10^9/L$); low absolute lymphocyte count, $0.6 \times 10^9/L$ (N , 1.2 – $3.5 \times 10^9/L$); normal hemoglobin level, 144 g/L (N , 130–180 g/L); normal platelets, $223 \times 10^9/L$ (N , 130 – $400 \times 10^9/L$); normal creatinine, 91 $\mu\text{mol/L}$ (N , 58–110 $\mu\text{mol/L}$); normal C-reactive protein, 3.0 mg/L (N , 0–8.0 mg/L); normal sedimentation rate, 12 mm/h (N , 0–15 mm/h); normal lactate dehydrogenase, 234 UI/L (N , 0–250 UI/L); normal serum angiotensin-converting enzyme level, 36.8 U (N , 8–52 U); and slightly elevated beta-2-microglobulin, 204.6 nmol/L (N , 68–186 nmol/L); as well as normal serum sodium, potassium, calcium, albumin, liver function tests, and coagulation parameters. Lumbar puncture was repeated and was normal including angiotensin-converting enzyme level, bacterial, mycobacterial, and herpes virus PCR. MRI of the head was unchanged and a repeat PET scan was again normal. Pathology from the frontal lobe biopsy was reviewed and the initial diagnosis of PACNS was maintained. Intravenous solumedrol 1 g daily for 3 days was given with significant improvement. The patient was discharged with an increase in his prednisone dose to 60 mg daily and the same concomitant cyclophosphamide treatment.

Almost 2 months later, during the prednisone taper, the patient suffered a relapse in his usual neurologic symptoms as well as gait instability and severe delirium. The patient also complained of diminished visual acuity. Ophthalmologic evaluation revealed bilateral endophthalmitis. Given the patient's history of exposure to intravesical BCG and septic shock of unknown etiology soon after, disseminated BCGitis was suggested as the possible cause of the current central nervous system vasculitis. Right vitrectomy was performed and culture was positive for *Mycobacterium bovis*. Urine culture was also positive for *Mycobacterium bovis* (after 27 days). Cerebral biopsy images were again reviewed and Fite-Faraco and Auramine colorations revealed scant perivascular mycobacteria (Fig. 4). Cyclophosphamide was stopped, treatment with ethambutol 800 mg daily, pyridoxine 50 mg daily, isoniazide 300 mg daily, rifampicin 600 mg daily, moxifloxacin 400 mg daily, difluprednate 0.05% ophthalmic drops four times daily, and dexamethasone ophthalmic drops four times daily was initiated. While the hospitalization was

Fig. 3 Hematoxylin and eosin staining showing granulomatous inflammation consisting of aggregates of epithelioid histiocytes with a peripheral cuff of lymphocytes and plasma cells at $\times 10$ magnification (a) and $\times 20$ magnification (b)

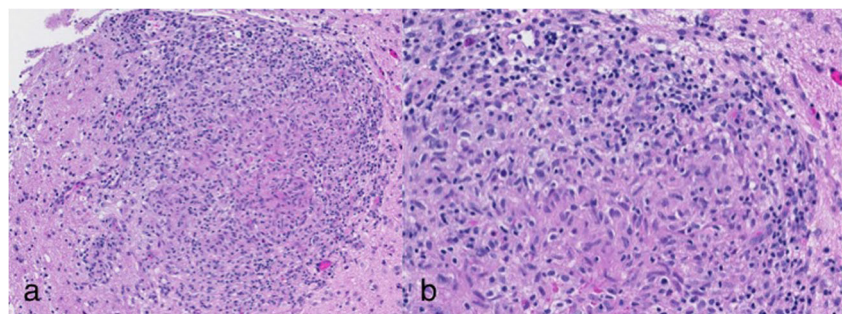
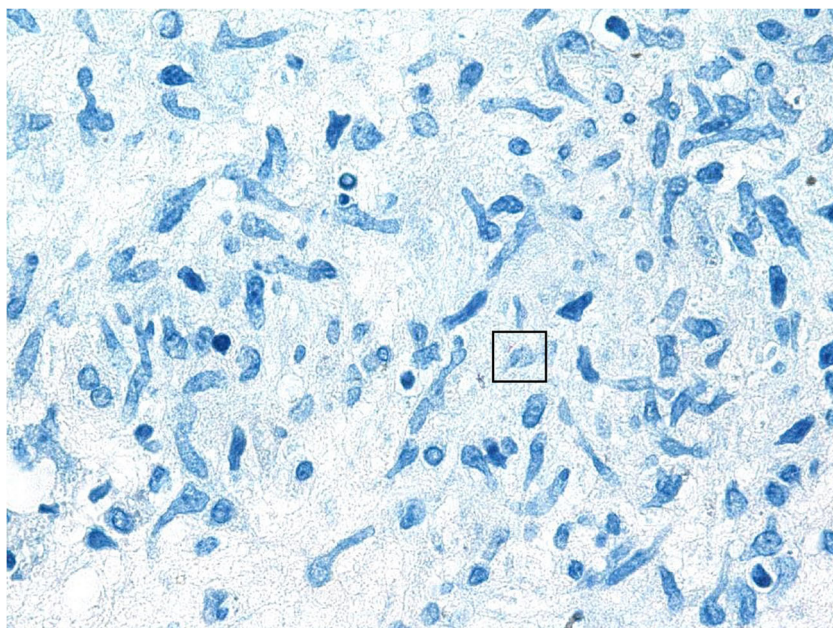


Fig. 4 Fite-Faraco staining demonstrating the presence of mycobacteria



long (6 weeks) and eventful, the patient showed a net regression of his many neurological symptoms. He was discharged with prednisone 40 mg daily.

Eighteen months after diagnosis of BCG-induced central nervous system vasculitis, the patient remains stable and relapse-free. Current medication is unchanged except for prednisone, which is now at 10 mg daily and continues to be tapered progressively. The patient also receives intraocular corticosteroids twice yearly. The latest two brain MRIs demonstrated stability of the existing lesions and the absence of new lesions.

Discussion

PACNS mimickers

The approach to patients with suspected primary central nervous system vasculitis should include a thorough evaluation in search of alternative etiologies and potential mimickers. Ruling out all known causes of secondary central nervous system vasculitis, as well as these mimicking conditions, is necessary to make a diagnosis of PACNS (Table 1) [1]. Mimickers are classified as systemic inflammatory conditions, infections, conditions with cerebral angiographic abnormalities, and miscellaneous conditions [2]. PACNS is very rare with an incidence of 2.4 cases per million person-years [3]. Affected patients are usually older Caucasian males and can present with a heterogeneous constellation of symptoms including headache, encephalopathy, cognitive decline, personality changes, and/or recurrent strokes or transient ischemic attacks [4].

Every patient should be carefully questioned and examined to look for signs of systemic vasculitis most notably Behcet's syndrome, polyarteritis nodosa, granulomatosis with polyangiitis, eosinophilic granulomatosis with polyangiitis, or Cogan's syndrome. Inflammatory diseases such as systemic lupus erythematosus, Sjogren's syndrome, Crohn's disease, and sarcoidosis must also be sought out. Any bloodwork abnormality such as anemia or increased inflammatory markers should increase the suspicion that an underlying systemic process is present, as these are usually absent in PACNS.

Patients presenting with ischemic lesions should undergo a full stroke evaluation searching for causes other than PACNS such as atrial fibrillation, endocarditis, myxoma, atherosclerosis, or hypercoagulable states.

Patients diagnosed with PACNS have either angiographic or histopathologic features suggesting vasculitis. Both of these should be assessed properly to rule out mimickers. Angiographic abnormalities can also be seen in reversible cerebral vasoconstriction syndrome, fibromuscular dysplasia, moyamoya disease, and arterial dissection, as well as lymphoproliferative disorders.

Table 1 Proposed criteria for PACNS [1]

1. The presence of an acquired, and otherwise unexplained, neurological or psychiatric deficit.
2. The presence of either classic angiographic or histopathological features of angiitis within the CNS.
3. No evidence of systemic vasculitis or any disorder that could cause or mimic the angiographic or pathological features of the disease.

Many viral and bacterial infections can manifest symptoms similar to PACNS, such as herpes zoster, HIV, tuberculosis, syphilis, and Lyme disease. Tuberculous and syphilitic vasculitis of the central nervous system have a tendency to affect the arteries located at the base of the skull, notably the middle cerebral and basilar arteries [5–7]. A case of BCG-induced vasculitis of the basilar and cerebral arteries was described in a young female many years after BCG vaccination as a child [8]. Fungal cerebritis and vasculitis seem to have a predilection for the anterior circulation and can occur with aspergillosis, nocardiosis, cryptococcosis, histoplasmosis, candida, and zygomycetes [9].

Brain biopsy is useful both to support a diagnosis of PACNS and to rule it out by identifying other conditions, notably infections and malignancies such as intravascular lymphoma [10–14]. In a retrospective study of 79 patients with suspected PACNS, brain biopsies yielded alternative diagnoses in 30% [15].

Cases of Degos disease (DD) and retinocerebral vasculopathy with cerebral leukodystrophy (RVCL) mimicking PACNS have also been described, both of which were fatal [16].

Complications of BCG therapy

Bacille Calmette-Guérin (BCG) is a live attenuated form of *Mycobacterium bovis* and is widely used as tuberculosis vaccination and intravesical therapy for superficial forms of urothelial carcinomas. The recommended treatment duration is 1 to 3 years, based on tumor risk stratification [17, 18].

Although generally safe, common minor side effects of intravesical BCG therapy include dysuria, hematuria, urinary frequency, and flu-like symptoms with low-grade fever [19]. More serious side effects occur in approximately 5% of patients and include high-grade fever, granulomatous prostatitis, granulomatous epididymo-orchitis, granulomatous hepatitis or pneumonitis, ureteral obstruction, allergic reactions, contracted bladder, and BCG sepsis (BCGitis) [19, 20]. BCGitis is the most serious complication and occurs in 0–0.4% of patients [20, 21]. Any patient with high-grade fever, persistent fever, or chills should be suspected of having absorbed the organism—either as a result of traumatic catheterization or directly through the inflamed bladder wall—and should be treated empirically with antituberculous agents [20]. Diagnosis is clinical, as cultures often remain negative.

A retrospective study of 22 cases of BCGitis showed that patients had a median of five instillations before developing the complication. BCGitis was characterized by fever in 91%, malaise in 64%, and shortness of breath in 31%. A quarter of patients suffered from shock, most with multiple organ failure. Twenty-eight microbiological samples were taken from 17 patients and only 2 were positive for *Mycobacterium bovis*. Biopsy of the affected organ was more informative, as 10 out of 14 (71%) demonstrated the presence of granulomas.

Seventeen patients were treated with antituberculous agents, of which only one died [22]. Retrospectively, our patients' shock was likely undiagnosed BCGitis. He was not given any antituberculous agents.

The Society for Immunotherapy of Cancer 2017 guidelines suggest that oral quinolones be considered in all patients after BCG therapy (at least 6 h) to reduce the risk of toxicity [level A evidence] [23]. The 2010 Canadian Urology Association guidelines made no recommendations concerning quinolones [24]. Our patient did not receive quinolones.

A retrospective review has identified certain vascular and ocular complications resulting from BCG infection such as mycotic aneurisms, aorto-enteric fistulas, infection of vascular bypass graft, endophthalmitis, and uveitis [25]. A case of *Mycobacterium tuberculosis* meningovascularitis causing narrowing of the large arteries at the base of the brain has been described [26]. There were no cases of small-vessel central nervous system vasculitis caused by *Mycobacterium bovis*.

Conclusion

This complex case illustrates the inherent diagnostic difficulty in evaluating patients with suspected, even confirmed, central nervous system vasculitis. While the initial diagnosis of PACNS was incorrect, it was appropriate at the time given the available information and comprehensive search for alternative causes. Even the brain biopsy initially ruled out mycobacteria as a cause. The unfavorable evolution and refractoriness to the prednisone taper was cause for concern and prompted repeated in-depth investigations including cultures, which were normal, as is usually the case for BCG infections, and falsely supported a diagnosis of PACNS. The most valuable information for making the right diagnosis came from both careful review of the past medical history and the appearance of endophthalmitis, which led to the demonstration of a systemic mycobacterial presence.

This is, to our knowledge, the first documented case of BCG-induced small-vessel central nervous system vasculitis following intravesical therapy. Whether oral quinolones reduce the risk of developing such a complication is unknown.

Compliance with ethical standards

Disclosures None.

References

1. Calabrese LH, Mallek JA (1988) Primary angiitis of the central nervous system. Report of 8 new cases, review of the literature, and proposal for diagnostic criteria. *Medicine* 67(1):20–39

2. Hajj-Ali RA, Calabrese LH (2013) Primary angitis of the central nervous system. *Autoimmun Rev* 12(4):463–466. <https://doi.org/10.1016/j.autrev.2012.08.004>
3. Salvarani C, Brown RDJ, Calamia KT, Christianson TJH, Weigand SD, Miller DV et al (2007) Primary central nervous system vasculitis: analysis of 101 patients. *Ann Neurol* 62(5):442–451. <https://doi.org/10.1002/ana.21226>
4. Hajj-Ali RA, Calabrese LH (2014) Diagnosis and classification of central nervous system vasculitis. *J Autoimmun* 48–49:149–152. <https://doi.org/10.1016/j.jaut.2014.01.007>
5. Javaud N, Certal RDS, Stiememann J, Morin AS, Chamouard JM, Augier A, Bouchaud O, Carpentier A, Dhote R, Dumas JL, Fantin B, Fain O (2011) Tuberculous cerebral vasculitis: retrospective study of 10 cases. *Eur J Intern Med* 22(6):e99–e104. <https://doi.org/10.1016/j.ejim.2011.04.004>
6. Kakumani PL, Hajj-Ali RA (2009) A forgotten cause of central nervous system vasculitis. *J Rheumatol* 36(3):655. <https://doi.org/10.3899/jrheum.080605>
7. Flint AC, Liberato BB, Anziska Y, Schantz-Dunn J, Wright CB (2005) Meningovascular syphilis as a cause of basilar artery stenosis. *Neurology* 64(2):391–392. <https://doi.org/10.1212/01.WNL.0000149758.57386.B8>
8. Ehrengut W (1990) BCG-induced inflammation during childhood and in pregnancy. Additionally a contribution to BCG-induced necrotising cerebral arteritis. *Klin Padiatr* 202(5):303–307. <https://doi.org/10.1055/s-2007-1025536>
9. Gavito-Higuera J, Mullins CB, Ramos-Duran L, Olivas Chacon CI, Hakim N, Palacios E (2016) Fungal infections of the central nervous system: a pictorial review. *J Clin Imaging Sci* 6:24. <https://doi.org/10.4103/2156-7514.184244>
10. Parisi JE, Moore PM (1994) The role of biopsy in vasculitis of the central nervous system. *Semin Neurol* 14(4):341–348. <https://doi.org/10.1055/s-2008-1041093>
11. Alrawi A, Trobe JD, Blaivas M, Musch DC (1999) Brain biopsy in primary angitis of the central nervous system. *Neurology* 53(4):858–860
12. Sienknecht CW, Whetsell WOJ, Pollock P (1995) Intravascular malignant lymphoma (“malignant angioendotheliomatosis”) mimicking primary angitis of the central nervous system. *J Rheumatol* 22(9):1769–1770
13. Prayson RA (2016) Intravascular lymphoma mimicking vasculitis. *J Clin Neurosci* 34:224–225. <https://doi.org/10.1016/j.jocn.2016.06.010>
14. Hundsberger T, Cogliatti S, Kleger G-R, Fretz C, Gahler A, Anliker M et al (2011) Intravascular lymphoma mimicking cerebral stroke: report of two cases. *Case Rep Neurol* 3(3):278–283. <https://doi.org/10.1159/000334130>
15. Torres J, Loomis C, Cucchiara B, Smith M, Messé S (2016) Diagnostic yield and safety of brain biopsy for suspected primary central nervous system angitis. *Stroke* 47(8):2127–2129
16. Shahane A, Khasnis A, Hajj Ali R (2012) Three unusual mimics of primary angitis of the central nervous system. *Rheumatol Int* 32(3):737–742. <https://doi.org/10.1007/s00296-010-1679-8>
17. Morales A, Eidinger D, Bruce AW (1976) Intracavitary Bacillus Calmette-Guerin in the treatment of superficial bladder tumors. *J Urol* 116(2):180–183
18. Babjuk M, Bohle A, Burger M, Capoun O, Cohen D, Comperat EM et al (2016) EAU guidelines on non-muscle-invasive urothelial carcinoma of the bladder: update 2016. *Eur Urol* 71(3):447–461. <https://doi.org/10.1016/j.eururo.2016.05.041>
19. Koya MP, Simon MA, Soloway MS (2006) Complications of intravesical therapy for urothelial cancer of the bladder. *J Urol* 175(6):2004–2010. [https://doi.org/10.1016/S0022-5347\(06\)00264-3](https://doi.org/10.1016/S0022-5347(06)00264-3)
20. Lamm DL, van der Meijden PM, Morales A, Brosman SA, Catalona WJ, Herr HW et al (1992) Incidence and treatment of complications of bacillus Calmette-Guerin intravesical therapy in superficial bladder cancer. *J Urol* 147(3):596–600
21. Martinez-Pineiro JA, Jimenez Leon J, Martinez-Pineiro LJ, Fiter L, Mosteiro JA, Navarro J et al (1990) Bacillus Calmette-Guerin versus doxorubicin versus thiotepa: a randomized prospective study in 202 patients with superficial bladder cancer. *J Urol* 143(3):502–506
22. Pommier JD, Ben Lasfar N, Van Grunderbeeck N, Burdet C, Laouenan C, Rioux C et al (2015) Complications following intravesical bacillus Calmette-Guerin treatment for bladder cancer: a case series of 22 patients. *Infect Dis* 47(10):725–731. <https://doi.org/10.3109/23744235.2015.1055794>
23. Kamat AM, Bellmunt J, Galsky MD, Konety BR, Lamm DL, Langham D, Lee CT, Milowsky MI, O'Donnell MA, O'Donnell PH, Petrylak DP, Sharma P, Skinner EC, Sonpavde G, Taylor JA, Abraham P, Rosenberg JE (2017) Society for Immunotherapy of Cancer consensus statement on immunotherapy for the treatment of bladder carcinoma. *J Immunother cancer* 5(1):68. <https://doi.org/10.1186/s40425-017-0271-0>
24. Kassouf W, Kamat AM, Zlotta A, Bochner BH, Moore R, So A, Izawa J, Rendon RA, Lacombe L, Aprikian AG (2010) Canadian guidelines for treatment of non-muscle invasive bladder cancer: a focus on intravesical therapy. *Can Urol Assoc J* 4(3):168–173
25. Perez-Jacoiste Asin MA, Fernandez-Ruiz M, Lopez-Medrano F, Lumberras C, Tejido A, San Juan R et al (2014) Bacillus Calmette-Guerin (BCG) infection following intravesical BCG administration as adjunctive therapy for bladder cancer: incidence, risk factors, and outcome in a single-institution series and review of the literature. *Medicine* 93(17):236–254. <https://doi.org/10.1097/MD.0000000000000119>
26. Renard D, Morales R, Heroum C (2007) Tuberculous meningovascularitis. *Neurology* 68(20):1745. <https://doi.org/10.1212/01.wnl.0000263653.20798.09>