


Accepted Manuscript

Primary intracranial leiomyosarcoma with intra-tumoral hemorrhage: Case report and review of literature

Koichi Torihashi, Chin Masaki, Kazumichi Yoshida, Osamu Narumi, Sen Yamagata



PII: S1878-8750(18)30949-5

DOI: [10.1016/j.wneu.2018.05.004](https://doi.org/10.1016/j.wneu.2018.05.004)

Reference: WNEU 8065

To appear in: *World Neurosurgery*

Received Date: 19 March 2018

Revised Date: 1 May 2018

Accepted Date: 2 May 2018

Please cite this article as: Torihashi K, Masaki C, Yoshida K, Narumi O, Yamagata S, Primary intracranial leiomyosarcoma with intra-tumoral hemorrhage: Case report and review of literature, *World Neurosurgery* (2018), doi: 10.1016/j.wneu.2018.05.004.

This is a PDF file of an unedited manuscript that has been accepted for publication. As a service to our customers we are providing this early version of the manuscript. The manuscript will undergo copyediting, typesetting, and review of the resulting proof before it is published in its final form. Please note that during the production process errors may be discovered which could affect the content, and all legal disclaimers that apply to the journal pertain.

1 Abstract

2

3 Background

4 Primary intracranial leiomyosarcoma is a very rare occurrence. And
5 primary leiomyosarcoma with intra-tumoral hemorrhage has not been
6 published. We firstly present a case report of a rapidly enlarging
7 primary intracranial leiomyosarcoma with intra-tumoral hemorrhage.

8 Case Description

9 A 41-yr old female presented with right hemiparesis and gait disturbance.
10 And she has the brain tumor on frontal lobe. And the tumor was
11 increasing rapidly. Intra-tumoral hemorrhage was suddenly occurred. We
12 removed the tumor after hemorrhage. After operation, postoperative
13 chemotherapy and radiotherapy were not performed, but recurrence did
14 not occur.

15 Conclusions

16 To the best our knowledge, this presents the first report of primary
17 intracranial leiomyosarcoma with intra-tumoral hemorrhage. We firstly
18 describe the clinical and radiological findings and the histological
19 examination of this primary intracranial leiomyosarcoma with
20 intra-tumoral hemorrhage.

21

22

23 Background

24 Intracranial neoplasms of mesenchymal origin are exceptionally rare.
25 The majority of these tumors are metastatic lesions that originated from
26 the gastrointestinal tract or female reproductive system^{1 2}
27 Leiomyosarcoma is an aggressive cancer that exhibits smooth muscle
28 differentiation. Although primary intracranial leiomyosarcoma is very
29 rare, these tumors are seen in both adult and pediatric patients^{3 4 5 6}.
30 They often present as a mass lesion in the dura, but occasionally involve
31 the parenchyma of the central nervous system (CNS). Resection is the
32 most effective treatment for leiomyosarcoma. A high rate of local
33 recurrence of these cancers is seen despite gross total resection.

34 We describe a patient who underwent gross total resection without
35 postoperative radiotherapy and chemotherapy and in whom recurrence
36 did not occur. We describe the course of this patient with intra-tumoral
37 hemorrhage of a primary intracranial leiomyosarcoma.

38

39

40 Case Report

41 A 41-year-old female presented with right hemiparesis and gait
42 disturbance.

43 Magnetic resonance imaging (MRI) on admission showed a lobulated
44 cortical and subcortical lesion in the left frontal region. Most of the
45 mass was isointense compared with gray matter on T1-weighted images
46 and slightly hyperintense on T2-weighted images with minimal
47 associated vasogenic edema. Gadolinium-enhanced MRI was performed
48 6 days later and showed homogeneous enhancement and rapid growth of
49 the mass. Nine days later, she noted that the hemiparesis had appeared.
50 At that time, mass effect and edema had developed as observed with MRI
51 (Fig. 1). She experienced a sudden onset of consciousness disturbance
52 and aphasia. She developed multiple seizure. Significant intra-tumoral
53 hemorrhage with ventricular hemorrhage and uncal herniation was
54 observed with computed tomography (CT) (Fig. 2). She underwent
55 emergency surgery that involved a left fronto-parietal craniotomy. The
56 presumptive diagnosis was malignant lymphoma. Following the
57 fronto-parietal craniotomy, a reddish well-demarcated fibrous tumor was
58 identified that showed acute hemorrhage. The frontal hematoma was
59 evacuated. With dissection of the apparent capsule from surrounding
60 tissues, gross total removal of the tumor was accomplished (Fig. 3). The
61 size of the round tumor that was removed was $4 \times 4 \times 5$ cm. After the
62 removal of the tumor, the edema and mass effect of the brain is worsened.
63 And we thought the bone flap should not be replaced after the removal of
64 the tumor.

65 Hematoxylin and eosin staining of sections of the tumor demonstrated
66 interlacing fascicles of pleomorphic spindle cells with a moderate
67 amount of eosinophilic cytoplasm.

68 Moderate atypia and occasional mitotic figures were identified, and
69 necrosis was absent. Immunoperoxidase staining showed that the tumor
70 was positive for α -smooth muscle actin, but not glial fibrillary acidic
71 protein or S-100 protein (Fig. 4). The diagnosis of a leiomyosarcoma
72 was made, and the histological diagnosis was intracranial
73 leiomyosarcoma. An intensive search for an extracranial primary tumor,
74 which included plain radiographs of the abdomen and chest,
75 ultrasonography, CT, MRI, whole-body positron emission tomography,
76 and clinical follow-up, proved negative. The final diagnosis of a primary

77 intracranial leiomyosarcoma was then established.

78 After the operation, she became totally bedridden. Although we
79 explained her family about the chemotherapy and radiotherapy, her
80 family refused those treatments. And we didn't treat the radiotherapy
81 and chemotherapy. One month after surgery, hydrocephalus developed,
82 and she underwent surgery to insert a ventriculo-peritoneal shunt and for
83 placement of an Ommaya reservoir. She started rehabilitation, and she
84 could communicate better gradually. Six months later the tumor had not
85 enlarged as seen on MRI (Fig. 5). However, 7 months later, the patient
86 died suddenly due to a pulmonary embolism.

87

88

89 Discussion

90 Leiomyosarcomas are malignant neoplasms demonstrating smooth
91 muscle differentiation that arise primarily from the uterus,
92 gastrointestinal tract, skin, and blood vessels. Most intracranial soft
93 tissue sarcomas represent metastatic disease. Metastases from these
94 sites are unique, but may be directed to bone, lung, and liver^{7 1 8 2}. Even
95 more uncommon is metastasis to the CNS⁹. Primary intracranial
96 sarcomas are extremely rare. Three previous cases of leiomyosarcomas
97 were reported from a series of 25000 brain biopsies¹⁰, for a 0.012%
98 prevalence. We found no cases of intra-tumoral hemorrhage associated
99 with a primary intracranial leiomyosarcoma.

100 The prognosis of leiomyosarcoma depends on its location, size, and
101 mitotic rate. Intrauterine leiomyosarcomas have a much better prognosis
102 than deep-seated soft-tissue leiomyosarcomas, and this patient's lesion
103 is probably better classified as the latter.

104 The local recurrence rate is 25.9% after treatment of the initial lesion
105 with postoperative radiotherapy¹¹. This particular tumor appeared to
106 have grown extremely rapidly, as the non-contrast CT scan demonstrated
107 only moderate asymmetry with a minimal mass effect, but an MRI 6 days
108 later demonstrated edema and a moderate mass effect.

109 No treatment protocol exists for this extremely rare primary CNS
110 neoplasm. Although the number of cases of leiomyosarcoma is
111 increasing, too few patients have been identified to formulate effective
112 treatment regimens. The prognosis for primary intracranial
113 leiomyosarcoma remains poor. After a comprehensive literature review,
114 we found only 11 reported cases of primary intracranial leiomyosarcoma

115 without any association with immune-suppression, infection, prior
116 radiation, or plant history^{3, 5, 12-20} (Table 1). Due to very few cases
117 reports, there is no established standard treatment regimen for primary
118 intracranial leiomyosarcoma. But the main treatment seems to be the
119 complete resection of the tumor. Surgical resection is performed in 12
120 cases, and 3 cases were only partial resection and 1 case was biopsy. In 4
121 partial removal cases, 3 patients died (75%) and one patient was lost in
122 follow up one year. Chemotherapy was used in 4/12 (30%) of cases
123 reviewed. But 2 cases died (50%). Radiotherapy was used in 9/12
124 (75%) of cases. 5 cases died. (55.6%)

125 Complete surgical removal together with radiotherapy are the mainstay
126 for other non-CNS sarcomas. Gross total resection, depending on the site
127 and age of the patient, is the treatment goal. Postoperative regimens of
128 doxorubicin, vincristine, dactinomycin, cyclophosphamide, and/or
129 interferon- α are considered palliative treatment^{21 22 23}. We performed
130 adequate removal of the tumor, and thus, radiotherapy and chemotherapy
131 were not required. This patient did not develop the recurrence more than
132 6 months after surgery.

133

134

135 Conclusions

136 To the best of our knowledge, this is the first case of a tumoral
137 hemorrhage due to a primary intracranial leiomyosarcoma. The
138 prognosis for primary intracranial leiomyosarcoma is poor. Adequate
139 removal of the tumor may prevent a recurrence without postoperative
140 radiotherapy and chemotherapy.

141

142

- 143 1. Lewis AJ. Sarcoma metastatic to the brain. *Cancer*. 1988;61:593-601.
- 144 2. Wronski M, de Palma P, Arbit E. Leiomyosarcoma of the uterus metastatic to brain: a case
145 report and a review of the literature. *Gynecologic oncology*. 1994;54:237-241.
- 146 3. Fujimoto Y, Hirato J, Wakayama A, Yoshimine T. Primary intracranial leiomyosarcoma in
147 an immunocompetent patient: case report. *Journal of neuro-oncology*. 2011;103:785-790.
- 148 4. Kelley BC, Arnold PM, Grant JA, Newell KL. Primary intracranial beta-human chorionic
149 gonadotropin-producing leiomyosarcoma in a 2-year-old immunocompetent child. *Journal*
150 *of neurosurgery Pediatrics*. 2012;10:121-125.
- 151 5. Mathieson CS, St George EJ, Stewart W, Sastry J, Jamal S. Primary intracranial
152 leiomyosarcoma: a case report and review of the literature. *Child's nervous system* :

- 153 *ChNS : official journal of the International Society for Pediatric Neurosurgery.*
154 2009;25:1013-1017.
- 155 6. Takei H, Powell S, Rivera A. Concurrent occurrence of primary intracranial Epstein-Barr
156 virus-associated leiomyosarcoma and Hodgkin lymphoma in a young adult. *Journal of*
157 *neurosurgery.* 2013;119:499-503.
- 158 7. Haykal HA, Wang AM, Zamani A. Leiomyosarcoma metastatic to the brain: CT features
159 and review. *AJNR American journal of neuroradiology.* 1987;8:911-912.
- 160 8. Shapiro S. Myelopathy secondary to leiomyosarcoma of the spine. Case report. *Spine.*
161 1992;17:249-251.
- 162 9. Nirmel KN, Aleksic S, Sidhu G, Emancipator S, Ransohoff J, Budzilovich GN.
163 Leiomyosarcoma metastatic to the brain. *Surgical neurology.* 1978;10:147-151.
- 164 10. Paulus W, Slowik F, Jellinger K. Primary intracranial sarcomas: histopathological
165 features of 19 cases. *Histopathology.* 1991;18:395-402.
- 166 11. Lamyman MJ, Giele HP, Critchley P, Whitwell D, Gibbons M, Athanasou NA. Local
167 recurrence and assessment of sentinel lymph node biopsy in deep soft tissue
168 leiomyosarcoma of the extremities. *Clinical sarcoma research.* 2011;1:7.
- 169 12. Louis DN1 REJ, Dickersin GR, Petrucci DA, Rosenberg AE, Ojemann RG. Primary
170 intracranial leiomyosarcoma. Case report. *Journal of neurosurgery.* 1989;71:4.
- 171 13. Lee TT, Page LK. Primary cerebral leiomyosarcoma. *Clinical neurology and neurosurgery.*
172 1997;99:210-212.
- 173 14. Eckhardt BP, Brandner S, Zollikofer CL, Wentz KU. Primary cerebral leiomyosarcoma in
174 a child. *Pediatric radiology.* 2004;34:495-498.
- 175 15. Hussain S, Nanda A, Fowler M, Ampil FL, Burton GV. Primary intracranial
176 leiomyosarcoma: report of a case and review of the literature. *Sarcoma.* 2006;2006:52140.
- 177 16. Aeddula NR, Pathireddy S, Samaha T, Ukena T, Hosseinnezhad A. Primary intracranial
178 leiomyosarcoma in an immunocompetent adult. *Journal of clinical oncology : official*
179 *journal of the American Society of Clinical Oncology.* 2011;29:e407-410.
- 180 17. Zhang H, Dong L, Huang Y, Zhang B, Ma H, Zhou Y, et al. Primary intracranial
181 leiomyosarcoma: review of the literature and presentation of a case. *Onkologie.*
182 2012;35:609-616.
- 183 18. Alijani B, Yousefzade S, Aramnia A, Mesbah A. Primary intracranial leiomyosarcoma.
184 *Archives of Iranian medicine.* 2013;16:606-607.
- 185 19. Saito N AK, Hirai N, Ishii M, Fujita S, Hiramoto Y, et al. . Primary Intracranial
186 Leiomyosarcoma of the Cavernous Sinus: Case Report. *Austin J Med Oncol.* 2014;1(2).
- 187 20. Gautam S, Meena RK. Primary intracranial leiomyosarcoma presenting with massive
188 peritumoral edema and mass effect: Case report and literature review. *Surgical neurology*
189 *international.* 2017;8:278.
- 190 21. de Vries J, Scheremet R, Altmannsberger M, Michilli R, Lindemann A, Hinkelbein W.

- 191 Primary leiomyosarcoma of the spinal leptomeninges. *Journal of neuro-oncology*.
192 1994;18:25-31.
- 193 22. Lee ES, Locker J, Nalesnik M, Reyes J, Jaffe R, Alashari M, et al. The association of
194 Epstein-Barr virus with smooth-muscle tumors occurring after organ transplantation.
195 *The New England journal of medicine*. 1995;332:19-25.
- 196 23. McClain KL, Leach CT, Jenson HB, Joshi VV, Pollock BH, Parmley RT, et al. Association
197 of Epstein-Barr virus with leiomyosarcomas in young people with AIDS. *The New*
198 *England journal of medicine*. 1995;332:12-18.

199
200 FIG. 1 Axial T1-weighted MR images and T2-weighted MR images on
201 admission (A, B), enhanced T1-weighted MR images six days later (C),
202 T2-weighted MR images nine days later (D)

203
204 FIG. 2 Computed tomography scans with tumoral hemorrhage (A),
205 intraventricular hemorrhage (B).

206
207 Fig. 3 En bloc resection is performed. The tumor is reddish and solid.

208
209 Fig. 4 Photomicrographs of tumor sections. Hematoxylin and
210 eosin-stained sections revealing spindled (A). Immunoperoxidase stains
211 showed positively for smooth muscle antigen (B).

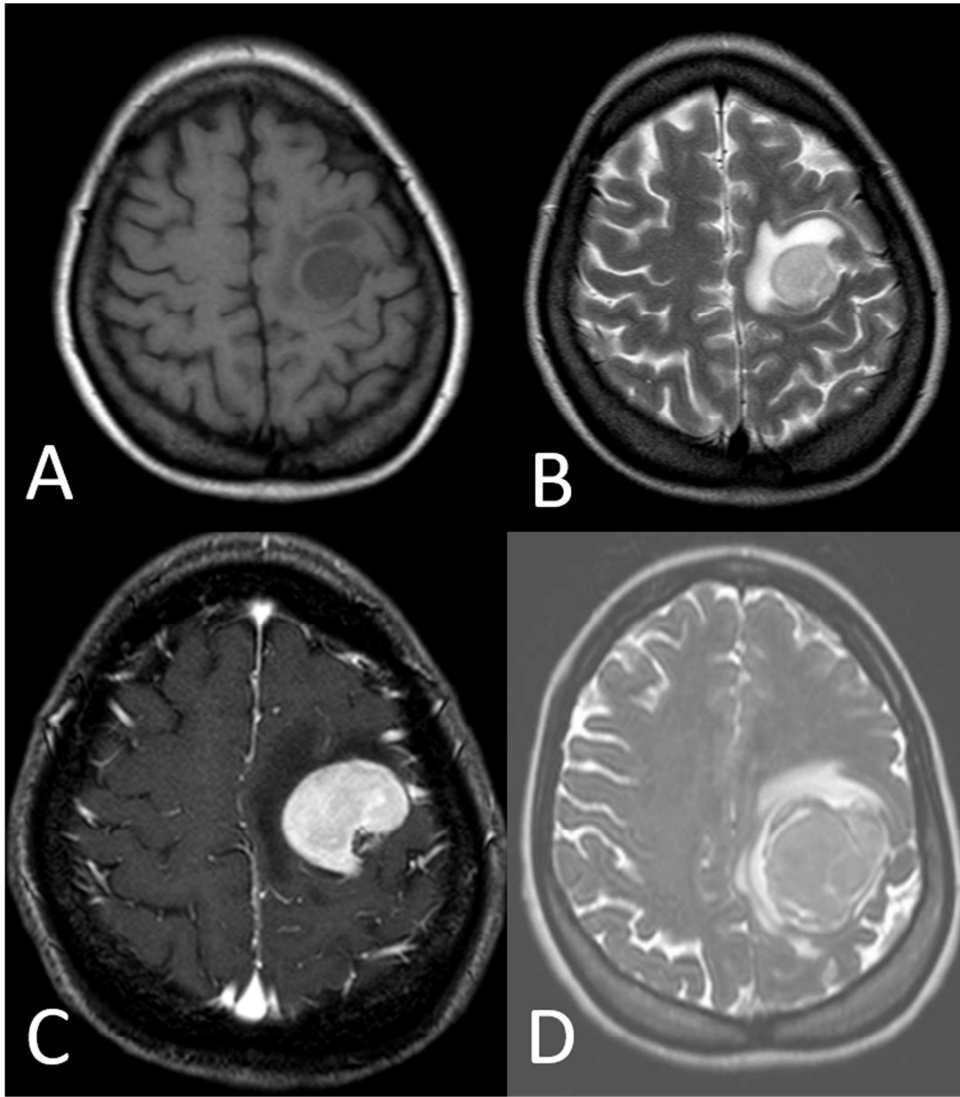
212
213 FIG. 5 Enhanced T1-weighted MR images after six months of surgery (A),
214 computed tomography scans after surgical removal (B),.

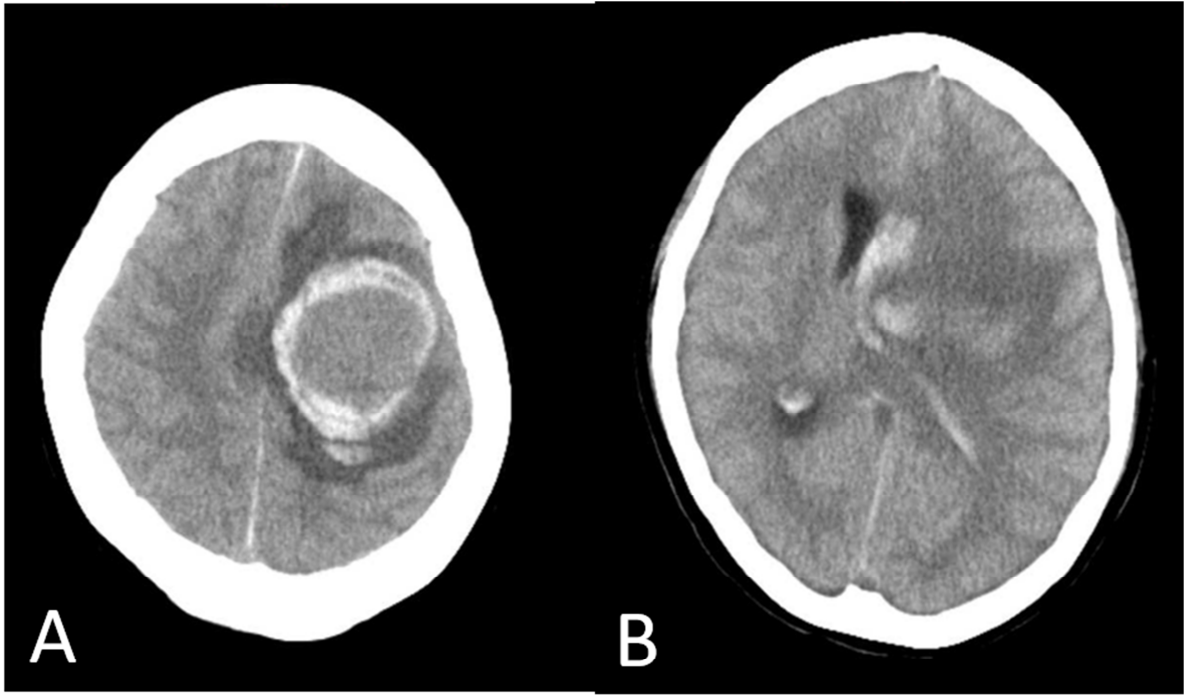
215
216

Table 1 Reported cases of primary intracranial leiomyosarcoma

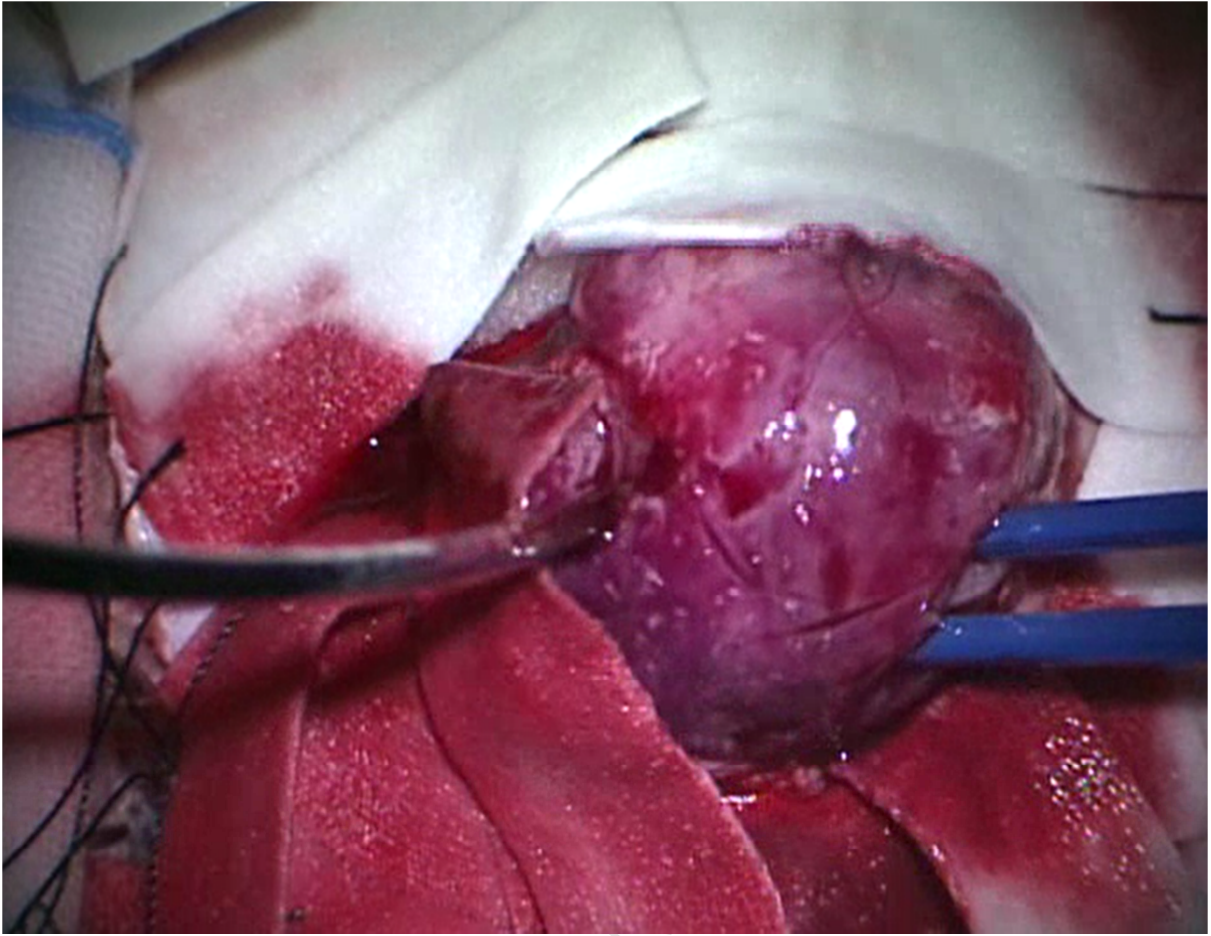
Author	Age (years)	Sex	Tumor size (cm)	Tumor lesion	Resection	Adjuvant therapy	Follow up (months)	Outcome
Louis et al., 1989	72	F	5×4×4	lt. lateral ventricle	CR	None	6	Alive
Lee TT et al., 1997	8	M	ND	lt. parietal	CR	RT + CT (Adriamycin, procarbazine)	20	Alive
Eckhardt et al., 2004	13	M	8×7×4	lt. parietal	CR	RT + CT	21	Dead
Hussain et al., 2006	26	M	ND	rt. parieto-occipital	CR	RT (61.8Gy 34fr) + CT	7	Dead
Mathieson et al., 2009	5	M	ND	subdural collection, rt. frontal	CR	RT (40.25Gy 23fr), CT (Vincristine, Ifosfamide, Doxorubicin, Etoposide)	18	Alive
Fujimoto et al., 2010	45	F	ND	lt. CP angle	PR	RT	10	Dead
Aeddula et al., 2011	58	M	1.6×1.4	lt. anteromedial temporal lobe	CR	None	3 weeks	Dead
Zhang et al., 2012	26	F	ND	corpus callosum	PR	Gamma knife	3	Dead
Alijani et al., 2013	19	M	5cm	subcutaneous, rt. parieto-occipital	CR	RT	30	Alive
Saito et al., 2014	75	F	ND	lt. cavernous sinus	biopsy	Stereotactic radiosurgery 15Gy 5fr	44	Dead
Gautam et al., 2017	45	M	5.9×4.4×5.2	lt. temporoparietal	PR	RT	12	NA dropout
present case	41	F	4×4×5	lt. frontal	CR	None	7	Dead

ND, not described; F, female; M, male; lt., left; rt., right; CR, complete resection; PR, partial resection; RT, radiotherapy; CT, chemotherapy; NA, not available

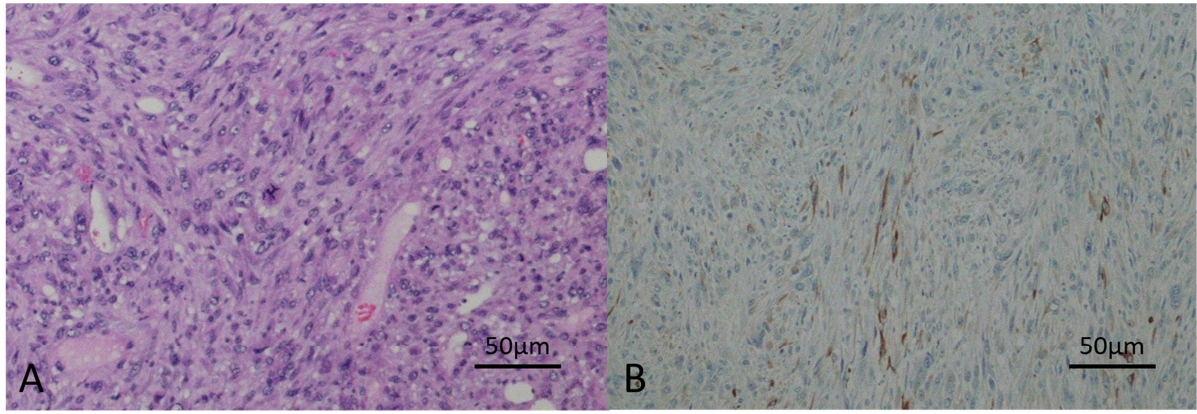




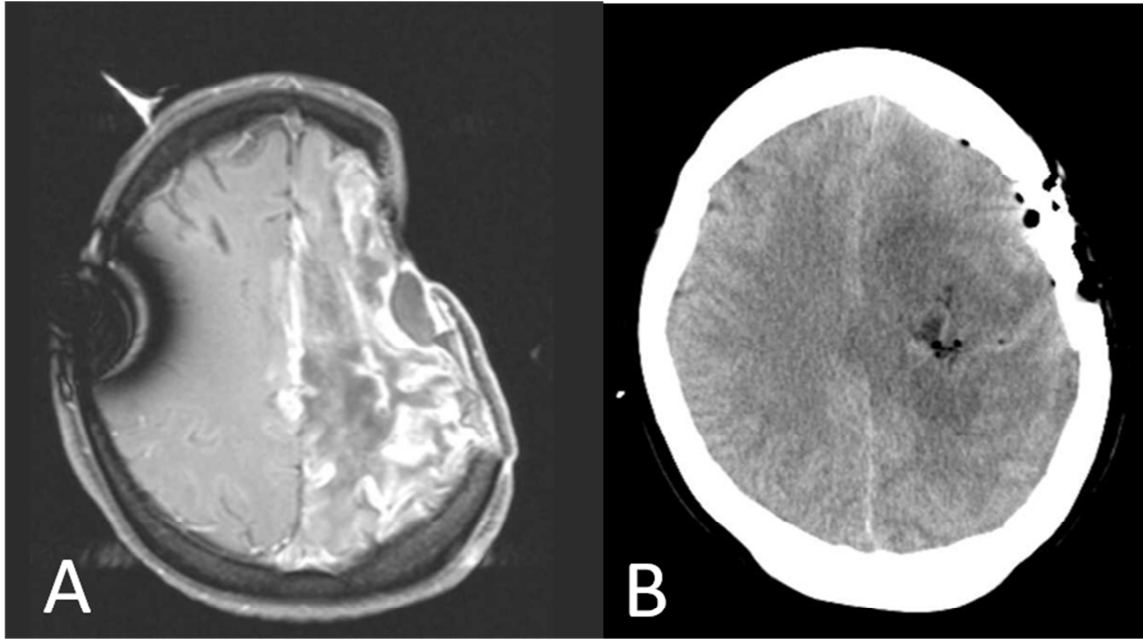
ACCEPTED MANUSCRIPT



ACCEPTED I



ACCEPTED MANUSCRIPT



ACCEPTED MANUSCRIPT

Highlight for review

• To the best of our knowledge, our report is the first documented case of a tumoral hemorrhage due to a primary intracranial leiomyosarcoma.

• I'm very pleased to see the favorable comments of reviewers. I fundamentally agree with all these comments and incorporated them.

• I added one figure about the removal of the tumor (Fig 3) and the review of the literature (table 1).

Abbreviation list

CT computed tomography

MRI magnetic resonance imaging

CNS central nervous system

ACCEPTED MANUSCRIPT