



# Hippocampal deep brain stimulation: persistent seizure control after bilateral extra-cranial electrode fracture

Massimo Piacentino<sup>1</sup>  · Giacomo Beggio<sup>1</sup> · Lara Zordan<sup>1</sup> · Paolo Bonanni<sup>2</sup>

Received: 11 September 2017 / Accepted: 8 May 2018  
© Springer-Verlag Italia S.r.l., part of Springer Nature 2018

## Abstract

Hippocampal deep brain stimulation (DBS) can provide an effective alternative for intractable temporal lobe epilepsy. In this case report, we describe a peculiar outcome after a post-traumatic wire-disconnection of a bilateral hippocampal DBS device. The patient presented a postoperative long-term significant reduction in seizure frequency even with an absent electric stimulation. This case gives the possibility to consider alternatives in epilepsy surgery, based on stimulation interference (lesional or electrical disturbing) in the epileptogenic zone.

**Keywords** Hippocampal DBS · Temporal lobe epilepsy · Traumatic wire-disconnection · Epilepsy surgery · Long-term seizure control

## Introduction

Epilepsy is a common neurological disorder that affects 0.5 to 1% of the population [4]. Almost 30% of epileptic patients suffers from an uncontrolled disease or presents drug-related side effects [6]. Surgery for epilepsy or deep brain stimulation (DBS) could provide an effective alternative in this medical refractory subgroup [3].

Hippocampal DBS showed good results for intractable temporal lobe epilepsy [8] by inducing significant ameliorations in seizure freedom and a borderline significant improvement in quality of life [1, 2, 10, 12].

Here, we present a peculiar outcome after posttraumatic wire-disconnection of a bilateral hippocampal DBS device for medical-refractory temporal lobe epilepsy with a long-term significant reduction in seizure frequency even with an absent electric stimulation.

## Case description

A 48-year-old male patient with a history of epilepsy with complex partial seizures came to our institution for a presurgical evaluation. He reported a posttraumatic generalized seizure at 9 months of age without subsequent episodes until the age of 25. From that moment on, he complained of occasional seizures starting with dizziness and generalized discomfort (face sensation of warmth) followed by hypertonic or tonic-clonic generalized episodes. After the loss of consciousness, the family members reported the presence of staring, chewing automatisms, vocalizations, and purposeless hands automatisms with final trunk inconstant (in terms of laterality) deviations. During the first years, the patient underwent several inconclusive neurological evaluations (electroencephalogram, clinical examination and seizures observation). All the tests were not able to identify a clear epileptogenic focus or at least the lateralization in terms of temporal side. All the electroencephalograms (EEGs) showed inter-ictal phases without a prevalence in terms of electrical pathological signs (spikes, spike-waves, and constant Delta-Tetha rhythms with no lateralization). The epileptic seizures were characterized by a frequency of 8 episodes per month, presented a mean duration of 2 to 3 min each, and were followed by drowsiness lasting up to 10 min. The patient was unsuccessfully treated by an association of carbamazepine, phenobarbital, and clonazepam (regularly controlled plasma concentrations).

---

✉ Massimo Piacentino  
massimo.piacentino@ulssvicenza.it

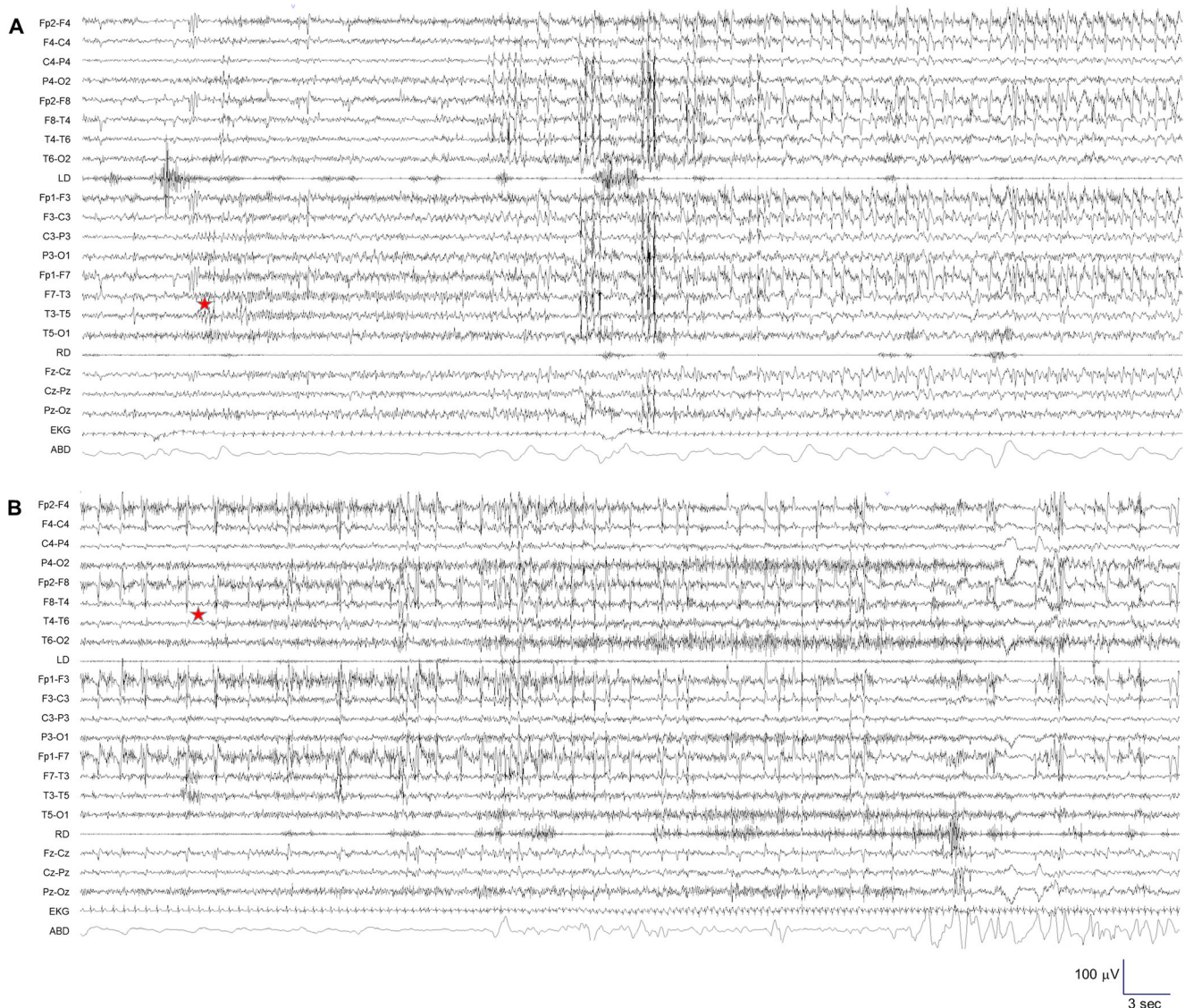
<sup>1</sup> Department of Neurosurgery, San Bortolo Hospital, Viale Rodolfi, 37, 36100 Vicenza, Italy

<sup>2</sup> IRCS A. Meda, Conegliano, Italy

## Presurgical evaluation

The patient was admitted for presurgical evaluation on March 2009. The neurological examination was normal and the neuropsychological tests showed a QIv at 67, a QIp at 75 and a QIt at 67 with verbal and visuospatial memory alteration associated to a deficit of attention. Standard and functional cerebral MRI showed a bi-temporal hippocampal sclerosis and a left dominant hemispheric localization. The preoperative antiepileptic therapy was rufinamide 1200 mg/day (600 mg + 600 mg), valproate 1000 mg/day (500 mg + 500 mg), phenobarbital 200 mg/day (100 mg + 100 mg), and topiramate 250 mg/day (50 mg + 100 mg + 100 mg). The inter-critical EEG showed bi-temporal slow wave rhythm with fronto-temporal left sharp waves and temporo-occipital high-voltage slow waves on the right hemisphere.

The video EEG recording documented two different kinds of seizure: staring with gestural automatism with both hands and feet followed by chewing and swallowing (Fig. 1a). During the attack, the patient was not able to respond to simple questions with evident unawareness and confusion. The episodes lasted about 1 min and were followed by confusion and aphasia up to 3 min. These seizures were characterized by temporal spikes starting and lasting on the left temporal hemisphere. The second typology of epileptic attacks was characterized by blinking, face muscle contractions with mouth repetitive movements, trunk bending on both sides, complex gestural automatisms, vocalization with confusion, and unawareness (Fig. 1b). These seizures lasted about 1 min and presented post-ictal dizziness up to 2 or 3 min. The video EEG recording showed spikes starting from the right temporal hemisphere.



**Fig. 1** EEG recording. Left (a) and right (b) temporal seizure. The red star indicates the beginning of the seizure

## Surgery

The presurgical evaluation did not give the possibility to plan a surgical action that could obtain a complete control of the symptomatology. The remaining alternative solutions were vagal nerve stimulation (VNS), anterior thalamic nucleus DBS (AN-DBS), or bilateral hippocampal stimulation. Considering the preoperative assessment and the evidence of bi-temporal independent foci with bilateral hippocampal sclerosis, we decided to perform a bilateral DBS hippocampal stimulation.

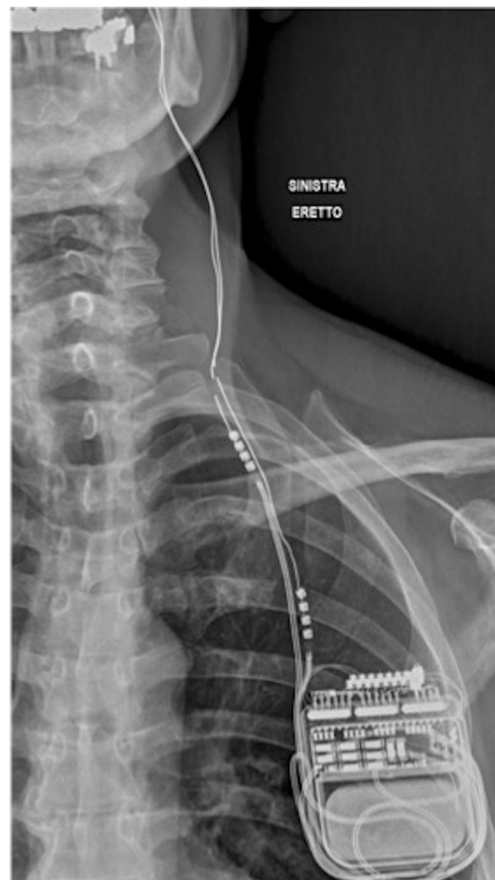Surgery was performed in two steps. First, the stereotactic hippocampal electrodes were implanted, followed by electrode externalization and video EEG recording, and second, the leads were internalized and connected to the pulse generator.

Under general anesthesia, the patient was fixed to the stereotactic frame (Radionics CRW Burlington Vermont), stereotactic computed tomography (CT) scan was performed, charged into the neuronavigation system (Stealth Station Medtronic Minneapolis) and merged with gadolinium-enhanced T1-weighted MRI and cerebral Angio-CT scan. Right and left hippocampal targeting was obtained choosing the Subiculum as center. The trajectory passed through an occipital extra-ventricular line parallel to the length of the hippocampus with contact 0 at the tip of the hippocampal head. The intraoperative X-ray control showed a mispositioning of the right electrode although the EEG signal was compatible with the chosen target (slow wave rhythm with sharp wave). The electrode was removed and replaced in the planned position. After surgery, the external cables were connected to the electrodes for stereo EEG recording. The inter-critical EEG showed bilateral slow waves rhythm with bilateral independent spikes and waves. Unfortunately, no seizures were seen in the postoperative week. The external cables were subsequently removed because of the potential infection risk. Successively, the wire extensions were tunneled along the neck and connected to the pulse generator (Medtronic Kinetra Medtronic Inc. Minneapolis MN) in a sub-clavicular pouch on the anterior right side of the chest. During the postoperative period, no seizures were recorded and the pulse generator was activated 2 weeks later starting with 0.5 V, 130 Hz PW 450 Ms. The intensity was progressively increased up to 1.5 V in the following month. No side effect or surgical complications were observed. Medical therapy was left unchanged.

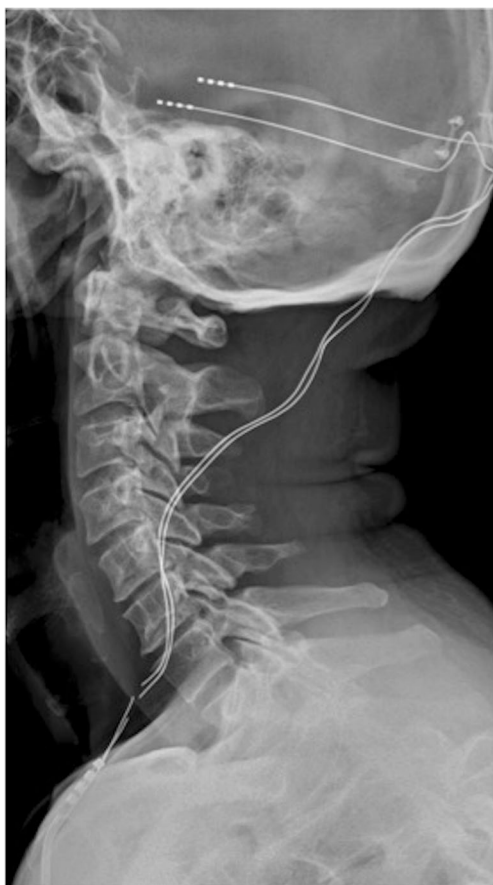## Follow-up

After an initial stability of the illness, in May 2011, the number of seizures started to decrease progressively reaching a frequency of 2 episodes per month. In June 2012, the patient

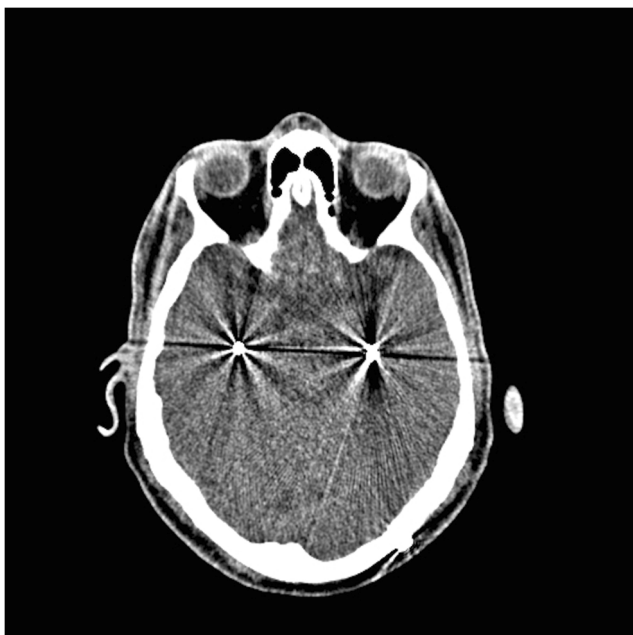had a severe bladder infection with high fever that induced a generalized tonic-clonic seizure with fall and consequently fracture of the right electrode and stretching of both extensions. After this episode, the patient experienced only 3 minor episodes that lasted up to 1 min without loss of consciousness. In January 2015, a bronchopneumonia induced a second generalized seizure with subsequent fall and fracture of the left implanted electrode, confirmed by impedance measurement, cranial and neck X-ray (Figs. 2 and 3). The post-traumatic CT scan did not show any kind of contusive or hemorrhagic brain damages (Fig. 4). Secondary to the low frequency of epileptic symptoms, we decided a wait-and-see solution. After 2 months, the patient presented a new generalized seizure. We newly decided to wait-and-see and eventually propose a surgical solution in case of epileptic recurrence. After the posttraumatic total disconnection of the DBS system, the patient reported no major seizure (Fig. 5). The EEG presented the absence of great pathological aspects except for few spikes and some bilateral slow waves. At present, at 5 years from the surgery, the patient describes only minor dizziness sensation at the awakening. The most recent neuropsychological evaluation showed a QIv at 74, a QIp at 82 and a QIt at 75.



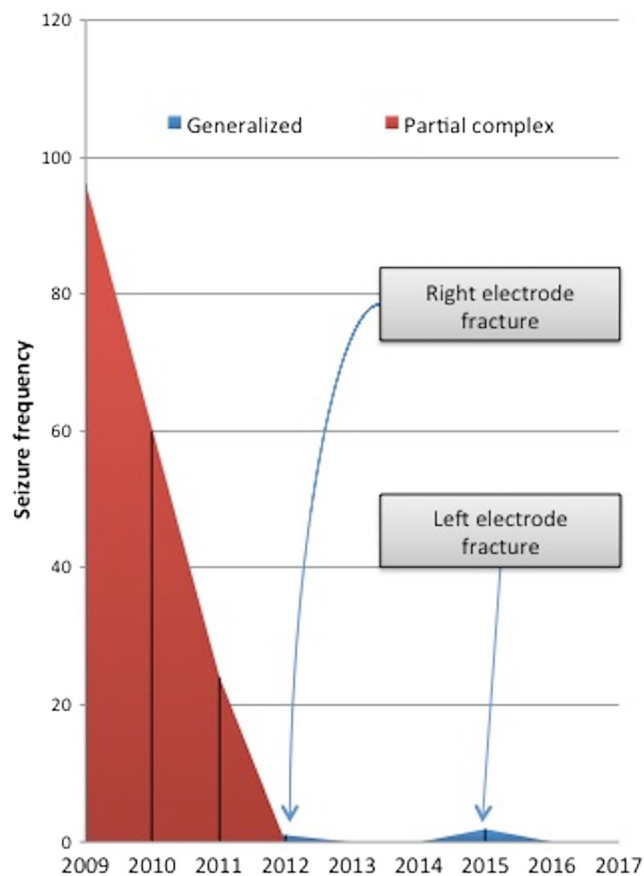
**Fig. 2** Coronal X-ray confirming the fracture and the stretching of the implanted electrodes



**Fig. 3** Sagittal X-ray confirming the fracture and the stretching of the implanted electrodes



**Fig. 4** Axial reconstruction of post traumatic CT scan, showing the absence of contusive or hemorrhagic brain damages



**Fig. 5** Graphic representation of seizure episodes during the 8 years of follow-up. The y-axis indicates the number of episodes per year. The x-axis shows the years of follow-up

## Discussion

Medial temporal lobe epilepsy is characterized by electrical seizure onset in the amygdala and hippocampus [8] and medial temporal lobe structures stimulation via DBS showed the possibility to control the symptomatology [11]. As described by Sprengers et al. [9], a direct stimulation of the epileptogenic onset region may lead to a focal inhibition of the hyper excitable region and suppression of the epileptic symptoms. However, the mechanism of action of DBS remains unclear and some authors explain the efficacy of DBS by the induced lesion secondary to the insertion of the electrode, the microthalamotomy effect [5].

This case report shows a very particular outcome in terms of controlling a refractory epileptic disease without a real current delivery. Discussing the patient's file two possible explanations is fundable to describe the produced DBS effect. First, the related iatrogenic lesion secondary to the repositioning of the right electrode for the reported misplacement could have produced a disconnection on the right hippocampus. However, this could not efficiently explain the control of the bi-temporal epilepsy. Secondly, the presence of a foreign body

inside the hippocampus may interfere with the electrical activity inside the involved neuronal pathway. Theoretically, a deep electrical recording represents the only way to show a possible change in the involved neural structures. However, this cannot be proposed to the patient with the only goal to detect a merely speculative aspect.

The amelioration of QI reported by the patient was in contrast with the results reported by the literature. Both Tellez-Zenteno et al. [9] and McLachlan et al. [7] reported the absence of amelioration or even slight worsening in neuropsychological outcome after hippocampal DBS. However, the effects of neuromodulation were recorded with a short follow-up and therefore could not be appropriately compared to our results.

This case focuses also on the fragility of the DBS implant. Patients that are suspected to be prone to falls need a periodical test concerning the impedance of their neuromodulating system. This control should be made in all patients implanted with DBS system without a disease selection subgroup. Therefore, either patients affected by epilepsy or by other neurological disorders, like Parkinson's Disease, should be continuously monitored.

## Conclusions

This case gives the possibility to explore and consider new alternatives in epilepsy surgery. Less invasive methodologies, based on the idea of stimulation interference (lesional or electrical disturbing) in the epileptogenic zone, could represent a potential surgical solution. Moreover, this does not contraindicate or prevent a traditional and more aggressive surgical treatment in case of failure.

Although the particular interest that this case could rise, it is necessary to gather a larger number of patients with similar conditions in order to draw reliable conclusions.

## Compliance with ethical standards

**Conflict of interest** The authors declare that they have no conflict of interest.

**Patient consent** The patient has consented to submission of this case report to the journal.

## References

1. Borghs S, de la Loge C, Cramer JA (2012) Defining minimally important change in QOLIE-31 scores: estimates from three placebo-controlled lacosamide trials in patients with partial-onset seizures. *Epilepsy Behav* 23(3):230–234
2. Cramer JA, Hammer AE, Kustra RP (2004) Quality of life improvement with conversion to lamotrigine monotherapy. *Epilepsy Behav* 5(2):224–230
3. Engel JJ, Wiebe S, French J, Sperling M, Williamson P, Spencer D, Gummit R, Zahn C, Westbrook E, Enos B (2003) Practice parameter: temporal lobe and localized neocortical resections for epilepsy. *Epilepsia* 44(6):741–751
4. Forsgren L, Beghi E, Öun A, Sillanpää M (2005) The epidemiology of epilepsy in Europe - a systematic review. *Eur J Neurol* 12(4): 245–253
5. Hodaie M, Wennberg RA, Dostrovsky JO, Lozano AM (2002) Chronic anterior thalamus stimulation for intractable epilepsy. *Epilepsia* 43(6):603–608
6. Kwan P, Beodie MJ (2000) Early identification of refractory epilepsy. *N Engl J Med* 342(5):314–319
7. McLachlan RS, Pigott S, Tellez-Zenteno JF, Wiebe S, Parrent A (2010) Bilateral hippocampal stimulation for intractable temporal lobe epilepsy: impact on seizures and memory. *Epilepsia* 51(2): 304–307
8. Spencer SS, Guimaraes P, Katz A, Kim J, Spencer D (1992) Morphological patterns of seizures recorded intracranially. *Epilepsia* 33(3):537–545
9. Sprengers M, Vonck K, Carrette E, Marson AG, Boon P (2014) Deep brain and cortical stimulation for epilepsy. *Cochrane Database Syst Rev*. <https://doi.org/10.1002/14651858.CD008497.pub2>
10. Tellez-Zenteno JF, McLachlan RS, Parrent A, Kubu CS, Wiebe S (2006) Hippocampal electrical stimulation in mesial temporal lobe epilepsy. *Neurology* 66(10):1490–1494
11. Velasco M, Velasco F, Velasco AL, Boleaga B, Jimenez F, Brito F, Marquez I (2000) Subacute electrical stimulation of the hippocampus blocks intractable temporal lobe seizures and paroxysmal EEG activities. *Epilepsia* 41(2):158–169
12. Wiebe S, Matijevic S, Eliasziw M, Derry PA (2002) Clinically important change in quality of life in epilepsy. *J Neurol Neurosurg Psychiatry* 73(2):116–120