



Spontaneous spinal epidural haematoma mimicking acute ischaemic stroke: case report

A. Romaniuc¹ · S. Maier^{1,2} · M. Buruian³ · L. Liptak⁴ · A. Bălașa⁴

Received: 20 April 2018 / Accepted: 25 April 2018
© Belgian Neurological Society 2018

Keywords Spontaneous spinal epidural hematoma · Ischemic stroke mimic · Hemiparesis

Spontaneous spinal epidural haematoma (SSEH) is an uncommon condition with an estimated incidence of 0.1/100.000 people/year representing less than 1% of spinal epidural space-occupying lesions. It is defined as an acute myelopathy leading to severe neurological deficits caused by the accumulation of blood in the vertebral epidural space in the absence of an underlying haematologic or haemostatic disorder, vascular malformation, trauma, systemic or local disease, drug use or any history of medications that interfere with the coagulation cascade [1–3].

The manifestations of SSEH range from neck or back pain with/without radiculopathy, paraparesis, tetraparesis (most common) to hemiparesis (feature most often attributed to a supraspinal injury such as stroke). The posterior epidural venous network is the most likely source of bleeding [2, 4].

Faced with a suspected SSEH, based on the clinical presentation, an emergency spinal computer tomography (CT) or magnetic resonance imaging (MRI) should be performed (MRI being the investigation of choice). An epidural haematoma is isointense to the spinal cord in T₁ weighted images, hyperintense/heterogeneous in T₂ weighted images within the first 24 h, and hyperintense in both T₁ and T₂ sequences by 48 h. Most symptomatic patients require early surgical intervention to evacuate the haematoma as the main

treatment, although there are cases of patients undergoing conservative therapy [3, 5].

A 74-year-old male presented with acute onset of left hemiparesis grade 4/5 MRC and was admitted to the neurology ward with the diagnosis of acute ischaemic stroke outside the time window for thrombolysis or thrombectomy. At admission the patient had no neck pain or bladder dysfunction. Head CT showed no pathological changes for acute stroke. There was no history of trauma, smoking or drug use. The patient did not use anticoagulants or antiplatelets before admission. On the following day, he presented acute pain in the left shoulder, then a progression of left hemiparesis to grade 3/5 MRC superior limb and 2/5 MRC inferior limb, superficial sensory loss to the upper left limb, then tetraparesis within an hour, but without cranial nerve involvement. An urgent cervical spine CT revealed a large epidural mass compressing the spinal cord between C4–D1. Spinal MRI confirmed the diagnostic of epidural haematoma. The patient was transferred to the neurosurgery ward and underwent emergency left C5–C6–C7 hemilaminectomy with haematoma evacuation. Postoperative, within 48 h the motor deficits improved in all limbs and he was able to walk without support at the time of discharge. At the 3-month follow-up he underwent a bilateral vertebral artery angiography, which did not reveal any pathological changes, therefore, excluding a low flow arterial malformation as the etiology of the haematoma that could easily have been missed on the first MRI examination. At this point the patient had only a mild paraparesis grade 4+/5MRC (Figs. 1, 2, 3, 4).

Spontaneous spinal epidural hematoma is an acute and severe condition without a clear etiology that can lead to progressive and permanent neurological damage if left untreated and should be added to the list of differential diagnoses of ischaemic stroke in patients without supraspinal signs. We presented the case of an elderly patient with no significant medical history, whose onset symptoms pointed

✉ S. Maier
maier_smaranda@yahoo.com

¹ Neurology 1 Clinic, Emergency Clinical County Hospital, Targu-Mures, Romania

² Discipline of Neurology, UMF, Targu-Mures, Romania

³ Department of Radiology, University of Medicine and Pharmacy Targu Mures, Targu-Mures, Romania

⁴ Neurosurgery Clinic, Emergency Clinical County Hospital, Targu-Mures, Romania

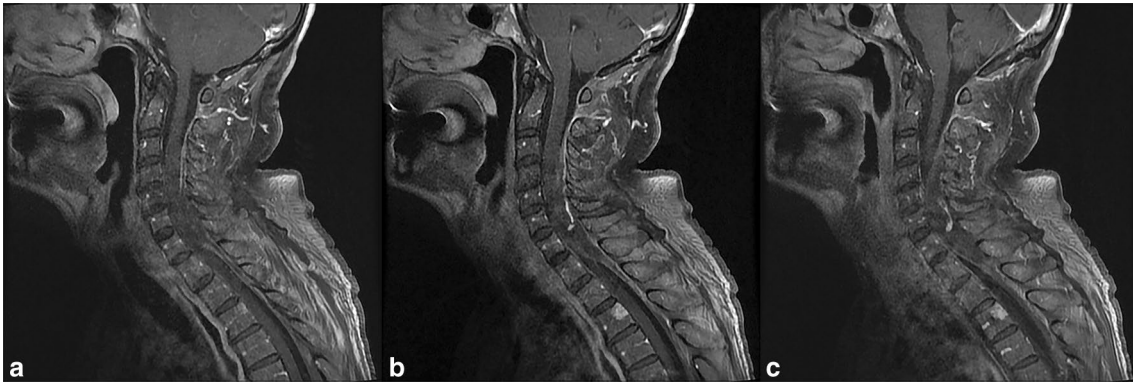


Fig. 1 Pre-operative sagittal T1 weighted spinal MRI with gadolinium administration is showing an isointense mass lesion compressing the spinal cord between C4 and D1

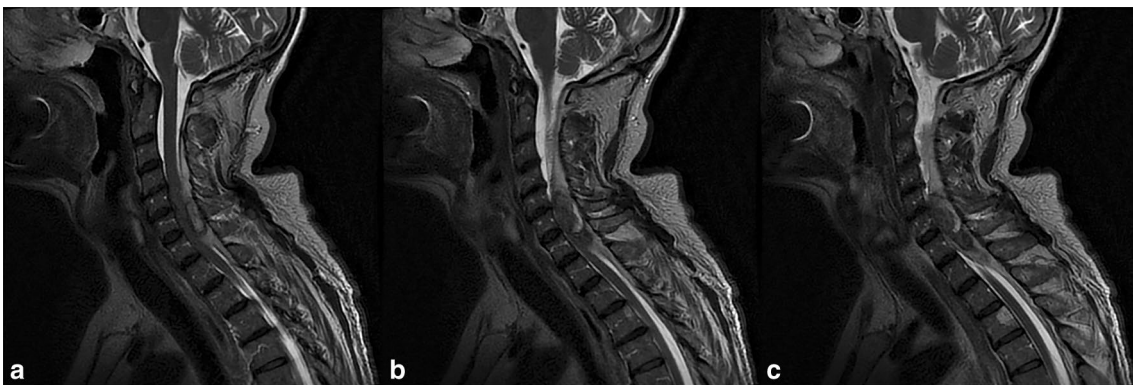


Fig. 2 Pre-operative sagittal T2 weighted spinal MRI reveals the same lesion with heterogeneous aspect

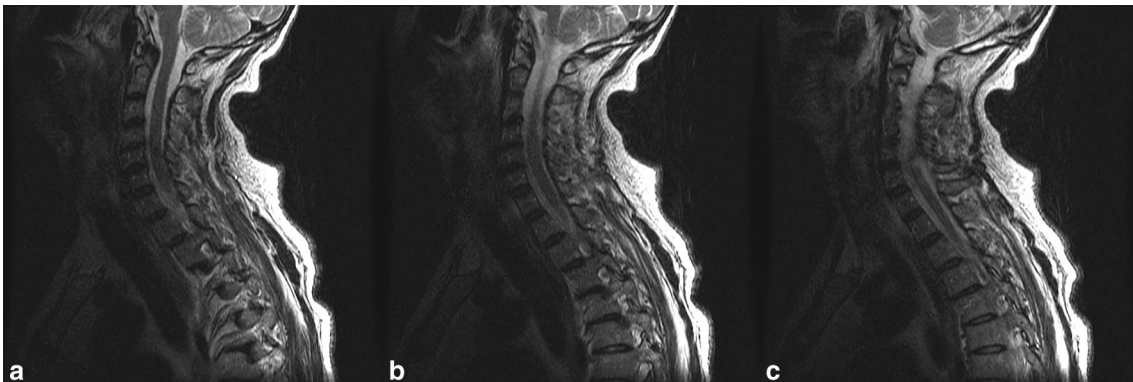

Fig. 3 Postoperative sagittal T2 weighted spinal MRI without any compression remaining on the spinal cord

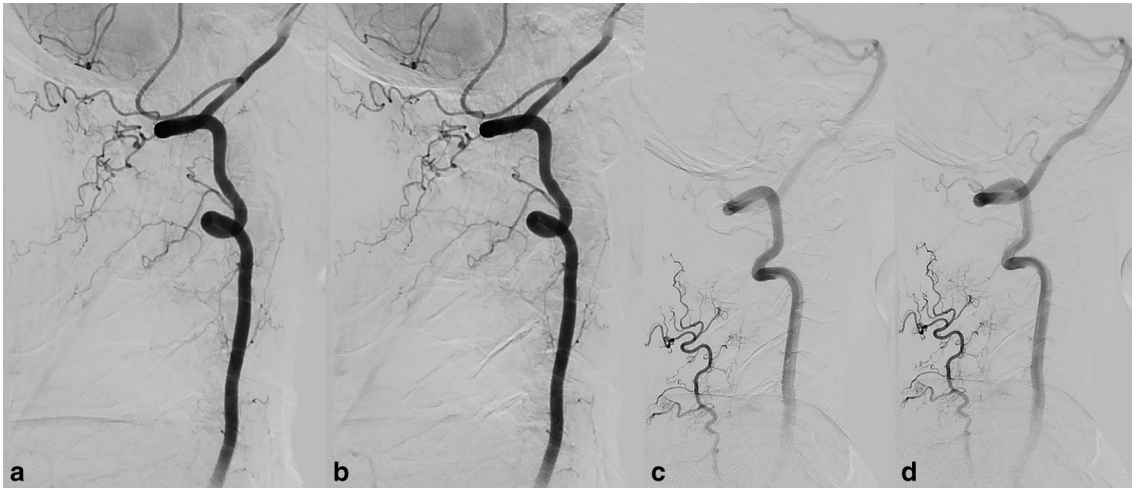


Fig. 4 Three months follow-up of bilateral vertebral artery angiography without any signs of vascular malformations (**a, b**—right vertebral artery and **c, d**—left vertebral artery)

towards the diagnostic of ischaemic stroke, but his subsequent clinical evolution had an unexpected outcome, radically changing the therapeutic approach.

Compliance with ethical standards

Conflict of interest The authors declare that they have no conflict of interest.

Ethical approval The authors certify that they comply with the Principles of Ethical Publishing.

Informed consent The authors certify that the patient reported here gave his informed consent.

References

1. Figueroa J, DeVine JG (2017) Spontaneous spinal epidural hematoma: literature review. *J Spine Surg* 3(1):58–63. <https://doi.org/10.21037/jss.2017.02.04>
2. Raasck K, Habis AA, Aoude A et al (2017) Spontaneous spinal epidural hematoma management: a case series and literature review. *Spinal Cord Ser Cases* 3:16043. <https://doi.org/10.1038/scsanc.2016.43> (eCollection 2017)
3. Gopalkrishnan CV, Dhakoji A, Nair S (2012) Spontaneous cervical epidural hematoma of idiopathic etiology: case report and review of literature. *J Spinal Cord Med* 35(2):113–117. <https://doi.org/10.1179/2045772312Y.0000000001> (Epub 2012 Feb)
4. Akimoto T, Yamada T, Shinoda S et al (2014) Spontaneous spinal epidural hematoma as a potentially important stroke mimic. *J Cent Nerv Syst Dis* 6:15–20. <https://doi.org/10.4137/JCNSD.S13252> (eCollection 2014)
5. Domenicucci M, Mancarella C, Santoro G et al (2017) Spinal epidural hematomas: personal experience and literature review of more than 1000 cases. *J Neurosurg Spine*. 27(2):198–208. <https://doi.org/10.3171/2016.12.SPINE15475> (Epub 2017 Jun 2)