



Status epilepticus and white matter ischemia complicating dural arteriovenous fistula

M. Derasse¹ · K. Jacobs² · T. Duprez³ · P. Goffette³ · P. Hantson¹ 

Received: 30 April 2018 / Accepted: 12 May 2018
© Belgian Neurological Society 2018

Keywords Dural arteriovenous fistula · Embolization · Status epilepticus · White matter ischemia · Venous hypertension

Introduction

A 56-year-old man was admitted to the intensive care unit (ICU) for refractory status epilepticus. His medical history started in September 2014 when the patient developed left retro-orbital pain with conjunctival chemosis, ptosis and paresthesia of the scalp. Visual acuity was preserved at this stage (80/100 at left eye). Ophthalmological examination revealed in addition to left conjunctival chemosis, a major dilation of the capillaries on the ocular surface. Intraocular pressure was 19 mmHg at the left eye and 16 mmHg at the right eye. Fundoscopic examination was consistent with a bilateral papilledema. Initial brain magnetic resonance imaging (MRI) examination revealed marked enlargement of the left ophthalmic vein and abnormally increased contrast enhancement of dilated occipital veins and of the left portion of the lateral venous sinus. No parenchymal lesions were noted at the time. Angiography was performed to confirm the suspicion of left carotid-cavernous fistula (Fig. 1). During the first embolization session (January 2015), the main arterial feeders arising from the distal part of the left occipital artery were embolized with a histoacryl/lipiodol mixture. During the same session, partial occlusion of the right transverse and sigmoid sinus was diagnosed, contraindicating embolization of arterial feeders. After the first embolization, the patient developed dysphagia, hiccup,

diplopia, alternating hypoesthesia and progressive impairment of cognition. Episodes of tonic-clonic- and partial complex seizures were first noted in August 2015. The patient's neurological status progressively worsened with impairment of speech fluency and bradypsychism. Left facial and right hemiparesia, left-sided retro-orbital pain with conjunctival chemosis, proptosis and distortion of the visual field were noted at physical examination.

The patient was re-admitted in March 2016 for stupor and optimization of antiepileptic drug (AED) treatment. Due to the progression of seizures, the patient was admitted in the ICU for third-line antiepileptic therapy (barbiturates) under mechanical ventilation. In April 2016, the brain MRI (not shown) revealed that the superior sagittal sinus (SSS) was patent in the 3/4 of its anterior part, but was thrombosed in its last segment, just before the torcular Herophili. In addition, the right transverse sinus (TS) was fully occluded. The diversion of the venous blood flow was achieved by a large left transverse sinus draining the SSS and by cortical collateral veins on both sides. These changes were confirmed by the phlebography obtained during cerebral angiography performed after MRI (Fig. 2). A second endovascular embolization was attempted to reduce the flow coming from branches of the right external carotid artery and from the middle meningeal artery. At the end of the procedure, the size of the fistula was reduced by 80–85%. However, during the contrast venous phase, a venous cortical congestion was noted in relationship with a tight stenosis at the junction of the sigmoid sinus and left jugular vein.

Further evolution in the ICU was characterized by status epilepticus that was refractory to all major antiepileptic drugs. After a new withdrawal of general anesthetics, the patient remained comatose and diffuse epileptic activity of the left hemisphere was still recorded at electroencephalogram. The last brain MRI performed in May 2016 revealed extensive and chronic white matter injury consistent with a demyelinating

✉ P. Hantson
philippe.hantson@uclouvain.be

¹ Department of Intensive Care, Cliniques St-Luc, Université catholique de Louvain, Avenue Hippocrate, 10, 1200 Brussels, Belgium

² Department of Neurology, CHR Namur, 5000 Namur, Belgium

³ Department of Neuroradiology, Cliniques St-Luc, Université catholique de Louvain, 1200 Brussels, Belgium

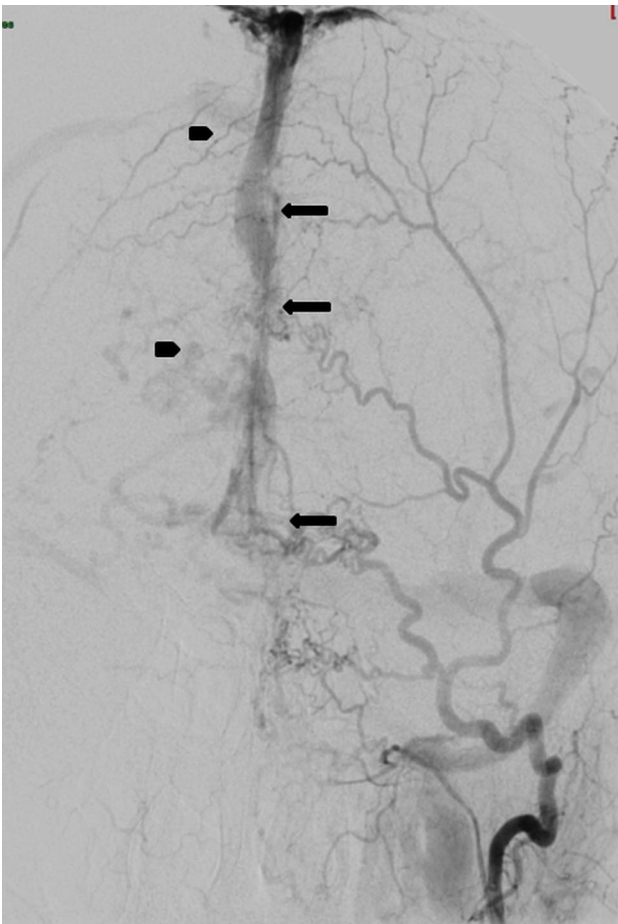


Fig. 1 Frontal view of left external carotid injection (January 2015) with multiple arteriovenous fistulous sites draining the superior sagittal sinus (arrows). The main arterial feeders arise from the posterior auricular and occipital arteries. Cortical veins engorgement and dilatation due to hyperpressure in the superior sagittal sinus (arrow heads)

process of ischemic origin (Fig. 3). In addition, the left transverse sinus appeared almost completely occluded (Fig. 4). On the control angiography performed 6 days before, there was also a progression of the impairment of the cervical venous drainage due to the occlusion of the right internal jugular vein and of the left innominate vein and confluence of subclavian vein and internal jugular.

The absence of neurological improvement together with the extensive white matter injuries at brain MRI led to the decision of intensive care discontinuation. Post-mortem examination could not be obtained.

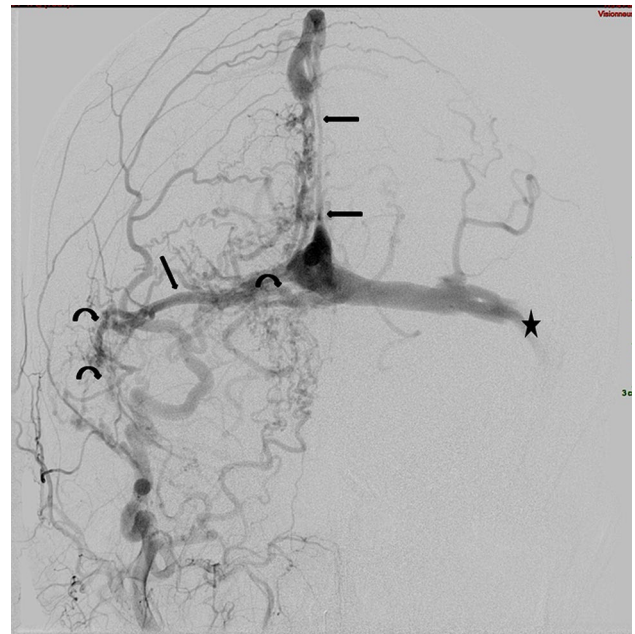


Fig. 2 Frontal view of the right external carotid artery injection (April 2016) with sub-occlusion of the right transverse, sagittal and sigmoid sinuses and tight stenosis of the distal part of the superior sagittal sinus (arrows). Development of multiple tiny collaterals (curved arrows). Note also a stenosis of the junction between the left transverse sinus and the left sagittal sinus inducing a venous stasis in the left transverse sinus (star)

Discussion

The signs and symptoms of dAVFs may vary greatly depending on the type, localization, size, progression, and direction of drainage [1]. Contrasting to previous descriptions dealing with anterior fossa or cavernous sinus dAVFs, this is, to our best knowledge, the first reported case of a dAVF in the occipital lobe presenting with exophthalmos, conjunctival chemosis and complex partial seizures [2]. Seizures and status epilepticus have been exceptionally reported after dAVFs [3]. Status epilepticus (SE) secondary to dAVFs was recently reported in three cases, including one case without concomitant cerebral venous sinus thrombosis (CVST) [4]. The presentations were characterized as generalized convulsive SE, complex partial SE, and non-convulsive SE. In two cases, SE was controlled by the combination of antiepileptic drugs (AED) and endovascular intervention. By contrast, the recurrence of SE was noted in one patient in association with residual dAVFs and re-stenosis of the venous sinus following the first endovascular treatment. In this patient, SE was effectively controlled after the completion of endovascular intervention. Seizures in patients with dAVFs are usually ascribed to venous hypertension caused either

Fig. 3 Brain MRI performed in May 2016 with T2/FLAIR sequences. Demonstration of extensive and chronic white matter injury likely of venous ischemic origin. The lesions extended to the dorsal corticospinal tract due to wallerian degeneration (black arrows). Note that the superior sagittal sinus appeared occluded (white arrow)

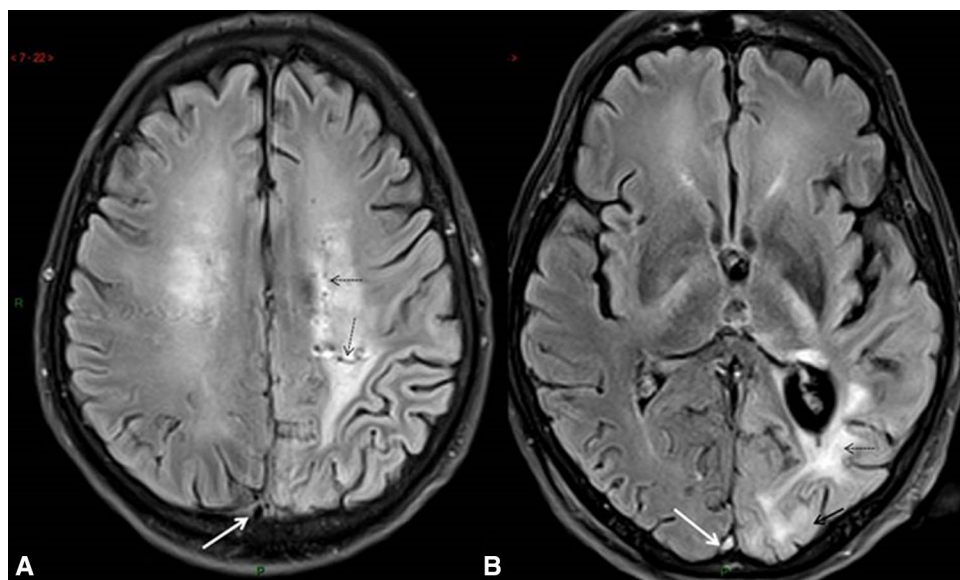
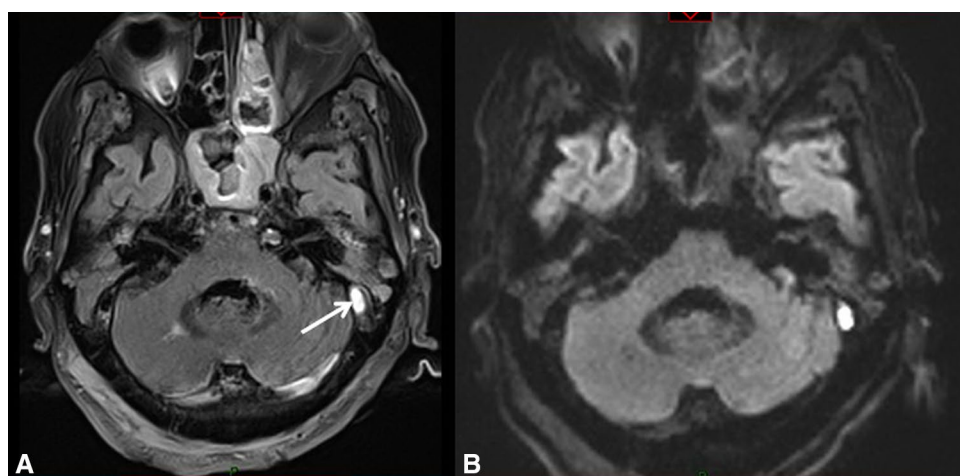


Fig. 4 Brain MRI with FLAIR (a) and DWI (b) sequences. Demonstration of an acute clot within the left transverse sinus (white arrow) with restriction of water diffusivity on DWI



by dAVFs or co-existing venous sinus outflow obstruction due to concomitant CVST or venous sinus stenosis. In the present case, clinical worsening occurred when a late occlusion of the left TS (demonstrated by MRI) was combined with a reduction of venous flow in the right TS in a patient who had already developed a thrombosis of the distal part of the SSS. The result was the development of new ischemic lesions in the left occipital lobe, due to the major impairment of cortical venous drainage. This illustrates the importance to control venous hypertension by stenting the narrowed or thrombosis sinus. In addition, venous hypertension of the deep cerebral veins may induce cerebral ischemia [5]. These changes may be diagnosed at MRI as diffuse white matter changes with dilated and tortuous cortical veins. Studies using positron emission tomography and single photon emission tomography have confirmed the venous ischemia caused by dAVFs. As in

our case, the patients with dAVFs are then presenting with progressive neurological signs including dementia [5]. Some reversibility of white matter changes together with improvement in clinical status may be observed after successful endovascular embolization.

In conclusion, endovascular intervention should always be considered to control or prevent seizures in dAVFs patients presenting with SE. However, the neurological prognosis seems also to be related to the development of white matter ischemia secondary to venous hypertension.

Compliance with ethical standards

Conflict of interest The authors declare that they have no conflict of interest.

Ethical approval This article does not contain research including human participants or animals performed by any of the authors.

Informed consent Informed consent was obtained from the relatives of patient included in the study.

References

1. Cognard C, Gobin YP, Pierot L, Bailly AL, Houdart E, Carasco A et al (1995) Cerebral dural arteriovenous fistulas: clinical and angiographic correlation with a revised classification of venous drainage. *Radiology* 194:671–680
2. Feyissa AM, Ponce LL, Patterson JT, Von Ritschl RH, Smith RG (2014) Dural arteriovenous fistula presenting with exophthalmos and seizures. *J Neurol Sci* 338:229–231
3. Rabinov JD, Yoo AJ, Ogilvy CS, Carter BS, Hirsch JA (2013) ONYX versus n-BCA for embolization of cranial dural arteriovenous fistulas. *J Neurointerv Surg* 5:306–310
4. Lee C-Y, Yeh S-J, Tsai L-K, Rang S-C, Jeng J-S (2015) Dural arteriovenous fistula presenting with status epilepticus treated successfully with endovascular intervention. *Acta Neurol Taiwan* 24:52–56
5. Zeidman SM, Monsein LH, Arosarena O, Aletich V, Biafore JA, Dawson RC, Debrun GM, Hurko O (1995) Reversibility of white matter changes and dementia after treatment of dural fistulas. *AJNR Am J Neuroradiol* 16:1080–1083