

Accepted Manuscript

CD59 deficiency presenting as polyneuropathy and Moyamoya syndrome with endothelial abnormalities of small brain vessels

Christian Klemann, Janbernd Kirschner, Sandra Ammann, Horst Urbach, Olaf Moske-Eick, Barbara Zieger, Myriam Ricarda Lorenz, Klaus Schwarz, Soroush Doostkam, Stephan Ehl, Rudolf Korinthenberg

PII: S1090-3798(17)30131-9

DOI: [10.1016/j.ejpn.2018.04.003](https://doi.org/10.1016/j.ejpn.2018.04.003)

Reference: YEJPN 2409

To appear in: *European Journal of Paediatric Neurology*


Received Date: 7 March 2017

Revised Date: 17 February 2018

Accepted Date: 4 April 2018

Please cite this article as: Klemann C, Kirschner J, Ammann S, Urbach H, Moske-Eick O, Zieger B, Lorenz MR, Schwarz K, Doostkam S, Ehl S, Korinthenberg R, CD59 deficiency presenting as polyneuropathy and Moyamoya syndrome with endothelial abnormalities of small brain vessels, *European Journal of Paediatric Neurology* (2018), doi: 10.1016/j.ejpn.2018.04.003.

This is a PDF file of an unedited manuscript that has been accepted for publication. As a service to our customers we are providing this early version of the manuscript. The manuscript will undergo copyediting, typesetting, and review of the resulting proof before it is published in its final form. Please note that during the production process errors may be discovered which could affect the content, and all legal disclaimers that apply to the journal pertain.



CD59 deficiency presenting as polyneuropathy and Moyamoya syndrome with endothelial abnormalities of small brain vessels.

Christian Klemann^{1,2,3}, Janbernd Kirschner^{2,4}, Sandra Ammann^{1,5}, Horst Urbach⁶,
Olaf Moske-Eick^{6,2}, Barbara Zieger², Myriam Ricarda Lorenz⁷, Klaus Schwarz^{7,8},
Soroush Doostkam⁹, Stephan Ehl^{1,2}, Rudolf Korinthenberg^{2,4}

¹Center for Chronic Immunodeficiency (CCI), Medical Center – University of Freiburg, Faculty of Medicine, University of Freiburg, Germany.

²Center for Pediatrics, Medical Center – University of Freiburg, Faculty of Medicine, University of Freiburg, Germany

³Department of Pediatric Pneumology, Allergy and Neonatology, Hannover Medical School, Hannover, Germany.

⁴Center for Pediatrics, Department of Neuropediatrics and Muscle Disorders, Medical Center – University of Freiburg, Faculty of Medicine, University of Freiburg, Germany

⁵Cambridge Institute for Medical Research, Cambridge Biomedical Campus, Cambridge, United Kingdom.

⁶Department of Neuroradiology, Medical Center – University of Freiburg, Faculty of Medicine, University of Freiburg, Germany

⁷Institute for Transfusion Medicine, University of Ulm, Ulm, Germany;

⁸Institute for Clinical Transfusion Medicine and Immunogenetics Ulm, German Red Cross Blood Service, Baden Württemberg – Hessen, Ulm, Germany

⁹Institut for Neuropathology, Medical Center – University of Freiburg, Faculty of Medicine, University of Freiburg, Germany

Corresponding author:

Dr. med. Christian Klemann,
Department of Pediatric Pneumology, Allergy and Neonatology,
Hannover Medical School, Hannover, Germany.

Email: Klemann.Christian@mh-hannover.de

Conflict of interests: none

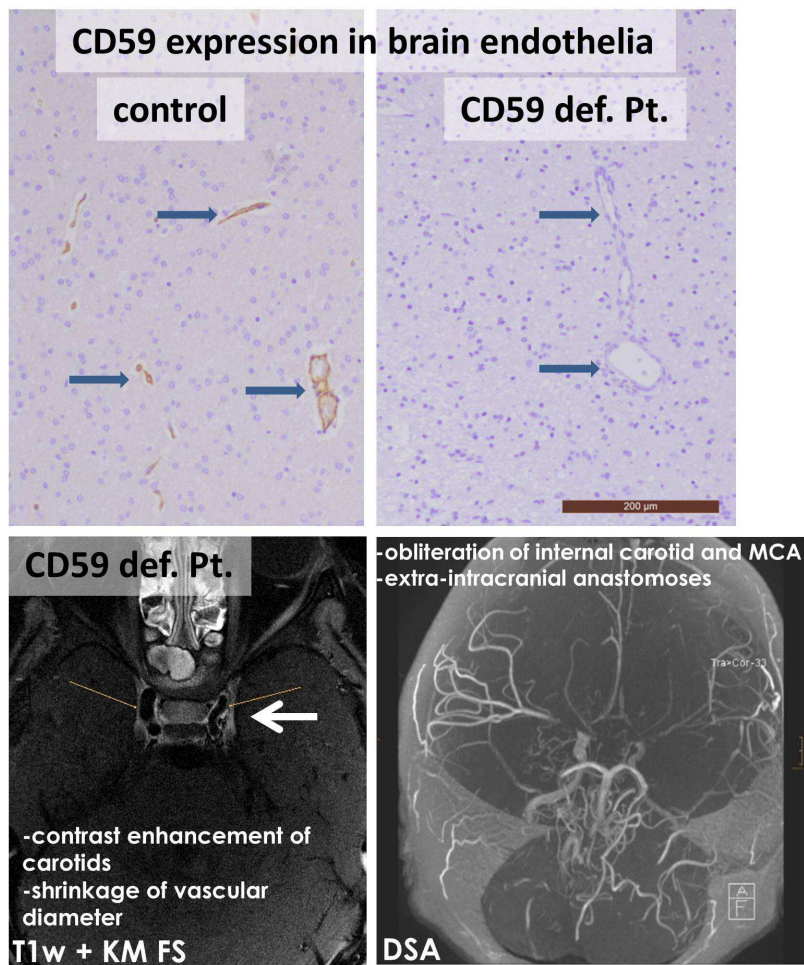
Key words: MMD, MMS; high resolution vessel wall imaging; HR-VWI; CIPD; GBS; pediatric stroke, early-onset stroke, hemolysis, hemolytic anemia

Highlights:

- Congenital isolated CD59 deficiency has previously been associated with recurrent episodes of hemolytic anemia, peripheral neuropathy, and strokes.
- In this 4th patient with the p.Asp49Valfs*31 mutation in CD59 reported, brain endothelium showed absent CD59 expression. Moyamoya syndrome developed with contrast enhancement of the distal carotid arteries and shrinkage of vascular diameter while systemic vasculitis could be excluded.
- Targeted therapy with eculizumab might have prevented the lethal course in our patient.

Abstract: (word count: 214)

CD59 is involved in lymphocyte signal transduction and regulates complement-mediated cell lysis by inhibiting the membrane attack complex. In the cases reported so far, congenital isolated CD59 deficiency was associated with recurrent episodes of hemolytic anemia, peripheral neuropathy, and strokes. Here, we report on a patient from a consanguineous Turkish family, who had a first episode of hemolytic anemia at one month of age and presented at 14 months with acute Guillain-Barré syndrome (GBS). The child suffered repeated infection-triggered relapses leading to the diagnosis of chronic inflammatory demyelinating polyneuropathy (CIDP). Although partly steroid-responsive, the polyneuropathy failed to be stabilized by a number of immunosuppressive agents. At the age of 6 years, he developed acute hemiparesis and showed progressive stenosis of proximal cerebral arteries, evolving into Moyamoya syndrome (MMS) with recurrent infarctions leading to death at 8 years of age. Post-mortem genetic analysis revealed a pathogenic p.Asp49Valfs*31 mutation in *CD59*. Re-analysis of brain biopsy specimens showed absent CD59 expression and severe endothelial damage. Whereas strokes are a known feature of CD59 deficiency, MMS has not previously been described in this condition. Therefore, we conclude that in MMS combined with hemolysis or neuropathy CD59 deficiency should be considered. Establishing the diagnosis and targeted therapy with eculizumab might have prevented the lethal course in our patient.

65 **Graphical abstract:**

66

67 CD59 deficiency presenting as polyneuropathy and Moyamoya syndrome with
68 endothelial abnormalities of small brain vessels.

Introduction:

The complement system is a complex family of proteins with a myriad of functions, including killing of target cells via the membrane attack complex (MAC). CD59 is the only protein inhibitor of the terminal pathway of the complement cascade preventing formation of the MAC [1]. Somatic mutations in the protein anchoring CD59 and related proteins on the cell surface of erythrocytes result in paroxysmal nocturnal hemoglobinuria presenting with recurrent hemolysis. However, deleterious autosomal recessive germline mutations in CD59 have recently been described to cause severe early-onset immune-mediated chronic neuropathy, chronic or relapsing Coombs-negative hemolysis, and cerebrovascular events [2–7]. These observations, summarized in table 1, are based on the 12 hitherto reported patients.

Moyamoya disease (MMD) is a rare, chronic, occlusive cerebrovasculopathy and a known cause of pediatric stroke. The pathogenesis and etiology is largely unknown despite devastating, permanent neurological disability if left untreated. MMD is characterized by progressive stenosis of the intracranial internal carotid arteries and their main branches and the development of compensatory collateral vessels at the base of the brain vascularizing the hypoperfused brain distal to the occluded vessels. Sometimes, similar clinical and radiologic signs are evident in children with other medical conditions then termed Moyamoya syndrome (MMS). In this report, we extend the clinical phenotype of CD59 deficiency to angiographic features of cerebral vasculopathy progressing to MMS.

Materials & methods:

Informed consent for retrospective collection of patient history and clinical data as well as for genetic analyses was obtained from the patient and his family members in accordance with local ethics committee guidelines.

Biopsy material from frontal left dura and cortex was investigated by histology and immunohistochemistry. After formalin fixation, conventional staining for H&E, EvG and PAS were performed from the paraffin-embedded biopsy material. Antibodies directed towards CD59 (BioScience, 7BIO-1B-233-C100), CD34 (Dako, M 7165) and CD61 (Dako, M 0753) were used for immunohistochemistry.

For sequencing of CD59, 100 ng genomic DNA or cDNA corresponding to 25 ng total RNA of PBMC was amplified, followed by sequencing using Big Dye Terminator v1.1 Cycle Sequencing Kit (Applied Biosystems, Darmstadt, Germany). Sequencing products were separated on an Applied Biosystems 3130xl Genetic Analyzer. Primer sequences are available upon request from K.S. Multiple sequence alignments were performed at <http://www.ncbi.nlm.nih.gov/>. Databases for analyzing the frequency of the variation used were SNPbase (<http://www.ncbi.nlm.nih.gov/snp>), 1000 Genome-Database (http://browser.1000genomes.org/Homo_sapiens/Info/Index), EVS-Database (<http://evs.gs.washington.edu>), Kaviar-Database (<http://db.systemsbiology.net/kaviar/>), and ExAC-Database (<http://exac.broadinstitute.org/>).

Results:

Our patient was born as the first son of healthy consanguineous Turkish parents (**fig. 1A**). No relationship to previously reported Turkish patients could be established. Pregnancy was uneventful; birth was complicated by meconium aspiration and sepsis requiring antibiotic treatment. The patient presented at the age of 1 month with an episode of hemolysis (minimal hemoglobin 7.0 g/dl) prompting an erythrocyte transfusion. LDH was increased while direct and indirect Coombs tests were negative. Osmotic testing of erythrocytes, Hb-electrophoresis and G6PDH were normal. In the year thereafter no new episodes of hemolysis occurred and neuro-cognitive and motor development were normal.

After the development of the independent walking capability, at the age of 14 months the boy fell ill with apathy, areflexia and progressive tetraparesis including loss of control of head position and dysphagia after a mild gastroenteritis. PCR for Coxsackie A2 virus in stool was positive and again Coombs-negative hemolytic anemia became apparent. Guillain-Barré syndrome (GBS) was diagnosed and the condition improved markedly under a high dose of immunoglobins i.v. (IVIG). No nerve conduction studies were performed during this episode. A broad metabolic workup was negative. At the age of 17 months a relapse of the neurological symptoms was again treated successfully with IVIG.

At the age of 27 months a severe relapse of GBS unresponsive to IVIG prompted referral to our department of child neurology. CSF analysis was acellular with an increased protein level (164 mg/dl, normal value 15 - 40 mg/dl) without signs of local IgG synthesis. Similar results were found in repeated CSF investigations in the following years. Nerve conduction studies in three nerves showed severe slowing of conduction velocity (15-19 m/sec), dispersed motor action potentials with diminished amplitude (0.4-0.5 mV), and a conduction block proving primary demyelination with secondary axonal injury. This gave rise to a diagnosis of chronic inflammatory demyelinating polyneuropathy (CIDP) and intravenous treatment with steroids was initiated rapidly improving the clinical condition. Under continued treatment with oral steroids the clinical course was initially satisfying without any signs of hemolysis and positive neurocognitive and motor development (standing and walking few steps with aids). Tendon reflexes remained absent throughout the further clinical course. Nine months later, again following a febrile infection CIDP and hemolysis relapsed prompting increasing the steroid dose and additional treatment with azathioprine. In the following years the clinical course was characterized by numerous infection-associated relapses of CIDP which responded well to pulsed treatment with corticosteroids, but immunoglobulins were without lasting effect. Only after introduction of mycophenolate-mofetil the neuropathy stabilized with a gradual increase of the unaided walking distance from 50 to 500 meters.

Unexpectedly, at the age of 6 years the boy suffered an acute stroke with right-sided dysesthesia and paresis. MRI showed multiple left-sided thromboembolic and/or hemodynamic infarctions. With TOF-MRA on the left side severe stenosis involving the carotid-T and the proximal M1 and A1-segments and signs of a fine collateral network, and on the right side a distinct but less pronounced stenosis of the M1 origin was found (**fig. 2A-C**). At follow-up 18 months later, progression of both left- and right-sided stenoses, and on high-resolution Vessel-Wall Imaging (HR-VWI) diffuse and circular enhancement of arterial walls affecting the distal ICA and proximal M1- and A1-segments with shrinkage of the vessel diameter were shown (**fig. 2D-E**). Systemic vasculitis diseases were excluded by whole body MRI, PET scan, and repeated blood works including repeatedly normal von Willebrand factor antigen and activity, factor VIII activity and normal D-Dimers (in episodes of absent hemolysis). A combined meningeal and brain biopsy did not confirm an inflammatory process but showed a severely damaged intima of blood vessels, as indicated by a loss of the

endothelial marker CD34, (**fig. 3A**) and an aggregation of platelets shown by the immunoreactivity for the platelet marker CD61 (**fig. 3B**). Rituximab along with steroids, antithrombotic treatment and MMF initially seemed to stabilize the vasculopathy, but during the following year the arterial stenoses showed further progression despite additional aggressive treatment with cyclophosphamide. Eventually this progression resulted in the occlusion of most large cerebral arteries but only a faint basal collateral network. Under the diagnosis of MMS and due to repeated TIAs and minor strokes burr-hole trepanations and synangiostoses were performed resulting in a clear cortical collateral network (**fig. 2F**). However, despite these measures and maximal care the boy died at the age of 8 years due to multiple malignant cerebral infarctions (**fig. 2G**).

Genetic analyses investigating known genes predisposing for Moya-Moya disease proofed normal. Years later, following recently published reports of chronic neuropathy, hemolysis and recurrent brain ischemic infarctions in pediatric patients due to a germline CD59 deficiency, a post-mortem genetic investigation revealed a previously reported homozygous point mutation at c.146delA (hg19, NM_203330) on Exon 5 of CD59 (**fig. 1B**). This deletion leads to a frameshift at position 49 (p.Asp49Valfs*31) with a premature stop. The variation was not listed in SNPbase, 1000 Genome-Database, EVS-Database, Kaviar-Database, and ExAC-Database. Both parents and the sister were heterozygous for the mutation.

Educated by the genetic analysis, a reanalysis of the brain and dural biopsies showed subacute cerebral infarction with macrophages and capillary proliferation. Several cerebral and meningeal blood vessels showed severe endothelial damage with platelet aggregation both inside and outside the infarcted areas. Immunohistochemically analysis of brain tissue for CD59 expression showed a complete absence of CD59 staining when compared to a healthy control (**fig. 3 C&D**).

Discussion

CD59 (also known as MAC-inhibitory protein, membrane inhibitor of reactive lysis, or protectin) is a complement regulatory protein linked to the cell surface by a GPI-anchor protein [1]. Somatic mutations in hematopoietic stem cells affecting the GPI anchor of several proteins reduce, amongst other proteins, the expression of CD59 leading to paroxysmal nocturnal hemoglobinuria (PNH) [8]. PNH is characterized by Coombs-negative hemolytic anemia due to the lack of inhibition of the complement cascade [8]. About half of all PNH patients additionally suffer of thrombosis, including cerebral venous thrombosis in about 4 % of patients [8]. Anecdotal reports have described that besides acquired mutations in GPI-anchors - and thus secondary lack of CD59 – germline mutations in *CD59* can cause PNH [2,3]. In contrast to PNH, germline CD59 mutations affect all cells of the body and thus the more severe phenotype is comprehensible. Recent reports of inherited CD59 deficiency leading to early-onset CIDP, coombs negative hemolytic anemia, and strokes led us to reanalyze post mortally the case of a boy of Turkish descent with similar presentation. We identified the 4th patient reported with a homozygous p.Asp49Valfs*31 mutation (**fig. 1**) in addition to the 8 reported patients with other mutations in *CD59* (**tbl. 1**). Of note, no relationship to the other affected Turkish patients could be established over the past 4 generations, albeit this does not contradict the presence of a founder mutation in the Turkish population.

Although at first sight the combination of hemolytic anemia, recurrent polyneuropathy and cerebrovascular disease sounds quite uniform in all reported patients with congenital CD59 deficiency, at a closer look there are some remarkable differences even between patients with the same mutation that are probably due to variable pathophysiological pathways depending on the genetic background or on exogenous influences. With the exception of the first reported Japanese case all patients suffered from usually very early onset, severe, chronic, relapsing-remitting polyneuropathy that in some of them lead to severe disability and even death (**tbl.1**). In our patient as well as in the cases reported by Nevo et al., Ben-Zeev et al., and Höchsmann et al. electrophysiological criteria showed that the neuropathy was clearly of the classical demyelinating CIDP type with secondary axonal damage, whereas the cases of Haliloglu et al. suffered from primary axonal neuropathy (in one case with secondary demyelination) [4–7]. We conclude that CD59 deficiency can

lead to a primary insult either at the Schwann cell or to the axon itself. Pathophysiologically, CD59 deficiency might increase the vulnerability of spinal roots and peripheral nerves due to diminished protection from the MAC; a previous *in vitro* study demonstrated protection from complement-mediated lysis of neurons when CD59 expression was increased [9]. Alternatively, autoimmunity could be causative, as experimental investigations in mice lacking CD59 have shown an increased susceptibility for autoimmune-phenomena [10]. Clinically, the occurrence of CIDP or chronic axonal neuropathy already in infancy is extremely rare so in such cases CD59 deficiency should be considered as being disease causing.

Not all cases with CD59 deficiency reported in the literature have suffered strokes (**tbl. 1**). The affected children might have been too young at the age of reporting, but this seems improbable for the 13 to 55 years old cases in the North African Jewish families of Nevo et al [4]. If reported the strokes have usually been diagnosed by MRI showing supra- or infratentorial infarctions due to assumed thrombo-embolic events in the anterior or posterior cerebral circulation (**tbl. 1**). In one case hemorrhagic stroke due to an occlusion of the PICA (posterior inferior cerebellar artery) has been demonstrated by MR-angiography [7]. In contrast, serial MRI, TOF-MRA, HR-VWI and DSA show relentless progression of stenoses of the proximal cerebral arteries at the Circulus of Willisii in our patient and thus MMS was diagnosed (**fig. 2**). Moyamoya (meaning a "hazy puff of smoke" in Japanese) is the term for a radiologic finding of progressive intracranial vascular stenoses of the distal internal carotid arteries and the proximal medial, anterior and less frequently posterior cerebral arteries associated with enlarged collateral supply via the lenticulostriate and thalamoperforating arteries and in later stages leptomeningeal and transdural arteries [11–13]. Strokes and epileptic seizures constitute the prevailing presentation in childhood [12]. The etiology of Moyamoya is multifactorial and largely unknown. 'Idiopathic Moyamoya disease' (MMD) is considered to be an entity to be separated from secondary occurrences termed 'Moyamoya syndrome' (MMS). In far-eastern countries the largest part of idiopathic cases is caused by a single mutation in the *RNF213* gene. Other hereditary factors comprise mutations in *ACTA2*, *TIMP2*, *GUCY A3*, *COL4A1* or *MOPD2*. MMS is associated with Trisomy 21, Neurofibromatosis type 1, Alagille syndrome, radiotherapy, cerebrovascular atherosclerosis, cerebral vasculitis and others [12, 13]. A single case of MMS has

been reported in the context of PNH, but whether pro-inflammatory or pro-thrombotic mechanism were causative remained elusive [14].

Histologically, MMD and MMS are characterized by focally thickened vascular intima due to proliferation of endothelial and smooth muscle cells, loss of muscle cells of the media, and dilated or irregular-shaped vessel lumen [11–13]. Novel neuroradiological techniques allow to consider not only the vessel lumen but also the vessel wall [15,16]. However, the role of contrast-enhancement of the arterial wall in MMS is not uniformly agreed on. With high resolution vessel wall imaging (HR-VWI) Ryoo et al. found diffuse and circular enhancement in the arterial walls of the stenotic segments in 90% of 32 MMD cases, whereas Kim et al. observed focal enhancement in only 2 of 7 cases [17,18]. Diffuse contrast enhancement associated with swelling of the arterial wall is the radiological hallmark of acute vasculitis, as opposed to cerebrovascular atherosclerosis which is characterized by focal and eccentric deposition of plaques, hemorrhage and contrast enhancement [16]. Contrast enhancement in cases of MMS could be an unspecific sign of an inflammatory pathophysiology, and following recent reviews only the lack of swelling of the whole vascular wall with increase of the vascular diameter could be an argument to differentiate MMS from acute vasculitis [19–21]. It should be emphasized that development of collaterals is not pathognomonic for idiopathic MMD and could also represent MMS due to an unspecific reaction of the stenosis of the proximal intracerebral arteries in progressive large vessel CNS vasculitis. In our patient however, systemic vasculitis work-up was negative, including repeatedly normal serum markers and lack of inflammatory changes in the brain- and meningeal biopsy. In line with these findings, aggressive immunosuppressant treatment failed to control the disease. Antiplatelet therapy may have extended the time without thromboembolic events, but finally failed also to prevent the recurrent infarction in the final stage of the disease because of progressive stenosis of the cerebral arteries. Eventually, these investigations as well as the clinical and neuroradiological course led to the diagnosis of MMS, which is now post-mortemally explained by CD59 deficiency

Concerning a possible pro-thrombotic component, intravascular hemolysis resulting in depletion of nitric oxygen might have activated the platelets and endothelium [1]. However, the neuroradiological and haemostaseological investigations were not

compatible with local thrombotic disease which would be the hallmark in PNH. MMS is known to be associated with intimal and endothelial dysfunction [13]. In CD59 deficiency chronic or acute hemolysis might trigger leukocyte- and endothelial dysfunction promoting an inflammatory component in the vasculopathy which could give rise to the observed contrast enhancement of vessel walls. Furthermore, it seems possible that the cerebral events are a direct consequence of the lack of CD59 on the cerebral endothelium making it vulnerable to disruption by the complement system (fig. 3).

Recognizing the combination of early onset hemolysis, CIDP and stroke would have prompted further diagnostics including PNH flow cytometry. With this, lack of CD59 expression while other GPI-anchored proteins are normally present would have enabled a timely diagnosis [7]. Therapeutically, targeted complement inhibition with the anti-C5 monoclonal antibody eculizumab appears to be a promising treatment option also for CD59 deficiency [6,7].

In summary, this case expands the clinical spectrum of autosomal-recessive CD59 deficiency syndrome to radiologic findings of MMS. We conclude, that our case emphasizes the need for early diagnosis of CD59 deficiency in young children with hemolysis and chronic neuropathy as treatment with eculizumab could positively influence the clinical course.

Acknowledgements

The authors would like to thank the patient's family as well as all physicians involved. We thank Dr. Christian Schulz-Huotari, Institute for Transfusion Medicine, University of Freiburg and Dr. Christof Weinstock, Institute for Transfusion Medicine, University of Ulm, Germany for helpful discussion. We are grateful to the other team members of the Center for Pediatrics and CCI Advanced Diagnostic Unit for their excellent work. This study was supported by the German Federal Ministry of Education and Research (BMBF01EO1303). The authors declare no conflicting interests.

References:

- [1] Höchsmann B, Schrezenmeier H. Congenital CD59 Deficiency. *Hematol Oncol Clin North Am* 2015;29:495–507. doi:10.1016/j.hoc.2015.01.006.
- [2] Motoyama N, Okadan N, Yamashinam M, Okada H, Yamashina M, Okada N, et al. Paroxysmal nocturnal hemoglobinuria due to hereditary nucleotide deletion in the HRF20 (CD59) gene. *Eur J Immunol* 1992;22:2669–73. doi:10.1002/eji.1830221029.
- [3] Yamashina M, Ueda E, Kinoshita T, Takami T, Ojima A, Ono H, et al. Inherited complete deficiency of 20-kilodalton homologous restriction factor (CD59) as a cause of paroxysmal nocturnal hemoglobinuria. *N Engl J Med* 1990;323:1184–9. doi:10.1056/NEJM199010253231707.
- [4] Nevo Y, Ben-Zeev B, Tabib A, Straussberg R, Anikster Y, Shorer Z, et al. CD59 deficiency is associated with chronic hemolysis and childhood relapsing immune-mediated polyneuropathy. *Blood* 2013;121:129–35. doi:10.1182/blood-2012-07-441857.
- [5] Ben-Zeev B, Tabib A, Nissenkorn A, Garti B-Z, Gomori JM, Nass D, et al. Devastating recurrent brain ischemic infarctions and retinal disease in pediatric patients with CD59 deficiency. *Eur J Paediatr Neurol* 2015;19:688–93. doi:10.1016/j.ejpn.2015.07.001.
- [6] Höchsmann B, Dohna-Schwake C, Kyrieleis H a, Pannicke U, Schrezenmeier H. Targeted therapy with eculizumab for inherited CD59 deficiency. *N Engl J Med* 2014;370:90–2. doi:10.1056/NEJMc1308104.
- [7] Haliloglu G, Maluenda JJJ, Sayinbatur B, Aumont C, Temucin C, Tavit B, et al. Early-onset chronic axonal neuropathy, strokes, and hemolysis: Inherited CD59 deficiency. *Neurology* 2015;84:1220–4. doi:10.1212/WNL.0000000000001391.
- [8] DeZern AE, Brodsky RA. Paroxysmal nocturnal hemoglobinuria: a complement-mediated hemolytic anemia. *Hematol Oncol Clin North Am* 2015;29:479–94. doi:10.1016/j.hoc.2015.01.005.
- [9] Kolev M V, Tediose T, Sivasankar B, Harris CL, Thome J, Morgan BP, et al. Upregulating CD59: a new strategy for protection of neurons from complement-mediated degeneration. *Pharmacogenomics J* 2010;10:12–9. doi:10.1038/tpj.2009.52.

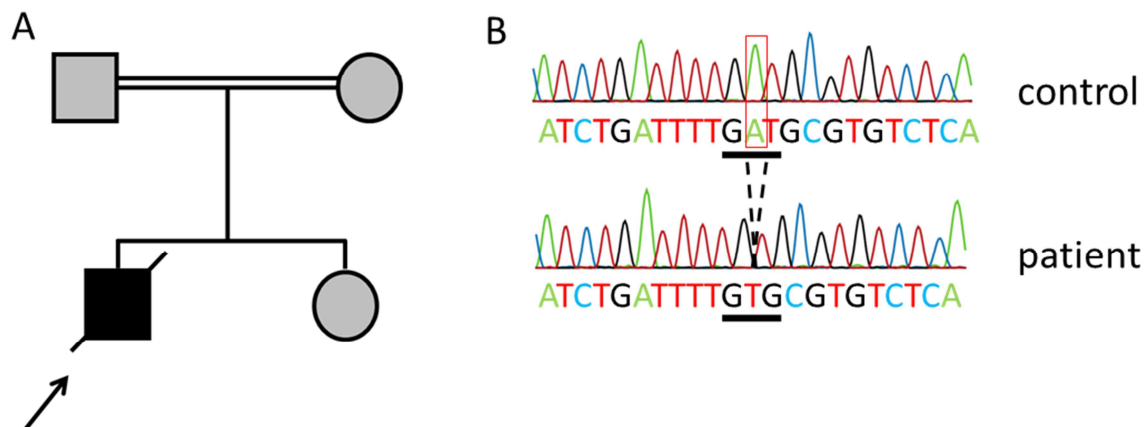
- [10] Miwa T, Zhou L, Maldonado MA, Madaio MP, Eisenberg RA, Song W-C. Absence of CD59 exacerbates systemic autoimmunity in MRL/lpr mice. *J Immunol* 2012;189:5434–41. doi:10.4049/jimmunol.1201621.
- [11] Kim T, Oh CW, Bang JS, Kim JE, Cho W-S. Moyamoya Disease: Treatment and Outcomes. *J Stroke* 2016;18:21–30. doi:10.5853/jos.2015.01739.
- [12] Kim JS. Moyamoya Disease: Epidemiology, Clinical Features, and Diagnosis. *J Stroke* 2016;18:2–11. doi:10.5853/jos.2015.01627.
- [13] Bang OY, Fujimura M, Kim S-K. The Pathophysiology of Moyamoya Disease: An Update. *J Stroke* 2016;18:12–20. doi:10.5853/jos.2015.01760.
- [14] Lin HC, Chen RL, Wang PJ. Paroxysmal nocturnal hemoglobinuria presenting as moyamoya syndrome. *Brain Dev* 18:157–9.
- [15] Kaku Y, Morioka M, Ohmori Y, Kawano T, Kai Y, Fukuoka H, et al. Outer-diameter narrowing of the internal carotid and middle cerebral arteries in moyamoya disease detected on 3D constructive interference in steady-state MR image: Is arterial constrictive remodeling a major pathogenesis? *Acta Neurochir (Wien)* 2012. doi:10.1007/s00701-012-1472-4.
- [16] Yuan M, Liu Z qiang, Wang Z qiang, Li B, Xu L jun, Xiao X lan. High-resolution MR imaging of the arterial wall in moyamoya disease. *Neurosci Lett* 2015. doi:10.1016/j.neulet.2014.10.021.
- [17] Ryoo S, Cha J, Kim SJ, Choi JW, Ki CS, Kim KH, et al. High-resolution magnetic resonance wall imaging findings of moyamoya disease. *Stroke* 2014;45:2457–60. doi:10.1161/STROKEAHA.114.004761.
- [18] Kim YJ, Lee DH, Kwon JY, Kang DW, Suh DC, Kim JS, et al. High resolution MRI difference between moyamoya disease and intracranial atherosclerosis. *Eur J Neurol* 2013. doi:10.1111/ene.12202.
- [19] Küker W, Gaertner S, Nügele T, Dopfer C, Schüning M, Fiehler J, et al. Vessel Wall Contrast Enhancement: A Diagnostic Sign of Cerebral Vasculitis. *Cerebrovasc Dis* 2008;26:23–9. doi:10.1159/000135649.
- [20] Alexander MD, Yuan C, Rutman A, Tirschwell DL, Palagallo G, Gandhi D, et al. High-resolution intracranial vessel wall imaging: imaging beyond the lumen. *J Neurol Neurosurg Psychiatry* 2016;87:589–97. doi:10.1136/jnnp-2015-312020.
- [21] Choi YJ, Jung SC, Lee DH. Vessel Wall Imaging of the Intracranial and

386 Cervical Carotid Arteries. J Stroke 2015;17:238–55.
387 doi:10.5853/jos.2015.17.3.238.

388

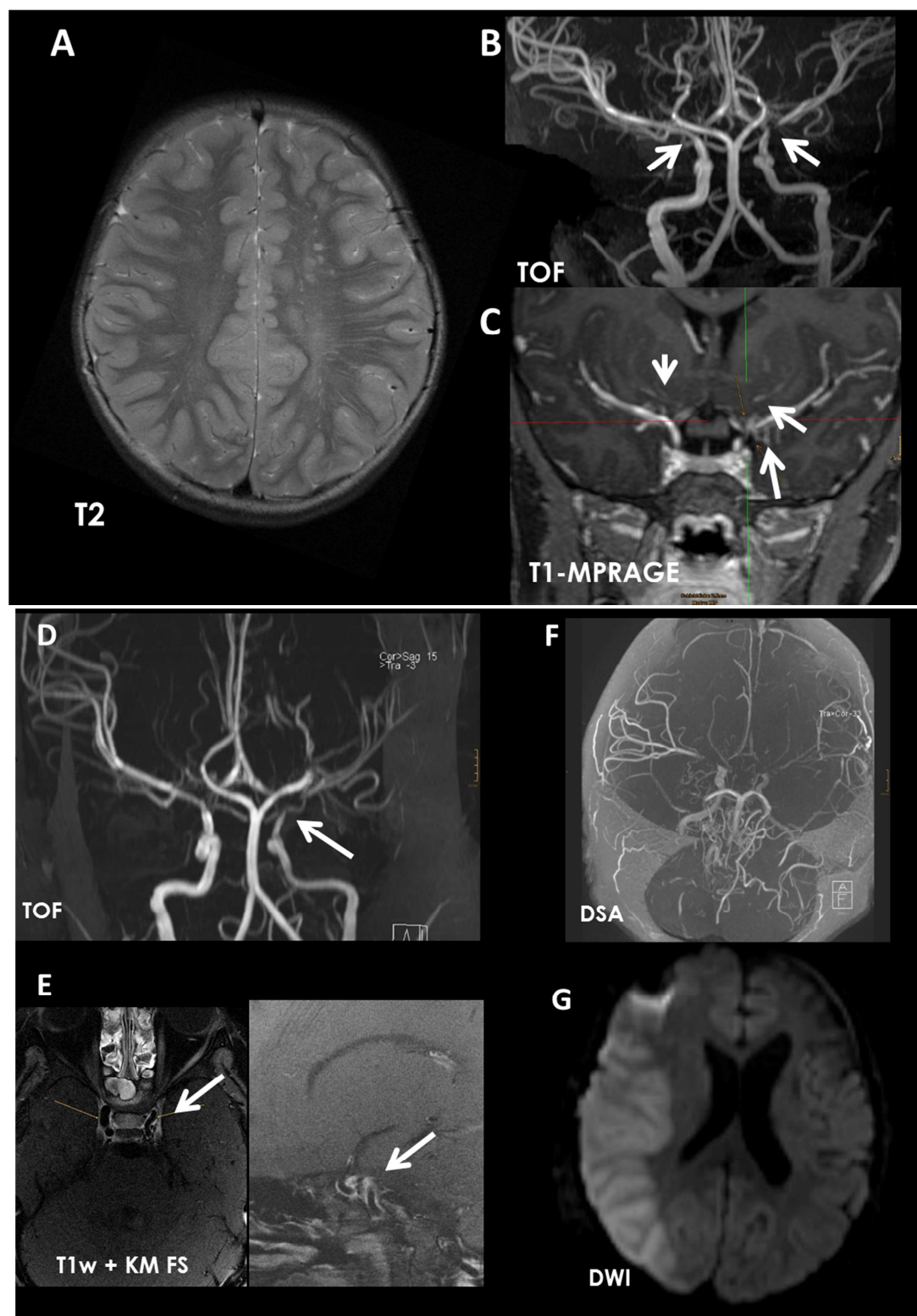
389

ACCEPTED MANUSCRIPT

Figures:**Figure 1**

A) Pedigree of the family with CD59 deficiency: The index patient (arrow) was homozygous (black) for a frameshift mutation in CD59. His sister and parents proved to be heterozygous (grey).

B) CD59 p.Asp49Valfs*31 mutation: Forward genomic DNA sequence of a control and the index patient. The homozygous deletion of A introduces a shift of the open reading frame.

Figure 2**Legend Figure 2:**

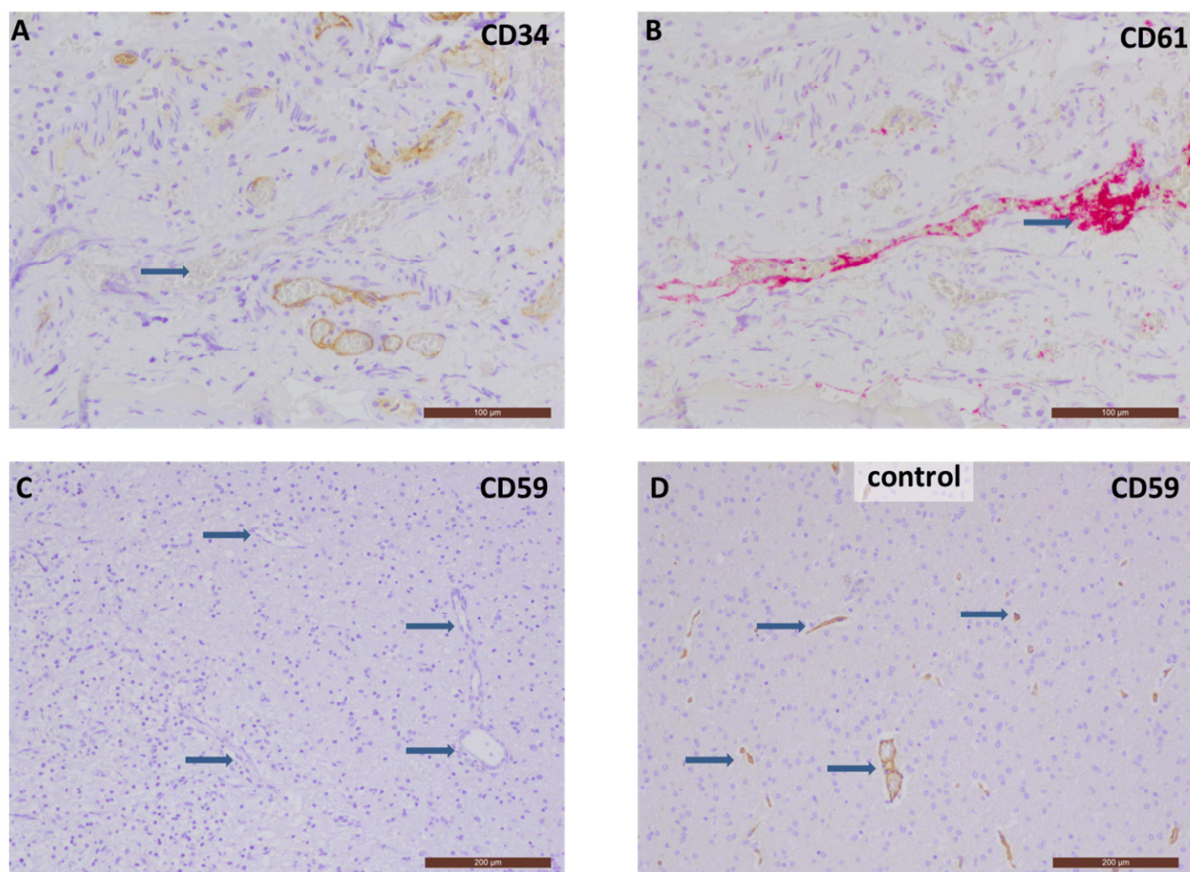
A-C) MR imaging at age of 6 yrs.: A) An axial T2-weighted image shows multiple lesions in the left centrum semiovale. B) 3D-TOF-MRA shows severe stenosis of the

carotid-T on the left and moderate stenosis on the right side. C) The arrows in C point to enlarged lenticulostriate arteries indicating the Moyamoya pattern

D-E) MR imaging at age of 7 yrs.: D) 3D TOF-MRA shows progressive stenosis on both sides. E) 3Tesla vessel wall imaging shows distinct diffuse contrast enhancement of the distal carotid arteries with shrinkage of vascular diameter.

F-G) MRI imaging at age of 8 yrs. 1 month: F) 3D TOF show complete obliteration of the distal internal carotid and proximal MCA on both sides and extra-intracranial anastomoses after multiple synangiosis operations. G) DWI-MRT shows severe atrophy on the left after repeated infarctions and a recent complete media infarction on the right.

Figure 3



Legend Figure 3:

Serial sections were stained immunohistochemically for CD34 and CD61.

(A) Blood vessels with endothelial damage (arrow) show a lack of immunoreactivity of CD34.

(B) Detection of platelet aggregates within the same vessel in the CD61 reaction.

(C) The brain biopsy tissue shows a complete lack of CD59 (arrows) compared to a healthy control (D).

Table 1:

Report	Yamashina 1990, Motoyama 1992 [2,3]	Nevo 2013 [4]	Ben-Zeev 2015 [5]	Höchsmann 2014 [6]	Haliloglu 2015 [7]	Current report
Patient #	1	2-6	11/12	7	8-10	13
Ethnic Origin	Japanese	North African Jewish, 4 families	North African Jewish, 1 family	Turkish	Turkish, 1 family	Turkish
Consanguinity	yes	1/5 yes	no	yes	yes	Yes
Mutation	compound heterozygous p.Val42Serfs*38; p.Ala121Glnfs	homozygous c.266 G>A p.Cys89Tyr	homozygous c.266 G>A p.Cys89Tyr	homozygous c.146delA, p.Asp49Valfs*31	homozygous c.146delA, p.Asp49Valfs*31	homozygous c.146delA, p.Asp49Valfs*31
Onset of disease	13 yrs	3-7 mo	3-5 mo	7 mo	6-11 mo	1 mo
Hemolysis	yes, chronic and acute	Yes	yes	yes	no/ yes, chronic/yes acute & chronic	yes, chronic and acute
Coombs test	not reported	not reported	not reported	not reported	negative	intermittently positive
Peripheral neurological disease	none reported	Motor-sensory, recurrent, 4/5 demyelinated secondary axonal (CIPD), 1/5 primary axonal, sMRT dorsal root enhancement 2/3	recurrent peripheral demyelinating neuropathy with conduction block (CIPD)	Demyelinating neuropathy with secondary axonal damage	3/3 primary recurrent axonal polyneuropathy, 1/3 secondary demyelination in later course, 2/3 gadolinium enhancement of dorsal roots	Recurrent-remitting, steroid-responsive demyelinated with conduction block
Central neurological disease	cerebral infarction	None reported	Recurrent cerebral infarctions from age 18 mo and 5 y, retinal and optic nerve involvement	Possible brainstem infarction versus encephalitis (MRI) at age 18 mo	1/3 supratentorial stroke at age 5y; 1/3 infratentorial hemorrhagic stroke and occlusion of PICA at age 18 mo; 1/3 no stroke up to age 4.5 y	Recurrent supratentorial infarctions from age 6 y, small vessel endothelial damage, large vessel enhancement, moyamoya
Others:		1/5 HUS like disease w/ renal failure	atypical glomerulo-nephritis, necrotic fingers		2/3 phototherapy as newborn necessary	
Treatment	not reported	IVIg, plasmapheresis, steroids, rituximab, cyclosporin	IVIg, steroids	IVIg, plasmapheresis, eculizumab	not reported/IVIg/IVIg & eculizumab	IVIg, steroids, azathioprin, MMF, rituximab, cyclophosphamid
Outcome	n/a	4 alive ~5 yrs of age, 1 deceased at 3.5 yrs.	deceased at age of 8 and 2.5 yrs.	5 yrs, improvement under eculizumab therapy	deceased at age 16 /alive ~10 yrs with mild cognitive impairment /alive ~5 yrs with global developmental delay	Deceased at age 8 years

Table legend:

Table 1: Summary of reported patients with CD59 deficiency.