

# Usefulness of F-18 FP-CIT PET to predict dopamine-responsive hand tremor in patients other than Parkinson's disease

## Two case reports

Kwang Jae Yu, MD<sup>a</sup>, Byung Joo Lee, MD<sup>b</sup>, Jin Han, BS<sup>c</sup>, Donghwi Park, MD<sup>a,c,\*</sup>

### Abstract

**Rationale:** Treating the patients with hand tremors is clinically difficult, because a wide range of disorders can result in hand tremors. Therefore, when treatment for hand tremors begins, various pharmacological options have to be considered. In clinical practice, a practical approach is to initially check hand tremor patients for signs of Parkinson's disease (PD), because patients with PD can benefit from dopamine treatment. However, only part of patients with PD tends to show a meaningful improvement in hand tremors for dopamine treatment. On the other hand, dopamine treatment may help with hand tremors of patients with other disorders, but dopamine responsiveness can't be predicted by clinical assessment alone.

**Patients concerns:** Hand tremors.

**Diagnoses:** Hemiplegic patients (A 78-year-old man with cerebral infarction and a 65-year-old woman with traumatic brain injury) with hemi-sided hand tremor.

**Interventions:** Fluorinated N-3-fluoropropyl-2β-carbomethoxy-3β-(4-iodophenyl) nortropane (F-18 FP-CIT) positron emission tomography (PET) and dopamine agonist.

**Outcomes:** After the medication, hemi-side hand tremor dramatically improved.

**Lessons:** Collectively, a dysfunction of the dopaminergic nigro-striatal pathway may lead to abnormal findings of F-18 FP-CIT PET, and these abnormal findings in brain-lesion patients with hand tremor may help predict dopamine responsiveness of hand tremor. We believe that our report may be helpful in the diagnosis and treatment of hand tremor in patients with brain-lesion.

**Abbreviations:** ACA = anterior cerebral artery, DaT = dopamine transporter, F-18 FP-CIT = fluorinated N-3-fluoropropyl-2β-carbomethoxy-3β-(4-iodophenyl) nortropane, IPD = idiopathic Parkinson's disease, MCA = middle cerebral artery, MRI = magnetic resonance image, PET = positron emission tomography, SDH = subdural hemorrhage, SMA = striatum-supplementary motor area.

**Keywords:** dopamine, dopamine agonist, F-18 FP-CIT, Parkinsonism, PET, pramipexole, tremor

## 1. Introduction

Treating the patients with hand tremors is clinically difficult, because a wide range of disorders can result in hand tremors.<sup>[1,2]</sup>

Editor: N/A.

KJY and BJL equally contributed to this paper and should therefore be regarded as equivalent first authors.

This research was supported by Basic Science Research Program through the National Research Foundation of Korea (NRF) funded by the Ministry of Science, ICT, and Future Planning (NRF-2017R1D1A1B03033127).

The authors have no conflicts of interest to disclose.

Supplemental Digital Content is available for this article.

<sup>a</sup> Department of Rehabilitation medicine, Daegu Fatima Hospital, Daegu,

<sup>b</sup> Department of Rehabilitation medicine, Asan Medical Center, University of Ulsan College of Medicine, Seoul, <sup>c</sup> Department of Pharmacology, Kyungpook National University School of Medicine, Daegu, South Korea.

\* Correspondence: Donghwi Park, Department of Rehabilitation Medicine, Daegu Fatima Hospital, 99 Ayang-ro, Dong-gu, Daegu 41199, South Korea (e-mail: bdome@hanmail.net).

Copyright © 2018 the Author(s). Published by Wolters Kluwer Health, Inc. This is an open access article distributed under the terms of the Creative Commons Attribution-Non Commercial-No Derivatives License 4.0 (CCBY-NC-ND), where it is permissible to download and share the work provided it is properly cited. The work cannot be changed in any way or used commercially without permission from the journal.

Medicine (2018) 97:22(e10983)

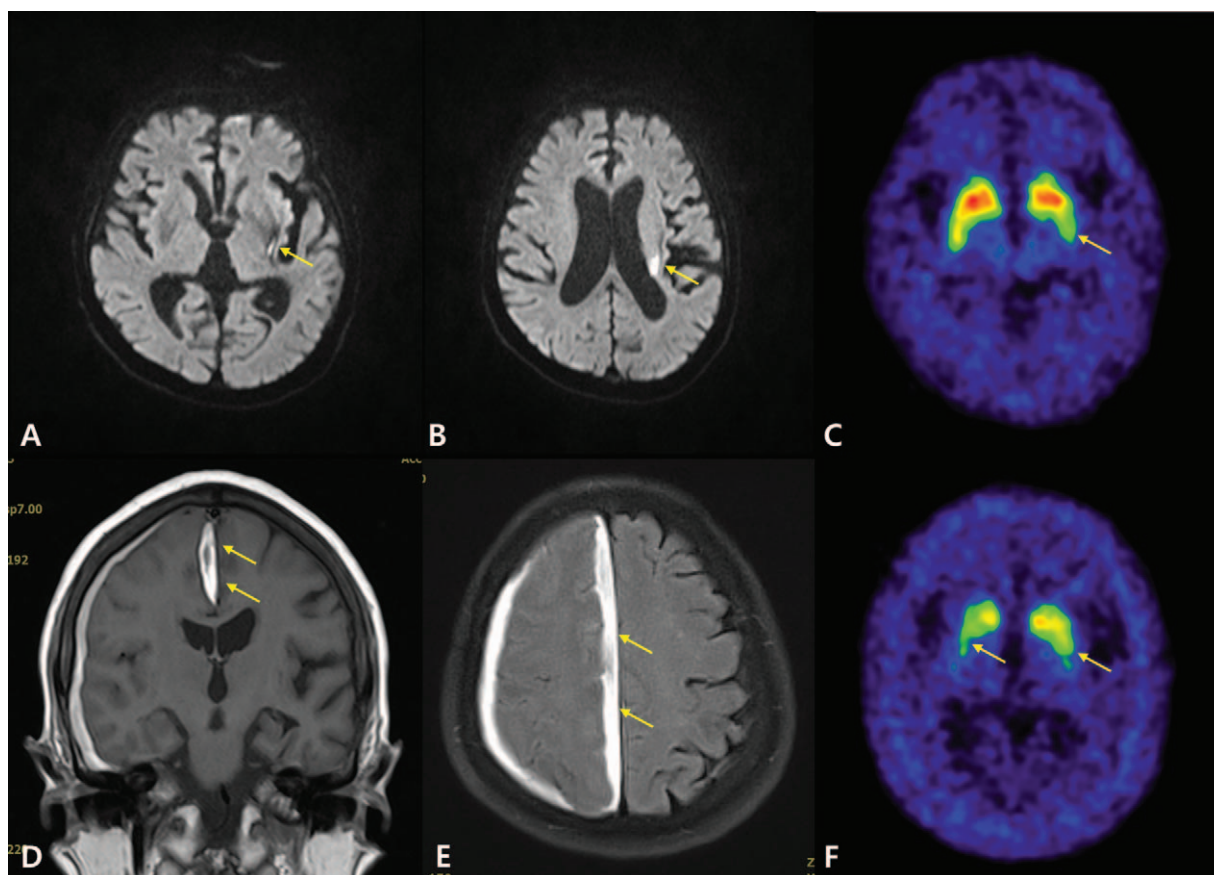
Received: 1 March 2018 / Accepted: 8 May 2018

<http://dx.doi.org/10.1097/MD.00000000000010983>

Therefore, when treatment for hand tremors begins, various pharmacological options have to be considered. In clinical practice, a practical approach is to initially check hand tremor patients for signs of Parkinson's disease (PD), because patients with PD can benefit from dopamine treatment.<sup>[3]</sup> However, only part of patients with PD tends to show a meaningful improvement in hand tremors for dopamine treatment.<sup>[3-5]</sup> On the other hand, dopamine treatment may help with hand tremors of patients with other disorders (e.g. midbrain tremor), but dopamine responsiveness can't be predicted by clinical assessment alone.<sup>[1]</sup> Although the usefulness and diagnostic popularity of fluorinated N-3-fluoropropyl-2β-carbomethoxy-3β-(4-iodophenyl) nortropane (F-18 FP-CIT) positron emission tomography (PET) in patients with PD is widely known, there has been no report about predictability of F-18 FP-CIT PET in dopamine responsiveness of hand tremor in patients with conditions other than PD. Here, therefore, we describe two interesting cases of hemiplegic patients with similar hemi-sided hand tremor in which the results of F-18 FP-CIT PET were helpful in treating tremor. The clinical data and images were obtained with informed consent of the patient including consent to use the photographs in this report, according to the Declaration of Helsinki.

## 2. Case 1

A 78-year-old man suddenly developed right hemiparesis (II/V, on the 0-V Medical Research Council scale,<sup>[6]</sup> in the arm and II/V



**Figure 1.** (A, B) Brain MRI of case 1. Diffusion weighted MR imaging showed an acute infarction in the left basal ganglia and periventricular area of the left MCA territory. (C) F-18 FP-CIT PET showed a slightly decreased uptake of the left basal ganglia, which was possibly associated with structural abnormalities due to infarction (arrow). (D, E) Brain MRI of case 2. FLAIR imaging showed a subdural hemorrhage in the falx cerebri and right frontoparietal cerebral cortex, which overlapped with the right ACA territory. (F) F-18 FP-CIT PET showed a rostrocaudal gradient in the bilateral putamen, which is consistent with IPD (arrow).

in the leg). The patient had no history of previous episodes, or any other sign or symptoms of PD. According to the brain magnetic resonance image (MRI), there was an acute infarction in the left basal ganglia and periventricular area of the left middle cerebral artery (MCA) territory (Fig. 1A, B). His muscle strength gradually improved (IV/V in the arm, IV/V in the leg), but 1 month later, he started to show resting tremor in his left hand (Supplementary 1\_Video 1, <http://links.lww.com/MD/C265>). His physical examination revealed a cogwheel rigidity in the left upper limbs, but without any tremor or cogwheeling in the foot. F-18 FP-CIT PET showed a slightly decreased uptake at the left basal ganglia. This was presumably associated with structural abnormalities due to infarction, considering the fact that it is not a typical PD pattern (rostrocaudal gradient in bilateral putamen) (Fig. 1C).<sup>[7]</sup> Then, he was started on a dopaminergic agonist (pramipexole 0.75 mg/d extended release). Two days after the medication, hand tremor in his left hand dramatically improved.

### 3. Case 2

A 65-year-old woman suddenly developed left hemiparesis (IV/V in the arm and IV/V in the leg) after a trauma to her head. The patient had no history of previous episodes, or any other sign or symptoms of PD. Brain MRI showed an acute subdural hemorrhage (SDH) in the falx cerebri and right frontoparietal cortex (Fig. 1D, E). Her muscle strength slightly improved (V/V in the arm and IV/V in the leg), but 3 months later, she started to

show a resting tremor in her left hand, with a mildly decreased left leg motion during gait (Supplementary 2\_Video 2, <http://links.lww.com/MD/C266>). In physical examination, a cogwheel rigidity in the left upper limb was also observed, but there was little tremor or cogwheeling in the right upper and both lower limb. Interestingly, F-18 FP-CIT PET showed a rostrocaudal gradient in the bilateral putamen, which is consistent with PD (Fig. 1F). She was then started on a dopaminergic agonist (pramipexole 0.75 mg/d extended release). Three days after the medication, hand tremor in her left hand was dramatically improved, and her mildly decreased left leg motion also showed a slight improvement.

### 4. Discussion

Nowadays, the functional integrity of the dopaminergic nigrostriatal pathway can be evaluated using F-18 FP-CIT PET.<sup>[8]</sup> A reduction of dopamine transporter (DaT) radioligand (ex. FP-CIT) uptake has been known to be correlated with the loss of presynaptic nigrostriatal neurons.<sup>[7]</sup> Interestingly, both patients showed similar hand tremors on one side, but the findings of F-18 FP-CIT PET were quite different. In the first case, a structural abnormality in the basal ganglia due to cerebral infarction seemed to be a plausible explanation for hemi-sided hand tremor. Conversely, in the second case, only hemi-sided hand tremor developed despite typical PD findings of bilateral putamen in F-18 FP-CIT PET. The mechanism of hemi-sided

hand tremor in the second case may be a functional disconnection of the striatum-supplementary motor area (SMA) circuitry.<sup>[9]</sup> As SDH occurred in the falx cerebri and right frontoparietal cerebral cortex, which overlapped with the right anterior cerebral artery (ACA) territory, the disconnection of the right basal ganglia output to SMA by traumatic brain injury could have resulted in hemi-sided hand tremor. This hypothesis can be supported by a previous report describing the development of hemi-sided hand tremor in patients with ACA territory infarction<sup>[2]</sup> and another report presenting significant DaT changes preceding the onset of clinical symptoms.<sup>[10]</sup> Therefore, in the second case, hemi-sided hand tremor can be thought to be caused by traumatic brain injury of the right frontoparietal hemisphere before the onset of idiopathic PD symptom.

In both cases, a dopaminergic agonist was started as the initial treatment, and seemed to be effective in managing the hand tremor. Considering the fact that it is difficult to predict dopamine responsiveness of hand tremor with clinical assessment alone in clinical practice, abnormal finding of F-18 FP-CIT PET may be helpful in predicting dopamine responsiveness of hand tremor, although the findings of F-18 FP-CIT PET were quite different. Collectively, in both cases, the dysfunction of the dopaminergic nigrostriatal pathway may lead to abnormal findings of F-18 FP-CIT PET, and these abnormal findings of F-18 FP-CIT PET in brain-lesion patients with hand tremor may help predict dopamine responsiveness of hand tremor. We believe that our report may be helpful in the diagnosis and treatment of hand tremors in patients with brain lesion.

#### Author contributions

**Conceptualization:** Donghwi Park.

**Data curation:** Kwang Jae Yu, Donghwi Park.

**Investigation:** Kwang Jae Yu.

**Writing – original draft:** Donghwi Park.

**Writing – review and editing:** Byung Joo Lee, Jin Han, Donghwi Park.

#### References

- [1] Imbach LL, Sommerauer M, Leuenberger K, et al. Dopamine-responsive pattern in tremor patients. *Parkinsonism Relat Disord* 2014;20:1283–6.
- [2] Deuschl G, Bain P, Brin M. Consensus statement of the Movement Disorder Society on Tremor. Ad Hoc Scientific Committee. *Mov Disord* 1998;13(Suppl. 3):2–3.
- [3] Cotzias GC, Papavasiliou PS, Gellene R. Modification of Parkinsonism—chronic treatment with L-dopa. *N Engl J Med* 1969;280:337–45.
- [4] Park D. Correspondence: The pathophysiology of pramipexole-associated dystonia in patients with Parkinson's disease. *Parkinsonism Relat Disord* 2017;38:106–7.
- [5] Park D. Pramipexole-induced limb dystonia and its associated complex regional pain syndrome in idiopathic Parkinson's disease: a case report. *Medicine* 2017;96:e7530.
- [6] Park D. Application of ultrasound-guided C5 nerve root block using polydeoxyribonucleotide in traumatic C5 nerve root injury caused by fracture of the articular process of the cervical spine: a case report. *Medicine* 2017;96:e8728.
- [7] Jin S, Oh M, Oh SJ, et al. Differential diagnosis of Parkinsonism using dual-phase F-18 FP-CIT PET imaging. *Nucl Med Mol Imaging* 2013;47:44–51.
- [8] Zijlmans J, Evans A, Fontes F, et al. [123I] FP-CIT spect study in vascular parkinsonism and Parkinson's disease. *Mov Disord* 2007;22:1278–85.
- [9] Miyagi Y, Morioka T, Otsuka M, et al. Striatal glucose metabolism and [18F]fluorodopa uptake in a patient with tumor-induced hemiparkinsonism. *Neurosurgery* 1993;32:838–41.
- [10] Marek KL, Seibyl JP, Zoghbi SS, et al. [123I] beta-CIT/SPECT imaging demonstrates bilateral loss of dopamine transporters in hemi-Parkinson's disease. *Neurology* 1996;46:231–7.