

Accepted Manuscript

Vein of Galen Malformation Thrombosis by Single Stage, Two-Coil Embolization

Nathan Todnem, MD, Vamsi Reddy, BS, Miranda Hayworth, MD, Cargill Alleyne, MD



PII: S1878-8750(18)31138-0

DOI: [10.1016/j.wneu.2018.05.184](https://doi.org/10.1016/j.wneu.2018.05.184)

Reference: WNEU 8246

To appear in: *World Neurosurgery*

Received Date: 26 March 2018

Revised Date: 23 May 2018

Accepted Date: 24 May 2018

Please cite this article as: Todnem N, Reddy V, Hayworth M, Alleyne C, Vein of Galen Malformation Thrombosis by Single Stage, Two-Coil Embolization, *World Neurosurgery* (2018), doi: 10.1016/j.wneu.2018.05.184.

This is a PDF file of an unedited manuscript that has been accepted for publication. As a service to our customers we are providing this early version of the manuscript. The manuscript will undergo copyediting, typesetting, and review of the resulting proof before it is published in its final form. Please note that during the production process errors may be discovered which could affect the content, and all legal disclaimers that apply to the journal pertain.

VoGM THROMBOSIS BY SINGLE STAGE, TWO-COIL EMBOLIZATION

Vein of Galen Malformation Thrombosis by Single Stage, Two-Coil EmbolizationNathan Todnem¹ MD, , Vamsi Reddy³ BS, Miranda Hayworth² MD, Cargill Alleyne⁴ MD**Keywords:** Vein of Galen Malformations, transarterial multistage embolization, complete occlusion, single stage transarterial venous sac embolization¹ Department of Neurosurgery, Augusta University, Augusta GA; no funding² Department of Neurosurgery, Augusta University, Augusta GA; no funding³ Medical College of Georgia- Augusta University, Augusta GA; no funding⁴ Department of Neurosurgery, Augusta University, Augusta GA; no funding**Corresponding Author Contact Information:**

Vamsi Reddy, BS
Medical College of Georgia
1120 15th Street,
Augusta, GA 30912
Office: (706) 721-3071
Fax: (706) 721-8084
Email: vareddy@augusta.edu

Abstract	0
Text Word Count	372
Number of References	3
Number of tables and/or figures	4 parts
Number of videos	0

*This paper has not been presented anywhere at any time previously

VoGM THROMBOSIS BY SINGLE STAGE, TWO-COIL EMBOLIZATION

Case Illustration:

Advances in endovascular embolization have dramatically improved morbidity and mortality among patients with vein of Galen malformations (VoGMs). Current methods favor transarterial multistage embolization to prevent normal perfusion pressure breakdown and massive venous thrombosis. Here we present a case of complete occlusion of a VoGM through progressive thrombosis of the venous sac after single stage transarterial venous sac embolization using only 2 coils with minimal coil mass. The patient originally presented at 3 months of age with increased head circumference, poor head control and a bruit over his anterior fontanelle. Further workup revealed mild congestive heart failure and obstructive hydrocephalus secondary to a 5 x 5cm aneurysm with venous drainage via a stenotic straight sinus on head CT. Diagnostic cerebral angiography confirmed the presence of a large mural type VoGM with arterial supply from two dominant posterior choroidal branches that coalesced at the junction of the lesion. An intracranial endoscope was used to place a VP shunt to avoid vascular injury. The decision was made to undergo a staged arterial embolization at 4 years of age after developing worsening right-sided hemiparesis. Prior to the procedure, it was appreciated that the high flow of vasculature would make coiling difficult; however, an attempt to embolize the arterial feeders to the lesion was pertinent to prevent his high output cardiac failure from worsening. From previous cases, there have been successful coil feeders associated with high flow lesions. During the surgical procedure by a dual trained cerebrovascular neurosurgeon, an attempt was made to occlude the posterior choroidal feeding vessel with a large 25mm x 50cm coil, followed by a 6mm x 20cm coil. The high flow of the lesion displaced both coils into the wall of the aneurysmal venous sac and the procedure was terminated. Interval MRI and angiography revealed progressive occlusion of the VoGM with partial thrombosis of the aneurysm at 7 months and complete thrombosis at 24 months post procedure, precluding a need for additional coiling. This case illustrates that a minimal change in the intramural flow dynamics of VoGMs could lead to progressive thrombosis of the lesion. This technique can be considered in the relatively stable patient, but must be studied in order to be replicated before being prioritized over a tiered approach.

References:

- Johnston I.H., Whittle I.R., Besser M., Morgan M.K. Vein of Galen malformation: diagnosis and management. *Neurosurgery*. 1987;20:747–758.
- Khullar D., Andeejani A.M.I., Bulsara K.R. Evolution of treatment options for vein of Galen malformations. *J Neurosurg Pediatr*. 2010;6:444–451.
- Yan J, Wen J, Gopaul R, Zhang CY, Xiao SW. Outcome and complications of endovascular embolization for vein of Galen malformations: a systematic review and meta-analysis. *J Neurosurg*. 2015; 123:872–890.

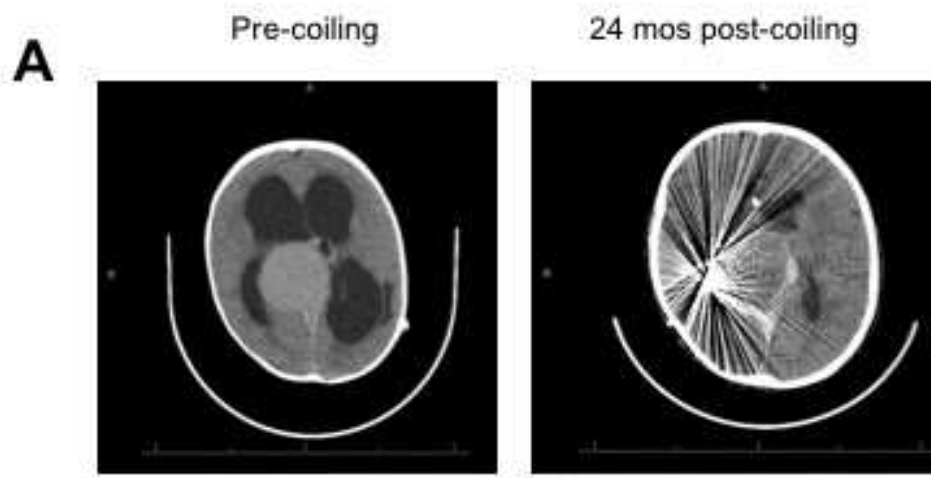
Figure legend:

- A. Axial head CT demonstrating aneurysmal VoGM at 7 months of age (left) and 24 months post transarterial endovascular coil embolization of the venous sac (right)
- B. 3D reconstruction of head CT angiogram showing two dominant medial and lateral posterior choroidal feeder branches coalescing at junction with the median prosencephalic vein (MPV)
- C. Top panel: Axial T2W MRI of VoGM pre-coiling (left) and at 7 months post-endovascular coil embolization with partial thrombosis of the aneurysm (middle). 3D reconstruction of MRA of VoGM demonstrating regression of arterial feeders previously supplying the VoGM. Bottom panel: Axial (left) and Sagittal (middle) views of T2W and sagittal T1W MRI with gadolinium contrast (right) at 5 years

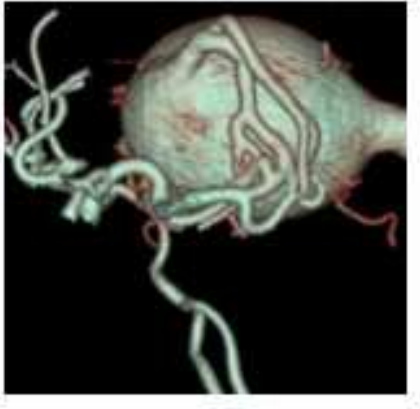
VoGM THROMBOSIS BY SINGLE STAGE, TWO-COIL EMBOLIZATION

post-endovascular coil embolization demonstrating interval thrombosis of VoGM varix with layering arrangement of thrombus and lack of intraluminal abnormal enhancement after gadolinium administration.

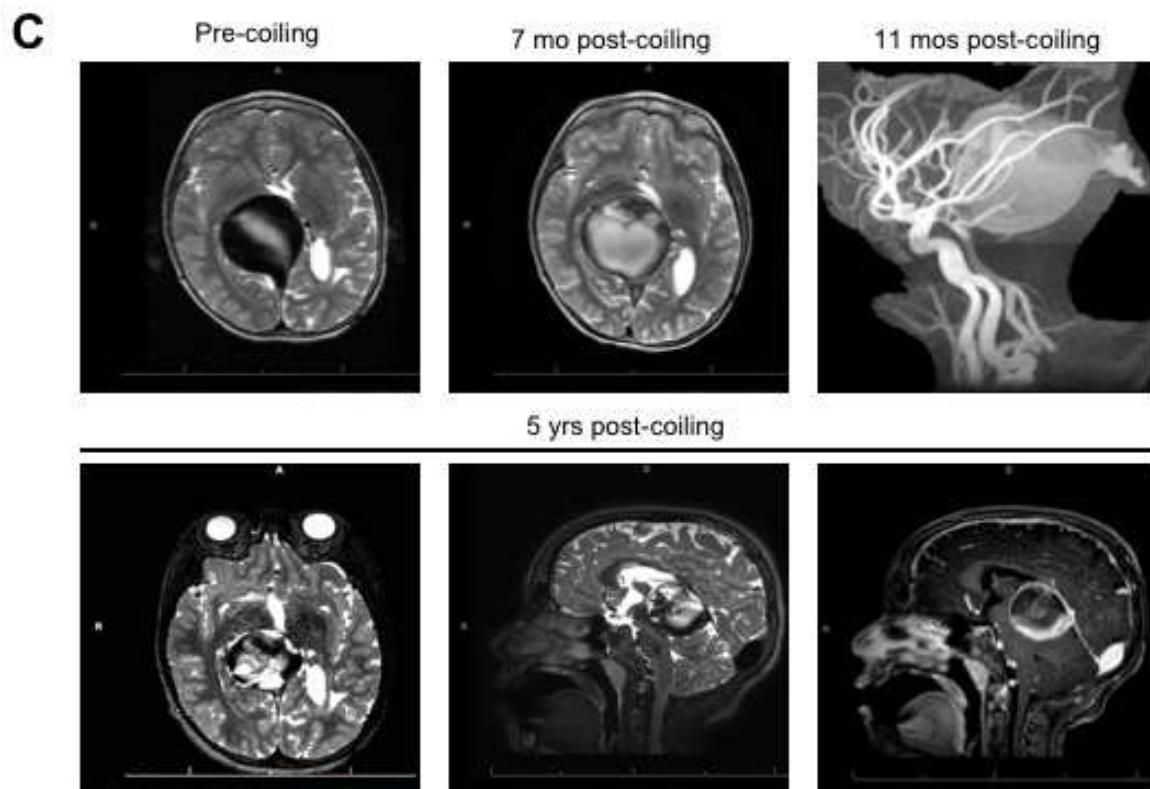
- D. Cerebral angiograms in lateral (top panel) and anterior-posterior (bottom panel) views of VoGM pre-endovascular coil embolization (left column), at the time of coil embolization with coils displaced into the wall of the aneurysmal venous sac (middle column) and 24 months after coil-embolization demonstrating complete occlusion of VoGM (right column)



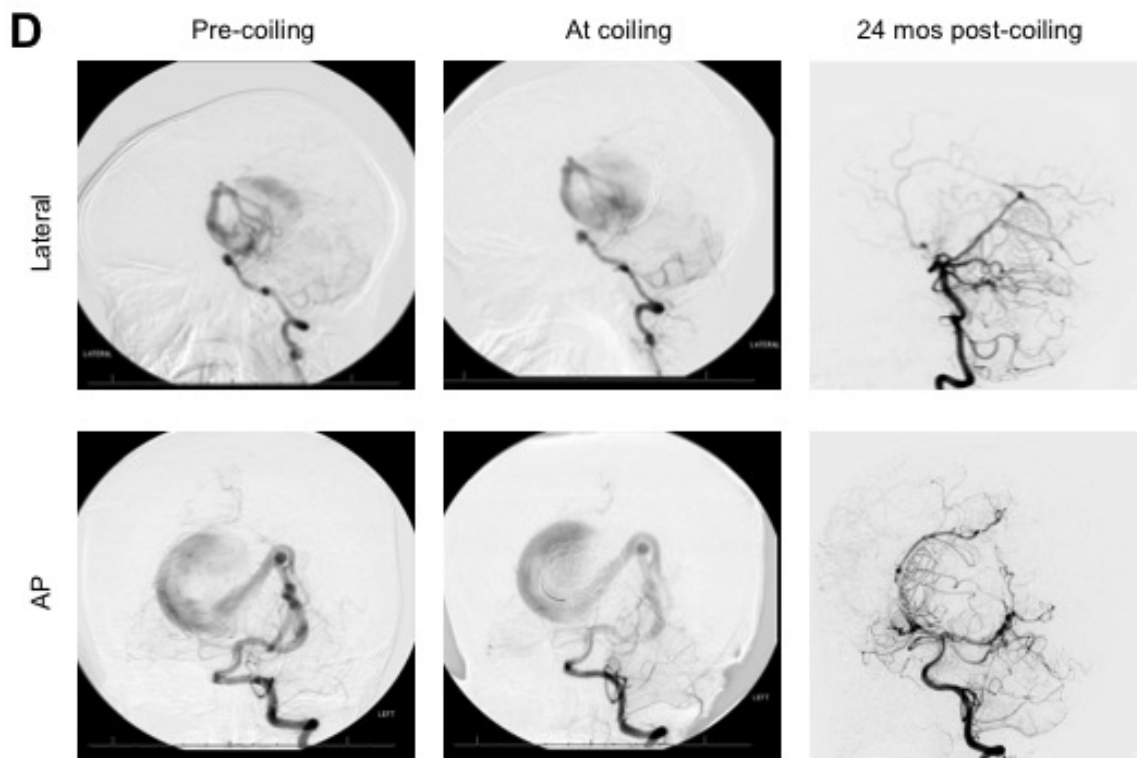
B



ACCEPTED MANUSCRIPT



ACCEPTED



Highlights

- Current methods to treat VOGMs favor transarterial multistage embolization to prevent normal perfusion pressure breakdown and massive venous thrombosis.
- Diagnostic cerebral angiography confirmed the presence of a large mural type VoGM with arterial supply from two dominant posterior choroidal branches.
- During the procedure, an attempt was made to occlude the posterior choroidal feeding vessel with a large 25mm x 50cm coil, followed by a 6mm x 20cm coil.
- The high flow of the lesion displaced both coils into the wall of the aneurysmal venous sac and the procedure was terminated.
- This procedure precluded a need for additional coiling.

Abbreviations

VOGM – Vein of Galen Malformation

ACCEPTED MANUSCRIPT