

## CASE REPORT

# New-onset headaches secondary to spontaneous intracranial hypotension

Subhendu Rath,<sup>1</sup> Ahmed Shaikh,<sup>2</sup> Priya Narwal,<sup>3</sup> Ankit Gupta<sup>1</sup>

<sup>1</sup>Department of Medicine, Hartford HealthCare, Hartford, Connecticut, USA

<sup>2</sup>Emergency Medicine, New York Presbyterian Hospital, New York, USA

<sup>3</sup>Department of Medicine, Rhode Island Hospital, Providence, Rhode Island, USA

## Correspondence to

Dr Ankit Gupta,  
ankitguptapulmonary@gmail.com

Accepted 18 May 2018

## SUMMARY

We describe the case of a 54-year-old man who presented with new-onset positional headaches and seizures, which were determined to be secondary to spontaneous intracranial hypotension due to a cervicothoracic spinal cerebrospinal fluid leak, and its associated complications.

## BACKGROUND

Spontaneous intracranial hypotension (SIH) is an under-recognised entity that can present with a myriad of neurological symptoms, the most common of which is headache. Certain complications of untreated SIH can be potentially life threatening. We would like to share our experience with the management of a patient with SIH.

## CASE PRESENTATION

### First encounter

A 54-year-old man with no significant medical history was referred for the management of pressure-like holocranial, positional headaches with poor response to analgesics, and focal-onset generalised tonic clonic seizures, ongoing for a week prior to presentation. The headaches were orthostatic right from the onset. He already had

a CT head and a lumbar puncture (LP), both of which were unremarkable. Opening pressure was not checked as the procedure was done with the patient in sitting position. Neurological examination showed no focal deficits. Magnetic resonance imaging/venogram of brain (MRI/V) done after the LP ([figure 1](#)) showed thrombosis of a right-hemispheric cortical vein, extending into the superior sagittal sinus, which was the likely explanation for the seizures. He was treated with levetiracetam, and heparin later transitioned to enoxaparin, and discharged home on symptom relief. MRI showed diffuse pachymeningeal enhancement typical of intracranial hypotension ([figure 2](#)).

### Second encounter

He presented 4 days later for the recurrence of positional headaches and was found to have bilateral subdural hygromas (SDHs) ([figure 3](#)). His anticoagulation was reversed for CT myelogram, a blood patch was administered in the L3–L4 interspace and MRI of cervical/thoracic / lumbo-sacral (C/T/L-S) spine and CT myelogram ([figure 4](#)) located the site of the leak to be in the region of the lower cervical/upper thoracic spine. His anticoagulation was resumed, and he was discharged home.

### Third encounter

He presented again 3 days later with progressive positional headaches, and this time he was found to have right-sided subdural haemorrhage at the site of the hygroma ([figure 5](#)). Once again, his anticoagulation was reversed, a second blood patch was administered and his SDH was managed conservatively.

## INVESTIGATIONS

First encounter: MRI/V

Second encounter: CT head, MRI C/T spine, CT myelogram

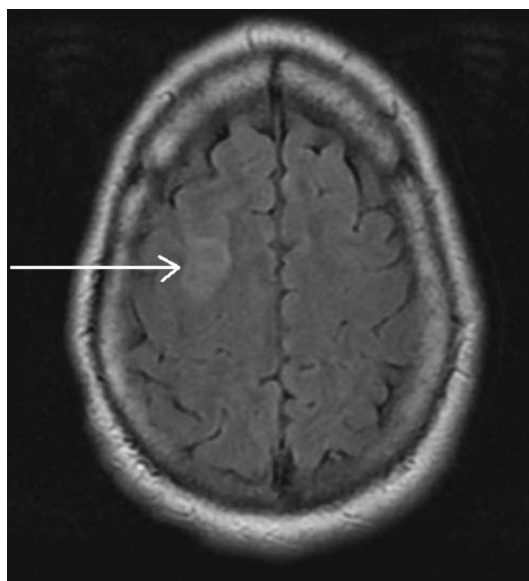
Third encounter: CT head

## DIFFERENTIAL DIAGNOSIS

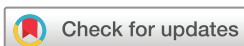Second encounter: the lumbar puncture could have contributed to the development of the SDHs in addition to the cervicothoracic spinal site of cerebrospinal fluid (CSF) collection identified on MRI spine/CT myelogram.

## TREATMENT

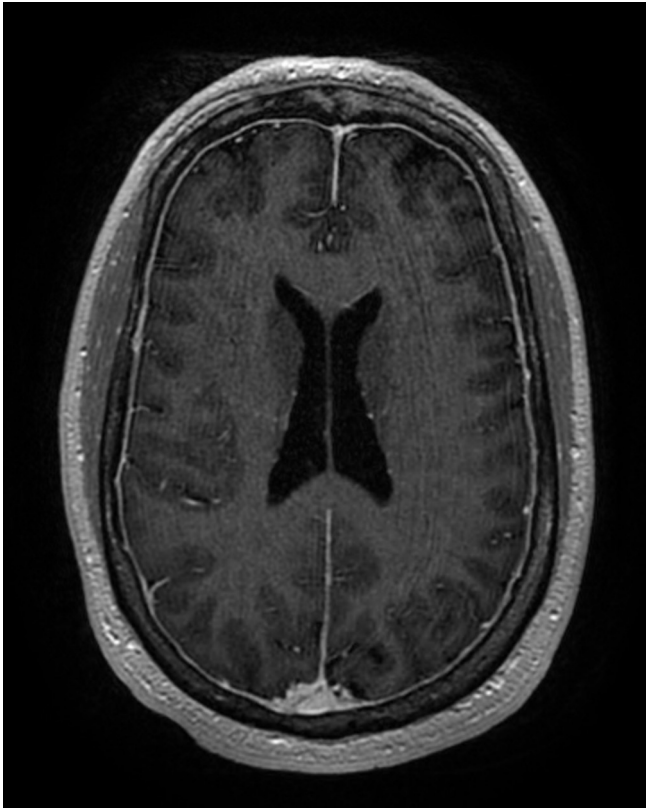
► Caffeine



**Figure 1** MRI brain T2 FLAIR showing a right frontal hyperintensity—area of venous infarction. FLAIR, fluid attenuated inversion recovery.



**To cite:** Rath S, Shaikh A, Narwal P, et al. *BMJ Case Rep* Published Online First: [please include Day Month Year]. doi:10.1136/bcr-2018-224240

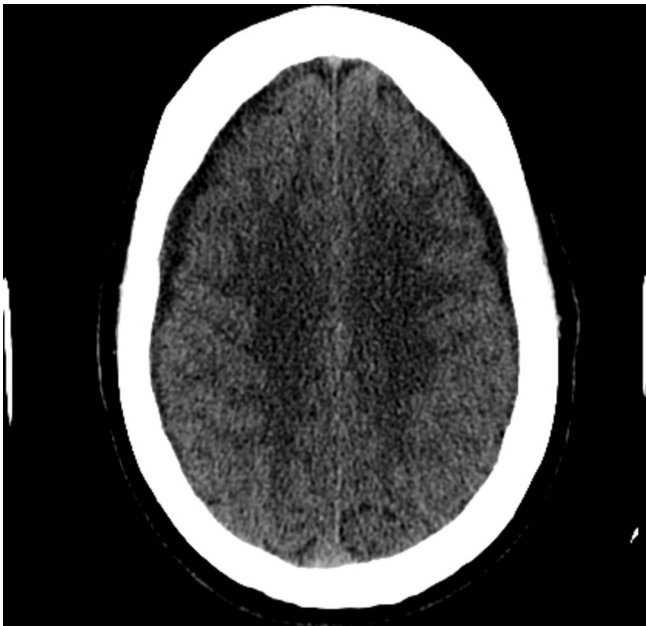


**Figure 2** MRI showing diffuse pachymeningeal enhancement.

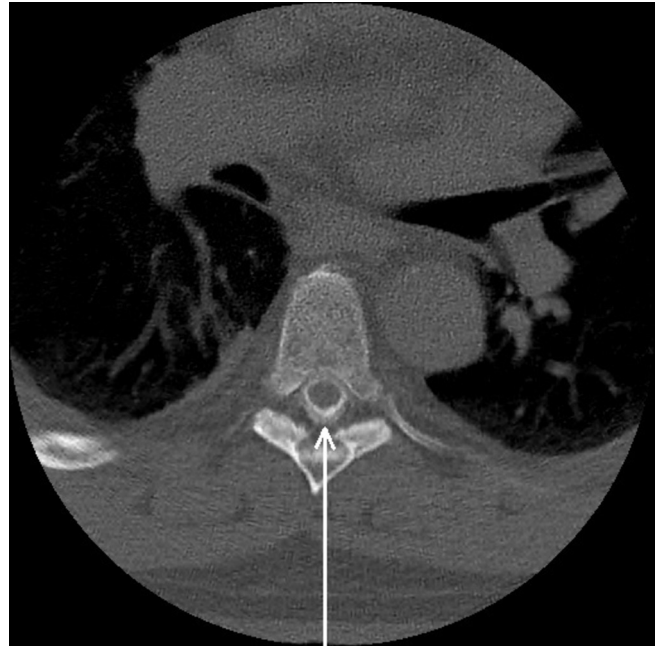
- ▶ Strict bed rest
- ▶ Multiple blood patches

**OUTCOME AND FOLLOW-UP**

After discharge following the third hospitalisation, the patient has been headache-free and seizure-free, and does not have any focal neurological deficits at 3 months of follow-up.



**Figure 3** CT head showing bilateral subdural hygroma.



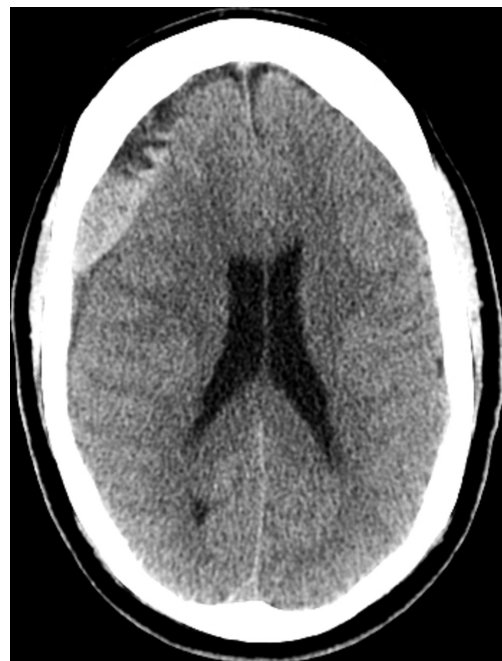**Figure 4** CT myelogram showing contrast collection posterior to the thoracic spinal cord.

**DISCUSSION**

Dural enhancement with contrast/meningeal enhancement can be seen after an LP, but in our patient, MRI was done after the LP.

Our patient developed SIH and associated complications of cortical venous and venous sinus thrombosis, and SDHs. There are a few prior reported cases of venous sinus thrombosis in association with SIH.<sup>1 2</sup> Cerebral venous sinus thrombosis has been described as an uncommon cause of iatrogenic postpartum headache after receiving epidural anaesthesia.<sup>3</sup>

The anticoagulation could have played a role in the development of SDH, but there have been reports<sup>4</sup> of SDH in patients with SIH in absence of anticoagulation.



**Figure 5** CT head showing right-sided subdural hygroma.

Headache Classification Committee of the International Headache Society in the third edition of the International Classification of Headache Disorders (ICHD-3) defined SIH as

a headache with low CSF pressure and absence of a procedure or trauma known to be able to cause CSF leakage, headache has developed in temporal relation to occurrence of low CSF pressure or CSF leakage, or has led to its discovery and is not better accounted for by another ICHD-3 diagnosis.<sup>5</sup> The aetiology often remains elusive, but pre-existing dural weakness is thought to play a role. Clinical features of SIH and associated complications are a result of compression/traction/distortion of brain structures and/or venous engorgement, and include SDHs, cerebral venous and venous sinus thrombosis, and rebound intracranial hypertension, among others.<sup>6</sup> Conservative treatment includes strict bed rest, adequate hydration,

use of caffeine/theophylline and so on. Blood patching/surgical intervention are indicated in intractable cases. Epidural blood patch has been described to eliminate the determinants of cortical venous thrombosis (CVT) (vein dilatation and slow vein drainage) and can be exclusively used to treat CVT by intracranial hypotension.<sup>7</sup>

**Contributors** SR and PN were involved in planning and acquisition of data. AS and AG were involved in literature review and preparing the manuscript.

**Funding** The authors have not declared a specific grant for this research from any funding agency in the public, commercial or not-for-profit sectors.

**Competing interests** None declared.

**Patient consent** Obtained.

**Provenance and peer review** Not commissioned; externally peer reviewed.

© BMJ Publishing Group Ltd (unless otherwise stated in the text of the article) 2018. All rights reserved. No commercial use is permitted unless otherwise expressly granted.

### Patient's perspective

I am still apprehensive about my condition, having sudden headaches are always at the back of my mind.

### Learning points

- ▶ Spontaneous intracranial hypotension (SIH) can be a risk factor for the development of cortical venous and venous sinus thrombosis, and subdural hygromas.
- ▶ Serial blood patches are often required for the treatment of SIH.
- ▶ In most cases, there is no identifiable offsetting event leading to the development of SIH.

### REFERENCES

- 1 Sinnaeve L, Vanopdenbosch L, Paemeleire K. Association of cerebral venous thrombosis and intracranial hypotension: review of 3 cases. *J Stroke Cerebrovasc Dis* 2017;26:e165–e169.
- 2 Rice CM, Renowden SA, Sandeman DR, *et al.* Spontaneous intracranial hypotension and venous sinus thrombosis. *Pract Neurol* 2013;13:120–4.
- 3 Gonen KA, Taskapilioglu O, Dusak A, *et al.* Persistent headache in a postpartum patient: the investigation and management. *BMJ Case Rep* 2013;2013:bcr2013009931.
- 4 Ferrante E, Rubino F, Beretta F, *et al.* Treatment and outcome of subdural hematoma in patients with spontaneous intracranial hypotension: a report of 35 cases. *Acta Neurol Belg* 2018;118.
- 5 Headache Classification Committee of the International Headache Society (IHS) The International Classification of Headache Disorders, 3rd edition. *Cephalalgia* 2018;38:1–211.
- 6 Mokri B. Spontaneous intracranial hypotension. *Continuum* 2015;21:1086–108.
- 7 Ferrante E, Citterio A, Valvassori L, *et al.* A case of convexity subarachnoid haemorrhage from intracranial hypotension treated with epidural blood patch. *Neurol Sci* 2012;33:715–6.

Copyright 2018 BMJ Publishing Group. All rights reserved. For permission to reuse any of this content visit <http://group.bmj.com/group/rights-licensing/permissions>.  
BMJ Case Report Fellows may re-use this article for personal use and teaching without any further permission.

Become a Fellow of BMJ Case Reports today and you can:

- ▶ Submit as many cases as you like
- ▶ Enjoy fast sympathetic peer review and rapid publication of accepted articles
- ▶ Access all the published articles
- ▶ Re-use any of the published material for personal use and teaching without further permission

For information on Institutional Fellowships contact [consortiasales@bmjgroup.com](mailto:consortiasales@bmjgroup.com)

Visit [casereports.bmj.com](http://casereports.bmj.com) for more articles like this and to become a Fellow